

Intracorneal ring implantation using Intralase® with partial coverage of the cone in a patient after an alkaline injury

Hanefi Cakir¹
Canan Asli Utine²
Mehmet Baykara³

¹Turkiye Hospital Eye Clinic, Istanbul,

²Department of Ophthalmology,
Yeditepe University, Istanbul,

³Department of Ophthalmology,
Uludag University, Bursa, Turkey

Purpose: To report the use of intracorneal ring segment (ICRS) implantation in a case of severe corneal thinning and irregularity secondary to alkali burn.

Case report: A 33-year-old man who had a history of ocular alkali burn in the right eye was admitted. His best corrected visual acuity was 0.16 with manifest refraction of +5.00 (−7.00 × 180°). Orbscan II® revealed steepening of >53 D superiorly, excessive thinning inferiorly with thinnest pachymetric reading of 269 μm. Two KeraRing® segments, 200 μm thick and 90° arced, were implanted. During intrastromal channel creation by Intralase®, the inferior half of the applanating cone was covered by a gelatinous paper to prevent the penetration of the laser beam into the anterior chamber. In the first year postoperation, best corrected visual acuity was 0.7 with manifest refraction of +1.50 (−3.50 × 35°). Visante® optical coherence tomography displayed ICRS at a depth of ~370 μm.

Conclusion: ICRS implantation with this novel approach may be an option in eyes with severe corneal irregularity and thinning.

Keywords: alkali burn, ectasia, intrastromal corneal ring segments

Introduction

The outcome of an ocular alkali burn might range from mild epithelial injury to permanent blindness secondary to destruction of the ocular surface and damage to the intraocular structures.^{1,2} Once immediate first aid and preventive measures are performed and a quiescent ocular surface with no inflammation is achieved, visual rehabilitation becomes important. Keratoplasty techniques in excessively thinned corneas with limbal stem-cell insufficiency pose unique challenges for surgeons.

Intracorneal ring segments (ICRS) have been used with success in the treatment of primary and secondary corneal ectasia.^{3–6} However, there have been no reports on their use in eyes that have suffered chemical injury.

Here, the authors report a patient with corneal thinning and irregularity secondary to alkali burn who underwent ICRS implantation using femtosecond laser keratome, with a novel approach to prevent the penetration of laser shoots through the excessively thinned cornea.

Case report

A 33-year-old man was admitted to Türkiye Hospital in April 2008 complaining of decreased vision in his right eye. In September 2002 he had sustained alkaline chemical injury from caustic soda (sodium hydroxide) in this eye. He had suffered

Correspondence: Canan Asli Utine
Department of Ophthalmology, Yeditepe
University, Gazi Umur Pasa Sok. No: 28,
Besiktas Balmumcu 34349 Istanbul, Turkey
Tel +90 533 5587635
Fax +90 212 2112500
Email cananutine@gmail.com

from nonprogressive loss of vision since then. At time of admission, his uncorrected visual acuity (UCVA) enabled him to count fingers held up at a distance of 2 m away. His best corrected visual acuity (BCVA) was 0.16 in Snellen lines, with a manifest refraction of +5.00 ($-7.00 \times 180^\circ$). The patient was emmetropic in the left eye, with a UCVA of 1.0. He mentioned that vision in his right eye had been the same as in his left eye before the injury. His medical records from the center where he had received immediate first aid eye care for the management of alkali burn showed that his UCVA and BCVA had remained stable since the injury. The potential visual acuity, assessed by placing a rigid contact lens over his eye, revealed a BCVA of 0.3.

Orbscan® II (Bausch & Lomb, Rochester, NY) topography revealed that severe corneal thinning was present inferiorly with excessive steepening in the superior quadrants. The minimum and maximum simulated K readings were 42.1 D and 48.6 D, respectively; however, steepening in the superior quadrants reached >53 D. The central and thinnest pachymetric readings were 358 μm and 269 μm , respectively, with a reverse keratectasia pattern (Figure 1). The corneal

transparency was not affected centrally, but, as a consequence of localized limbal stem cell deficiency, perilimbal opacification and corneal neovascularization were noted inferiorly. The intraocular pressure was 16 mmHg and fundus examination was unremarkable.

In an attempt to improve the vision, ICRS (KeraRing®, Mediphacos Ltda, Belo Horizonte, Brazil) implantation was planned for the correction of the corneal steepening and irregularity. Two segments with 200 μm thickness and 90° arcs were to be placed temporally and nasally, where corneal thicknesses were greater than 400 μm . The patient was given detailed information about the planned surgery; its possible risks and complications, particularly those that were relevant to his unique corneal characteristics; and possible modifications of the surgical technique. Written informed consent was obtained from the patient before any procedures were performed.

Surgical technique

The pachymetric readings were confirmed by ultrasonic pachymetry prior to the surgery. The femtosecond laser keratome (Intralase®, Advanced Medical Optics, Inc,

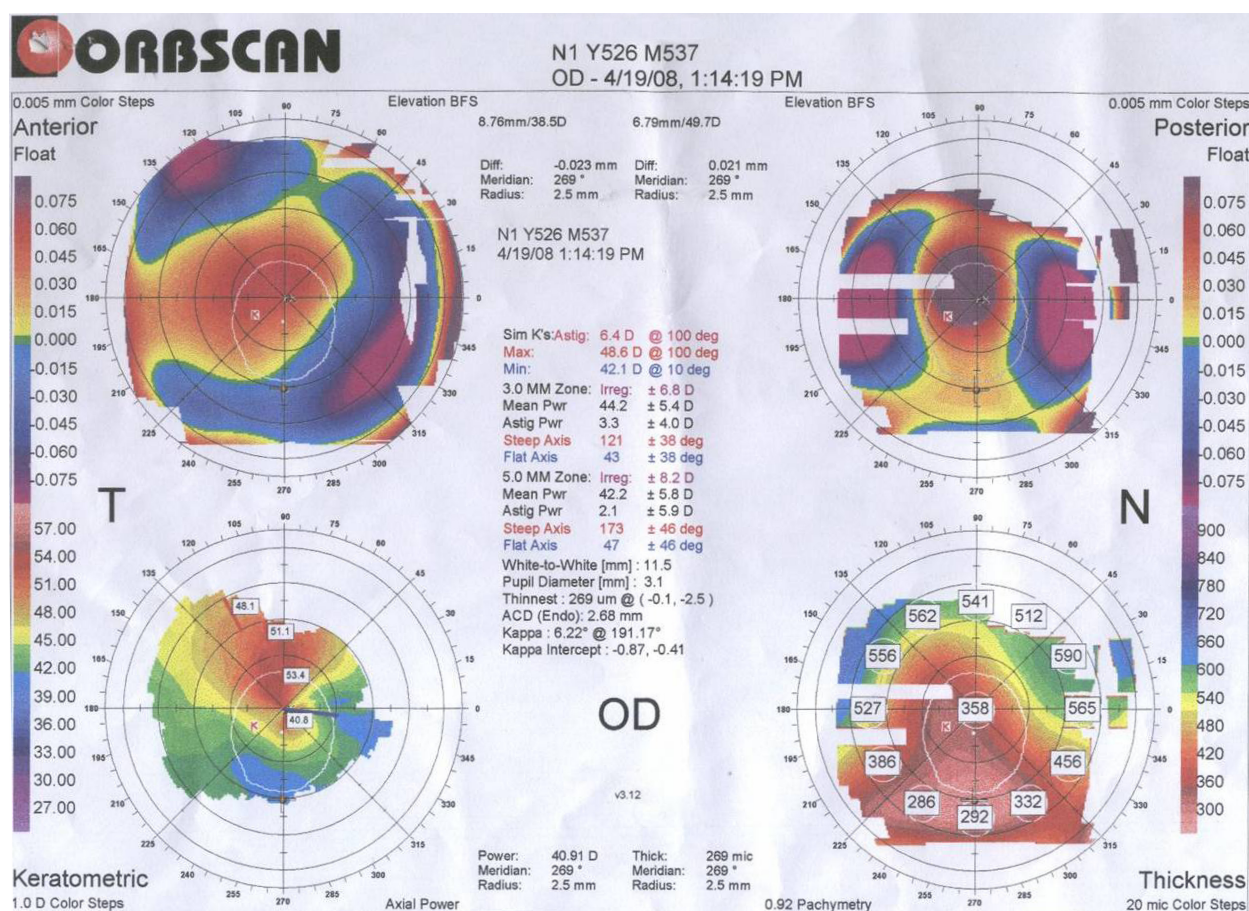


Figure 1 Patient's preoperative Orbscan II® corneal topography imaging information.

Abbott Park, IL) was used to create intrastromal channels for ICRS at a depth of 370 μm , with inner and outer diameters of 5.0 and 5.6 mm, respectively. A disposable suction ring and an applanation cone were used to stabilize and flatten the cornea to maintain a precise distance from the laser head to the focal point. The pulse duration was 600 fs. The femtosecond laser settings were as follows: entry cut thickness, 1 μm ; ring energy, 1.50–2.50 μJ ; and entry cut energy 1.50 μJ . Since the inferior cornea was thinner than the depth of the planned intrastromal channels, a novel technique had to be developed to prevent the penetration of the femtosecond laser beam into the anterior chamber. Thus, a piece of gelatinous paper was placed into the applanation cone of the femtosecond laser, at the area corresponding to the extremely thin inferior segment, which prevented the femtosecond laser beam from passing through. In this way, a C-shaped intrastromal channel with an inferior opening was created instead of a full circle (Figure 2A). This allowed the implantation of the ICRS as in routine procedures with no additional technical difficulties, while protecting the anterior segment structures inferiorly (see Supplementary video, available here).

Postoperatively, topical ofloxacin 0.3% (Exocin®; Allergan, Mougins, France) four times daily and prednisolone acetate 1% eye drops (PredForte®; Allergan, Mougins, France) four times daily were used for 1 week. The steroid eye drop was tapered over 3 weeks. Preservative-free artificial tear (Refresh plus®; Allergan, Irvine, CA, USA) eye drops were used as needed.

Postoperative course

In his examination 1 month postoperation, the patient's UCVA was 0.05 and his BCVA had improved to 0.6 with a manifest refraction of +3.00 ($-4.50 \times 45^\circ$). Slit-lamp examination revealed well-centered intracorneal rings with no migration or inflammatory reaction (Figure 2B). In Orbscan II® topography, minimum and maximum simulated K readings were 42.3 D and 38.5 D, respectively (Figure 3). Visante® (Carl Zeiss Meditec Inc, Dublin, CA) anterior segment optical coherence tomography displayed that the intrastromal channels were created at a depth of $\sim 370 \mu\text{m}$. No signs of damage to the anterior segment structures were noted.

In his examination at 1 year postoperation, his UCVA was 0.1 and BCVA was 0.7, with a manifest refraction of +1.50 ($-3.50 \times 35^\circ$) in the operated eye.

Discussion

Eyes affected by alkali burn are often complicated by limbal stem-cell insufficiency and dry eye, persistent epithelial defects, stromalysis, and even perforation.^{7–9} Penetrating keratoplasty (PK) poses technical difficulties in these eyes due to irregularly thinned corneas and high risk for graft rejection due to stem-cell insufficiency, corneal neovascularization, and dry eye. Corneal grafting should be deferred until a healthy ocular surface with no inflammation is achieved. ICRS implantations have been successfully implemented for the rehabilitation of primary corneal ectasias such as keratoconus and pellucid corneal marginal degenerations^{3,4,6}

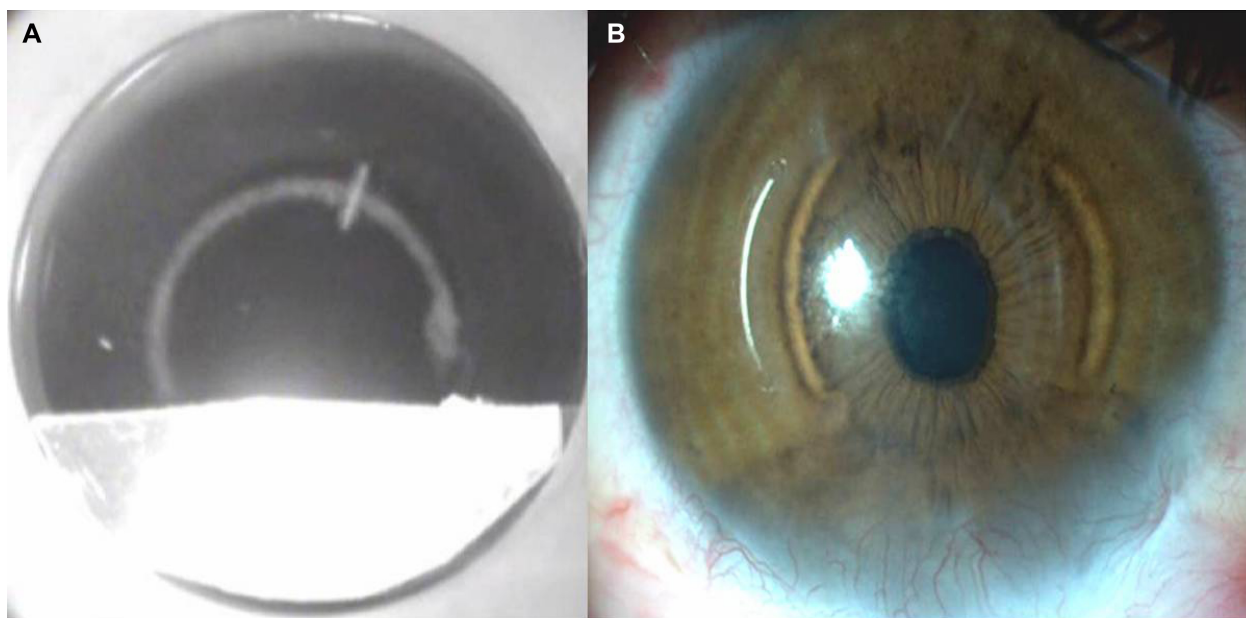


Figure 2 (A) Intraoperative image of intrastromal channel creation with femtosecond laser; inferior half of the cone was covered by a gelatinous paper. (B) Postoperative first-month slit-lamp image of the cornea showing the inferiorly thin and vascularized cornea and temporal and nasal placement of the intracorneal ring segments.

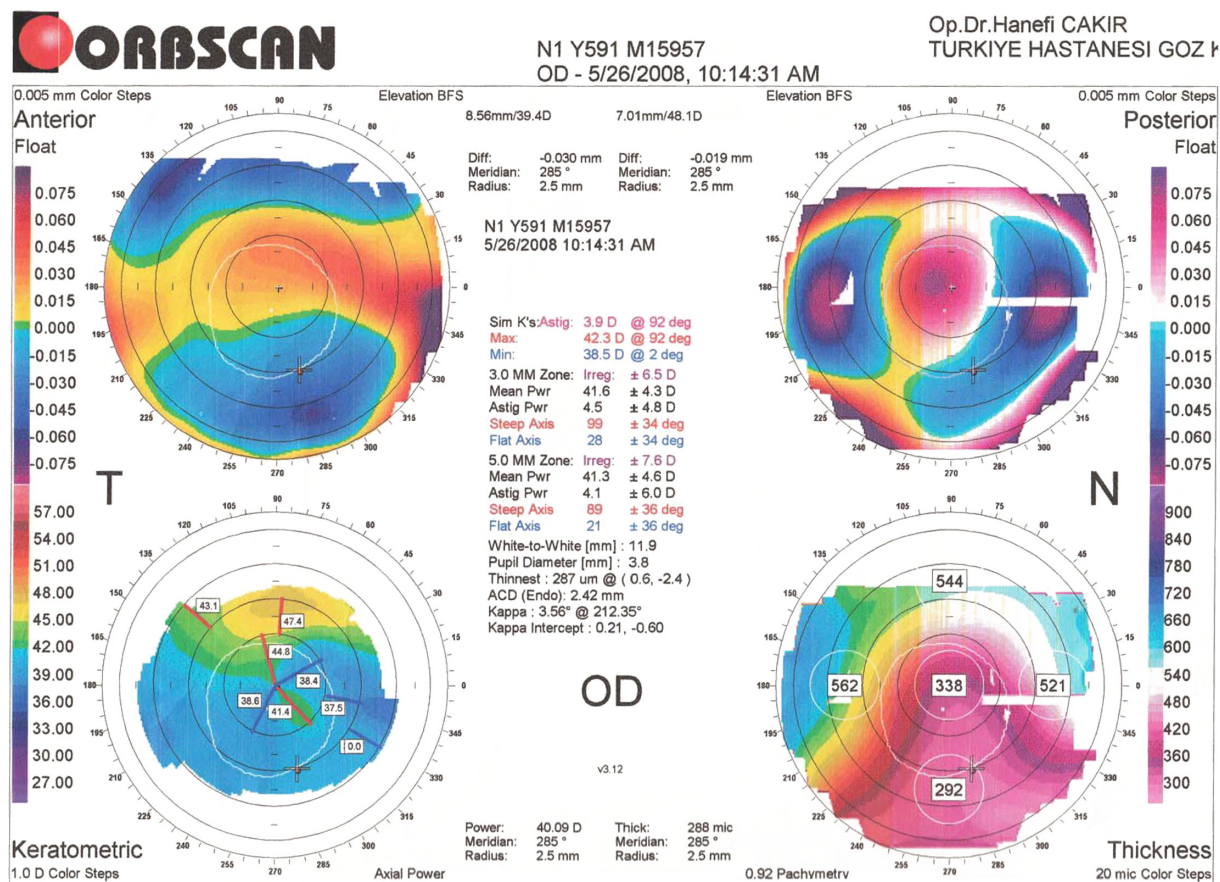


Figure 3 Patient's postoperative Orbscan II® corneal topography imaging information.

and iatrogenic postrefractive surgery corneal ectasias.^{5,6} However, there have been no reports on their use in alkali burn corneas.

The patient discussed here had been scheduled for PK in another clinic when he was first seen by the authors for a second opinion. Having high-risk characteristics for corneal graft rejection, the authors recommended a trial for intracorneal ring surgery, which would not rule out future PK in the case of an unsuccessful outcome. To achieve the maximum improvement in astigmatism in the central optic zone of the cornea, ICRS with smaller inner diameter were selected for implantation (ie, KeraRing®, Mediphacos). The thickness of the rings and depth of intracorneal channels were selected using the nomogram provided by the manufacturer. Given the high amount of astigmatism, implantation of two rings along the horizontal axis was planned. The second-line strategy would be placing one ring superiorly; however, the amount of cylinder that is expected to be corrected with that technique is low.

The femtosecond laser was used to create the intracorneal channels in this case, since it was of paramount importance that they be created at uniform intracorneal depth. During

manual intracorneal channel formation in such an injured cornea, epithelial disturbance and associated stromal edema can be inevitable and posterior corneal perforation the worst complication.⁶ In this case, it was aimed to arrest the laser shoots in the thinnest areas of the cornea, where the anterior chamber structures could have been affected. For this purpose, the region of the cone that corresponded to the inferior thinned segment of the cornea was covered by gelatinous paper. The gelatinous paper is covered with aluminium foil, which is used in the industry due to its resistance and protection performance for femtosecond laser illumination,¹⁰ the beam of which can travel in the transparent media and cause destruction to the tissue at a focused plane of predetermined distance, unlike the 196 nm excimer laser beam, which ablates the tissue it faces within a range of distances.

A C-shaped intracorneal channel, rather than a full circle, allowed the implantation of the intracorneal rings. Creating individual channels separately would have been harder to accomplish due to the technical difficulties in placing them at a regular distance from each other around the pupil, at different applications of the femtosecond laser cone. Therefore,

it was aimed to create a C-shaped channel in a single attempt for full-circular intrastromal channel.

Postoperatively, increased regularity of the central optic zone of the cornea with reduced irregular astigmatism led to subsequent improvement in the BCVA, to the level that might never be achieved after PK on such an irregular ocular surface. This relatively noninvasive method of optical correction also avoided the healing problems of graft failure/rejection and frequent follow-up visits.

In cases with irregular corneal surface due to chemical injury, it is important to perform manual ultrasonic pachymetry prior to surgery to confirm Orbscan readings, which can be inaccurate when corneal opacities are present. Additionally, these cases should be carefully followed up, as corneal neovascularization and stromal inflammation or melting can be stimulated by ICRS implantation even in normal eyes, and might be more likely in an eye with lasting damage from a chemical burn, even when the segments are placed away from the area of most severely injured cornea.

In conclusion, ICRS implantation might be an option for the management of corneal irregularities secondary to ocular surface problems, if special consideration is given and required preventive measures are taken according to the thickness of the cornea in the region of the femtosecond laser beam.

Disclosure

The study was presented at the 42nd National Meeting of Turkish Ophthalmology Society in Antalya, Turkey, in November 2008.

The authors do not have any financial or proprietary interests in any of the devices mentioned in this manuscript. There has been no public or private support in the conduct of this study.

References

1. Brodovsky SC, McCarty CA, Snibson G, et al. Management of alkali burns: an 11-year retrospective review. *Ophthalmology*. 2000;107(10):1829–1835.
2. Bagley DM, Casterton PL, Dressler WE, et al. Proposed new classification scheme for chemical injury to the human eye. *Regul Toxicol Pharmacol*. 2006;45(2):206–213.
3. Zare MA, Hashemi H, Salari MR. Intracorneal ring segment implantation for the management of keratoconus: safety and efficacy. *J Cataract Refract Surg*. 2007;33(11):1886–1891.
4. Akaishi L, Tzelikis PF, Raber IM. Ferrara intracorneal ring implantation and cataract surgery for the correction of pellucid marginal corneal degeneration. *J Cataract Refract Surg*. 2004;30(11):2427–2430.
5. Woodward MA, Randleman JB, Russell B, Lynn MJ, Ward MA, Stulting RD. Visual rehabilitation and outcomes for ectasia after corneal refractive surgery. *J Cataract Refract Surg*. 2008;34(3):383–388.
6. Carrasquillo KG, Rand J, Talamo JH. Intacs for keratoconus and post-LASIK ectasia: mechanical versus femtosecond laser-assisted channel creation. *Cornea*. 2007;26(8):956–962.
7. Hughes WF Jr. Alkali burns of the eye; review of the literature and summary of present knowledge. *Arch Ophthalmol*. 1946;35:423–426.
8. Hughes WF Jr. Alkali burns of the eye; clinical and pathologic course. *Arch Ophthalmol*. 1946;36:189–214.
9. Roper-Hall MJ. Thermal and chemical burns. *Trans Ophthalmol Soc U K*. 1965;85:631–653.
10. Martin S, Krüger J, Hertwig A, Fiedler A, Kautek W. Femtosecond laser interaction with protection materials. *Appl Surf Sci*. 2003;208–209:333–339.

Clinical Ophthalmology

Publish your work in this journal

Clinical Ophthalmology is an international, peer-reviewed journal covering all subspecialties within ophthalmology. Key topics include: Optometry; Visual science; Pharmacology and drug therapy in eye diseases; Basic Sciences; Primary and Secondary eye care; Patient Safety and Quality of Care Improvements. This journal is indexed on

Submit your manuscript here: <http://www.dovepress.com/clinical-ophthalmology-journal>

Dovepress

PubMed Central and CAS, and is the official journal of The Society of Clinical Ophthalmology (SCO). The manuscript management system is completely online and includes a very quick and fair peer-review system, which is all easy to use. Visit <http://www.dovepress.com/testimonials.php> to read real quotes from published authors.