

Williams–Campbell syndrome: a case report

Maria Konoglou¹
 Konstantinos Porpodis²
 Paul Zarogoulidis²
 Nikolaos Loridas¹
 Nikolaos Katsikogiannis³
 Alexandros Mitrakas²
 Vasilis Zervas²
 Theodoros Kontakiotis²
 Despoina Papakosta²
 Panagiotis Boglou⁴
 Stamatia Bakali⁵
 Nikolaos Courcoutsakis⁶
 Konstantinos Zarogoulidis²

¹First Pulmonary Clinic, “G. Papanikolaou” General Hospital, Thessaloniki, Greece; ²Pulmonary Department, “G. Papanikolaou” General Hospital, Aristotle University of Thessaloniki, Greece; ³Surgery Department (NHS), University General Hospital of Alexandroupolis, Greece; ⁴Pulmonary Department, University General Hospital of Alexandroupolis, Democritus University of Thrace, Greece; ⁵Microbiology Department, University General Hospital of Alexandroupolis, Democritus University of Thrace, Greece; ⁶Radiology Department, University General Hospital of Alexandroupolis, Democritus University of Thrace, Greece

Correspondence: Paul Zarogoulidis
 Pulmonary Department,
 “G. Papanikolaou” General Hospital,
 Aristotle University of
 Thessaloniki, Greece
 Tel +30 231 099 2433
 Fax +30 231 099 2433
 Email pzarog@hotmail.com

Introduction: Williams–Campbell syndrome, also known as bronchomalacia, is a rare disorder characterized by a deficiency of cartilage in subsegmental bronchi, leading to distal airway collapse and bronchiectasis. There have been few reports about patients affected by saccular bronchiectasis, paracatricial emphysema, and diminished cartilage. These are all characteristic of Williams–Campbell syndrome.

Case presentation: This report presents a 57-year-old woman with progressive dyspnea, cough, sputum production, and fever. The clinical and laboratory examination revealed that the patient had a respiratory infection due to bronchiectasis caused by Williams–Campbell syndrome, which was undiagnosed in the patient until then.

Conclusion: Although a rare syndrome, when patients’ signs and symptoms include recurrent respiratory infections, bronchiectasis, productive cough, and dyspnea, Williams–Campbell syndrome should be included in the differential diagnosis.

Keywords: bronchiectasis, Williams–Campbell syndrome, bronchomalacia

Introduction

Williams–Campbell syndrome is a rare disorder characterized by a deficiency of cartilage in subsegmental bronchi, leading to distal airway collapse and bronchiectasis. Williams–Campbell syndrome results from the absence of cartilage rings beyond the first and second bronchial divisions with resultant bronchiectasis, which typically affects the fourth- to sixth-order bronchi. Affected patients have normal caliber trachea and central bronchi. The symptoms and prognosis ultimately depend on the extent of cartilage maldevelopment of the bronchi. Although the syndrome has been best described in children with recurrent pneumonia and broncho-obstructive symptoms such as coughing and wheezing, there have been recent descriptions in adults as well.^{1,2}

Case presentation

A 57-year-old woman presented in the emergency department complaining of progressive dyspnea for the previous 5 days. On clinical examination she had productive cough with clear sputum and intermittent fever. She was a lifelong nonsmoker but with multiple hospitalizations due to respiratory infections and asthma-like episodes from the age of 8 years. During the past 15 years the patient was treated symptomatically with antibiotics, nebulizer bronchodilators, and long-term oxygen therapy (2 L/min/24 hours). She had daily exposure to gases from a brazier used at home

since childhood. Her family past medical history included her 30-year-old sister's sudden death from unknown reasons and her mother's infection from tuberculosis.

At the time of admission her axillary temperature was 38°C and blood pressure 120/70 mmHg. The patient was in respiratory insufficiency with an arterial pH of 7.46, PCO₂ of 56 mmHg, PO₂ of 72 mmHg, and HCO₃ of 30 mmol/L on air. Lung auscultation revealed widespread bilateral crepitating and crackles over the lower part of both lungs. No lymphadenopathy was found and examination of other systems was unremarkable. The electrocardiogram was normal with a heart rate of 69 beats per minute.

Laboratory data showed an elevated erythrocyte sedimentation rate of 100 mm/h and a white blood count of 9000/μL without peripheral blood eosinophilia, and C-reactive protein was 9.3 mg/dL. Biochemical values were normal. Her sputum sample for acid-fast bacilli was negative on multiple occasions. Sputum sent for fungal culture did not grow any organisms. Screening for *Aspergillus* in sputum cultivation was also negative. *Pseudomonas aeruginosa* was isolated from her sputum culture. Urine antigen for *Legionella* and *Streptococcus* was negative.

Her chest X-ray demonstrated increased lung volumes and revealed multiple ring shadows in lungs that were almost symmetrical in distribution and more apparent in the mid and lower zones. There was the sense of air-fluid levels in some of them corresponding to cystic bronchiectasis. Also, there was thickening of the interstitial network. The trachea and main bronchi were normal (Figure 1).

A laboratory investigation was performed for α-1 antitrypsin level and was normal. Total serum immunoglobulin (Ig)E concentration was elevated at 2500 U/mL (normal range 0–165 U/mL). Immediate cutaneous reaction to *Aspergillus fumigatus* was not available at the time of the patient's hospitalization; nevertheless, *A. fumigatus*-specific serum

IgE levels were 1.37 U/mL. This is essential for the diagnosis of allergic bronchopulmonary aspergillosis.³

Total serum IgG, IgA, and IgM levels were quantified to rule out hypogammaglobulinemia and did not reveal any deficiencies. Antinuclear and antineutrophilic cytoplasmic antibody tests were performed to exclude Churg–Strauss syndrome, and the results were negative.

A pulmonary function test demonstrated a mixed obstructive and restrictive pattern. There was a reduced forced vital capacity of 1200 mL (43.35% pred), reduced expiratory volume in 1 second of 720 mL (30.7% pred) with Tiffeneau index, reduced expiratory volume in 1 second/forced vital capacity of 76.29, and carbon monoxide-diffusing capacity of 28%.

A contrast-enhanced computed tomography (CT) scan of the chest demonstrated central cylindrical/cystic bronchiectasis involving segmental/subsegmental bronchi, bronchial wall thickening with air-fluid levels, and mucus plugging with predominant localization in the lower lobes. There was ground glass and tree-in-bud scattered in all lobes, a finding consistent with pneumonitis and acute bronchiolitis. Chest CT also revealed a mosaic picture, which also emerges in all lobe findings consistent with bronchiolitis obliterans. Collapse of bronchi with distal air trapping, the result of an excessively compliant bronchial wall, particularly in the left and right lower lobe, was also present (Figure 2).

We also performed fiberbronchoscopy on the patient. The findings were unremarkable. The bronchoalveolar lavage fluid obtained from the patient for an acid-fast *bacillus* was negative on multiple occasions, but the same *P. aeruginosa* was again isolated. The bronchoalveolar lavage fluid was negative for *Aspergillus* antibodies (IgG and IgM).

A diagnosis of saccular bronchiectasis due to Williams–Campbell syndrome was made based on clinicoradiological findings, laboratory testing, and past medical history. Genetic testing was planned, but the patient refused further investigations due to financial constraints. The patient was treated with intravenous antibiotics; third-generation cephalosporins, ciprofloxacin, and acetylcysteine; and chest physiotherapy, and was discharged after 1 month.

Written informed consent was obtained from the patient upon discharge for publication of this case report and all accompanying images.

Discussion

In 1960, Williams and Campbell first reported the unusual pattern of bronchiectasis in five patients whose disease presented in infancy with similar clinical features.

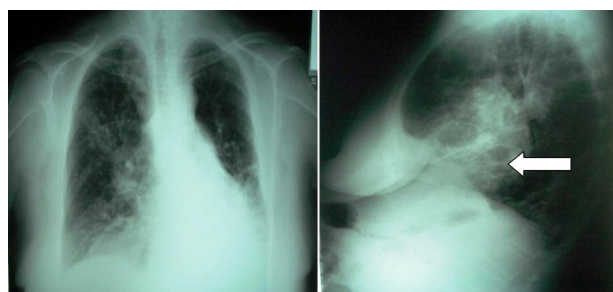


Figure 1 Posteroanterior and lateral chest radiographs demonstrating prominent lung markings and interstitial thickening, as well as volume loss, which is more evident in the left lower lobe and right upper lobe. Bronchiectases are more obvious in the lateral radiograph.

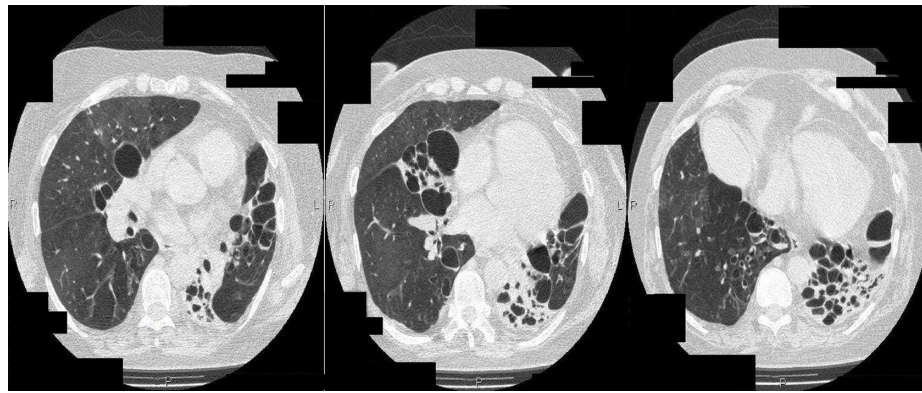


Figure 2 Sequential axial high-resolution computed tomography images of the upper, middle, and lower lung fields demonstrate multiple large and coalescent cystic bronchiectases, associated with volume loss. Some of the bronchiectases have air-fluid levels that are due to bronchial secretions.

They noted markedly compliant, soft central bronchi that ballooned on inspiration and collapsed on expiration. In this syndrome, bronchiectasis due to deficiency in cartilage of the third- to sixth-order bronchi generation is observed.

The syndrome is usually presented in childhood, with recurrent pneumonia and broncho-obstructive symptoms such as coughing and wheezing. Nevertheless, adult cases have been reported without pathologic confirmation.^{2,4–6} The symptoms and prognosis depend on the extent of cartilage maldevelopment. CT imaging demonstrates bilateral cylindrical/cystic bronchiectasis distal to the third-generation bronchi (segmental/subsegmental) with hyperinflation of the lung.^{4,7} On expiration, collapse of the bronchi with distal air trapping is observed as the result of an excessively compliant bronchial wall. The trachea and central bronchi remain normal in caliber, a distinguished feature of this disease. The mechanism for the deficiency in cartilage is not well understood; no evidence suggests that cartilage deficiency occurs outside of the bronchi.^{8,9} In addition, regarding diagnostic exams, bronchoscopy is often unrevealing.¹⁰

A genetic background and familial occurrence are also reported.^{10–12} The compliant bronchi collapse during coughing, leading to poor airway drainage. Subsequently, progressive obstructive disease develops, causing hyperinflation of the lung and segmental or lobar collapse. Recurrent destruction of the bronchial tree and inadequate clearance of mucus result in further damage to the lung parenchyma.^{8,9}

The long-term prognosis is variable, with rapid clinical deterioration and death in some children and prolonged survival in others.¹³ No specific treatment exists for Williams–Campbell syndrome. Prophylaxis from exacerbations remain the basis of treatment.^{14,15} Prophylaxis can be achieved if an oral or intravenous antibiotic is given for 7–10 days or until sputum production decreases. For severe cases, several

different antibiotics may be used sequentially in a continuous regimen to minimize bacterial resistance. Transplantation has been reported in a patient with severe respiratory symptoms from Williams–Campbell syndrome, but the patient died 1 year later. Upon postmortem examination it was observed that the main bronchi had bronchomalacia, which was attributed to a respiratory infection during the postsurgery period.¹ Moreover, when necessary, based on the patient's symptoms (bronchospasm and thick, tenacious sputum), a bronchodilator, combined with postural drainage and chest percussion, can help remove secretions. Respiratory exercise with free flow and bronchoscopy may be used to help mobilize secretions. Hypoxia requires oxygen therapy.¹⁴ Noninvasive positive airway pressure can be used when respiratory acidosis exists.¹⁶ Other acquired and congenital conditions associated with bronchiectasis, including ciliary dyskinesia, cystic fibrosis, allergic bronchopulmonary aspergillosis, and immunoglobulin deficiencies, must be excluded. We were able to exclude cystic fibrosis, immunodeficiencies, and aspergillosis.

Conclusion

Differential diagnosis of saccular bronchiectasis includes cystic fibrosis, allergic bronchopulmonary aspergillosis, α -1 antitrypsin deficiency, Ig deficiency, radiation fibrosis, tuberculosis, immotile (dyskinetic) cilia syndrome, Mounier-Kuhn syndrome, and Williams–Campbell syndrome. When patients' signs and symptoms include recurrent respiratory infections, bronchiectasis, productive cough, and dyspnea, Williams–Campbell syndrome should be included in the differential diagnosis.

Author contributions

PZ, MK, KP, and PB wrote the manuscript. AM, VZ, DP, NL, and TK diagnosed and treated the patient. SB performed the

microbiology tests. NC evaluated the radiographic images. NK and KZ provided useful insights.

Disclosure

The authors report no conflicts of interest in this work.

References

- Palmer SM Jr, Layish DT, Kussin PS, Oury T, Davis RD, Tapson VF. Lung transplantation for Williams-Campbell syndrome. *Chest*. 1998; 113(2):534–537.
- Amano S, Yoshida Y, Shimizu H, et al. An adult case of Williams-Campbell syndrome associated with pulmonary hypertension and a severe decrease in ventilatory response. *Nihon Kyobu Shikkan Gakkai Zasshi*. 1997;35(11):1265–1270.
- Tillie-Leblond I, Tonnel AB. Allergic bronchopulmonary aspergillosis. *Allergy*. 2005;60(8):1004–1013.
- Kaneko K, Kudo S, Tashiro M, Kishikawa T, Nakanishi Y, Yamada H. Case report: computed tomography findings in Williams-Campbell syndrome. *J Thorac Imaging*. 1991;6(2):11–13.
- Mitchell RE, Bury RG. Congenital bronchiectasis due to deficiency of bronchial cartilage (Williams-Campbell syndrome): a case report. *J Pediatr*. 1975;87(2):230–234.
- Watanabe Y, Nishiyama Y, Kanayama H, Enomoto K, Kato K, Takeichi M. Congenital bronchiectasis due to cartilage deficiency: CT demonstration. *J Comput Assist Tomogr*. 1987;11(4):701–703.
- Di Scioscio V, Zompatori M, Mistura I, et al. The role of spiral multidetector dynamic CT in the study of Williams-Campbell syndrome. *Acta Radiol*. 2006;47(8):798–800.
- Williams HE, Landau LI, Phelan PD. Generalized bronchiectasis due to extensive deficiency of bronchial cartilage. *Arch Dis Child*. 1972; 47(253):423–428.
- Marom EM, Goodman PC, McAdams HP. Focal abnormalities of the trachea and main bronchi. *AJR Am J Roentgenol*. 2001;176(3): 707–711.
- McAdams HP, Erasmus J. Chest case of the day. Williams-Campbell syndrome. *AJR Am J Roentgenol*. 1995;165(1):190–191.
- Jones VF, Eid NS, Franco SM, Badgett JT, Buchino JJ. Familial congenital bronchiectasis: Williams-Campbell syndrome. *Pediatr Pulmonol*. 1993;16(4):263–267.
- Wayne KS, Taussig LM. Probable familial congenital bronchiectasis due to cartilage deficiency (Williams Campbell Syndrome). *Am Rev Resp Dis*. 1976;114:15–22.
- Tucciarone L, Tomassini A, Anaclerio S, Colasanti A, Papandrea S. Left pneumonectomy in a child with congenital bronchiectasis. *Pediatr Med Chir*. 1996;18(3):323–325.
- Rosen JM. Chronic cough due to bronchiectasis: ACCP evidence-based clinical practice guidelines. *Chest*. 2006;129:122S–131S.
- Przerwa KB, Bestry I, Gawryluk D, Wiatr E. Case report: Williams-Campbell syndrome. *Pol J Radiol*. 2009;74:76–78.
- Wada H, Seto R, Yamada H, Nagao T, Hajiro T, Nakano Y. Respiratory failure of Williams-Campbell syndrome is effectively treated by noninvasive positive pressure ventilation. *Intern Med*. 2011;50(16): 1729–1732.

International Journal of General Medicine

Publish your work in this journal

The International Journal of General Medicine is an international, peer-reviewed open-access journal that focuses on general and internal medicine, pathogenesis, epidemiology, diagnosis, monitoring and treatment protocols. The journal is characterized by the rapid reporting of reviews, original research and clinical studies across all disease areas.

Submit your manuscript here: <http://www.dovepress.com/international-journal-of-general-medicine-journal>

Dovepress

A key focus is the elucidation of disease processes and management protocols resulting in improved outcomes for the patient. The manuscript management system is completely online and includes a very quick and fair peer-review system. Visit <http://www.dovepress.com/testimonials.php> to read real quotes from published authors.