

# Congenital depressed skull fracture in the absence of trauma: case report and literature review

Zulma S Tovar-Spinoza  
Peter D Kim

Department of Neurosurgery,  
SUNY Upstate Medical University,  
Syracuse, NY, USA

**Abstract:** There are limited reports of neonatal depressed skull fractures in the absence of any known trauma or obvious risk factors. Here we describe a male neonate with a significant frontal nontraumatic depressed fracture, his course of treatment, and a literature review. A male neonate was attended for a significant congenital depressed skull fracture in the left frontal bone. He was born full term after an uncomplicated delivery to a multiparous mother who was a human immunodeficiency syndrome (HIV)-positive immigrant from sub-Saharan Africa. The pregnancy was otherwise uncomplicated. There was no history of trauma to the mother during the pregnancy or delivery. Ultrasonography had been unremarkable. No other abnormalities were noted. The patient was brought to the operating room at the age of 13 days for elevation of his fracture due to its nonreducible nature. A small linear incision was made just posterior to the coronal suture. The dura mater was stripped and a combination of Penfield and periosteal elevators was used to elevate the depressed fracture. Nontraumatic depressed skull fractures are uncommon in neonates. The cause of this entity has not been identified, and many theories about its origin have been proposed. Treatment can be either surgical or conservative.

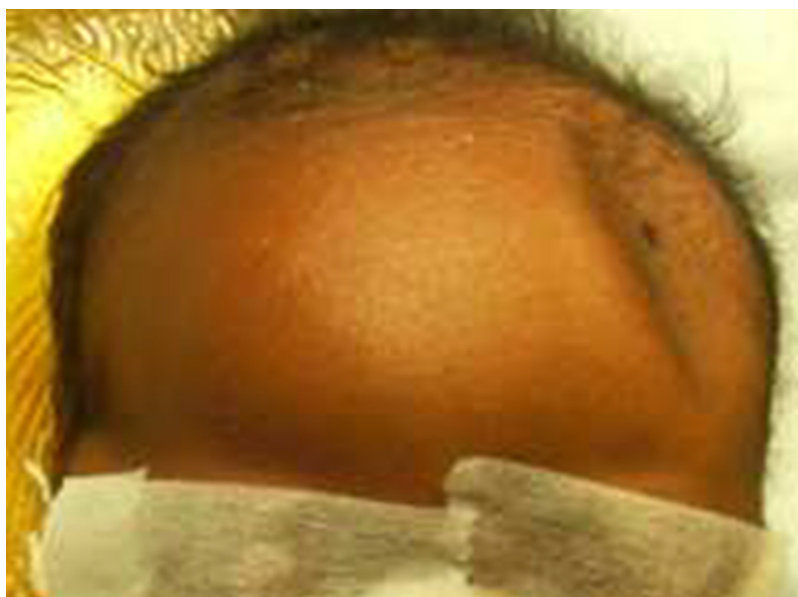**Keywords:** neonatal, congenital, depressed fracture, spontaneous, nontraumatic

## Case report

A full-term male neonate was attended for a significant congenital depressed skull fracture in the left frontal bone. He was born after an uncomplicated delivery to a multiparous mother who was a human immunodeficiency syndrome (HIV)-positive immigrant from sub-Saharan Africa. The mother was on a highly active antiretroviral regimen, and her HIV disease was well suppressed. The pregnancy was otherwise uncomplicated. There was no history of trauma to the mother during the pregnancy. Ultrasonography had been unremarkable. Calcium levels were normal in both mother and baby. The neonate was found to have a significant healed skull depression over the left frontal area (Figure 1), confirmed by a computerized tomographic scan of the head (Figure 2). No other abnormalities were noted. Neurological examination showed no deficits and the head circumference was within normal limits.

The infant had an otherwise uncomplicated neonatal course in which he received standard antiretroviral prophylaxis. The decision was made to bring the patient to the operating room at 13 days of age for elevation of his fracture. A small linear incision was made just posterior to the coronal suture. The dura mater was stripped, and periosteal elevators were used with unusual force to elevate the depressed fracture. Significant improvement in the depression was achieved with mild residual deformity (Figure 3).

Correspondence: Zulma Tovar-Spinoza  
Pediatric Neurosurgery, SUNY Upstate  
Medical University, 604 Jacobsen Hall,  
750 East Adams Street, Syracuse,  
NY 13210, USA  
Tel +1 315 464 4418  
Fax +1 315 464 4415  
Email tovarspz@upstate.edu

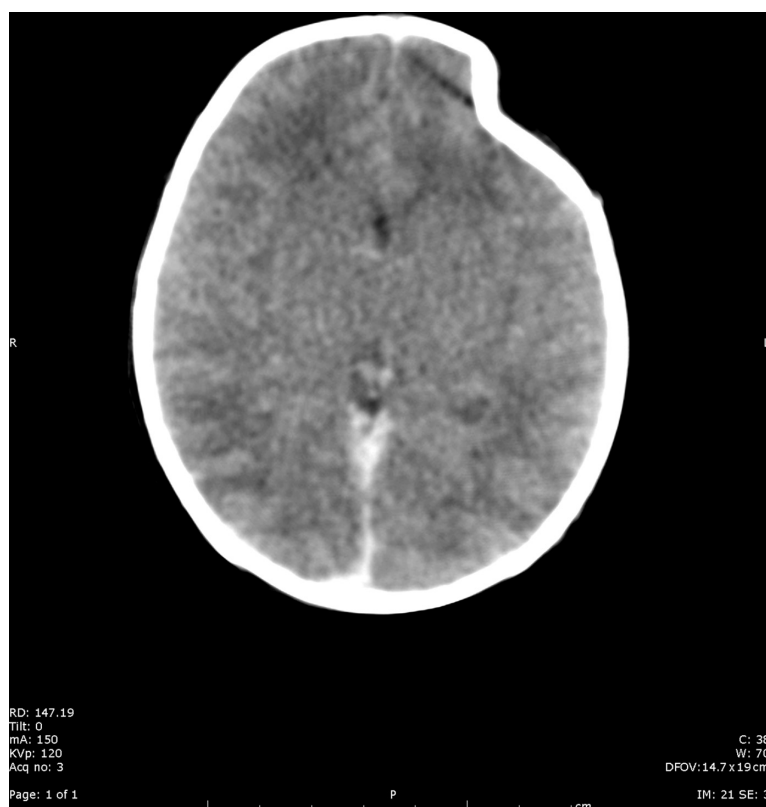

**Figure 1** Preoperative photograph of depressed fracture.

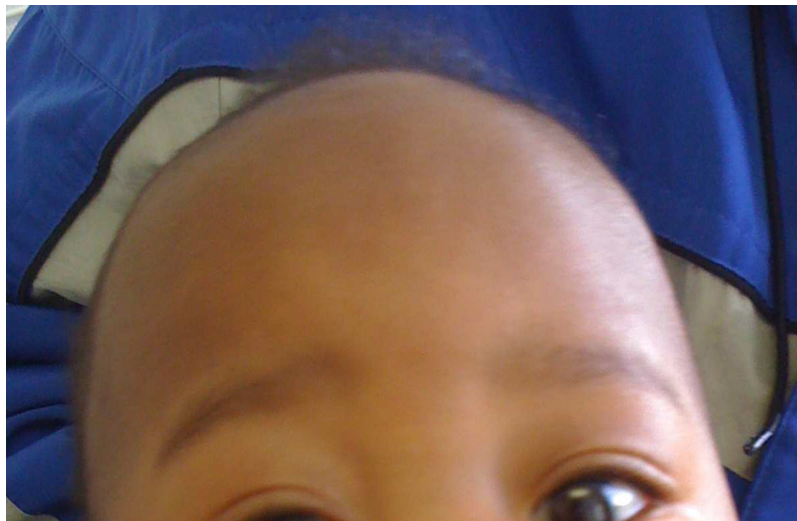
The infant recovered from surgery uneventfully and was noted to have an improved cosmetic result on follow-up at 5 weeks and at 3 and 7 months. At the most recent follow-up, the infant was found to be neurologically intact and achieving all developmental milestones.

## Discussion

Congenital skull fractures have been described in the literature in association with trauma, Ehlers-Danlos syndrome, multiple gestations, and maternal or fetal masses.<sup>1-4</sup> Depressed skull fractures associated with birth trauma are most often



**Figure 2** Preoperative computed tomographic scan of depressed fracture.



**Figure 3** Five months following surgical correction.

caused by pressure from forceps delivery or obstetric maneuvers during a difficult labor. There are limited reports of depressed skull fractures in the absence of any known trauma or obvious risk factors.<sup>5-7</sup>

Spontaneous intrauterine fractures in African women may be more common, and a larger series by Axton and Levy<sup>8</sup> suggests that the most frequent mechanism may be occult trauma from pressure of the fetal head on the sacral promontory, resulting in molding. Multiparity was also reported as a risk factor, which was postulated to be secondary to increased fetal size of successive pregnancies and decreased calcium due to poor nutrition and subsequent depletion with multiple pregnancies. Ultrasonography was not helpful in this case, and has been reported as normal in other similar cases. Whether this represents a limitation of imaging or rather suggests that these injuries occurred late in the gestation is not clear. In the event of a suspected head abnormality on fetal ultrasound, it may be worthwhile to perform fetal magnetic resonance imaging. At birth, computerized tomography is the method of choice to evaluate bone abnormalities and possible underlying bleeds. Structural magnetic resonance imaging is indicated if there are suspected structural brain anomalies, but it is probably better then to wait until the age of 3 months or more when the white/gray matter differentiation offers a higher quality view. The presence of HIV as a diagnosis in this case does not clearly point to causality of the fracture, although there has been an increased risk of trauma reported in neonates born to HIV-positive parents.<sup>9</sup>

Most spontaneous depressed skull fractures are, like the one in this patient, not true fractures but rather depressions, with the calvarium left in continuity. Congenital nontraumatic

linear fractures are exceedingly rare,<sup>6</sup> and likely represent a different mechanism.

Both operative and nonoperative approaches to congenital skull fractures have been described. In this case, we describe a gratifying outcome using an operative approach, and others have done so as well. Spontaneous resolution of smaller fractures has also been reported.<sup>8,10</sup> Active nonsurgical interventions have been described, including the use of vacuum elevation techniques<sup>3</sup> as well as digital compression on the margins of the depressed area (Raynor-Parsa maneuver). We favored an operative approach in this case because we felt that the fracture was large and deep enough to make spontaneous resolution unlikely.

Our operative technique of elevation by undermining the depression and applying direct upward pressure with elevators has been described previously.<sup>11</sup> This technique is dependent upon early intervention, because even at the age of 13 days, skull depression requires significant force to elevate it without disrupting the calvarium. Similar depressions presenting later in infancy would likely require formal craniotomy for repair.

The outcome is favorable in the absence of underlying abnormalities, with most case reports describing normal outcomes.<sup>6,7</sup> Infants with developmental delay after depressed skull fracture have also been reported, but the delay is likely to be the result of insults to the brain resulting directly from the original trauma. The child in this case is, at present, noted to be meeting developmental milestones.

## Disclosure

The authors report no conflicts of interest in this work.

## References

1. Gallo P, Mazza C, Sala F. Intrauterine head stab wound injury resulting in a growing skull fracture: a case report and literature review. *Childs Nerv Syst.* 2010;26(3):377–384.
2. Bar-Yosef O, Polak-Charcon S, Hoffman C, Feldman Z, Frydman M, Kuint J. Multiple congenital skull fractures as a presentation of Ehlers-Danlos syndrome type VIIC. *Med Genet A.* 2008;146A(23):3054–3057.
3. Ben-Ari Y, Merlob P, Hirsch M, Reisner S. Congenital depression of the neonatal skull. *Eur J Obstet Gynecol Reprod Biol.* 1986;22(4):249–255.
4. Heise R, Srivatsa P, Karsell P. Spontaneous intrauterine linear skull fracture: a rare complication of spontaneous vaginal delivery. *Obstet Gynecol.* 1996;87(5 Pt 2):851–854.
5. Vidal Micó S, López Navarro M, Téllez de Meneses M, Alvarez Garijo J, Pérez Aytés A. Spontaneous resolution of a congenital depressed skull fracture. *An Esp Pediatr.* 2004;54(1):78–80. Spanish.
6. Chauvet A, Boukerrou M, Nayama M, Dufour P, Puech F. Spontaneous intrauterine depression skull: myth or reality? *Gynecol Obstet Fertil.* 2005;33(9):582–585.
7. Dupuis O, Silveira R, Dupont C, et al. Comparison of “instrument-associated” and “spontaneous” obstetric depressed skull fractures in a cohort of 68 neonates. *Am J Obstet Gynecol.* 2005;192(1):165–170.
8. Axton J, Levy L. Congenital moulding depressions of the skull. *Br Med J.* 1965;1(5451):1644–1647.
9. Starc T, Langston C, Goldfarb J, et al. Unexpected non-HIV causes of death in children born to HIV-infected mothers. Pediatric Pulmonary and Cardiac Complications of Vertically Transmitted HIV Infection Study Group. *Pediatrics.* 1999;104(1):e6.
10. Rugolotto S, Grippaldi E, Sidoti G, Padovani E. Intrauterine depressed skull fracture with spontaneous resolution. *Pediatr Med Chir.* 2007;29(1):47–49.
11. Nakahara T, Sakoda K, Uozumi T, et al. Intrauterine depressed skull fracture. A report of two cases. *Pediatr Neurosci.* 1989;15(3):121–124.

### Research and Reports in Neonatology

### Publish your work in this journal

Research and Reports in Neonatology is an international, peer-reviewed, open access journal publishing original research, reports, editorials, reviews and commentaries on neonatal health. The manuscript management system is completely online and includes a very quick and fair

peer-review system. Visit <http://www.dovepress.com/testimonials.php> to read real quotes from published authors.

Submit your manuscript here: <http://www.dovepress.com/research-and-reports-in-neonatology-journal>

Dovepress