

Infantile hemangiomas: from pathogenesis to clinical features

Adena Rosenblatt¹
Erin F Mathes²
Kristina W Rosbe³

¹Department of Pediatrics, University of California, San Francisco,

²Division of Pediatric Dermatology, Departments of Dermatology and Pediatrics, University of California, San Francisco, ³Division of Pediatric Otolaryngology, Department of Otolaryngology – Head and Neck Surgery, University of California, San Francisco, CA, USA

Abstract: Infantile hemangiomas (IH) are benign vascular tumors consisting of a collection of immature cells, including progenitor stem cells and disorganized blood vessels. They are the most common benign tumors in childhood. Recently, there have been significant, exciting advancements in the understanding of the pathogenesis and treatment of infantile hemangiomas, which are discussed in this review. The decision to initiate treatment for IH is based on many factors, including size and location, functional compromise, psychosocial implications, and risks and benefits of the proposed therapy. For most families of children with hemangiomas, education about the natural history of IH and reassurance are often the only “treatment” required. A minority of patients with large, complex lesions or lesions that cause functional compromise require early intervention. These patients and families benefit from a multidisciplinary approach to care in vascular birthmark centers. Ongoing multi-institutional clinical trials will provide further important data on the efficacy and safety of hemangioma treatments.

Keywords: progenitor stem cell, glucose transporter 1, PHACES, LUMBAR, infantile hemangioma

Introduction

Infantile hemangiomas (IH) are benign vascular tumors consisting of a collection of immature cells, including progenitor stem cells and disorganized blood vessels. They are the most common benign tumors of childhood, occurring in approximately 4% of children by the age of 1.¹ Unlike other vascular growths, IHs have a proliferative phase shortly after birth, which is followed by a slower involution phase. They are more common in premature infants less than 2500 grams and in females.^{2–4} Other risk factors include Caucasian race, multiple gestation pregnancy, in vitro fertilization, and maternal age greater than 30 years.⁴ Recently, there have been significant, exciting advancements in the understanding of the pathogenesis and treatment of infantile hemangiomas.

Pathogenesis

IHs are primarily composed of endothelial cells, but they also contain fibroblasts, pericytes, interstitial cells, and mast cells. The exact mechanism of growth and involution of these cells is not clear.^{5–7} The patterns found in segmental hemangiomas suggest that at least some hemangiomas occur via developmental error as early as 4–6 weeks gestation.⁸

IHs arise because of aberrations in angiogenesis – the formation of new vessels from pre-existing vasculature – and de novo vasculogenesis – the formation of new vessels from progenitor cells – in the skin and other sites. One of the first findings that

Correspondence: Kristina W Rosbe
Professor of Otolaryngology and
Pediatrics; Director, Division of Pediatric
Otolaryngology, University of California,
San Francisco, 2330 Post Street Suite 310,
San Francisco, CA 94115-0342, USA
Tel +1 415 353 9385
Fax +1 415 885 3511
Email krosbe@ohns.ucsf.edu

distinguished blood vessels in hemangiomas from normal blood vasculature was the presence of glucose transporter 1 (GLUT1) in all stages of hemangiomas. GLUT1 is also present in placental blood vessels and the blood–brain barrier, but it is absent in the normal cutaneous vasculature.^{9,10} GLUT1 transports glucose across the plasma membrane and is widely distributed in fetal tissue, but it is usually only expressed in erythrocytes and endothelial cells in the blood–brain barrier in adults. This finding, along with studies that show a similar gene expression profile by microarray between hemangiomas and human placenta, initially supported the hypothesis that hemangiomas may be derivatives of the placenta.^{10,11} However, further investigation has revealed that this is unlikely, given that the endothelial cells in hemangiomas are of fetal, not maternal, origin and do not express trophoblastic markers.¹² Studies investigating the cellular origin of hemangioma endothelial cells (HemeEC) have demonstrated that these cells are derived from immature mesenchymal cells, also known as hemangioma stem cells (HemeSC). During proliferation, HemeSCs have features similar to early embryologic vessels – the cardinal vein and express CD133, a primitive cell marker.^{13,14} HemeSCs can differentiate into pericytes, endothelial cells, or adipocytes, and they play an important role in vasculogenesis.¹⁵ Implantation of CD133+ cells into immunodeficient mice isolated from IH gives rise to GLUT1+ vessels that later diminish and are replaced by adipocytes.¹⁶

HemeSCs produce vascular endothelial growth factor-A (VEGF-A), which activates vasculogenesis by binding to VEGF-receptor (VEGFR-1) and stimulates the differentiation of HemeSCs to endothelial cells.^{15,17} VEGFR-2 also appears to play a role in angiogenesis and vasculogenesis.^{18,19} One of the important activators of vascular endothelial growth factor-2 production in HemeSCs is nuclear factor κ -light-chain-enhancer of activated B cells (NF- κ B), a transcription factor that regulates genes involved with inflammation, cell proliferation, and cell survival. NF- κ B is known to be constitutively active in cancer and chronic inflammation.^{20,21} Corticosteroids, a treatment for hemangiomas, is thought to suppress NF- κ B and, in turn, VEGF-A production in HemeSC.²²

Beta-adrenergic receptors play a role in the pathogenesis of IH through multiple mechanisms. One of the early effects of beta-adrenergic receptors is vasodilation via release of nitric oxide (NO). These receptors also promote angiogenesis by stimulating the synthesis of proangiogenic factors, such as VEGF and metalloproteinases, as well as activating proangiogenic cascades. In addition, beta-adrenergic receptors inhibit apoptosis via the

sarc/mitogen-activated protein kinase pathway.²³ Beta-blockers, including propranolol, inhibit these actions.

Tissue hypoxia also appears to be an inducer of angiogenesis and vasculogenesis. Hypoxia leads to the activation of hypoxia inducible factor (HIF- α) in HemeSCs, which in turn increases the production and activity of GLUT-1 and VEGF-A.²⁴ In vitro studies have indicated that hypoxia and estrogen synergistically enhance hemangioma proliferation.²⁵

Finally, a new study by Greenberger et al suggests that the mammalian target of rapamycin (mTOR) may also play a role in stem cell proliferation. mTOR is a protein kinase that regulates cell growth, proliferation, motility, and survival. Thus, the use of rapamycin, a known mTOR inhibitor, has been found to prevent new blood vessel formation and increased the regression of already formed vessels in vitro, providing a new possible therapeutic option for IH in the future.¹⁵

Clinical features

Classification and growth characteristics

The diagnosis of IH can be made by history and physical exam. In contrast to other types of vascular malformations, IHs are usually absent at birth, or there may be a small area of pallor, telangiectasias, or duskiness. However, a fully formed mass at birth usually indicates a diagnosis other than IH. Superficial hemangiomas (Figure 1) involve the upper dermis and have a bright strawberry red color, whereas those with deep dermal and subcutaneous location (deep hemangiomas) may appear blue and be firm and rubbery on palpation. Mixed hemangiomas involve both superficial and deeper skin structures and have both features (Figure 1). A minimally proliferative IH is an uncommon type of IH that presents with fine telangiectasias, with a minimal-to-absent proliferative component (Figure 2). These IHs are GLUT-1 positive, indicating that they are, indeed, a variant of common IH.²⁶ Minimally proliferative IHs are more common in the lower body.^{26,27}

IHs can also be classified as localized, segmental, or indeterminate.^{28,29} Localized hemangiomas show spatial containment, as if arising from one central focus (Figure 1). Segmental hemangiomas correspond to a portion of a developmental segment or broad anatomical territory (Figure 1).²⁹ They are often plaque-like, with a linear or geographic configuration. Segmental hemangiomas have a higher risk of complications. Those hemangiomas, which are not clearly identifiable as localized or segmental, are termed indeterminate. Multiple localized hemangiomas are considered multifocal, and the presence of five or more confers an increased

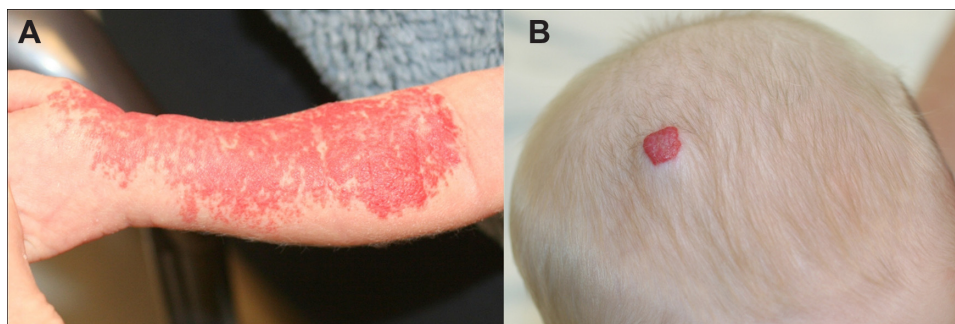


Figure 1 (A) Segmental, superficial hemangioma of the forearm in a 2-week-old infant; (B) Localized, mixed scalp hemangioma in a 4-month-old-infant.

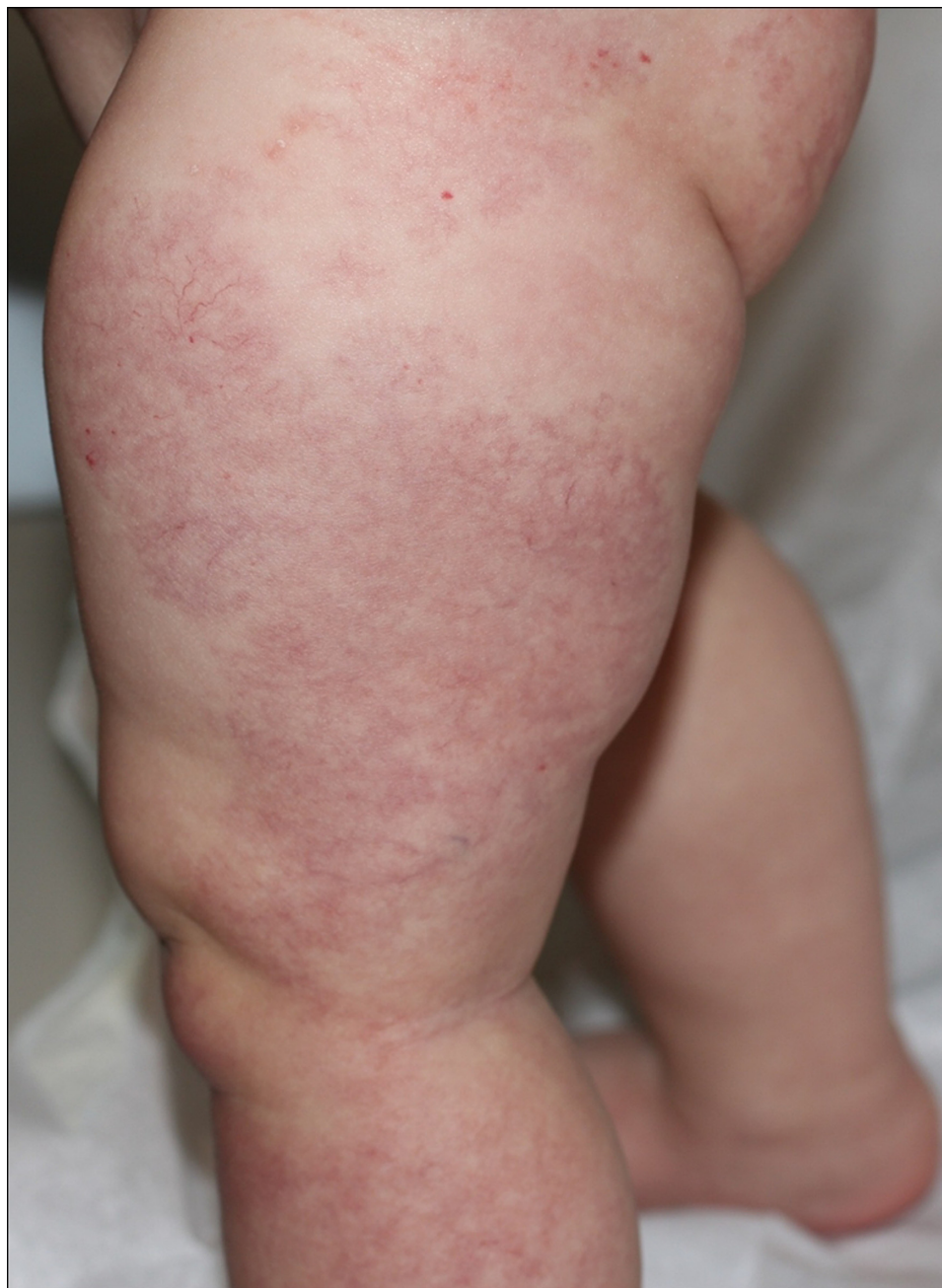

Figure 2 Minimally proliferative IH in a 1-year-old infant with a telangiectatic patch and small, bright red proliferative papules on the upper thigh and buttock.

risk of extra-cutaneous hemangiomas, particularly hepatic hemangiomas.³⁰ Multifocal hemangiomas are more common in premature infants.

Although many IHs are not present at birth, superficial IHs almost always become apparent within the first month of life. The period of most rapid growth occurs within the first 4 to 6 weeks, with 80% of growth completed by 5 months of age.³¹ Deep hemangiomas appear, on average, 1 month later than superficial IHs; however, in some cases, they are not appreciated until a few months of life. In contrast to the relatively short initial growth phase, the involution phase occurs over many months to years. During the involution phase, superficial IHs change in appearance to a dull red, then a gray or milky-white color, followed by flattening and softening, which is usually apparent by 1 year of age (Figure 3).³¹ Generally, smaller hemangiomas involute earlier than larger ones. Most IHs complete their course by the age of 7–10 years. Most children have normal skin after involution; however, a significant minority has telangiectasias, atrophy, fibrofatty residuum, or scarring (Figure 3).

Complications and associated syndromes

The majority of patients suffer no complications from IHs, but certain types of IH confer an increased risk of complications such as ulceration, disfigurement, and compromise of vital structures. Higher risk features include facial location, segmental distribution, and large size. Infants with high-risk

IH should be referred to a specialist early for consideration of work-up and treatment (Table 1).

Ulceration (Figure 4) is the most common complication of IH, occurring in approximately 15% of patients, usually during the proliferative phase, with a median age of onset of 4 months.³² It occurs most frequently with segmental IH and at sites that are exposed to moisture and friction, such as the perioral, perianal, and other intertriginous sites.³³

Facial hemangiomas can compromise vital structures, ulcerate, and lead to permanent disfigurement because IHs stretch the skin and disrupt important cosmetic units. The nasal tip and ear can be particularly problematic because the hemangioma can cause permanent changes in the cartilage (Figure 4). IH of the nose and ear can also ulcerate, sometimes deeply, leading to loss of cartilage. Perioral IHs lead to distortion of important cosmetic boundaries, such as the vermilion border, and commonly ulcerate, causing pain, poor feeding, and permanent scars.

In addition to disfigurement, periocular hemangiomas can lead to anisometropia and amblyopia, which, if untreated, can cause permanent visual loss.^{34,35} Direct pressure on the cornea can produce astigmatism or myopia, and the mass effect of the tumor itself can cause ptosis, proptosis, visual axis occlusion, or strabismus. Segmental hemangiomas involving the preauricular, mandibular area, chin, and neck (the “beard area”) have up to a 60% risk of having symptomatic airway hemangiomas, presenting with slow onset of biphasic stridor,

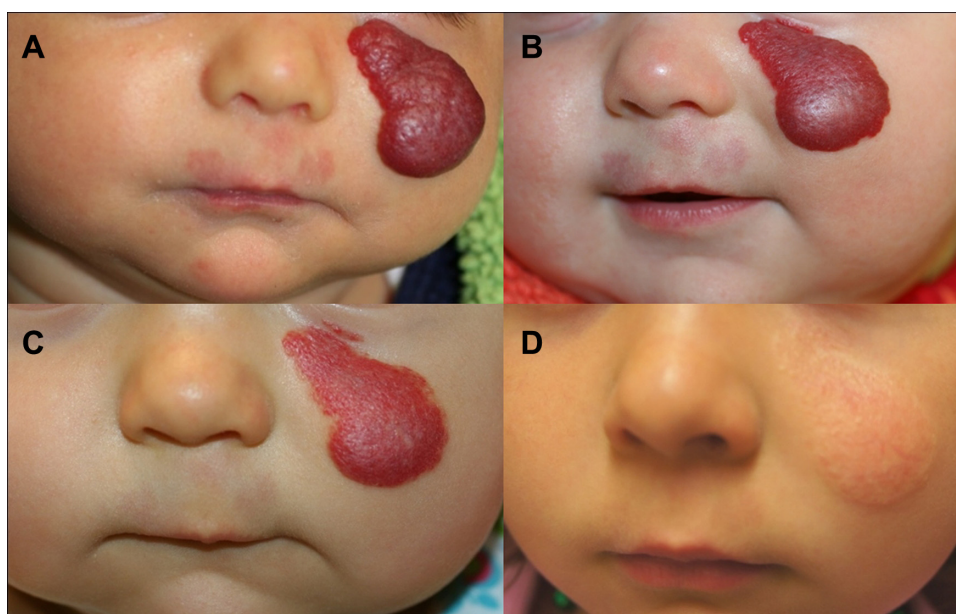

Figure 3 Thick superficial IH at (A) 3 months – proliferative phase; (B) 7 months; (C) 11 months – early involution; and (D) 2 years – after laser treatment demonstrating telangiectasias and subtle atrophodermia.

Abbreviation: IH, infantile hemangioma.

Table 1 Features of high-risk infantile hemangiomas and recommended evaluation

IH type	Associated risk	Recommended evaluation*
Facial, large segmental	PHACES syndrome	Echocardiogram; ophthalmology; MRI/MRA of the brain and neck
Nasal tip, ear, large facial	Permanent scarring, disfigurement	
Periorbital and retrobulbar	Ocular axis occlusion, astigmatism, amblyopia, tear-duct occlusion	Ophthalmology
Segmental "beard area," central neck	Airway hemangioma	Otolaryngology
Perioral	Ulceration, disfigurement, feeding difficulties	
Segmental overlying lumbosacral spine	Tethered spinal cord, genitourinary anomalies	MRI of lumbosacral spine; consider renal ultrasound
Perineal, axilla, neck, perioral	Ulceration	
Multiple hemangiomas (>5)	Visceral involvement (especially liver), hypothyroidism	Liver ultrasound; if liver hemangiomas are present, obtain TSH, T4, reverse T3

Note: *In addition to evaluation by pediatric dermatology or other specialists.

Abbreviations: IH, infantile hemangioma; MRA, magnetic resonance angiography; MRI, magnetic resonance imaging; PHACES, posterior fossa brain malformations, segmental cervicofacial hemangioma, arterial anomalies, cardiac defects or coarctation of the aorta, eye anomalies, sternal defects; TSH, thyroid stimulating hormone.

usually between 4 and 12 weeks of life (Figure 5).^{35,36} If the hemangioma continues to enlarge, respiratory distress can ensue and become life threatening. Hemangiomas involving the parotid gland may cause deformity of adjacent structures due to massive growth and, rarely, high-output congestive heart failure.^{37,38}

PHACES is a neurocutaneous syndrome associated with facial segmental IH, which consists of the following features: Posterior fossa brain malformations, segmental cervicofacial Hemangioma, Arterial anomalies, cardiac defects or Coarctation of the aorta (most often the transverse aorta), Eye anomalies, and Sternal defects (such as sternal clefting or supraumbilical raphe).³⁹ Diagnostic criteria for PHACES have been developed recently and are detailed elsewhere.³⁹ Up to one-third of patients with large (over 5 cm) segmental facial hemangiomas will be found to have PHACES, when studied thoroughly (Figure 6).³⁹ Prospective studies suggest that the greater the total surface area of the IH, the higher the risk of PHACES.⁴⁰ Arterial anomalies of the head and neck are more common than structural brain abnormalities.^{39,41,42} These intracranial arterial defects can lead to a Moyamoya phenomenon, ischemia, and stroke.⁴³ The most common cardiac anomaly is coarctation of the aorta, most often involving the transverse aorta. Brain imaging (magnetic resonance imaging [MRI] and magnetic resonance angiography), echocardiogram, and formal ophthalmologic evaluation should be considered in all infants with a large segmental hemangioma of the face.³⁴

Segmental hemangiomas overlying the lumbosacral or perineal area can have associated spinal, bony, and genitourinary anomalies. Several acronyms have been used to describe this association, including LUMBAR syndrome (Lower body hemangioma and other cutaneous defects, Urogenital anomalies, Ulceration, Myelopathy, Bony deformities, Anorectal malformations, Arterial anomalies, and Renal anomalies). Segmental hemangiomas overlying the lumbosacral spine have up to 50% increased risk of spinal dysraphism and tethered spinal cord, as well as a risk of intraspinal hemangiomas.⁴⁴ The liver is the most common extracutaneous IH site. Patients with multifocal

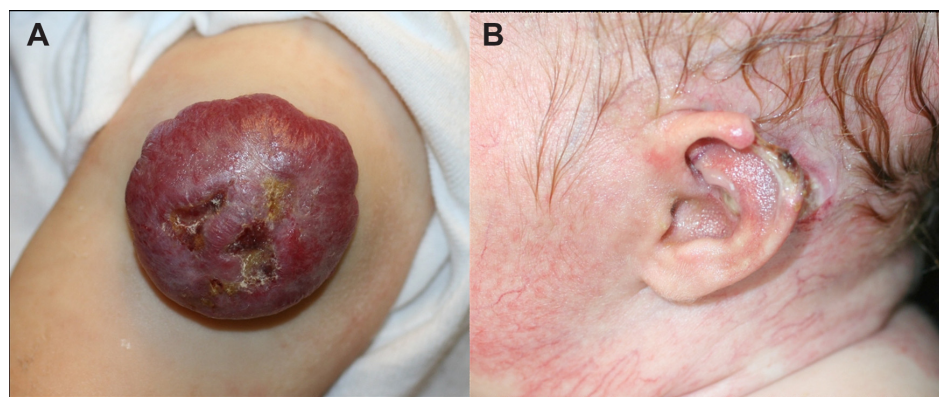


Figure 4 Two examples of ulcerated hemangiomas: (A) 8-month-old with a thick superficial IH with central ulceration and (B) 8 week-old with PHACES syndrome and a large, minimally proliferative IH with ulceration, leading to destruction of the helical cartilage.

Abbreviations: IH, infantile hemangioma; PHACES, posterior fossa brain malformations, segmental cervicofacial hemangioma, arterial anomalies, cardiac defects or coarctation of the aorta, eye anomalies, sternal defects.

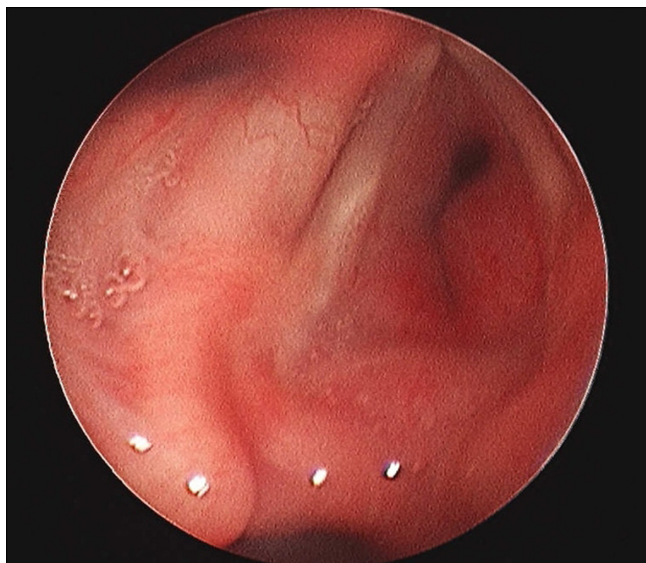


Figure 5 Bilateral subglottic hemangioma.

cutaneous hemangiomas (five or more) are at risk for hepatic hemangiomas and should have a liver-screening ultrasound to evaluate for liver IH. Few or multifocal liver hemangiomas are often asymptomatic, but they can sometimes cause high-output congestive heart failure. However, diffuse liver hemangiomas, a rare condition where the liver is almost replaced by hemangiomas, can result in life-threatening abdominal compartment syndrome and a severe form of hypothyroidism due to tumor-related deiodination of the thyroid.⁴⁵

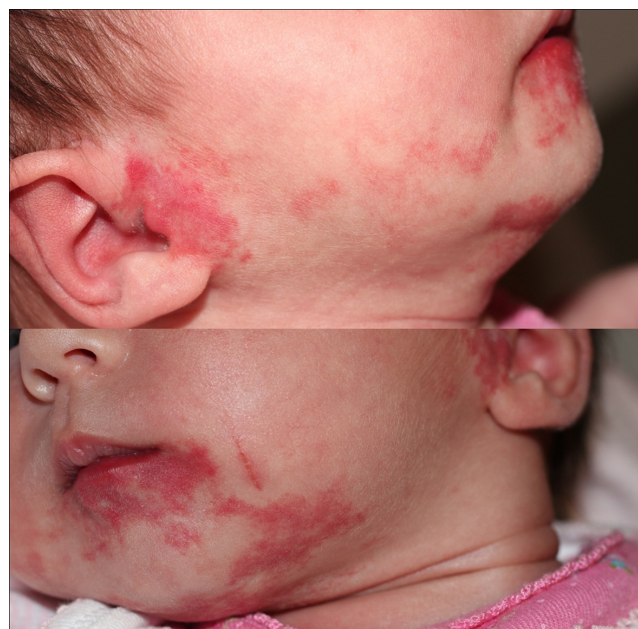

Figure 6 Bilateral "beard" IH in a 2-week-old infant. At 4 months, she presented with biphasic stridor and 90% occlusive airway IH.
Abbreviation: IH, infantile hemangioma.

Treatment

The decision to initiate treatment for IH is based on many factors, including size and location, functional compromise, psychosocial implications, and risks and benefits of the proposed therapy. For the majority of small hemangiomas, close observation and follow-up ("active non-intervention") is the most appropriate approach. These infants should be seen frequently (approximately monthly) during the proliferative phase of the IH. During these visits, discussions about the natural course of IH and the psychosocial impact of the IH on the child and/or the family should occur.⁴⁶ Photographs of the outcome of similar lesions are often helpful. As facial hemangiomas, in particular, can cause psychological suffering once the child reaches school age, potential treatment options should be discussed prior to the child starting elementary school. If it is decided that treatment is necessary, options include pharmacologic, laser, and surgical interventions.

Historically (prior to 2008), systemic corticosteroids were the first-line medical treatment for IH, but their use has been largely replaced by propranolol. Corticosteroids are most effective during the growth phase, causing slowing or cessation of growth in up to 90% of cases, with actual shrinkage in approximately one-third of cases. Prednisone or prednisolone is generally given at a dose of 2–3 mg/kg/day, typically for 4 to 8 weeks, followed by a tapering of varying length, depending on the age of the child and indication for treatment. A meta-analysis showed an 84% response rate with an average dose of 2.9 mg/kg for a mean of 1.8 months before tapering. Although 3 mg/kg/day is more effective (94% response) than 2 mg/kg/day (75% response), greater adverse events are found with the higher dose.⁴⁷ Adverse events with prolonged high-dose systemic corticosteroids are relatively common and can be severe, such as cushingoid faces, personality changes, gastric irritation, fungal infection, hypertension, steroid-induced myopathy, immunosuppression, transient adrenal insufficiency, and diminished gain of height and weight during treatment.^{48,49} Prednisone is now being used for patients where propranolol is contraindicated, or where propranolol is not having the desired clinical response. The combination is used in symptomatic airway hemangiomas, with the goal of tapering the steroids quickly once the propranolol has reached target dosing.

In the last few years, oral beta-blockers, in particular propranolol, have dramatically altered the treatment paradigm and have become the treatment of choice for IH. Propranolol has been found to cause cessation of growth and involution of IH.⁵⁰ Propranolol hydrochloride administered orally at

2 mg/kg/day has been found to reduce the volume, color, and elevation of focal and segmental IH in infants younger than 6 months and children up to 5 years of age.⁵¹ Furthermore, propranolol is effective in the treatment of IH in both the proliferative and post-proliferative phases.⁵² Studies have also shown propranolol to be an effective treatment for head and neck IH, especially when started early within the rapid growth phase. Propranolol is now the first-line treatment for orbit and airway hemangiomas, as well as periocular hemangiomas.^{53,54} Side effects of propranolol are usually mild, including asymptomatic transient decrease in blood pressure, agitation, sleep alteration, sweating, cold hands, and (rarely) wheezing and hypoglycemia.⁵⁵ A recent meta-analysis examined six studies, with a total of 154 patients, and found an overall adverse event rate of 18%, with the most common complications being hypotension and somnolence.⁵⁶ Side effects are more likely in patients under 3 months of age. Monitoring protocols to maximize patient safety are continuing to evolve, but most physicians who prescribe propranolol for patients aged under 3 months recommend monitoring the heart rate when the medication is initiated and feeding at least every 3–4 hours, to minimize the risk of hypoglycemia.

There is currently no consensus on appropriate cardiac work-up prior to starting an infant on propranolol. Some physicians routinely consult a pediatric cardiologist and obtain an echocardiogram and electrocardiogram, while others base their cardiac evaluation on the patient's risk of cardiac disease. Special caution is needed when beginning propranolol in PHACES patients. Patients with PHACES syndrome who have central nervous system vascular anomalies may be at risk for stroke or other sequelae, due to impaired arterial blood flow related to a drop in blood pressure or heart rate. However, one preliminary study of several patients with PHACES did not find a decrease in brain perfusion during treatment with propranolol.⁵⁷ Patients at high risk for PHACES should have a cardiac evaluation, as described previously, prior to starting propranolol.

When compared to prednisone for the treatment of IH, propranolol induced more rapid and greater clinical improvement, was more cost effective, and led to fewer surgical interventions.⁵⁸ Furthermore, the response rate to propranolol in prospective studies is approximately 90%.⁵¹ It remains unclear why some IHs do not respond to propranolol.

Intralesional corticosteroids can be an effective treatment for relatively small, localized hemangiomas in high-risk sites, such as the lip, nasal tip, cheek, and ear. Injections for periocular hemangiomas are usually performed by

ophthalmologists, but reports of retinal artery embolization and blindness have resulted in a reduced use of this modality.^{59–61} The largest published case series of intralesional steroids found that the majority showed a reduction greater than 50% in volume, with the best results occurring in relatively superficial hemangiomas.

Topical treatment is often appropriate for small, superficial, localized hemangiomas. Timolol (an ophthalmologic beta-blocker) has been reported to be effective in this setting.⁶² A recent multicenter, retrospective, cohort study demonstrated good response with timolol 0.5% solution twice a day for superficial hemangiomas, especially if the hemangiomas were treated for 3 months or longer.⁶³ Prospective studies are underway. A few case series have reported on the efficacy of class 1 topical corticosteroids, especially for small, superficial hemangiomas.^{64,65} Topical imiquimod 5% cream also has been shown to improve IH color, but not size, confirming that its utility is limited to superficial hemangiomas.⁶⁶ However, crusting and ulceration are potential side effects of topical imiquimod use.⁶⁷

There are additional systemic treatments for IH that are less commonly used and reserved for hemangiomas unresponsive to first and second-line therapy. Interferon- α therapy is reserved for life-threatening hemangiomas in which propranolol and corticosteroids are contraindicated or ineffective. Interferon- α has proven to be effective, but potential neurotoxicity – specifically, spastic diplegia – has limited its use.⁶⁸ Vincristine also has been tried for aggressive, complicated IHs resistant to other therapies. In addition, there are some reports of cyclophosphamide use in the pediatric hematology–oncology literature for the treatment of life-threatening diffuse neonatal hemangiomatosis.⁶⁹

Laser therapy is another treatment modality for IH. The pulsed dye laser (PDL) has been used to treat IH, with varying results.⁷⁰ Several reports have shown improvement in treating hemangioma ulceration, although the mechanism of action of PDL in this setting is not clear.⁷¹ PDL is widely used for diminishing residual telangiectasias and erythema after involution, but its use in the treatment of proliferating hemangiomas is controversial. One study showed no difference between complete and nearly complete clearance with early laser treatment compared to observation alone at 1 year of age.⁷² Other studies have demonstrated good results with either the 585 nm PDL or 595 nm PDL on superficial IH, but not deep IH.^{73,74} Severe ulceration and scarring have been reported, particularly when treating segmental hemangiomas during the proliferative phase.⁷⁵ The authors reserve PDL primarily for treating ulceration and for hastening resolution

of erythema in IH after the proliferative phase is completed. Endoscopic carbon dioxide lasering has been used to debulk symptomatic airway hemangiomas refractory to medical therapy. Circumferential lesions have the risk of developing subglottic stenosis with overly aggressive lasering, and lasering in the airway always carries a small risk of airway fire. Meticulous attention to keeping the percentage of inspired oxygen low and avoiding excessive charring of the tissues is needed in order to minimize this risk. Finally, surgical excision may be considered for IH patients of any age. In most cases, it is best to wait until regression is well under way, so that an accurate assessment can be made regarding the extent of textural change, scarring, and anatomic distortion. Decisions regarding the need for surgery can often be made before the child enters school (between 3 to 5 years of age), even if involution is not complete.⁷⁶ The nasal tip and lip often require surgery.^{77–79} In cases where the IH is pedunculated, very ulcerated, or has an extremely thick dermal component, scarring will inevitably occur, and earlier excision may be indicated. A standard elliptical excision is often performed; however, for some IHs, circular excision followed by a purse-string closure may leave a smaller scar.⁸⁰ Submucosal resection of airway hemangiomas has been performed through a laryngofissure. Most surgeons try to avoid placement of a tracheotomy, as there is a 1% risk of mortality with pediatric tracheotomy, and because it will cause significant additional care needs for the child, which may delay discharge from the hospital.

Conclusion

Hemangiomas are the most common benign tumor in children. There have been significant advancements in the understanding of the pathogenesis, clinical features, and treatment of infantile hemangiomas in the past few years. HemeSCs seem to play an important role in vasculogenesis and angiogenesis by stimulating molecular pathways, such as VEGF-A, mTOR, and beta-adrenergic receptors. All of these pathways play a critical role in the formation and progression of IH and are possible therapeutic targets.

For most families of children with hemangiomas, education about the natural history of IH and reassurance are often the only “treatment” required. A minority of patients with large, complex lesions or lesions that cause functional compromise will require early intervention. These patients and families benefit from a multidisciplinary approach to care in vascular birthmark centers.⁸¹ The serendipitous discovery of propranolol’s dramatic effects on hemangioma growth has caused a paradigm shift in the medical treatment of

hemangioma by offering an effective medical treatment with a lower risk profile than more traditional medical therapies, such as high-dose systemic steroids or interferon. There are some hemangiomas, however, which have been found not to respond to propranolol. Moreover, propranolol is not an entirely benign medication, especially in infants less than 3 months of age; consequently, monitoring protocols continue to be refined. Ongoing multi-institutional clinical trials will provide further important data on the efficacy and safety of hemangioma treatments.

Disclosure

The authors report no conflict of interest in this work.

References

- Kilcline C, Frieden IJ. Infantile hemangiomas: how common are they? A systematic review of the medical literature. *Pediatr Dermatol*. 2008; 25(2):168–173.
- Hemangioma Investigator Group, Haggstrom AN, Drolet BA, et al. Prospective study of infantile hemangiomas: demographic, prenatal, and perinatal characteristics. *J Pediatr*. 2007;150(3):291–294.
- Drolet BA, Swanson EA, Frieden IJ, Hemangioma Investigator Group. Infantile hemangiomas: an emerging health issue linked to an increased rate of low birth weight infants. *J Pediatr*. 2008;153(5):712–715.
- Dickison P, Christou E, Wargon O. A prospective study of infantile hemangiomas with a focus on incidence and risk factors. *Pediatr Dermatol*. 2011;28(6):663–669.
- Bischoff J. Progenitor cells in infantile hemangioma. *J Craniofac Surg*. 2009;20 Suppl 1:695–697.
- Boscolo E, Bischoff J. Vasculogenesis in infantile hemangioma. *Angiogenesis*. 2009;12(2):197–207.
- Chang EI, Chang EI, Thangarajah H, Hamou C, Gurtner GC. Hypoxia, hormones, and endothelial progenitor cells in hemangioma. *Lymphat Res Biol*. 2007;5(4):237–243.
- Haggstrom AN, Lammer EJ, Schneider RA, Marcucio R, Frieden IJ. Patterns of infantile hemangiomas: new clues to hemangioma pathogenesis and embryonic facial development. *Pediatrics*. 2006;117(3): 698–703.
- North PE, Waner M, Mizeracki A, et al. A unique microvascular phenotype shared by juvenile hemangiomas and human placenta. *Arch Dermatol*. 2001;137(5):559–570.
- Barnes CM, Huang S, Kaipainen A, et al. Evidence by molecular profiling for a placental origin of infantile hemangioma. *Proc Natl Acad Sci U S A*. 2005;102(52):19097–19102.
- Bree AF, Siegfried E, Sotelo-Avila C, Nahass G. Infantile hemangiomas: speculation on placental trophoblastic origin. *Arch Dermatol*. 2001;137(5):573–577.
- Pittman KM, Losken HW, Kleinman ME, et al. No evidence for maternal-fetal microchimerism in infantile hemangioma: a molecular genetic investigation. *J Invest Dermatol*. 2006;126(11):2533–2538.
- Dadras SS, North PE, Bertocini J, Mihm MC, Detmar M. Infantile hemangiomas are arrested in an early developmental vascular differentiation state. *Mod Pathol*. 2004;17(9):1068–1079.
- Yu Y, Flint AF, Mulliken JB, Wu JK, Bischoff J. Endothelial progenitor cells in infantile hemangioma. *Blood*. 2004;103(4):1373–1375.
- Greenberger S, Yuan S, Walsh LA, et al. Rapamycin suppresses self-renewal and vasculogenic potential of stem cells isolated from infantile hemangioma. *J Invest Dermatol*. 2011;131(12):2467–2476.
- Khan ZA, Boscolo E, Picard A, et al. Multipotential stem cells recapitulate human infantile hemangioma in immunodeficient mice. *J Clin Invest*. 2008;118(7):2592–2599.

17. Boscolo E, Mulliken JB, Bischoff J. VEGFR-1 mediates endothelial differentiation and formation of blood vessels in a murine model of infantile hemangioma. *Am J Pathol*. 2011;179(5):2266–2277.
18. Greenberger S, Boscolo E, Adini I, Mulliken JB, Bischoff J. Corticosteroid suppression of VEGF-A in infantile hemangioma-derived stem cells. *N Engl J Med*. 2010;362(11):1005–1013.
19. Jinnin M, Medici D, Park L, et al. Suppressed NFAT-dependent VEGFR1 expression and constitutive VEGFR2 signaling in infantile hemangioma. *Nat Med*. 2008;14(11):1236–1246.
20. Kumar A, Takada Y, Boriek AM, Aggarwal BB. Nuclear factor-kappaB: Its role in health and disease. *J Mol Med (Berl)*. 2004;82(7):434–448.
21. Yamamoto Y, Gaynor RB. Role of the NF-kappaB pathway in the pathogenesis of human disease states. *Curr Mol Med*. 2001;1(3):287–296.
22. Greenberger S, Adini I, Boscolo E, Mulliken JB, Bischoff J. Targeting NF- κ B in infantile hemangioma-derived stem cells reduces VEGF-A expression. *Angiogenesis*. 2010;13(4):327–335.
23. Storch CH, Hoeger PH. Propranolol for infantile haemangiomas: insights into the molecular mechanisms of action. *Br J Dermatol*. 2010;163(2):269–274.
24. Herbert A, Ng H, Jessup W, et al. Hypoxia regulates the production and activity of glucose transporter-1 and indoleamine 2,3-dioxygenase in monocyte-derived endothelial-like cells: possible relevance to infantile haemangioma pathogenesis. *Br J Dermatol*. 2011;164(2):308–315.
25. Kleinman ME, Greives MR, Churgin SS, et al. Hypoxia-induced mediators of stem/progenitor cell trafficking are increased in children with hemangioma. *Arterioscler Thromb Vasc Biol*. 2007;27(12):2664–2670.
26. Corella F, Garcia-Navarro X, Ribe A, Alomar A, Baselga E. Abortive or minimal-growth hemangiomas: Immunohistochemical evidence that they represent true infantile hemangiomas. *J Am Acad Dermatol*. 2008;58(4):685–690.
27. Suh KY, Frieden IJ. Infantile hemangiomas with minimal or arrested growth: a retrospective case series. *Arch Dermatol*. 2010;146(9):971–976.
28. Chiller KG, Passaro D, Frieden IJ. Hemangiomas of infancy: clinical characteristics, morphologic subtypes, and their relationship to race, ethnicity, and sex. *Arch Dermatol*. 2002;138(12):1567–1576.
29. Happle R. Superimposed segmental hemangioma of infancy. *Dermatology*. 2010;220(2):180–182.
30. Horii KA, Drolet BA, Frieden IJ, et al. Prospective study of the frequency of hepatic hemangiomas in infants with multiple cutaneous infantile hemangiomas. *Pediatr Dermatol*. 2011;28(3):245–253.
31. Chang LC, Haggstrom AN, Drolet BA, et al. Growth characteristics of infantile hemangiomas: Implications for management. *Pediatrics*. 2008;122(2):360–367.
32. Chamlin SL, Haggstrom AN, Drolet BA, et al. Multicenter prospective study of ulcerated hemangiomas. *J Pediatr*. 2007;151(6):684–689.
33. Kim HJ, Colombo M, Frieden IJ. Ulcerated hemangiomas: clinical characteristics and response to therapy. *J Am Acad Dermatol*. 2001;44(6):962–967.
34. Ceisler EJ, Santos L, Blei F. Periocular hemangiomas: what every physician should know. *Pediatr Dermatol*. 2004;21(1):1–9.
35. Orlow SJ, Isakoff MS, Blei F. Increased risk of symptomatic hemangiomas of the airway in association with cutaneous hemangiomas in a “beard” distribution. *J Pediatr*. 1997;131(4):643–646.
36. Rahbar R, Nicollas R, Roger G, et al. The biology and management of subglottic hemangioma: past, present, future. *Laryngoscope*. 2004;114(11):1880–1891.
37. Reinisch JF, Kim RY, Harshbarger RJ, Meara JG. Surgical management of parotid hemangioma. *Plast Reconstr Surg*. 2004;113(7):1940–1948.
38. Girard C, Bigorre M, Guillot B, Bessis D. PELVIS syndrome. *Arch Dermatol*. 2006;142(7):884–888.
39. Metry D, Heyer G, Hess C, et al. Consensus statement on diagnostic criteria for PHACE syndrome. *Pediatrics*. 2009;124(5):1447–1456.
40. Haggstrom AN, Garzon MC, Baselga E, et al. Risk for PHACE syndrome in infants with large facial hemangiomas. *Pediatrics*. 2010;126(2):e418–e426. Epub 2010.
41. Metry DW, Garzon MC, Drolet BA, et al. PHACE syndrome: Current knowledge, future directions. *Pediatr Dermatol*. 2009;26(4):381–398.
42. Metry DW, Dowd CF, Barkovich AJ, Frieden IJ. The many faces of PHACE syndrome. *J Pediatr*. 2001;139(1):117–123.
43. Drolet BA, Dohil M, Golomb MR, et al. Early stroke and cerebral vasculopathy in children with facial hemangiomas and PHACE association. *Pediatrics*. 2006;117(3):959–964.
44. Iacobas I, Burrows PE, Frieden IJ, et al. LUMBAR: association between cutaneous infantile hemangiomas of the lower body and regional congenital anomalies. *J Pediatr*. 2010;157(5):795–801.
45. Huang SA, Tu HM, Harney JW, et al. Severe hypothyroidism caused by type 3 iodothyronine deiodinase in infantile hemangiomas. *N Engl J Med*. 2000;343(3):185–189.
46. Tanner JL, Dechert MP, Frieden IJ. Growing up with a facial hemangioma: parent and child coping and adaptation. *Pediatrics*. 1998;101(3 Pt 1):446–452.
47. Bennett ML, Fleischer AB Jr, Chamlin SL, Frieden IJ. Oral corticosteroid use is effective for cutaneous hemangiomas: an evidence-based evaluation. *Arch Dermatol*. 2001;137(9):1208–1213.
48. Lomenick JP, Reifschneider KL, Lucky AW, et al. Prevalence of adrenal insufficiency following systemic glucocorticoid therapy in infants with hemangiomas. *Arch Dermatol*. 2009;145(3):262–266.
49. Lomenick JP, Backeljauw PF, Lucky AW. Growth, bone mineral accretion, and adrenal function in glucocorticoid-treated infants with hemangiomas – a retrospective study. *Pediatr Dermatol*. 2006;23(2):169–174.
50. Leaute-Labreze C, Dumas de la Roque E, Hubiche T, Boralevi F, Thambo JB, Taieb A. Propranolol for severe hemangiomas of infancy. *N Engl J Med*. 2008;358(24):2649–2651.
51. Hogeling M, Adams S, Wargon O. A randomized controlled trial of propranolol for infantile hemangiomas. *Pediatrics*. 2011;128(2):e259–e266.
52. Zvulunov A, McCuaig C, Frieden IJ, et al. Oral propranolol therapy for infantile hemangiomas beyond the proliferation phase: a multicenter retrospective study. *Pediatr Dermatol*. 2011;28(2):94–98.
53. Al Dhaybi R, Superstein R, Milet A, et al. Treatment of periocular infantile hemangiomas with propranolol: case series of 18 children. *Ophthalmology*. 2011;118(6):1184–1188.
54. Fuchsmann C, Quintal MC, Giguere C, et al. Propranolol as first-line treatment of head and neck hemangiomas. *Arch Otolaryngol Head Neck Surg*. 2011;137(5):471–478.
55. Sans V, de la Roque ED, Berge J, et al. Propranolol for severe infantile hemangiomas: follow-up report. *Pediatrics*. 2009;124(3):e423–e431. Epub Aug 2009.
56. Menezes MD, McCarter R, Greene EA, Bauman NM. Status of propranolol for treatment of infantile hemangioma and description of a randomized clinical trial. *Ann Otol Rhinol Laryngol*. 2011;120(10):686–695.
57. Hernandez-Martin S, Lopez-Gutierrez JC, Lopez-Fernandez S, et al. Brain Perfusion SPECT in Patients with PHACES Syndrome Under Propranolol Treatment. *Eur J Pediatr Surg*. 2012;22(1):54–59.
58. Price CJ, Lattouf C, Baum B, et al. Propranolol vs corticosteroids for infantile hemangiomas: a multicenter retrospective analysis. *Arch Dermatol*. 2011;147(12):1371–1376.
59. O’Keefe M, Lanigan B, Byrne SA. Capillary haemangioma of the eyelids and orbit: a clinical review of the safety and efficacy of intralesional steroid. *Acta Ophthalmol Scand*. 2003;81(3):294–298.
60. Egbert JE, Paul S, Engel WK, Summers CG. High injection pressure during intralesional injection of corticosteroids into capillary hemangiomas. *Arch Ophthalmol*. 2001;119(5):677–683.
61. Wasserman BN, Medow NB, Homa-Palladino M, Hoehn ME. Treatment of periocular capillary hemangiomas. *J AAPOS*. 2004;8(2):175–181.
62. Guo S, Ni N. Topical treatment for capillary hemangioma of the eyelid using beta-blocker solution. *Arch Ophthalmol*. 2010;128(2):255–256.
63. Chakkittakandiyil A, Phillips R, Frieden IJ, et al. Timolol maleate 0.5% or 0.1% gel-forming solution for infantile hemangiomas: a retrospective, multicenter, cohort study. *Pediatr Dermatol*. 2012;29(1):28–31.

64. Cruz OA, Zarnegar SR, Myers SE. Treatment of periocular capillary hemangioma with topical clobetasol propionate. *Ophthalmology*. 1995;102(12):2012–2015.
65. Garzon MC, Lucky AW, Hawrot A, Frieden IJ. Ultrapotent topical corticosteroid treatment of hemangiomas of infancy. *J Am Acad Dermatol*. 2005;52(2):281–286.
66. McCuaig CC, Dubois J, Powell J, et al. A phase II, open-label study of the efficacy and safety of imiquimod in the treatment of superficial and mixed infantile hemangioma. *Pediatr Dermatol*. 2009;26(2):203–212.
67. Ho NT, Lansang P, Pope E. Topical imiquimod in the treatment of infantile hemangiomas: a retrospective study. *J Am Acad Dermatol*. 2007;56(1):63–68.
68. Michaud AP, Bauman NM, Burke DK, Manaligod JM, Smith RJ. Spastic diplegia and other motor disturbances in infants receiving interferon-alpha. *Laryngoscope*. 2004;114(7):1231–1236.
69. Hurvitz SA, Hurvitz CH, Sloninsky L, Sanford MC. Successful treatment with cyclophosphamide of life-threatening diffuse hemangiomas involving the liver. *J Pediatr Hematol Oncol*. 2000;22(6):527–532.
70. Batta K, Goodyear HM, Moss C, Williams HC, Hiller L, Waters R. Randomised controlled study of early pulsed dye laser treatment of uncomplicated childhood haemangiomas: Results of a 1-year analysis. *Lancet*. 2002;360(9332):521–527.
71. David LR, Malek MM, Argenta LC. Efficacy of pulse dye laser therapy for the treatment of ulcerated haemangiomas: a review of 78 patients. *Br J Plast Surg*. 2003;56(4):317–327.
72. Michel JL. Treatment of hemangiomas with 595 nm pulsed dye laser dermobeam. *Eur J Dermatol*. 2003;13(2):136–141.
73. Kolde G. Early pulsed-dye laser treatment of childhood haemangiomas. *Lancet*. 2003;361(9354):348–349.
74. Kono T, Sakurai H, Groff WF, et al. Comparison study of a traditional pulsed dye laser versus a long-pulsed dye laser in the treatment of early childhood hemangiomas. *Lasers Surg Med*. 2006;38(2):112–115.
75. Witman PM, Wagner AM, Scherer K, Waner M, Frieden IJ. Complications following pulsed dye laser treatment of superficial hemangiomas. *Lasers Surg Med*. 2006;38(2):116–123.
76. McHeik JN, Renaud V, Dupont G, Vergnes P, Levard G. Surgical treatment of haemangioma in infants. *Br J Plast Surg*. 2005;58(8):1067–1072.
77. Demiri EC, Pelissier P, Genin-Etcheberry T, Tsakoniatis N, Martin D, Baudet J. Treatment of facial haemangiomas: the present status of surgery. *Br J Plast Surg*. 2001;54(8):665–674.
78. Hochman M, Mascareno A. Management of nasal hemangiomas. *Arch Facial Plast Surg*. 2005;7(5):295–300.
79. McCarthy JG, Borud LJ, Schreiber JS. Hemangiomas of the nasal tip. *Plast Reconstr Surg*. 2002;109(1):31–40.
80. Mulliken JB, Rogers GF, Marler JJ. Circular excision of hemangioma and purse-string closure: the smallest possible scar. *Plast Reconstr Surg*. 2002;109(5):1544–1554.
81. Mathes EF, Haggstrom AN, Dowd C, Hoffman WY, Frieden IJ. Clinical characteristics and management of vascular anomalies: findings of a multidisciplinary vascular anomalies clinic. *Arch Dermatol*. 2004;140(8):979–983.

Research and Reports in Neonatology

Publish your work in this journal

Research and Reports in Neonatology is an international, peer-reviewed, open access journal publishing original research, reports, editorials, reviews and commentaries on neonatal health. The manuscript management system is completely online and includes a very quick and fair

peer-review system. Visit <http://www.dovepress.com/testimonials.php> to read real quotes from published authors.

Submit your manuscript here: <http://www.dovepress.com/research-and-reports-in-neonatology-journal>

Dovepress