

Dexrazoxane for the treatment of chemotherapy-related side effects

Seppo W Langer

Thoracic and Neuroendocrine
Section, Department of Oncology,
Copenhagen University Hospital,
Copenhagen, Denmark

Abstract: For more than half a century, the different properties of dexrazoxane have captured the attention of scientists and clinicians. Presently, dexrazoxane is licensed in many parts of the world for two different indications: prevention of cardiotoxicity from anthracycline-based chemotherapy, and prevention of tissue injuries after extravasation of anthracyclines. This article reviews the historical, preclinical, and clinical background for the use of dexrazoxane for these indications.

Keywords: anthracyclines, cardiomyopathy, extravasation

Chemistry and mechanisms of action of dexrazoxane and anthracyclines

Dexrazoxane belongs to the bisdioxopiperazine compounds and is a water-soluble ring-closed analog of the iron chelator ethylenediaminetetraacetic acid (EDTA) (Figure 1). Unlike EDTA, dexrazoxane easily passes into cells. Upon hydrolysis, dexrazoxane opens into its EDTA-like form, ADR-925, which is a strong iron chelator that has the ability to displace iron from the anthracycline.¹

Dexrazoxane is also a catalytic inhibitor of DNA topoisomerase II that is the same target as the DNA topoisomerase II poisonous anticancer agents: the anthracyclines (eg, doxorubicin, epirubicin, daunorubicin), the anthracenediones (eg, mitoxantrone), and the podophyllotoxins (eg, etoposide, teniposide). However, dexrazoxane does not induce lethal DNA double-strand breaks as do the topoisomerase poisons.²

Historical background of dexrazoxane

In the 1950s, the bisdioxopiperazine compounds were investigated independently by scientists from The Eastman Kodak Company (Rochester, NY, USA) and The Ciba-Geigy Corporation (Basel, Switzerland), for their nonbiological properties and use as jet fuel additives and textile leveling agents.^{3,4} Based on the hypothesis that intercellular metal ion chelation leads to retardation of neoplastic cell growth, it was later suggested that these chelating compounds might be antineoplastics.⁵

In due course, this led to the generation of a number of potential antineoplastic bisdioxopiperazine compounds, all bearing the name of the fostering British institution, the Imperial Cancer Research Fund (ICRF). ICRF-159 (razoxane), ICRF-193, and ICRF-154 were initially found to exert in vitro antineoplastic effects in various tumors. In vivo activity was shown in patients with leukemia and lymphosarcoma.⁶ However, the compounds were soon discarded as antineoplastic agents due to unfavorable toxicity profiles.

Correspondence: Seppo W Langer
Thoracic and Neuroendocrine Section,
Department of Oncology 5073,
Copenhagen University Hospital,
Rigshospitalet Blegdamsvej 9, DK-2100
Copenhagen, Denmark
Email seppo.langer@regionh.dk

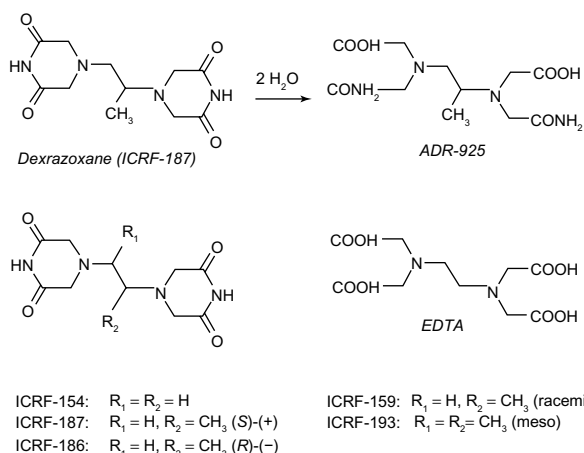


Figure 1 Chemical structures of dexrazoxane, EDTA, and related bisdioxopiperazines. **Abbreviation:** EDTA, ethylenediaminetetraacetic acid.

The interest in the bisdioxopiperazines as potential protectors against anthracycline-mediated myocardial damage emerged from a large series of preclinical studies, in particular those performed by Herman et al.⁷ For example, it was observed in 1974 that anthracycline-induced cardiotoxicity was prevented in isolated dog hearts that were pretreated with perfusions of razoxane.⁷ Pretreatment with dexrazoxane (ICRF-187) reduced cardiotoxicity and lethality in non-cancer-bearing Syrian golden hamsters receiving daunorubicin.⁸ Furthermore, pretreatment with dexrazoxane was shown to be cardioprotective in doxorubicin- and daunorubicin-treated beagle dogs, rabbits, and miniature swine.^{9–11} Later, clinical studies in humans confirmed the cardioprotection exerted by dexrazoxane. Hence, a new indication for the use of dexrazoxane was established.

The first report on the experimental amelioration of subcutaneous injuries caused by anthracyclines with dexrazoxane was published in 2000.¹² In several series of experiments, ulcers were introduced in mice with subcutaneously injected doxorubicin, daunorubicin, and idarubicin.^{13–15} Systemic treatment was highly efficacious in protecting against ulcers, and the protection obtained by triple-dose dexrazoxane was

superior to the protection obtained by a single dose. The effect was highly significant regarding both the frequency and sizes of wounds, and early treatment was more protective than late treatment. Hence, it was demonstrated that the protection depended on the dose of dexrazoxane as well as on the time and frequency of administration. Additional experiments were carried out to further explore the possible mechanism of action.^{13–15} Table 1 outlines the indications and schedules for treatment with dexrazoxane.

Background: anthracycline cardiotoxicity

Presently, the antineoplastic activity of anthracyclines is believed to be almost exclusively due to the ability to bind to DNA and act as a poison to topoisomerase II by inducing lethal double-strand DNA breaks.^{17,18} However, the anthracyclines also have a number of other potential cytotoxic effects mediated by several mechanisms, including intercalation into nuclear DNA, production of reactive oxygen species, and induction of apoptosis.

The cardiac side effects are believed to result from induction of oxidative stress and apoptosis. The anthracycline quinone can redox cycle after reductive activation by various reductase enzymes to its free semiquinone.¹⁹ The semiquinone reacts with oxygen to produce highly reactive oxygen species such as superoxide anion and hydrogen peroxide. The anthracycline also binds iron through its quinone/semiquinone functional groups, which are able to catalyze formation of the toxic and extremely reactive hydroxyl radical in a redox cycling reaction. This iron-dependent anthracycline-based oxidative stress and induction of the proapoptotic pathway is believed to be the main reasons for the myocardial toxicity.^{20,21} Cardiac mitochondria are easily injured by anthracyclines and the anthracycline–iron complexes, which have a high affinity for the dianionic phospholipid cardiolipin that is present in high concentration in the inner mitochondrial membrane.²² Cardiac progenitor cells may also be damaged by anthracyclines, which clinically translates into the delayed

Table 1 Schedules and indications for treatment with dexrazoxane for cardiotoxicity and accidental extravasation

Cardiotoxicity (Cardioxane®, Zinecard®)	Extravasation (Savene®, Totect®)
The indication for treatment with dexrazoxane is prevention of chronic cumulative cardiotoxicity caused by doxorubicin or epirubicin use in advanced and/or metastatic adult breast cancer patients who have received a prior cumulative dose of 300 mg/m ² of doxorubicin or 540 mg/m ² of epirubicin and when further anthracycline treatment is required. The recommended dose ratio (dexrazoxane:doxorubicin or dexrazoxane:epirubicin) is 10:1. In this setting, dexrazoxane is administered as an intravenous infusion 10–30 minutes before the anthracycline. The benefit–risk balance of dexrazoxane in children and adolescents is presently generally considered to be unfavorable.	The indication is prevention of tissue injuries from extravasation of anthracyclines. The recommended schedule is 1,000 mg/m ² intravenously within 6 hours after the extravasation incident, followed by intravenous administration of 1,000 mg/m ² and 500 mg/m ² after 48 and 72 hours, respectively.

left ventricular dysfunction that may occur decades of years after anthracycline treatment in children.²³

Clinically, anthracycline cardiotoxicity roughly exists in two forms: acute and chronic.²⁴ Acute toxicity is associated with intravenous administration of the anthracycline and is characterized by vasodilation, hypotension, and transient rhythm disturbances.

The most serious side effect of repeated anthracycline therapy is late cardiomyopathy. The clinical presentation is that of congestive heart failure, and the major risk factor is the cumulative dose of the anthracycline. Thus, Von Hoff et al demonstrated an incidence of 2.2% in a retrospective analysis of 3,941 patients treated with doxorubicin at various schedules with a median dose of 390 mg/m². The overall incidence of daunorubicin-induced cardiomyopathy in 5,613 patients was 0.7% in adults and 1.6% in children. Dose dependency was evident by the fact that a cumulative dose of 1,000 mg/m² was associated with cardiomyopathy in 11%, whereas the incidence was 1.5% at a total dose of 600 mg/m².²⁵ Aggravating risk factors for developing cardiomyopathy after anthracycline therapy include older age, radiation therapy to the mediastinal region, and combination chemotherapy with anticancer agents such as cyclophosphamide, trastuzumab, and taxanes. The clinical problem is of major importance in the treatment of pediatric patients. Hence, at follow-up 1–15 years after doxorubicin treatment in 115 children with leukemia, changes in ventricular wall thickness and/or contractility were found in 57%.²⁶ The effect of cardiotoxicity increases in long-term survivors, from 2% after 2 years to 5% after 15 years.²⁷ Epirubicin differs from doxorubicin only in the steric position of the 4'-hydroxy group. The resulting slightly lower potency may account for the lower cardiotoxicity. However, fatal late cardiotoxicity also occurs after equi-myelosuppressive doses.^{28,29} As a consequence of the dose-related risk of cardiomyopathy, epirubicin is usually administered to a maximal total dose of 900–1,000 mg/m², and doxorubicin and daunorubicin up to a maximum of approximately 550 mg/m².

Clinical efficacy in cardioprotection

The cardioprotective effect of dexrazoxane has been studied clinically for more than 20 years, and the results have been referenced, study-wise, in meta-analyses, reviews, and clinical guidelines.^{30–39} There is evidence that the incidence of heart failure is reduced in patients with advanced breast cancer, sarcoma, and lung cancer treated with dexrazoxane added to doxorubicin and epirubicin in these studies. Moreover, in these studies, the cardioprotection does not

significantly reduce the overall survival or progression-free survival. In one of the trials, the objective response rate was lower in dexrazoxane-treated patients, but it did not translate into impaired progression-free survival time.³⁹ The most recent multicenter study of women previously exposed to anthracyclines and thereafter receiving doxorubicin or epirubicin confirmed that those treated with dexrazoxane experienced fewer cardiac events (significant reduction in left ventricular ejection fraction or the appearance of clinical signs of cardiac insufficiency) compared with those treated with anthracycline only (13% in the dexrazoxane arm versus 39% in the no-dexrazoxane arm; $P < 0.001$).⁴⁰ The incidence of congestive heart failure was 1% in the dexrazoxane-treated group compared to 11% in the no-dexrazoxane arm ($P = 0.015$, ie, a reduction in risk of approximately 90%). These findings support the 76% overall risk reduction in congestive heart failure that was estimated in a meta-analysis of several large randomized controlled studies of patients treated with doxorubicin or epirubicin where dexrazoxane was given from the first dose of anthracycline.⁴¹

Recently, Kalam and Marwick summarized the clinical efficacy of dexrazoxane in a systematic review of randomized trials and observational studies of cardioprotection in chemotherapeutic treatment of patients with no prior history of heart failure.⁴² Looking at drop in ejection fraction or development of heart failure, they defined more than 2,000 patients from 14 studies in adult and pediatric patients treated with anthracyclines. In seven randomized controlled studies including 1,167 patients, cardiac events were significantly reduced with dexrazoxane (risk reduction = 0.35 [95% confidence interval: 0.27–0.45], $P < 0.00001$). Clinical data from randomized pediatric trials are far less solid, and short-term and long-term results from ongoing clinical trials are awaited.⁴³

Background: anthracycline extravasation

Extravasation is the unintentional leakage of a drug into the surrounding tissues. In cancer treatment, extravasation of the widely used anthracyclines such as doxorubicin, daunorubicin, and epirubicin may lead to severe, long-lasting tissue injuries. The clinical hallmarks of anthracycline extravasation are pain, swelling, and erythema at the infiltrated site that last for days, weeks, or even months.^{44–46} Symptoms of chest wall infiltration from a centrally placed catheter may have a delayed onset and may present as shoulder pain.⁴⁷ Over the following days, edema, blistering, and induration are often observed. The slowly growing ulceration, which may appear after several days or even weeks, has a propensity to invade

deep structures such as tendons and joints irrespective of fascia.^{48–51} Even though small lesions may heal spontaneously, larger lesions can have a prolonged course lasting several months (Figure 2). Long-term sequelae include pain and serious joint and nerve damage, permanent disfigurement, and other cosmetic changes. In severe cases of anthracycline extravasation, surgical debridement with subsequent skin grafting is necessary.^{46–49} Interruption or discontinuation of further scheduled cancer chemotherapy is an additional complication. Treatment options for anthracycline extravasation were limited and empirically based before dexrazoxane was found to be a potent and specific systemic antidote against the injuries.

Clinical efficacy in extravasation

Two larger prospective, multicenter clinical trials have been conducted: TT01 and TT02.⁵² In addition, a number of case reports and a small pharmacokinetic study have been published, as have two confirmative retrospective studies.^{53–59}

The prospective trials are unique for all extravasation studies due to the eligibility criteria of histologically verified accidental anthracycline extravasations (positive fluorescence microscopy), and not on the suspicion of extravasation alone. Patients were entered from 24 different European oncology centers and had clinical extravasations of mainly doxorubicin and epirubicin.⁵² Dexrazoxane was administered as an intravenous infusion over 1–2 hours: 1,000 mg/m² was given within 6 hours after the extravasation injury; 1,000 mg/m² 24 hours later; and 500 mg/m² another 24 hours later. Of 80 patients, 54 had positive biopsies and only one patient developed ulceration that required surgical intervention, corresponding to an overall efficacy

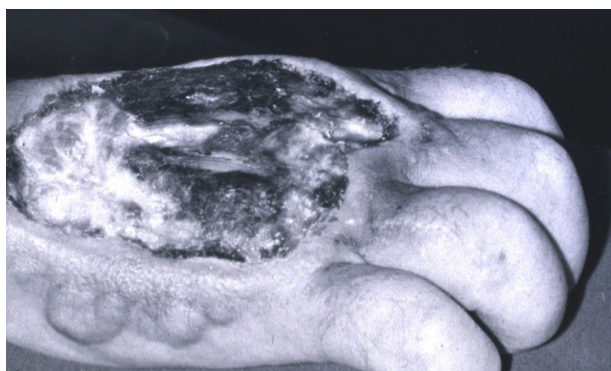

Figure 2 Necrosis after an accidental anthracycline extravasation that was left untreated (before the discovery of dexrazoxane as an antidote).

Note: Copyright © 2014 by John Wiley & Sons, Inc. Reproduced from Langer SW. Extravasation reactions. In: Lacouture ME, editor. *Dermatologic Principles and Practice in Oncology: Conditions of the Skin, Hair, and Nails in Cancer Patients*. John Wiley & Sons Inc. Hoboken, New Jersey; 2014:295–300. All rights reserved.¹⁶

rate of 98%. In addition, none of the additional 26 patients with suspected extravasations, but negative punch biopsies, developed ulceration. The secondary objectives of the studies were to avoid postponement of further planned cancer chemotherapy and to describe and evaluate subjective and objective symptoms and signs following dexrazoxane treatment, as well as evaluation of the tolerability and/or toxicity of dexrazoxane. More than two-thirds of the patients continued their planned chemotherapy without delay. One-third of the patients experienced a delay in planned chemotherapy of a median of 1 week. Few patients experienced mild, long-term sequelae as a result of the extravasation. No patients developed limitations of limb movement. In conclusion, dexrazoxane proved highly efficacious and tolerable in the management of accidental anthracycline extravasation. The treatment has also proved valuable in extravasations from central venous catheters.^{60–62}

Side effects and matters of concern

When administered as a single agent, i.e. without concomitant anthracycline, Phase I studies showed dose-limiting myelotoxicity (neutropenia) at 1,500 mg/m² per dose when administered for 3 or 5 consecutive days every 3 weeks, and with doses up to 7,400 mg/m² over 60 minutes per week when administered weekly.^{63–67} Other side effects at near-maximum doses included reversible elevation of hepatic transaminases and increased urinary excretion of iron and zinc.⁶⁷ Nausea, alopecia, mucositis, and vomiting have also been reported in early-phase clinical studies.^{63–67} However, in Phase III cardioprotection studies comprising anthracycline-containing regimens, eg, fluorouracil, doxorubicin, and cyclophosphamide, the addition of dexrazoxane did not aggravate these side effects. The hematological toxicity was exacerbated but the incidence of neutropenic fever was not consistently exacerbated.^{31,40} In the prospective extravasation studies TT01 and TT02, dexrazoxane was administered on a 3-day schedule to patients experiencing anthracycline extravasation who were already receiving cycles of chemotherapy.⁵² Consequently, the pattern of adverse events observed was therefore very similar to that of anthracyclines, and therefore it is hard to separate the adverse events due to dexrazoxane from those of anthracycline chemotherapy. In short, nausea/vomiting were reported in around one-third of patients, with approximately one-half of the patient population experiencing neutropenia and thrombocytopenia. Transient increases in liver enzymes (alanine aminotransferase/aspartate aminotransferase) were documented less commonly and reverted to normal within 10 days. Dexrazoxane may cause local injection-site reaction

(pain, superficial phlebitis), and it is recommended that dexrazoxane be infused in a large vein.

In recent years, concern has been raised about the risk of long-term effects of dexrazoxane, particularly in pediatric patients who had repeated doses to prevent cardiotoxicity. Although very rare, a threefold increase in the incidence of second primary malignancies (myelodysplastic syndrome and acute myeloid leukemia) in dexrazoxane-treated pediatric patients compared with controls was reported in two randomized studies.^{68,69} On the other hand, no increase in secondary malignant neoplasms was observed after dexrazoxane cardioprotection in other large pediatric trials.^{70,71} Nonetheless, these findings have led to a restriction in the labeled indication for dexrazoxane in cardioprotection in Europe.

Conclusion

The story of dexrazoxane is a journey of 50 years through translational chemistry and medicine. It has moved dexrazoxane from the laboratory benches into clinical practice, where it may be used as a protective agent against anthracycline induced cardiotoxicity and extravasation injuries.

Disclosure

The author reports no conflicts of interest in this work.

References

- Hasinoff BB, Kuschak TI, Yalowich JC, Creighton AM. A QSAR study comparing the cytotoxicity and DNA topoisomerase II inhibitory effects of bisdioxopiperazine analogs of ICRF-187 (dexrazoxane). *Biochem Pharmacol.* 1995;50(7):953–958.
- Nitiss JL. Targeting DNA topoisomerase II in cancer chemotherapy. *Nat Rev Cancer.* 2009;9(5):338–350.
- Geigy JR. UK Patent 978,724. 1964.
- Eastman Kodak Co. UK Patent 1,001,157. 1965.
- Creighton AM, Hellmann K, Whitecross S. Antitumour activity in a series of bisdiketopiperazines. *Nature.* 1969;222(5191):384–385.
- Hellmann K, Newton KA, Whitmore DN, Hanham IW, Bond JV. Preliminary clinical assessment of ICRF 159 in acute leukaemia and lymphosarcoma. *Br Med J.* 1969;1(5647):822–824.
- Herman EH, Mhatre RM, Chadwick DP. Modification of some of the toxic effects of daunomycin (NSC-82,151) by pretreatment with the antineoplastic agent ICRF 159 (NSC-129,943). *Toxicol Appl Pharmacol.* 1974;27:517–526.
- Herman EH, Ardalán B, Bier C, Waravdekar V, Krop S. Reduction of daunorubicin lethality and myocardial cellular alterations by pretreatment with ICRF-187 in Syrian golden hamsters. *Cancer Treat Rep.* 1979;63:89–92.
- Herman EH, Ferrans VJ. Influence of vitamin E and ICRF-187 on chronic doxorubicin cardiotoxicity in miniature swine. *Lab Invest.* 1983;49(1):69–77.
- Herman EH, Ferrans VJ, Young RS, Hamlin RL. Pretreatment with ICRF-187 allows a marked increase in the total cumulative dose of doxorubicin tolerated by beagle dogs. *Drugs Exp Clin Res.* 1988;14(9):563–570.
- Herman EH, Ferrans VJ. Preclinical animal models of cardiac protection from anthracycline-induced cardiotoxicity. *Semin Oncol.* 1998;25(4 Suppl 10):15–21.
- Langer SW, Sehested M, Jensen PB. Treatment of anthracycline extravasation with dexrazoxane. *Clin Cancer Res.* 2000;9(9):3680–3686.
- Langer SW, Sehested M, Jensen PB. Dexrazoxane is a potent and specific inhibitor of anthracycline induced subcutaneous lesions in mice. *Ann Oncol.* 2001;12(3):405–410.
- Langer SW, Thougard AV, Sehested M, Jensen PB. Treatment of anthracycline extravasation in mice with dexrazoxane with or without DMSO and hydrocortisone. *Cancer Chemother Pharmacol.* 2006;57(1):125–128.
- Thougard AV, Langer SW, Hainau B, et al. A murine experimental anthracycline extravasation model: pathology and study of the involvement of topoisomerase II alpha and iron in the mechanism of tissue damage. *Toxicology.* 2010;269(1):67–72.
- Langer SW. Extravasation reactions. In: Lacouture ME, editor. *Dermatologic Principles and Practice in Oncology: Conditions of the Skin, Hair, and Nails in Cancer Patients.* John Wiley & Sons Inc. Hoboken, New Jersey; 2014:295–300.
- Gewirtz DA. A critical evaluation of the mechanisms of action proposed for the antitumor effects of the anthracycline antibiotics adriamycin and daunorubicin. *Biochem Pharmacol.* 1999;57(7):727–741.
- Fortune JM, Osheroff N. Topoisomerase II as a target for anticancer drugs: when enzymes stop being nice. *Prog Nucleic Acid Res Mol Biol.* 2000;64:221–253.
- Hasinoff BB, Hellmann K, Herman EH, Ferrans VJ. Chemical, biological and clinical aspects of dexrazoxane and other bisdioxopiperazines. *Curr Med Chem.* 1998;5(1):1–28.
- Force T. Introduction to cardiotoxicity review series. *Circ Res.* 2010;106(1):19–20.
- Youssef G, Links M. The prevention and management of cardiovascular complications of chemotherapy in patients with cancer. *Am J Cardiovasc Drugs.* 2005;5:233–243.
- Hasinoff BB, Davey JP. Adriamycin and its iron(III) and copper(II) complexes. Glutathione-induced dissociation; cytochrome c oxidase inactivation and protection; binding to cardiolipin. *Biochem Pharmacol.* 1988;37(19):3663–3669.
- De Angelis A, Piegari E, Cappetta D, et al. Anthracycline cardiomyopathy is mediated by depletion of the cardiac stem cell pool and is rescued by restoration of progenitor cell function. *Circulation.* 2010;121(2):276–292.
- Ferrans VJ, Clark JR, Zhang J, Yu ZX, Herman EH. Pathogenesis and prevention of doxorubicin cardiomyopathy. *Tsitologia.* 1997;39(10):928–937.
- Von Hoff DD, Rozenzweig M, Layard M, Slavik M, Muggia FM. Daunomycin-induced cardiotoxicity in children and adults. A review of 110 cases. *Am J Med.* 1977;62(2):200–208.
- Lipshultz SE, Colan SD, Gelber RD, Perez-Atayde AR, Sallan SE, Sanders SP. Late cardiac effects of doxorubicin therapy for acute lymphoblastic leukemia in childhood. *N Engl J Med.* 1991;324(12):808–815.
- Kremer LC, van Dalen EC, Offringa M, Ottenkamp J, Voûte PA. Anthracycline-induced clinical heart failure in a cohort of 607 children: long-term follow-up study. *J Clin Oncol.* 2001;19(1):191–196.
- Nielsen D, Jensen JB, Dombernowsky P, et al. Epirubicin cardiotoxicity: a study of 135 patients with advanced breast cancer. *J Clin Oncol.* 1990;8(11):1806–1810.
- Dardir MD, Ferrans VJ, Mikhael YS, et al. Cardiac morphologic and functional changes induced by epirubicin chemotherapy. *J Clin Oncol.* 1989;7(7):947–958.
- Speyer JL, Green MD, Kramer E, et al. Protective effect of the bispiperazine ICRF-187 against doxorubicin-induced cardiac toxicity in women with advanced breast cancer. *N Engl J Med.* 1988;319:745–752.
- Speyer JL, Green MD, Zeleniuch-Jacquette A, et al. ICRF-187 permits longer treatment with doxorubicin in women with breast cancer. *J Clin Oncol.* 1992;10:117–127.
- Feldmann JE, Jones SE, Weisberg SR, et al. Advanced small cell lung cancer treated with CAV (cyclophosphamide + Adriamycin® + vincristine) chemotherapy and the cardioprotective agent dexrazoxane (ADR-529, ICRF-187, Zinecard®). *Proc Ann Meet Am Soc Clin Oncol.* 1992;11:AA93.

33. Venturini M, Michelotti A, Del Mastro L, et al. Multicenter randomized controlled clinical trial to evaluate cardioprotection of dexrazoxane versus no cardioprotection in women receiving epirubicin chemotherapy for advanced breast cancer. *J Clin Oncol*. 1996;14:3112–3120.
34. Wexler LH, Andrich MP, Venzon D, et al. Randomized trial of the cardioprotective agent ICRF-187 in pediatric sarcoma patients treated with doxorubicin. *J Clin Oncol*. 1996;14:362–372.
35. Swain SM, Whaley FS, Gerber MC, Ewer MS, Bianchini JR, Gams RA. Delayed administration of dexrazoxane provides cardioprotection for patients with advanced breast cancer treated with doxorubicin-containing therapy. *J Clin Oncol*. 1997;15(4):1333–1340.
36. Swain SM, Whaley FS, Gerber MC, et al. Cardioprotection with dexrazoxane for doxorubicin-containing therapy in advanced breast cancer. *J Clin Oncol*. 1997;15:1318–1332.
37. Lopez M, Vici P, Di Lauro K, et al. Randomized prospective clinical trial of high-dose epirubicin and dexrazoxane in patients with advanced breast cancer and soft tissue sarcomas. *J Clin Oncol*. 1998;16:86–92.
38. Lipshultz SE, Rifai N, Dalton VM, et al. The effect of dexrazoxane on myocardial injury in doxorubicin-treated children with acute lymphoblastic leukemia. *N Engl J Med*. 2004;351:145–153.
39. Hensley ML, Hagerty KL, Kewalramani T, et al. American Society of Clinical Oncology 2008 clinical practice guideline update: use of chemotherapy and radiation therapy protectants. *J Clin Oncol*. 2009;27(1):127–145.
40. Marty M, Espié M, Llombart A, Monnier A, Rapoport BL, Stahelova V; Dexrazoxane Study Group. Multicenter randomized phase III study of the cardioprotective effect of dexrazoxane (Cardioxane) in advanced/metastatic breast cancer patients treated with anthracycline-based chemotherapy. *Ann Oncol*. 2006;17(4):614–622.
41. Seymour L, Bramwell V, Moran LA. Use of dexrazoxane as a cardioprotectant in patients receiving doxorubicin or epirubicin chemotherapy for the treatment of cancer. The Provincial Systemic Treatment Disease Site Group. *Cancer Prev Control*. 1999;3:145–159.
42. Kalam K, Marwick TH. Role of cardioprotective therapy for prevention of cardiotoxicity with chemotherapy: a systematic review and meta-analysis. *Eur J Cancer*. 2013;49:2900–2909.
43. Sepe DM, Ginsberg JP, Balis FM. Dexrazoxane as a cardioprotectant in children receiving anthracyclines. *Oncologist*. 2010;15:1220–1226.
44. Langer SW, Sehested M, Jensen PB. Anthracycline extravasation: a comprehensive review of experimental and clinical treatments. *Tumori*. 2009;95(3):273–282.
45. Sonneveld P, Wassenaar HA, Nooter K. Long persistence of doxorubicin in human skin after extravasation. *Cancer Treat Rep*. 1984;68(6):895–896.
46. Reilly JJ, Neifeld JP, Rosenberg SA. Clinical course and management of accidental adriamycin extravasation. *Cancer*. 1977;40(5):2053–2056.
47. Mayo DJ, Pearson DC. Chemotherapy extravasation: a consequence of fibrin sheath formation around venous access devices. *Oncol Nurs Forum*. 1995;22(4):675–680.
48. Laughlin RA, Landeen JM, Habal MB. The management of inadvertent subcutaneous adriamycin infiltration. *Am J Surg*. 1979;137:408–412.
49. Preuss P, Partoft S. Cytostatic extravasations. *Ann Plast Surg*. 1987;19(4):323–329.
50. Linder RM, Upton J, Osteen R. Management of extensive doxorubicin hydrochloride extravasation injuries. *J Hand Surg Am*. 1983;8(1):32–38.
51. Rudolph R, Stein RS, Pattillo R. Skin ulcers due to adriamycin. *Cancer*. 1976;38:1087–1094.
52. Mouridsen HT, Langer SW, Buter J, et al. Treatment of anthracycline extravasation with Savene (dexrazoxane): results from two prospective clinical multicentre studies. *Ann Oncol*. 2007;18(3):546–550.
53. Langer SW, Sehested M, Jensen PB, Buter J, Giaccone G. Dexrazoxane in anthracycline extravasation. *J Clin Oncol*. 2000;18(16):3064.
54. Jensen JN, Lock-Andersen J, Langer SW, Mejer J. Dexrazoxane—a promising antidote in the treatment of accidental extravasation of anthracyclines. *Scand J Plast Reconstr Surg Hand Surg*. 2003;37(3):174–175.
55. El-Saghir N, Otroek Z, Mufarrij A, et al. Dexrazoxane for anthracycline extravasation and GM-CSF for skin ulceration and wound healing. *Lancet Oncol*. 2004;5(5):320–321.
56. Bos AM, van der Graaf WT, Willemse PH. A new conservative approach to extravasation of anthracyclines with dimethylsulfoxide and dexrazoxane. *Acta Oncol*. 2001;40(4):541–542.
57. Mouridsen HT, Langer SW, Tjoernelund J, et al. Anthracycline extravasation in breast cancer patients. Effective treatment with dexrazoxane in three multicenter trials. *European J Cancer (Suppl)*. 2008;6(7):197.
58. Muthuramalingam S, Gale J, Bradbury J. Dexrazoxane efficacy for anthracycline extravasation: use in UK clinical practice. *Int J Clin Pract*. 2013;67(3):244–249.
59. Fontaine C, Noens L, Pierre P, De Grève J. Savene® (dexrazoxane) use in clinical practice. *Support Care Cancer*. 2012;20(5):1109–1112.
60. Jordan K, Behlendorf T, Mueller F, Schmoll HJ. Anthracycline extravasation injuries: management with dexrazoxane. *Ther Clin Risk Manag*. 2009;5(2):361–366.
61. Hünelerlitürkoglou AN, Tappich C, Langer SW, Sehested M, Jensen PB, Heintges T. Successful use of dexrazoxane in two cases of anthracycline containing polychemotherapy. *European J Clin Med Oncology*. 2009;1(1):13–15.
62. Langer SW. Treatment of anthracycline extravasation from centrally inserted venous catheters. *Oncol Rev*. 2008;2:115–117.
63. Holcenberg JS, Tutsch KD, Earhart RH, et al. Phase I study of ICRF-187 in pediatric cancer patients and comparison of its pharmacokinetics in children and adults. *Cancer Treat Rep*. 1986;70(6):703–709.
64. Koeller JM, Earhart RH, Davis HL. Phase I trial of ICRF-187 by 48-hour continuous infusion. *Cancer Treat Rep*. 1981;65(5–6):459–463.
65. Liesmann J, Belt R, Haas C, Hoogstraten B. Phase I evaluation of ICRF-187 (NSC-169780) in patients with advanced malignancy. *Cancer*. 1981;47(8):1959–1962.
66. Von Hoff DD, Howser D, Lewis BJ, Holcenberg J, Weiss RB, Young RC. Phase I study of ICRF-187 using a daily for 3 days schedule. *Cancer Treat Rep*. 1981;65(3–4):249–252.
67. Vogel CL, Gorowski E, Davila E, et al. Phase I clinical trial and pharmacokinetics of weekly ICRF-187 (NSC 169780) infusion in patients with solid tumors. *Invest New Drugs*. 1987;5(2):187–198.
68. Salzer WL, Devidas M, Carroll WL, et al. Long-term results of the pediatric oncology group studies for childhood acute lymphoblastic leukemia 1984–2001: a report from the children's oncology group. *Leukemia*. 2010;24:355–370.
69. Tebbi CK, London WB, Friedman D, et al. Dexrazoxane-associated risk for acute myeloid leukemia/myelodysplastic syndrome and other secondary malignancies in pediatric Hodgkin's disease. *J Clin Oncol*. 2007;25:493–500.
70. Kopp LM, Bernstein ML, Schwartz CL, et al. The effects of dexrazoxane on cardiac status and second malignant neoplasms (SMN) in doxorubicin-treated patients with osteosarcoma (OS). *J Clin Oncol*. 2012;30(Suppl; abstr 9503).
71. Barry EV, Vrooman LM, Dahlberg SE, et al. Absence of secondary malignant neoplasms in children with high-risk acute lymphoblastic leukemia treated with dexrazoxane. *J Clin Oncol*. 2008;26(7):1106–1111.

Cancer Management and Research**Dovepress****Publish your work in this journal**

Cancer Management and Research is an international, peer-reviewed open access journal focusing on cancer research and the optimal use of preventative and integrated treatment interventions to achieve improved outcomes, enhanced survival and quality of life for the cancer patient. The journal welcomes original research, clinical & epidemiological

studies, reviews & evaluations, guidelines, expert opinion & commentary, case reports & extended reports. The manuscript management system is completely online and includes a very quick and fair peer-review system, which is all easy to use. Visit <http://www.dovepress.com/testimonials.php> to read real quotes from published authors.

Submit your manuscript here: <http://www.dovepress.com/cancer-management-and-research-journal>