

Is monthly retreatment with intravitreal bevacizumab (Avastin[®]) necessary in neovascular age-related macular degeneration?

Nicola G Ghazi
Tyler Q Kirk
Robert M Knappe
James S Tiedeman
Brian P Conway

Department of Ophthalmology,
University of Virginia Health System,
Charlottesville, VA, USA

Purpose: To report our short-term experience with bevacizumab in neovascular age-related macular degeneration (AMD) and recommend a new treatment strategy.

Methods: Retrospective chart review of 29 consecutive patients receiving 1.25 mg of intravitreal bevacizumab for AMD and completing 12 weeks of follow up. Outcome measures were best corrected visual acuity (BCVA) and optical coherence tomography (OCT) central macular thickness. Injections were repeated if no further improvement was observed.

Results: Twenty-nine eyes of 29 patients were included. The average BCVA improved from 20/148 at baseline to 20/106 at twelve weeks ($P = 0.041$). Of the 29 eyes, 25 (86.2%) had stable or improved BCVA. Average mean central macular thickness measured by OCT improved from 351 μm at baseline to 278 μm at 12 weeks ($P = 0.003$). Stabilization of vision and improved OCT central macular thickness were maintained for at least eight weeks following only a single injection in the majority of eyes. During the three months of follow up, only five eyes (17.2%) required repeat injections, with only three (10.3%) requiring retreatment at eight weeks and none at four weeks. No significant ocular or systemic side effects were observed.

Conclusion: This short-term data suggests that bevacizumab appears to be a safe and effective treatment for neovascular AMD. Injections as frequent as every month do not appear to be necessary since initial treatment effect appears to be maintained for at least eight weeks in almost all of our patients.

Keywords: retina, Avastin[®], bevacizumab, neovascular age-related macular degeneration, AMD

Background

Antivascular endothelial growth factor (VEGF) therapy has been recently established as an effective treatment for subfoveal neovascular age-related macular degeneration (AMD). Two anti-VEGF agents, pegaptanib¹ (Macugen; Eyetech Pharmaceuticals, Inc., New York, NY) and ranibizumab (Lucentis; Genentech, Inc., South San Francisco, CA) have been demonstrated to be effective in treating neovascular AMD. Bevacizumab (Avastin[®], Genentech), a humanized monoclonal VEGF antibody derived from the same murine monoclonal antibody as ranibizumab, is approved for intravenous use in the management of colorectal cancer.² Bevacizumab was initially used via intravenous injection in the management of AMD-related choroidal neovascularization (CNV).³ Given the potential systemic thromboembolic side effects associated with the intravenous use of bevacizumab,⁴ ophthalmologists have more recently been administering the medication via intravitreal injection in neovascular AMD. Several laboratory⁵⁻⁸ and clinical⁹⁻¹⁴ studies have supported the short-term safety and efficacy of intravitreal bevacizumab. However, the long term effects, the optimal dose, and the best treatment

Correspondence: Nicola G Ghazi
Department of Ophthalmology, Texas
Tech University Health Sciences Center,
4801 Alberta Avenue, El Paso,
Texas 79905, USA
Tel +1 915 545 6999
Fax +1 915 545 9450
Email n.ghazi@ttuhsc.edu

regimen have not been clarified. We report our short-term experience with intravitreal bevacizumab in the treatment of AMD-related subfoveal CNV, and based on these findings, suggest that a treatment interval of greater than one month may be sufficient.

Methods

Twenty-nine consecutive patients with subfoveal CNV due to neovascular AMD who completed three months of follow-up were included in the study. Intravitreal injection of bevacizumab was performed either as salvage or as primary therapy after all other treatment options were discussed. The Institutional Review Board (IRB) at the University of Virginia approved this retrospective chart review.

All included patients received 1.25 mg of intravitreal bevacizumab (0.05 mL of the aliquoted commercial solution of Avastin®) following a complete ocular evaluation, which included best-corrected Snellen visual acuity (BCVA), complete ocular examination, fluorescein angiography (FA), and optical coherence tomography (OCT Stratus, Model number 3000; Carl Zeiss Ophthalmic Systems, Dublin, CA, USA). Patients with a history of hypertension and thromboembolic events were not automatically excluded, since intravitreal administration of bevacizumab has not been shown to be unsafe in this population. Based on individual physician practices, patients were reevaluated at about two, four, eight, and 12 weeks following treatment. Moreover, ocular imaging with FA and OCT was not routinely performed at each follow up visit; however, OCT imaging was done for all included patients at presentation and at 12 weeks following initiation of treatment. Injections were repeated only if worsening or no further improvement in BCVA, macular edema, subretinal fluid, and/or pigment epithelial detachment was observed later during follow up after an initial favorable functional and/or anatomical response. Other forms of treatment were considered at the clinician's discretion in eyes with no measurable response or worsening after bevacizumab.

Best-corrected Snellen acuity was converted into logarithm of the minimum angle of resolution (logMAR) for statistical analysis. Mean visual acuity and OCT central macular thickness at baseline and each follow up visit were compared using a Student's *t*-test to determine statistical significance with 95% confidence intervals ($P < 0.05$).

Results

Out of the 29 patients included in the study, 21 were females. The age ranged from 62 to 89 years (mean, 77.7 years). All treated eyes completed 12 weeks of follow up. Visual

acuity and OCT data were available for all eyes at baseline and at 12 weeks follow up. The two-, four-, and eight-week data were available for 65.5%, 55.2%, and 55.2% of eyes, respectively. Of all 29 eyes, 20 (69.0%) had received prior treatments, 17 (58.6%) photodynamic therapy, five (17.2%) laser photocoagulation, one (3.4%) intravitreal triamcinolone, and one (3.4%) intravitreal pegaptanib.

The average BCVA improved from 20/148 at baseline to 20/106 at 12-week follow-up ($P = 0.041$). Twenty-five eyes (86.2%) had stable or improved BCVA (Figure 1) and nine eyes (31.0%) ended up with 20/50 vision or better. Eighteen (62.1%) and 11 (37.9%) eyes experienced at least one and two lines of vision improvement, respectively. Only four eyes had worse BCVA at 12 weeks compared to baseline. Improvement in average visual acuity occurred over the first four weeks of follow up ($P = 0.006$), after which a trend towards stabilization was observed (Figure 2).

Average mean central macular thickness measured by OCT improved from 351 μm at baseline to 278 μm at 12 weeks ($P = 0.003$). Twenty-four eyes (82.8%) had improved central macular thickness (Figure 3) and 15 eyes (51.7%) had less than 250 microns central macular thickness by 12 weeks (Figure 4). The majority of the change in average central macular thickness was observed over the first two weeks following treatment ($P = 0.0001$) and improvement was maintained through the 12-week follow-up visit (Figure 5). Worsening in average central macular thickness was observed at the four-week visit compared to the two-week visit but this was not associated with worsening in average BCVA. Twelve eyes had FA at the 12-week follow-up visit. Out of those, nine eyes (75%) had stable or less leakage compared to baseline, out of which six eyes (66.7%) had less leakage.

During the three months follow up, fewer than a fifth of the eyes (five eyes, 17.2%) required repeat injections, with only three eyes (10.3%) requiring retreatment at eight weeks and none at four weeks. No ocular or systemic side effects were observed, although patients were not specifically monitored for variations in their blood pressure during follow up.

Conclusion

Most eyes treated with bevacizumab in this study had a favorable anatomical and functional response, and 62.1% had improved BCVA by at least one line. As in previous studies,^{9,11–13} BCVA and central macular thickness as measured by OCT were stabilized or improved in the majority of eyes (86.2% and 82.8% respectively; Figures 1 and 3).

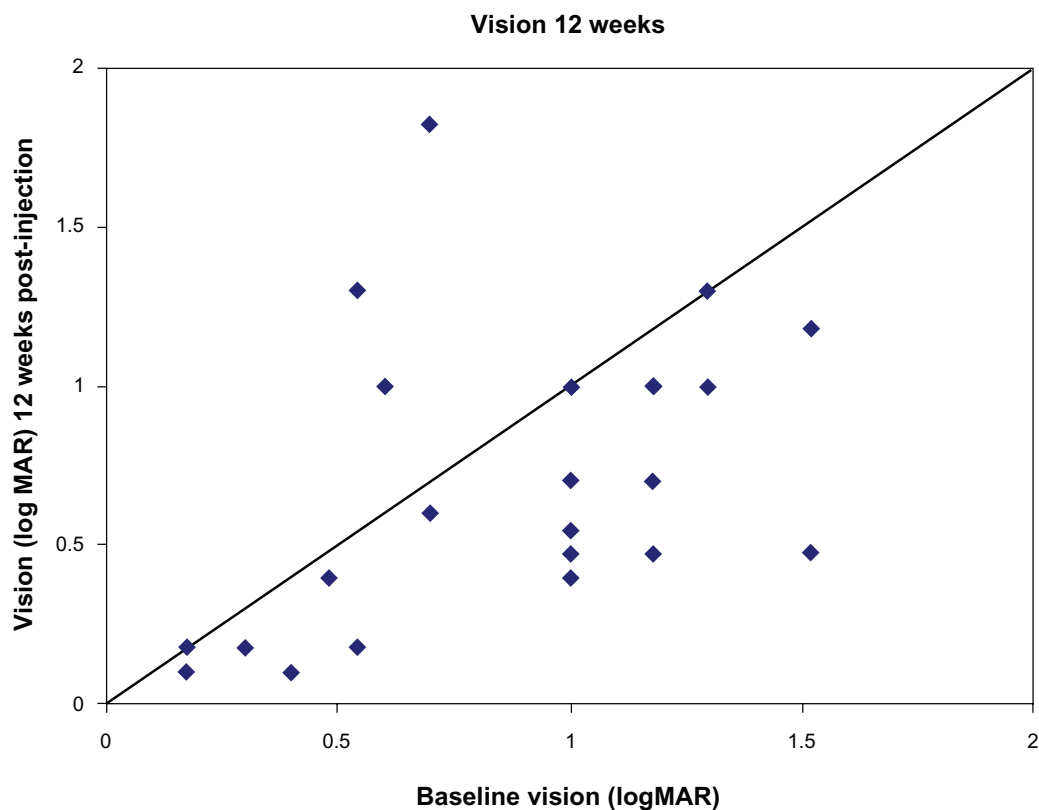


Figure 1 Change in visual acuity 12 weeks after initial treatment with bevacizumab (scatter plot).

Note: All dots below the line indicate eyes with improved vision.

Abbreviation: LogMAR, logarithm of the minimal angle of resolution.

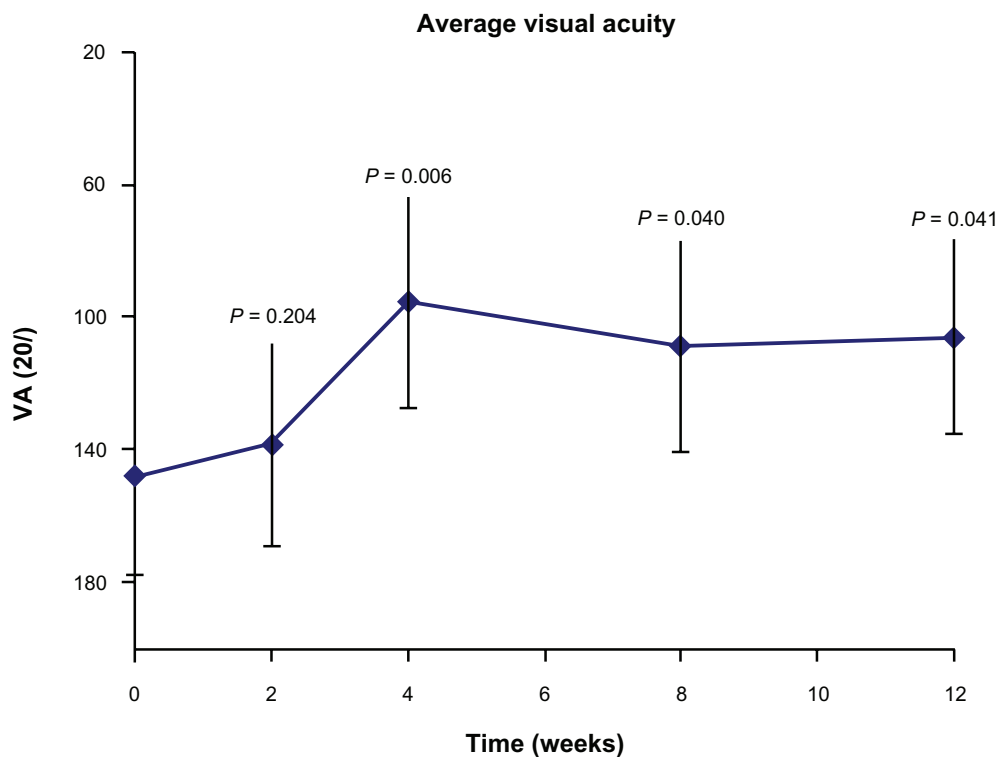


Figure 2 Change in average best-corrected Snellen visual acuity (VA) over time following initial treatment with bevacizumab.

Notes: The majority of the change occurred in the first 4 weeks following treatment with stabilization afterwards. *P* values at each follow up visit were obtained by comparing with baseline (*P* value less than 0.05 indicates statistical significance).

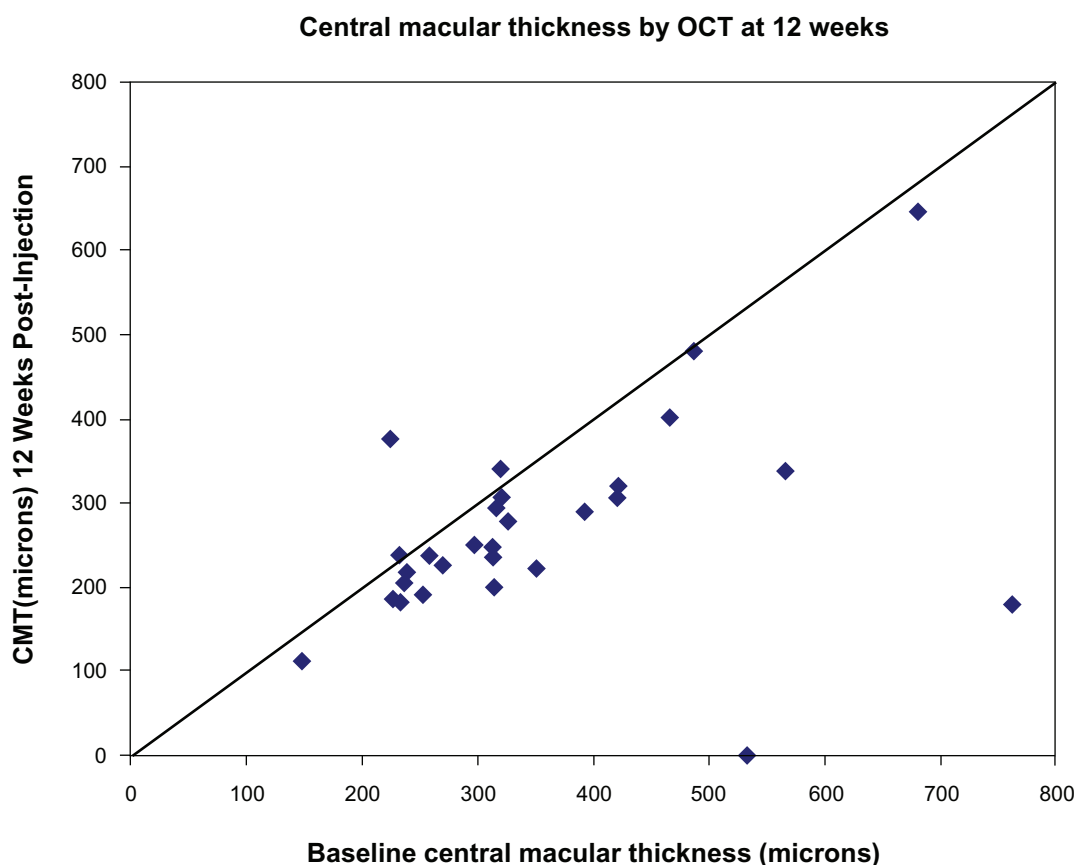


Figure 3 Change in average central macular thickness (CMT) as measured by optical coherence tomography (OCT) 12 weeks after initial treatment with bevacizumab (scatter plot).

Note: All dots below the line indicate eyes with reduced CMT.

Most of the change in BCVA and central OCT thickness was observed in the first month and first two weeks following initial treatment respectively (Figures 2 and 5). However, the treatment regimen used in this study differs from previous studies in that patients were not routinely treated on a monthly basis for the first three months in a manner similar to the ranibizumab studies. In the series reported by Bashshur and colleagues¹³ and Avery and colleagues,⁹ all eyes received monthly bevacizumab for the first three months. Moreover, Spaide and colleagues¹¹ reported that “patients were treated with the thought that they would be given three injections separated by one month and then followed until leakage reoccurred.” But no further details regarding the number of eyes reinjected as a function of time were reported. On the other hand, Rich and colleagues¹² reported that “while reinjections were at the discretion of the treating physician, most patients were treated until the OCT revealed no evidence of macular fluid and then retreated when the fluid recurred.” In this study, because we wished to minimize the ‘off-label’ use of an unproven agent, injections were repeated only if we felt that the effects of the injection were ‘wearing off’, as indicated by no further improvement or worsening later

during follow up after an initial favorable functional and/or anatomical response.

While it remains unknown how best to treat patients with intravitreal anti-VEGF therapy, particularly bevacizumab, we believe that fixed interval regimens used in previous studies may interfere with the ability to understand the pharmacokinetic properties of this drug. This also does not allow for establishing the optimal frequency of reinjection. Treating on a monthly basis for the first three months^{9,13} or until the OCT reveals no evidence of macular fluid¹² obscures the duration of effect of each injection and result in excessive number of injections that may be unnecessary. This likely explains why 55% of eyes reported by Rich and colleagues¹² (and 100% of eyes reported by Avery and colleagues⁹ and Bashshur and colleagues¹³ required retreatment after one month from initial injection compared to our study, where less than a fifth of the eyes (17.2%) required repeat injections during the three months follow up. In this study, eyes that showed initial OCT improvement were not retreated even if the OCT disclosed residual macular fluid. The presence of residual fluid may not necessarily mean that retreatment is indicated. Residual fluid may still indicate “less” fluid, which still suggests a good,

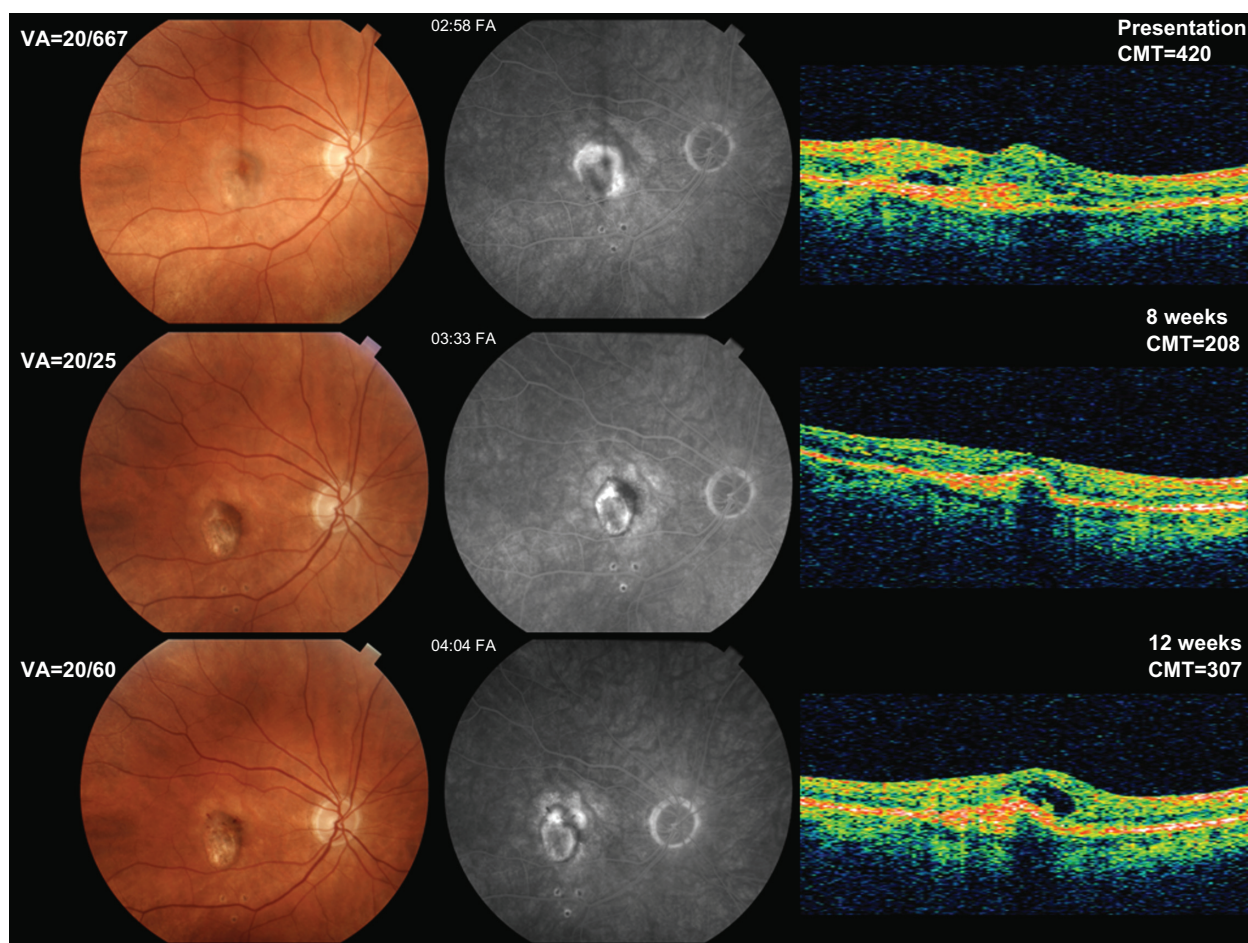


Figure 4 Fundus photos (left column), late fluorescein angiography frames (middle column) and optical coherence tomography (OCT; right column, same orientation scan in all three images) at presentation (upper row), eight weeks (middle row) and 12 weeks follow up (lower row) of the right eye of a patient with good response to bevacizumab. Following only one injection of bevacizumab, best-corrected visual acuity (VA) and central macular thickness (CMT; in microns) improved from 20/667 and 420 microns at presentation to 20/25 and 208 microns and to 20/60 and 307 microns at eight and 12 weeks, respectively.

Notes: Note absence of leakage on angiography with total resolution of intra-and-subretinal fluid on OCT by eight weeks following a single injection of bevacizumab. Retreatment was performed at 12 weeks because of worsening vision, active leakage along the superior border of the neovascular lesion and increased CMT (third row).

and possibly ongoing, response to treatment. Only eyes that experienced no further improvement or worsening after an initial favorable response were retreated.

In addition, treatment strategies used in ranibizumab¹⁵ trials with monthly injections do not necessarily apply to bevacizumab. The half-life of intravitreal bevacizumab is thought to be about twice that of ranibizumab.¹⁶ Mordenti and colleagues¹⁷ reported that the vitreous half life of a recombinant human monoclonal antibody rhuMAB HER2 (trastuzumab; Genentech), which is a molecule similar to bevacizumab, is 5.6 days. The authors concluded that injections of the antibody into the vitreous cavity may provide adequate concentrations for up to two months.¹⁷ Thus, less frequent bevacizumab administration may theoretically be required over a certain period of time compared to ranibizumab. During the three months follow up in this study, less than a fifth of the eyes (five eyes, 17.2%) required repeat

injections, with only three eyes (10.3%) requiring retreatment at eight weeks and none at four weeks. This suggests that monthly injections may not be necessary and that treatment effect appears to be maintained for at least eight weeks in the majority of cases. While it is possible that we inadvertently selected a group of 29 eyes that happened to be exceptional responders to bevacizumab, the fact that our findings are comparable to those reported by other investigators^{9,12,13} suggests that a less frequent dosing regimen may be as effective as monthly injections. Less frequent administration may greatly impact the United States health care system expenditure for AMD care, in addition to reducing the risk of intraocular infection inherent with each injection.

On the other hand, a potential downside related to a longer half-life is longer than desired duration of action in the case of ocular or systemic toxicity. While the systemic use of bevacizumab has been associated with an increased risk

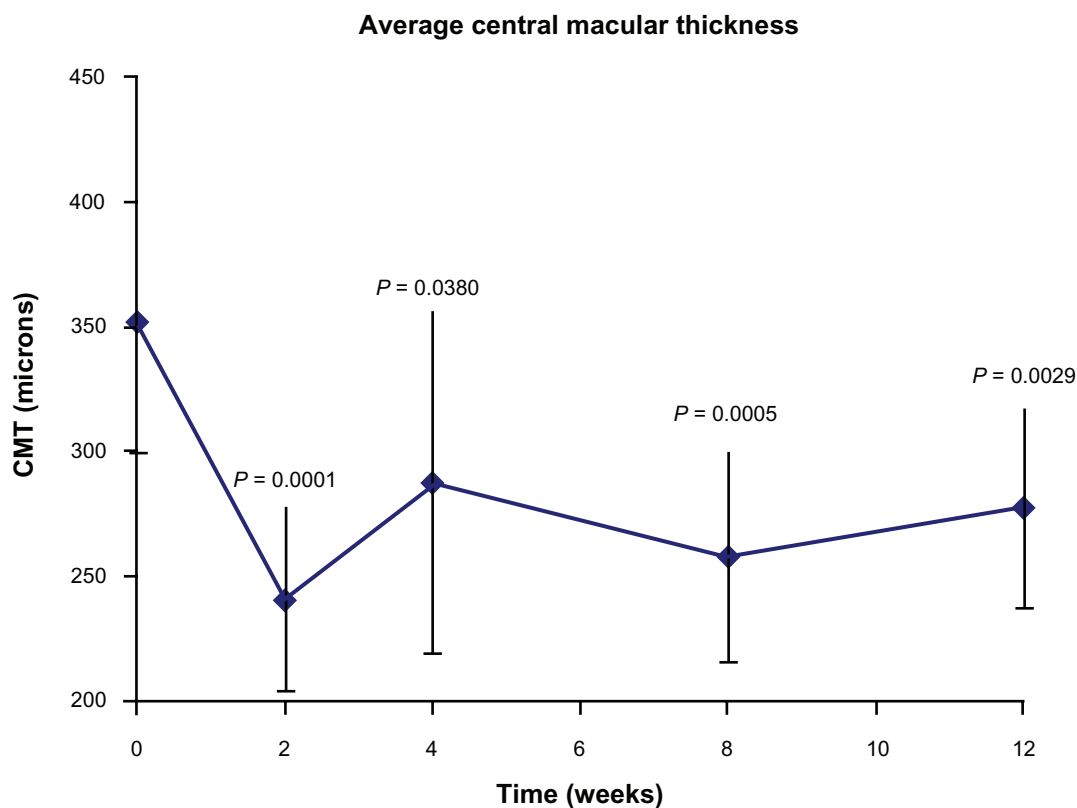


Figure 5 Change in average central macular thickness (microns) over time as measured by optical coherence tomography (OCT) following initial treatment with bevacizumab.

Notes: The majority of the change occurred in the first two weeks following treatment with stabilization afterwards. *P* values at each follow-up visit were obtained by comparing with baseline (*P* value less than 0.05 indicates statistical significance).

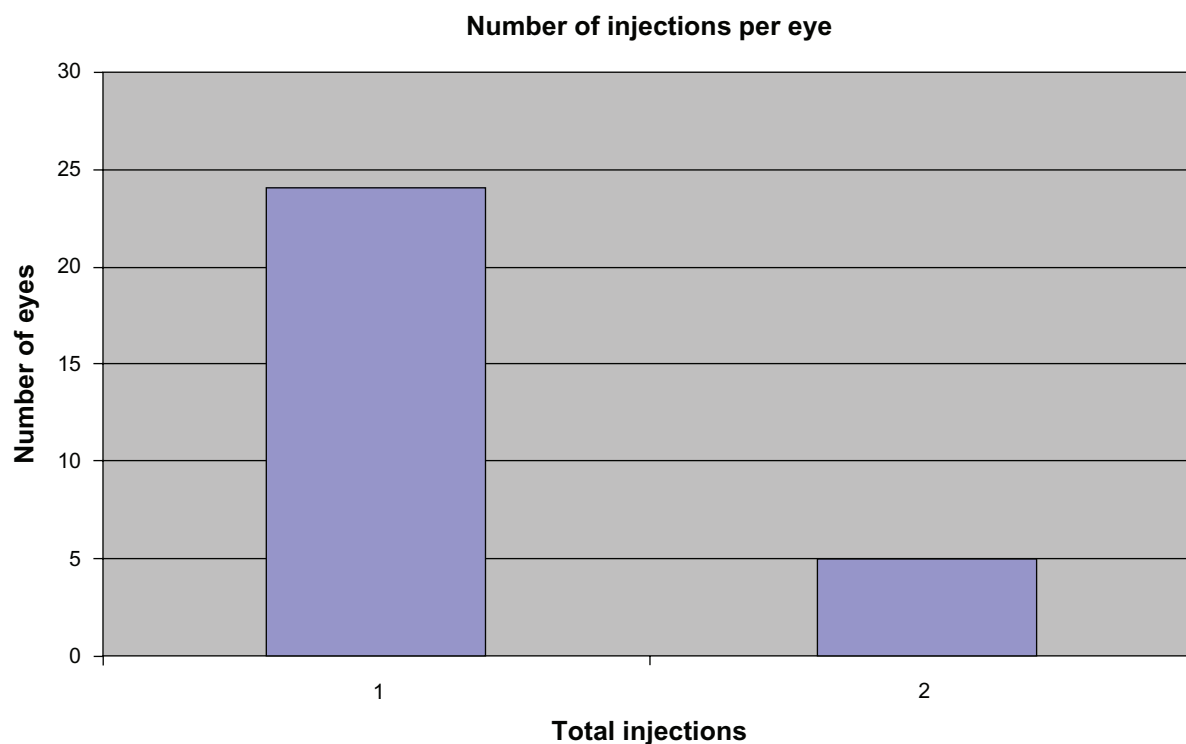


Figure 6 Number of eyes that required repeat bevacizumab injections during the three-month follow-up period.

Note: Only five out of 29 eyes required repeat injections.

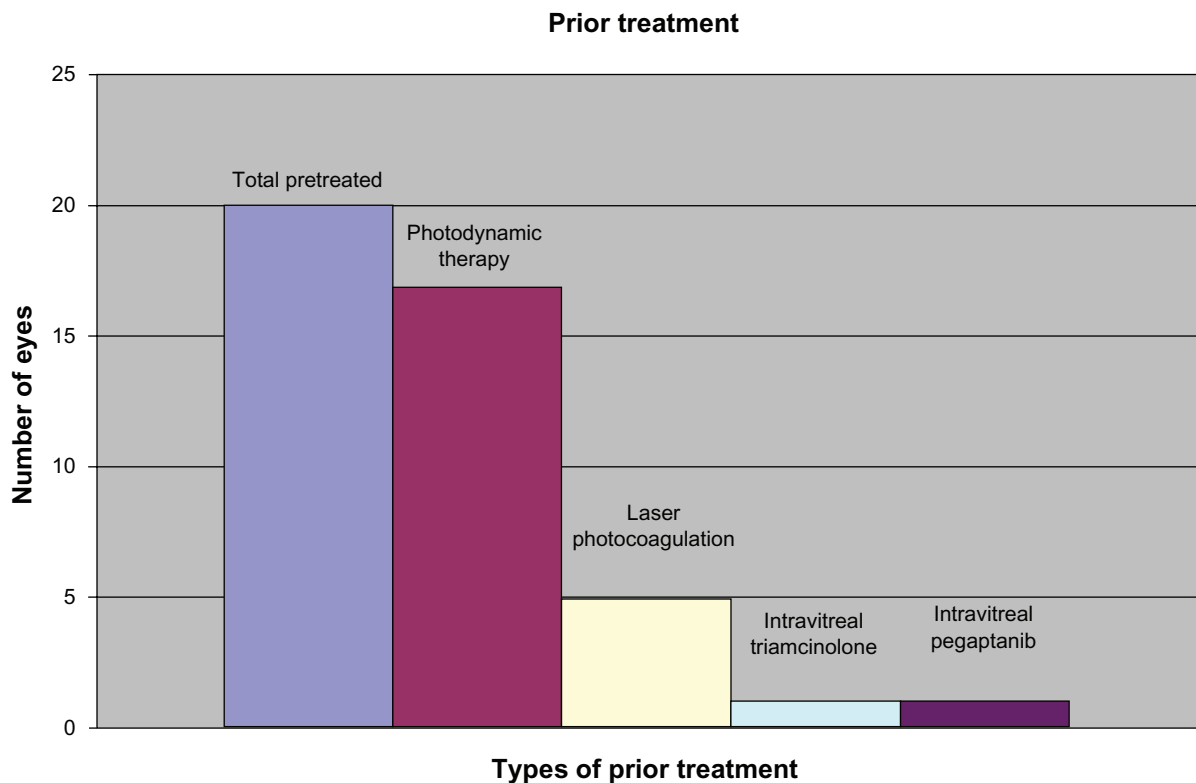


Figure 7 Breakdown of the eyes and the various types of treatment rendered prior to bevacizumab. Twenty of 29 eyes (69.0%) had received prior treatment. The majority of eyes received photodynamic therapy prior to bevacizumab.

of gastrointestinal bleeding, thromboembolic phenomena and hypertension,³ particularly in patients with cancer,⁴ no significant ocular or systemic effects have been reported with its intravitreal use to date.^{9–13} Out of all previous studies, only Spaide and colleagues¹¹ reported that three (1.2%) out of 251 patients developed mild vitritis following treatment, one patient had a nonfatal myocardial infarction, two patients had transient ischemic attacks, and two patients died while under treatment with bevacizumab. However, the authors concluded that the risk of intraocular inflammation appears to be less than that observed in the pegaptanib and ranibizumab trials (about 16%), and that the risk for thromboembolic disorders did not seem to be different than reported in previous studies on AMD. This observed short-term safety profile for intravitreal as compared to intravenous bevacizumab may be related to the localized nature of intraocular injections and the much smaller intravitreal dose (1.25–2.50 mg, about 400 times smaller than the intravenous dose used for neovascular AMD³). The safety profile of intraocular bevacizumab has been recently emphasized in the international intravitreal bevacizumab safety survey where over a mean follow up of 3.5 months none of the adverse event rates exceeded 0.21%.¹⁸ While the overall safety profile of both intravitreal bevacizumab and ranibizumab has been established, Klettner and colleagues¹⁹ have recently noted

that bevacizumab, and not ranibizumab, accumulates in RPE cells over time, suggesting that differences in their molecular structure and cellular interactions may prove clinically significant over time.

While the results of this study are encouraging, several shortcomings are worth mentioning. These include the retrospective design with varying baseline characteristics of included eyes, short-term follow up, small number of patients, lack of a control group, nonstandardized visual acuity testing, variability in prebevacizumab treatment, absence of defined inclusion and exclusion criteria other than subfoveal CNV due to AMD, and variable practice patterns by individual physicians involved in the study. Yet this short term data suggests that intravitreal bevacizumab is a safe and effective treatment for neovascular AMD. It also suggests that an injection frequency less than once per month may be sufficient since initial treatment effect was maintained for at least eight weeks in the majority of cases. We believe that an injection interval of eight weeks is not only as effective as four weeks, but also safer and less expensive. Nonetheless, prospective, controlled clinical trials are needed to determine the optimal dosing strategy and the long-term safety and efficacy of intravitreal bevacizumab.

Disclosures

Supported by intradepartmental funds through the Lions Sight Foundation of Virginia, 11-10-2009. The authors report no conflicts of interest in this work.

References

1. Gragoudas ES, Adamis AP, Cunningham ET Jr, et al. VEGF Inhibition Study in Ocular Neovascularization Clinical Trial Group, Pegaptanib for neovascular age-related macular degeneration. *N Engl J Med*. 2004;351:2805–2816.
2. Hurwitz H, Fehrenbacher L, Novotny W, et al. Bevacizumab plus irinotecan, fluorouracil, and leucovorin for metastatic colorectal cancer. *N Engl J Med*. 2004;350:2335–2342.
3. Michels S, Rosenfeld PJ, Puliafito CA, et al. Systemic bevacizumab (Avastin) therapy for neovascular age-related macular degeneration: Twelve-week results of an uncontrolled open-label clinical study. *Ophthalmology*. 2005;112:1035–1047.
4. van Wijngaarden P, Coster DJ, Williams KA. Inhibitors of ocular neovascularization promises and potential problems. *JAMA*. 2005;293:1509–1513.
5. Bakri SJ, Cameron JD, McCannel CA, et al. Absence of histologic retinal toxicity of intravitreal bevacizumab in a rabbit model. *Am J Ophthalmol*. 2006;142:162–164.
6. Luthra S, Narayanan R, Marques LE, et al. Evaluation of in vitro effects of bevacizumab (Avastin) on retinal pigment epithelial, neurosensory retinal, and microvascular endothelial cells. *Retina*. 2006;26:512–518.
7. Shahar J, Avery RL, Heilweil G, et al. Electrophysiologic and retinal penetration studies following intravitreal injection of bevacizumab (Avastin). *Retina*. 2006;26:262–269.
8. Manzano RP, Peyman GA, Khan P, Kivilcim M. Testing intravitreal toxicity of bevacizumab (Avastin). *Retina*. 2006;26:257–261.
9. Avery RL, Pieramici DJ, Rabena MD, et al. Intravitreal bevacizumab (Avastin) for neovascular age-related macular degeneration. *Ophthalmology*. 2006;113:363–372. e5.
10. Maturi RK, Bleau LA, Wilson DL. Electrophysiologic findings after intravitreal bevacizumab (Avastin) treatment. *Retina*. 2006;26:270–274.
11. Spaide RF, Laud K, Fine HF, et al. Intravitreal bevacizumab treatment of choroidal neovascularization secondary to age-related macular degeneration. *Retina*. 2006;26:383–390.
12. Rich RM, Rosenfeld PJ, Puliafito CA, et al. Short-term safety and efficacy of intravitreal bevacizumab (Avastin) for neovascular age-related macular degeneration. *Retina*. 2006;26:495–511.
13. Bashshur ZF, Bazarbachi A, Schakal A, et al. Intravitreal bevacizumab for the management of choroidal neovascularization in age-related macular degeneration. *Am J Ophthalmol*. 2006;142:1–9.
14. Yamamoto I, Rogers AH, Reichel E, et al. Intravitreal bevacizumab (Avastin) as treatment for subfoveal choroidal neovascularization secondary to pathologic myopia. *Br J Ophthalmol*. 2007;91:157–160.
15. Heier JS, Antoszyk AN, Pavan PR, et al. Ranibizumab for treatment of neovascular age-related macular degeneration: a phase I/II multicenter, controlled, multidose study. *Ophthalmology*. 2006;113(4):642. e1–e4.
16. Mordenti J, Cuthbertson RA, Ferrara N, et al. Comparisons of the intraocular tissue distribution, pharmacokinetics, and safety of 125I-labeled full-length and Fab antibodies in rhesus monkeys following intravitreal administration. *Toxicol Pathol*. 1999;27:536–544.
17. Mordenti J, Thomsen K, Licko V, et al. Intraocular pharmacokinetics and safety of a humanized monoclonal antibody in rabbits after intravitreal administration of a solution or a PLGA microsphere formulation. *Toxicol Sci*. 1999;52:101–106.
18. Fung AE, Rosenfeld PJ, Reichel E. The international intravitreal bevacizumab safety survey: using the internet to assess drug safety worldwide. *Br J Ophthalmol*. 2006;90(11):1344–1349.
19. Klettner AK, Kruse ML, Meyer T, et al. Different properties of VEGF-antagonists: bevacizumab but not ranibizumab accumulates in RPE cells. *Graefes Arch Clin Exp Ophthalmol*. 2009;247(12):1601–1608.

Clinical Ophthalmology

Publish your work in this journal

Clinical Ophthalmology is an international, peer-reviewed open-access journal committed to the rapid publication of the latest laboratory and clinical findings in the fields of diabetes, metabolic syndrome and obesity research. Original research, review, case reports, hypothesis formation, expert opinion and commentaries are all considered for

publication. The manuscript management system is completely online and includes a very quick and fair peer-review system, which is all easy to use. Visit <http://www.dovepress.com/testimonials.php> to read real quotes from published authors.

Submit your manuscript here: <http://www.dovepress.com/diabetes-metabolic-syndrome-and-obesity-targets-and-therapy-journal>