

Effectiveness of Suprachoroidal Injection of Triamcinolone Acetonide in Resistant Diabetic Macular Edema Using a Modified Microneedle

Amin E Nawar 

Ophthalmology Department, Faculty of Medicine, Tanta University, Tanta, Egypt

Correspondence: Amin E Nawar, Ophthalmology Department, Faculty of Medicine, Tanta University, Tanta, 31516, Egypt, Tel +20 1140095692, Email nawar20012002@gmail.com

Purpose: The present study evaluated the effectiveness of suprachoroidal injection of triamcinolone acetonide (TA) in resistant diabetic macular edema (DME) using a modified microneedle.

Patients and Methods: This is a prospective nonrandomized interventional study that was conducted on 55 eyes of 39 patients with centrally involving DME resistant to previous anti-vascular endothelial growth factor (VEGF) agents. All patients received suprachoroidal injection of triamcinolone acetonide 4 mg/0.1 mL by a modified specialized microneedle.

Results: The mean central macular thickness (CMT) decreased significantly from 478.7 ± 170.2 μ m before injection to 230.2 ± 47.4 μ m after 12 months with p -value < 0.001 . Significant improvement of the mean best corrected visual acuity (BCVA) from 1.193 ± 0.2 by logMAR at the baseline to 0.76 ± 0.3 by logMAR was achieved after 12 months with p -value < 0.001 . The IOP increased significantly at one month after injection and returned to the baseline value at the third month. Eyes with more baseline CMT and worse baseline BCVA achieved worse final BCVA 12 months after injection. Eyes with inner segment/outer segment (IS/OS) disruption and neurosensory detachment (NSD) showed worse final visual outcomes. IS/OS segment disruption, NSD and baseline BCVA were the main independent predictors of the final BCVA.

Conclusion: Suprachoroidal injection of TA using this new modified microneedle resulted in marked anatomical and functional results in cases of DME resistant to previous anti-VEGF drugs with no serious ocular or systemic side effects. The study was prospectively registered with clinical trial.gov ID (NCT04690608) in 27–12-2020.

Keywords: diabetic macular edema, suprachoroidal injection, triamcinolone acetonide, optical coherence tomography

Introduction

Diabetic macular edema (DME) is the main leading cause of visual loss in diabetic patients. In the past, laser was the mainstay in DME management,¹ but nowadays, three main anti-vascular endothelial growth factor agents (anti-VEGF) are currently available including aflibercept (Eylea, Bayer, Leverkusen, Germany), ranibizumab (Lucentis, Novartis, Basel, Switzerland) and bevacizumab (Avastin, Genentech Inc., San Francisco, CA, USA).² Despite their wide use in DME, some patients are not responsive to this type of therapy.³

Triamcinolone acetonide (TA) is a synthetic corticosteroid that has been used over the last decades as a treatment of various inflammatory conditions,⁴ it can reduce macular edema and improve visual acuity.⁵ Due to the poor compliance and the high cost of anti-VEGF agents, intravitreal injection of TA (IVTA) can be used as an alternative tool in cases resistant to anti-VEGF drugs, but secondary glaucoma and cataract progression were the main drawbacks of IVTA in DME management.⁶ Sustained release steroid implants are now available like Ozurdex[®] and Iluvien[®]. Ozurdex[®] (Allergan, Inc., Irvine, USA) is a dexamethasone implant that can slowly release steroids into the vitreous cavity for six months, it has a lower complication rate if compared to IVTA but still can lead to cataract and elevated intraocular

pressure (IOP);⁷ this raised the interest of the researchers in exploring other methods of TA delivery to the eye rather than intravitreal route to reduce its dangerous side effects.

The suprachoroidal space is a new route for TA delivery to the posterior segment of the eye, in a study done on rabbits, the concentration of TA in the posterior segment after suprachoroidal injection was 12 folds higher than intravitreal route with a lower amount of the drug detected in the anterior segment and the crystalline lens, thus suprachoroidal route minimized steroid complications regarding IOP elevation and cataract.⁸ Many studies proved the efficacy of suprachoroidal injection of steroids in treating cystoid macular edema (CME) due to uveitis and retinal vein occlusion, but the high cost of specialized microneedles was the main obstacle.^{9–11}

The present study evaluated suprachoroidal injection of TA by a modified inexpensive microneedle in cases of DME resistant to previous anti-VEGF agents.

Methods

Study Design

A prospective, nonrandomized, interventional study that was conducted on 55 eyes of 39 patients with resistant DME. The study was performed in Tanta University Ophthalmology Hospital, cases were recruited in January 2021 and the results were obtained after 12 months in January 2022. The study was approved by the Ethical Committee of the Faculty of Medicine, Tanta University, Egypt (approval code 34328/12/20). All procedures were performed under the tenets of the 1964 Declaration of Helsinki. Written informed consent was obtained from every participant after explaining the procedure, follow-up plans, possible benefits, and side effects. The study was prospectively registered with clinical trial.gov ID (NCT04690608) on December 27, 2020.

Participants

Thirty-nine patients more than 30 years old diagnosed with centrally involving DME on top of type 1 or type 2 diabetes mellitus were included. Suprachoroidal injection of triamcinolone acetonide 4 mg/0.1 mL was decided after diagnosis of resistant DME. Patients with one or more of the following characteristics were considered to have resistant DME after at least three consecutive injections of one of the three anti-VEGF agents (20 eyes received bevacizumab, 20 eyes received ranibizumab and the remaining 15 eyes received aflibercept) spaced at one month apart: (1) central macular thickness (CMT) more than 300 μ m by spectral-domain optical coherence tomography (SD-OCT), (2) failure of reduction of the CMT by more than 10% of baseline thickness before injection, or (3) failure to improve best corrected visual acuity (BCVA) by one line in the Snellen chart. Careful ophthalmic evaluation was performed for all patients including, BCVA by logMAR for statistical analysis, measurement of intraocular pressure (IOP) by applanation tonometry, slit lamp examination of the anterior segment, and retinal examination using slit lamp biomicroscopy by +78 D lens and indirect ophthalmoscopy. Spectral domain optical coherence tomography (SD- OCT) (Topcon 3D OCT) with a vertical line scan protocol centered on the fovea was performed for all patients at presentation and after 1, 3, 6, 9, and 12 months. Patients with history of previous intraocular surgery, other posterior segment pathology as retinal vascular occlusion, age-related macular degeneration, choroidal neovascular membrane (CNV), posterior uveitis and retinal degeneration were excluded. Cases with a history of previous intervention in the form of laser photocoagulation and intravitreal injection of steroids like triamcinolone acetonide and dexamethasone implants were also excluded from the study. Furthermore, patients with hazy media that interfered with good quality of OCT images and patients who did not complete 12 months of follow-up were not enrolled in our study. Systemic exclusion criteria included patients with renal failure or under dialysis, patients with major disease requiring hospitalization such as myocardial infarction, stroke, and heart failure, along with pregnant and lactating females.

Surgical Technique

Injection was performed by a single surgeon (AEN) in the operating theater. Patients were prepared by topical fluoroquinolone eye drops (moxifloxacin hydrochloride 0.5%, Vigamox, Alcon, USA) four times daily for three days before injection. Dilatation of the pupil was performed using Mydracil eye drops (tropicamide 1%, Alcon) followed by topical anesthesia by a drop of (benoxinate hydrochloride 0.4%, Benox, Epico, Egypt) was applied to the ocular

surface followed by topical instillation of 10% povidone iodine (Betadine®) for lids, eye lashes and periocular area and application of 5% povidone iodine into the conjunctival sac for three minutes before injection. For injection, 30 gauge 1 cc insulin syringe (Sungshim Medical Co., Ltd, Korea) and 24 gauge intravenous branula were used. Needle was withdrawn from the branula and then the branula was cut to allow only 1000 µm of insulin syringe to be exposed from the edge of branula, 0.1 mL (4 mg) of triamcinolone acetonide (Kenakort A by GlaxoSmithKline Brentford, Middlesex, UK) was injected in the operating room in the superotemporal quadrant 3.5 mm from the limbus with bevel pointing backwards. Perpendicular entry with slight pressure was performed to produce little scleral depression, if no resistance, the plunger was pushed and injection was performed followed by application of cotton tipped applicator to minimize reflux of the drug. Fundus examination to exclude inadvertent entry of triamcinolone acetonide into the vitreous and assessment of light perception immediately after injection were done to exclude central retinal artery occlusion (a video showing the preparation of the needle and the injection technique was supplied as [Supplementary Video S1](#)). After injection, topical antibiotic drop was applied (moxifloxacin hydrochloride 0.5%, Vigamox, Alcon, USA) and the eye was patched for several hours. After surgery topical antibiotic drops four times daily for three days and topical beta blocker drops (betaxolol HCL 0.5% Betoptic, Alcon, Novartis company) along the period of the study were prescribed to the patient. Injection was repeated every three months during the 12-month follow-up period if persistent intraretinal, subretinal fluid or intraretinal cysts were detected by OCT, CMT more than 250 µm and decline in BCVA by more than one line in the Snellen chart.

Examination Schedule

The patient was examined the next day and three days after injection to exclude major complications as uveitis, endophthalmitis, elevated IOP, vitreous hemorrhage, and retinal detachment, then the patient was examined monthly along the period of the study, at each visit, assessment of the BCVA, IOP measurement and slit lamp examination. OCT assessment of the macular area was performed after 1, 3, 6, 9, and 12 months of injection.

Primary outcomes included BCVA improvement and CMT reduction 12 months after injection while secondary outcomes include assessment of the safety of suprachoroidal injection of TA in DME cases resistant to previous anti-VGEF agents and its ability of decreasing the frequency of injections and reducing patient injection burden.

Statistical Analysis

Data analysis was done by IBM SPSS Statistics for Windows, Version 25.0. (IBM Corporation, Armonk, NY, USA, 2017). Categorical variables were expressed as number and percentage, while mean and standard deviation were used to express continuous data. Repeated measure ANNOVA test was used for comparing CMT, BCVA, and IOP at baseline, 1, 3, 6, 9, and 12 months. Student's *t*-test was used to compare continuous variables between the two groups. Correlation coefficient was used to express correlation between final CMT, final BCVA and other variables. Multivariable linear regression analysis was used to detect the independent predictors of the final BCVA. Categorical data included as regression model as dummy variables, which was coded as 0 for absent IS/OS (inner segment/outer segment) disruption and NSD (neurosensory detachment) and 1 for the presence of IS/OS disruption and NSD. A *p*-value of ≤0.05 was considered statistically significant.

Results

Six patients who received a single suprachoroidal injection were lost to follow-up after six months and were excluded from the study. Fifty-five eyes of 39 patients were enrolled in the present study. The mean age of the studied patients was 53.7±10.3 years, the study included 12 males and 27 females, the mean value of HbA1c was 8.4±0.6% and the mean duration of DM was 14.9±4.1 years. Concerning clinical data, IS/OS disruption was present in 26 eyes (47.3%) and NSD was detected in 19 eyes (34.5%). Regarding the number of injections, it ranged from 1–4 injections, most of the eyes (20 eyes) representing (36.4%) needed only two injections along the period of the study, 60% of these 20 eyes (12 eyes) needed the second injection at the third month. Fourteen eyes needed three injections and most of these eyes (11 eyes) needed the second injection at the third month. These sociodemographic and clinical characteristics are illustrated in [Table 1](#).

Table 1 Sociodemographic and Clinical Characters

Variables	N (%) / Mean \pm SD
Patient parameters	N=39 patients
Age	53.7 \pm 10.3
Gender	
Male	12 (30.8)
Female	27 (69.2)
Side	
Unilateral	23 (58.97)
Bilateral	16 (41.03)
HbA1c	8.4 \pm 0.6
Duration of DM in years	14.9 \pm 4.1
Eye parameters	N=55 eyes
IS/OS disruption	
Absent	29 (52.7)
Present	26 (47.3)
NSD	
Absent	36 (65.5)
Present	19 (34.5)
Number of injections	
1	12 (21.8)
2	20 (36.4)
3	14 (25.5)
4	9 (16.4)

Abbreviations: HbA1c, glycosylated hemoglobin; DM, diabetes mellitus; IS/OS, inner segment/outer segment; NSD, neurosensory detachment.

The present study detected statistically significant decrease in the mean CMT from 478.7 \pm 170.2 μ m before injection to 230.2 \pm 47.4 μ m after 12 months with p -value <0.001 (Figure 1). The mean BCVA improved significantly from 1.193 \pm 0.2 by logMAR at the baseline to 0.76 \pm 0.3 by logMAR after 12 months with p -value <0.001 (Figure 2). The IOP reached its maximum value one month after injection (increased from 12.31 \pm 0.2 mmHg before injection to 13.3 \pm 0.5 mmHg after one month) with p -value <0.001 and declined gradually till it reached the baseline value at the third month with topical beta blocker eye drops and remained relatively stable until the end of the study, no eyes needed glaucoma surgeries. The changes in CMT, BCVA, and IOP are shown in Table 2.

Positive correlation was detected between the number of injections and the final CMT with p -value <0.001. In addition, eyes with more baseline CMT and worse baseline BCVA before injection showed worse final BCVA, this is well documented in the strong positive correlation between baseline CMT and BCVA with the final BCVA with p -value <0.001. Furthermore, eyes with IS/OS disruption showed worse final BCVA with p -value <0.001 and eyes with NSD showed worse final BCVA with p -value 0.001. These findings are illustrated in Table 3.

Multivariable linear regression analysis to detect independent predictors of the final BCVA is shown in Table 4, it was detected that IS/OS disruption, NSD and baseline BCVA were the only predictors of the final BCVA after injection with p -values <0.001, 0.01, and <0.001, respectively.

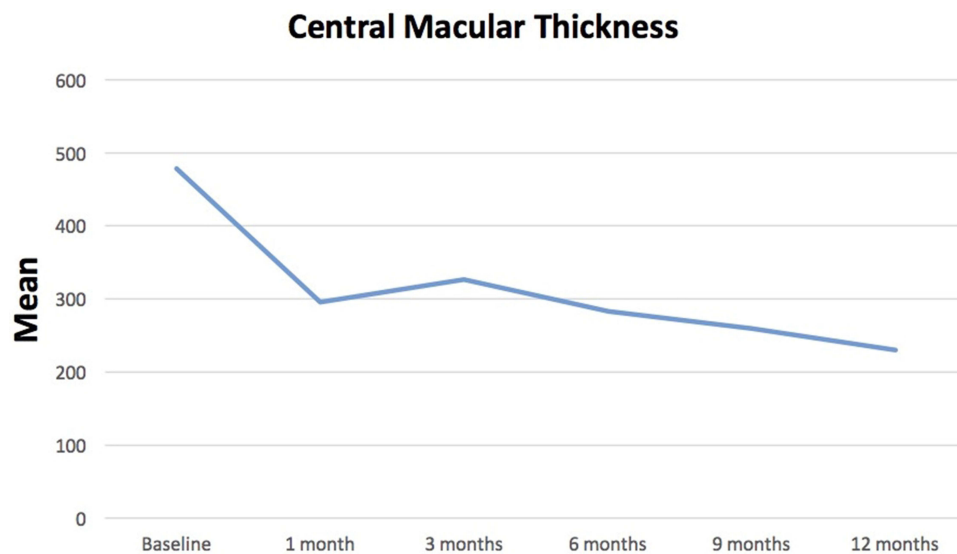


Figure 1 Central macular thickness at baseline, 1, 3, 6, 9, and 12 months.

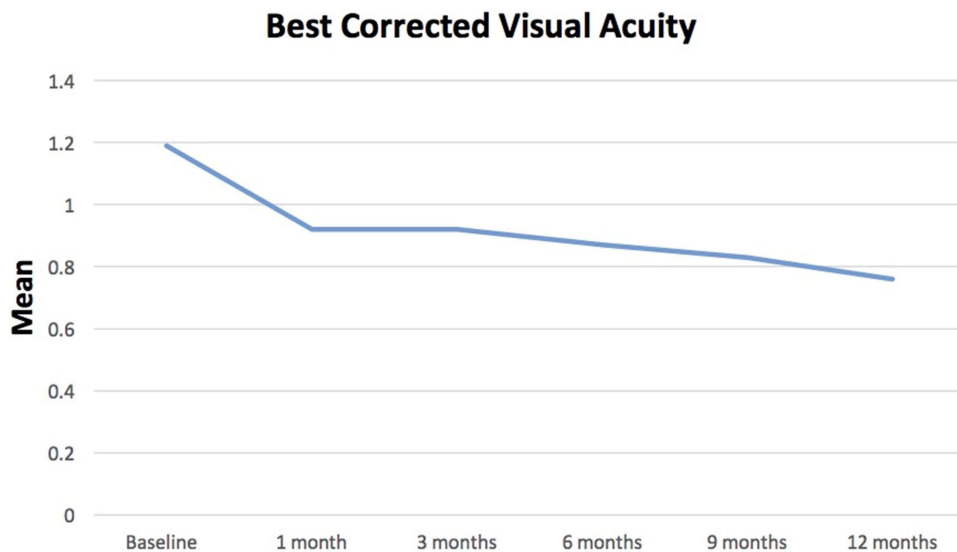


Figure 2 BCVA by logMAR at baseline, 1, 3, 6, 9, and 12 months.

Cataract progression occurred in five eyes (9.1%) that required phacoemulsification at the end of the study, these eyes were excluded from the study. No cases of uveitis, endophthalmitis, retinal detachment or vitreous hemorrhage were detected. No systemic adverse effects were reported during the duration of the study.

Figure 3 is an example of a male patient, aged 53 years old who presented with left centrally involving DME. (A): Baseline OCT after three consecutive intravitreal ranibizumab injections, the CMT is 433 μm , the BCVA is 1.2 by logMAR. (B) OCT after one month of suprachoroidal injection of TAAC, the CMT is 182 μm , the BCVA improved to 0.4 by logMAR. (C) OCT three months after suprachoroidal injection of TAAC, the CMT is 224 μm , the BCVA is 0.4 by logMAR. (D) OCT six months after suprachoroidal injection of TAAC shows recurrent macular edema, the CMT is 347 μm , the BCVA is 0.9 by logMAR, at this point the patient received the second suprachoroidal injection (E) OCT 3 months after the second injection, the CMT is 194 μm , the BCVA improved to 0.4 by logMAR. (F) OCT at the end of the follow up period (after 12 months of the first injection), the CMT is 199 μm , the BCVA is 0.3 by logMAR.

Table 2 Comparison of CMT, BCVA and IOP Changes Over the Study Period

Parameters	Mean \pm SD	p-value
	N=55 Eyes	
CMT (um)		
Baseline	478.7 \pm 170.2	<0.001
1 month	295.9 \pm 108.9 ^a	
3 months	326.5 \pm 136.4 ^a	
6 months	283.5 \pm 111.7 ^a	
9 months	259.6 \pm 103.7 ^{a,c}	
12 months	230.2 \pm 47.4 ^{a,b,c,d}	
BCVA (logMAR)		
Baseline	1.193 \pm 0.2	<0.001
1 month	0.92 \pm 0.2 ^a	
3 months	0.92 \pm 0.3 ^a	
6 months	0.87 \pm 0.3 ^a	
9 months	0.83 \pm 0.3 ^{a,b,c}	
12 months	0.76 \pm 0.3 ^{a,b,c,d}	
IOP changes (mmHg)		
Baseline	12.31 \pm 0.2	<0.001
1 month	13.3 \pm 0.5 ^a	
3 months	12.28 \pm 0.2 ^b	
6 months	12.34 \pm 0.3 ^b	
9 months	12.31 \pm 0.2 ^b	
12 months	12.14 \pm 0.3 ^{a,b,c,e}	

Notes: ^aStatistically significant compared to baseline value.

^bStatistically significant compared to values at 1 month. ^cStatistically significant compared to values at 3 months. ^dStatistically significant compared to values at 6 months. ^eStatistically significant compared to values at 9 months.

Abbreviations: CMT, central macular thickness; BCVA, best corrected visual acuity; IOP, intraocular pressure.

Discussion

Nowadays, anti-VEGF agents are the main treatment strategy and the standard of care method for DME management. However, the high cost and the need for large numbers of injections remained the main obstacle for their use, this mandates enrollment of other agents like steroids with long-lasting efficacy and fewer injections in DME management protocols. According to previous studies, a single patient with DME needed from 9–11 injections in the first year and nearly 17 injections over five years.^{12,13} Regarding the RESTORE study, the cost of ranibizumab is increasing by £4191 for 0.17 quality adjusted life year (QALY) and may reach £24,028 after 15 years,¹² this necessitates the need for cheaper methods of DME management.

Table 3 Relation of Sociodemographic and Clinical Variables with Final CMT and Final BCVA

Variables	Final CMT		Final BCVA	
	R	p-value	R	p-value
HbA1c	−0.1	0.3	−0.06	0.7
Duration of DM	−0.1	0.4	0.2	0.1
Number of injections	0.6	<0.001*	0.2	0.2
Age	−0.07	0.6	0.2	0.08
Baseline CMT	0.2	0.08	0.6	<0.001*
Baseline BCVA	0.2	0.1	0.8	<0.001*
	Mean ±SD	p-value	Mean ±SD	p-value
IS/OS disruption				
Absent	229.3±34.2	0.9	0.53±0.2	<0.001*
Present	231.2±59.4		1.02±0.2	
NSD				
Absent	222.1±31.6	0.08	0.66±0.3	0.001*
Present	245.6±66.4		0.96±0.3	

Note: *Significant.

Abbreviations: HbA1c, glycosylated hemoglobin; DM, diabetes mellitus; IS/OS, inner segment/outer segment; CMT, central macular thickness; BCVA, best corrected visual acuity; NSD, neurosensory detachment.

Table 4 Multivariable Linear Regression Analysis of Independent Predictors of Final BCVA

Variables ^a	Final BCVA	
	B	p-value
IS/OS disruption	0.3	<0.001*
NSD	0.1	0.01*
Baseline BCVA	0.6	<0.001*
Constant	−0.1	
Model F	51.6	
Model R2	0.72	
p-value	<0.001	

Notes: *Significant β; regression coefficient p-value ≤0.05 is considered statistically significant. ^aCategorical variables were entered in the model as dummy variables. They are coded as: 0 for absent IS/OS disruption and absent NSD and 1 for the presence of IS/OS disruption and NSD.

Abbreviations: IS/OS, inner segment/outer segment; NSD, neurosensory detachment; BCVA, best corrected visual acuity.

Suprachoroidal injection of triamcinolone acetonide (SCTA) is a novel method for DME treatment. SCTA can achieve a higher concentration of TA in the posterior segment about 10 times greater than the anterior segment of the eye,¹¹ thus minimizing the IOP elevation and cataract progression that can be induced by intravitreal injection of TA,¹² this necessitated the need for designing such a cheap modified microneedle for suprachoroidal injection in our study.

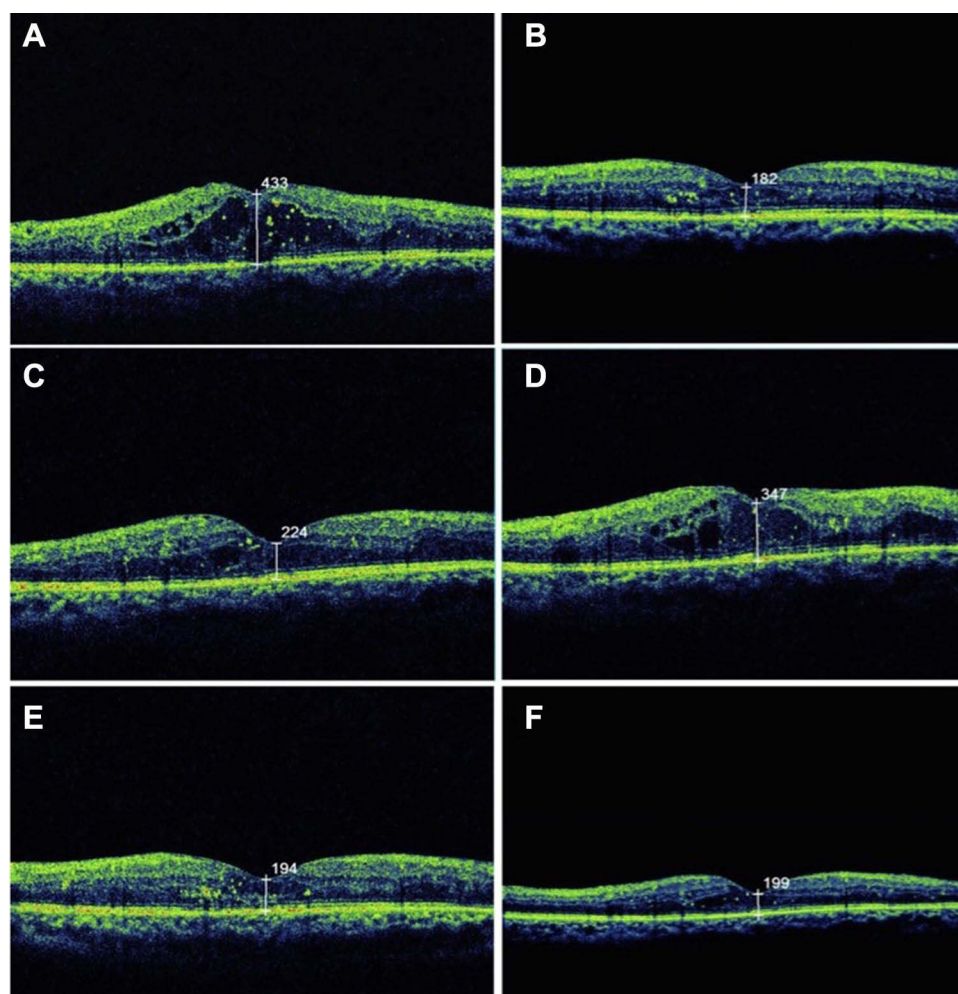


Figure 3 Male patient, aged 53 years old presented with left centrally involving DME. **(A)** Baseline OCT after three consecutive intravitreal ranibizumab injections, the CMT is 433 μm , the BCVA is 1.2 by logMAR. **(B)** OCT after one month of suprachoroidal injection of TAAC, the CMT is 182 μm , the BCVA improved to 0.4 by logMAR. **(C)** OCT 3 months after suprachoroidal injection of TAAC, the CMT is 224 μm , the BCVA is 0.4 by logMAR. **(D)** OCT six months after suprachoroidal injection of TAAC shows recurrent macular edema, the CMT is 347 μm , the BCVA is 0.9 by logMAR, at this point the patient received the second suprachoroidal injection **(E)** OCT three months after the second injection, the CMT is 194 μm , the BCVA improved to 0.4 by logMAR. **(F)** OCT at the end of the follow-up period (12 months after the first injection), the CMT is 199 μm , the BCVA is 0.3 by logMAR.

Marashi and Zazo used a new microneedle for suprachoroidal injection of TA in a case of pseudophakic cystoid macular edema with marked improvement of BCVA. In this microneedle, a rubber stopper was applied to a 30-gauge needle to allow only 1 mm of the needle to penetrate the sclera.¹⁴ Furthermore, Oli and Waikar used a similar technique to the present study for suprachoroidal injection of triamcinolone acetonide using a 26-G needle and sleeve of intracath with marked BCVA improvement and CMT reduction with no elevation of IOP.¹⁵

The present study reported a significant reduction of the CMT and a significant improvement of BCVA after 12 months of SCTA confirming good anatomical and functional results of SCTA in resistant DME cases, this is quite similar to a recent study (HULK Trial; N=20) that assessed the efficacy of SCTA in naïve and previously treated DME patients. In the HULK trial, the mean number of injections prior to SCTA was 21.6. CMT in the previously treated arm of the HULK trial improved from 473 μm at the baseline to 369 μm after six months. The BCVA increased by seven letters after SCTA and continued to improve over a period of six months. In contrast to the present study, HULK included both primary and previously treated patients while our study was performed only on previously injected cases with anti-VEGF agents. Furthermore, the HULK study combined the first injection with aflibercept, but in our cohort, only SCTA injection was performed.^{16,17}

In agreement with our study, Tayyab et al evaluated SCTA in resistant DME, the authors detected improvement of the mean CMT from $(636.5 \pm 200.11 \mu\text{m})$ to $(304.54 \pm 67.43$ and $302.66 \pm 66.93 \mu\text{m})$ after one and three months, respectively with p -value < 0.00001 . The mean BCVA improved from 0.8 ± 0.24 on the ETDRS chart to 0.47 ± 0.3 and 0.45 ± 0.27 after one and three months, respectively with p -value < 0.05 . This study differs from ours in that the follow-up duration was only three months, while in our study, the followup was extended to 12 months.¹⁸

In our cohort, recurrent edema that required second injection was mostly reported in the third month and in 60% of the eyes that needed two injections, the effect of the second injection at the third month was maintained until the end of the study, this does not agree with other studies performed on dexamethasone implants in which the effect of the steroid persisted only for six months.^{19,20}

In our study, The IOP reached its maximum value one month after injection (increased from 12.31 ± 0.2 mmHg before injection to 13.3 ± 0.5 mmHg after one month) and gradually declined until it reached its baseline value at the third month with topical beta blocker eye drops, this is not in line with another study in which IOP was elevated in one patient from 19 to 24 mmHg after one month then declined to 16 mmHg after three months with topical anti-glaucoma eye drops.¹⁸ In contrast to our cohort, Goldstein et al detected no rise in IOP after SCTA.²¹

Our study confirmed the safety of SCTA regarding IOP. In contrast, other studies performed on dexamethasone implant in posterior uveitis and retinal vein occlusion patients reported IOP elevation in 25% of cases which occurred about eight weeks postinjection.²² Similarly, another study performed on intravitreal injection of TA in patients with macular edema associated with uveitis detected a 10 mmHg rise in IOP in 43% of cases,²³ this proves the superiority of SCTA over dexamethasone implant and intravitreal TA regarding safety on IOP.

In the present study, there is a strong positive correlation between the baseline CMT and the final BCVA, so eyes with more baseline CMT achieved worse final BCVA, this is in line with another study done by Markan et al which detected that macular edema can overcome the stretching capability of the retina with subsequent damage of the bipolar axons and visual loss.²⁴

According to the present study, both NSD, IS/OS disruption and baseline BCVA were significant predictors of the final BCVA. Eyes with NSD showed worse final BCVA, this is coincident with another study that reported significant macular function impairment and diminished retinal sensitivity with NSD.²⁵ In contrast, many studies reported better visual outcomes after one year in cases with NSD and assumed a protective effect for the subretinal fluid even in cases the needed pars plana vitrectomy for diffuse macular edema.²⁶ Moreover, it was also reported in other studies that the presence of NSD at baseline was associated with better visual gain after intravitreal aflibercept²⁷ and dexamethasone implants.²⁸ Eyes with disrupted IS/OS showed worse outcomes regarding final BCVA, this agrees with Zur et al who concluded that eyes with intact IS/OS junctions have better final BCVA following dexamethasone implant injection,²⁹ also, Ota et al reported that better visual acuity was dependent on the integrity of the external limiting membrane (ELM) and the IS/OS junction.³⁰ In addition, the present study stated that eyes with poor baseline BCVA showed poor final visual acuity, similarly, Channa et al revealed that poor baseline BCVA predicted worse final visual acuity.³¹ Furthermore, both Eski Yucel et al and Sophie et al reported that poor baseline BCVA, disrupted IS/OS segment were predictors of poor final visual outcomes.^{32,33} On the contrary, Choovuthayakorn et al detected significant VA improvement in eyes with poor baseline visual acuity which can be explained by the floor effect (more gap for visual gain in eyes with poor visual acuity at the baseline).³⁴

Cataract progression is a well known adverse event that occurs with intravitreal steroids.^{35,36} Haller et al reported increased cataract progression after intravitreal dexamethasone implant.³⁷ According to our study, significant cataract progression occurred in five eyes (9.1%) that required phacoemulsification at the end of the study, other studies reported 2.0 to 58.8% incidence of cataract progression after intravitreal dexamethasone implant.^{38–41}

Small sample size, short duration of follow-up and absence of control group are the main limitations of the study and hence a larger number of patients with longer duration of follow-up is recommended for further evaluation of the effectiveness of suprachoroidal delivery of TA by this novel inexpensive modified microneedle in resistant DME cases.

Conclusions

Suprachoroidal injection of TA using this modified microneedle resulted in a significant improvement of BCVA and reduction of CMT 12 months after injection in DME cases resistant to prior anti-VEGF agents with less number of

injections needed per year if compared to intravitreal injection of anti-VEGF with no reported serious ocular or systemic side effects. The IS/OS disruption, presence of NSD and the baseline BCVA were the main predictors of the final BCVA. The author recommends the use of this novel inexpensive microneedle designed for suprachoroidal injection of TA in these cases to reduce the financial burden of anti-VEGF injection in DME cases.

Data Sharing Statement

All participants' data including figures, video of the surgical technique and clinical data are available from the corresponding author on reasonable request.

Ethical Approval and Consent to Participate

The study was approved by the Institutional Review Board of the Faculty of Medicine, Tanta University, Egypt (approval code 34328/12/20). All procedures were carried out under the tenets of the 1964 Declaration of Helsinki. Written informed consent was obtained from all participants. The study was prospectively registered with clinical trial.gov ID (NCT04690608) on December 27, 2020.

Acknowledgment

The author would like to acknowledge all staff members of Ophthalmology Department, Tanta University, Egypt, for their great support and help.

Funding

No funding was received in this study.

Disclosure

The author reports no relevant financial or nonfinancial conflicts of interest in relation to this work to disclose.

References

- Blinder KJ, Dugel PU, Chen S, et al. Anti-VEGF treatment of diabetic macular edema in clinical practice: effectiveness and patterns of use (ECHO Study Report 1). *Clin Ophthalmol*. 2017;11:393–401. doi:10.2147/OPTH.S128509
- Schmidt-Erfurth U, Garcia-Armi J, Bandello F, et al. Guidelines for the management of diabetic macular edema by the european society of retina specialists (EURETINA). *Ophthalmologica*. 2017;237(4):185–222. doi:10.1159/000458539
- He Y, Ren XJ, Hu BJ, Lam WC, Li XR. A meta-analysis of the effect of a dexamethasone intravitreal implant versus intravitreal anti-vascular endothelial growth factor treatment for diabetic macular edema. *BMC Ophthalmol*. 2018;18(1):121. doi:10.1186/s12886-018-0779-1
- Nozik RA. Periocular injection of steroids. Transactions-american academy of ophthalmology and otolaryngology. *Am Acad Ophthalmol Otolaryngol*. 1972;76(3):695–705.
- Munk MR, Bolz M, Huf W, et al. Morphologic and functional evaluations during development, resolution, and relapse of uveitis-associated cystoid macular edema. *Retina*. 2013;33(8):1673–1683. doi:10.1097/IAE.0b013e318285cc52
- Villegas VM, Schwartz SG. Current and future pharmacologic therapies for diabetic retinopathy. *Curr Pharm Des*. 2018;24(41):4903–4910. doi:10.2174/1381612825666190130140717
- Urbancic M, Gardasevic Topcic I. Dexamethasone implant in the management of diabetic macular edema from clinician's perspective. *Clin Ophthalmol*. 2019;13:829–840. doi:10.2147/OPTH.S206769
- Edelhauser HF, Verhoeven RS, Burke B, Struble CB, Patel SR. Intraocular distribution and targeting of triamcinolone acetonide suspension administered into the suprachoroidal space. *Invest Ophthalmol Vis Sci*. 2014;55(13):5259.
- Campochiaro PA, Wyckoff CC, Brown DM, et al. Suprachoroidal triamcinolone acetonide for retinal vein occlusion: results of the tanzanite study. *Ophthalmol Retina*. 2018;2(4):320–328. doi:10.1016/j.oret.2017.07.013
- Gilger BC, Abarca EM, Salmon JH, Patel S. Treatment of acute posterior uveitis in a porcine model by injection of triamcinolone acetonide into the suprachoroidal space using microneedles. *Invest Ophthalmol Vis Sci*. 2013;54(4):2483–2492. doi:10.1167/iiov.13-11747
- Yeh S, Kurup SK, Wang RC, et al. Suprachoroidal injection of triamcinolone acetonide, CLS-TA, for macular edema due to noninfectious uveitis: a randomized, Phase 2 study (DOGWOOD). *Retina*. 2019;39(10):1880–1888. doi:10.1097/IAE.0000000000002279
- Ghoraba HH, Leila M, Elgouhary SM, et al. Safety of high- dose intravitreal triamcinolone acetonide as low- cost alternative to anti-vascular endothelial growth factor agents in lower-middle-income countries. *Clin Ophthalmol*. 2018;12:2383–2391.
- Elman MJ, Ayala A, Bressler NM, et al. Diabetic Retinopathy Clinical Research Network. Intravitreal Ranibizumab for diabetic macular edema with prompt versus deferred laser treatment: 5-year randomized trial results. *Ophthalmology*. 2015;122(2):375–381. doi:10.1016/j.ophtha.2014.08.047
- Marashi A, Zazo A. A manually made needle for treating Pseudophakic cystoid macular edema by injecting triamcinolone acetonide in the suprachoroidal space: a case report. *Am J Ophthalmol Case Rep*. 2022;25:101254. doi:10.1016/j.ajoc.2021.101254
- Oli A, Waikar S. Modified inexpensive needle for suprachoroidal triamcinolone acetonide injections in pseudophakic cystoid macular edema. *Indian J Ophthalmol*. 2021;69(3):765. doi:10.4103/ijo.IJO_1464_20

16. Lampen SIR, Khurana RN, Noronha G, Brown DM, Wykoff CC. Suprachoroidal space alterations following delivery of triamcinolone acetonide: post-hoc analysis of the Phase 1/2 HULK study of patients with diabetic macular edema. *Ophthalmic Surg Lasers Imaging Retina*. 2018;49(9):692–697. doi:10.3928/23258160-20180831-07
17. Wykoff CC, Khurana RN, Lampen SIR, et al. Suprachoroidal triamcinolone acetonide for diabetic macular edema: the HULK trial. *Ophthalmol Retina*. 2018;2(8):874–877. doi:10.1016/j.oret.2018.03.008
18. Tayyab H, Ahmed CN, Sadiq MAA. Efficacy and safety of suprachoroidal triamcinolone acetonide in cases of resistant diabetic macular edema. *Pak J Med Sci*. 2020;36(2):42. doi:10.12669/pjms.36.2.1194
19. Haghjoui N, Soheilian M, Abdekhoodaie MJ. Sustained release intraocular drug delivery devices for treatment of uveitis. *J Ophthalmic Vis Res*. 2011;6(4):317.
20. Chang-Lin JE, Attar M, Acheampong AA, et al. Pharmacokinetics and pharmacodynamics of a sustained-release dexamethasone intravitreal implant. *Invest Ophthalmol Vis Sci*. 2011;52(1):80–86. doi:10.1167/iops.10-5285
21. Goldstein DA, Do D, Noronha G, Kissner JM, Srivastava SK, Nguyen QD. Suprachoroidal corticosteroid administration: a novel route for local treatment of noninfectious uveitis. *Transl Vis Sci Technol*. 2016;5(6):14. doi:10.1167/tvst.5.6.14
22. Ozurdex (dexamethasone intravitreal implant), prescribing information. Allergan, Irvine, CA, USA; 2014.
23. Kok H, Lau C, Maycock N, McCluskey P, Lightman S. Outcome of intravitreal triamcinolone in uveitis. *Ophthalmology*. 2005;112(11):1–7. doi:10.1016/j.ophtha.2005.06.009
24. Markan A, Agarwal A, Arora A, Bazgain K, Rana V, Gupta V. Novel imaging biomarkers in diabetic retinopathy and diabetic macular edema. *Ther Adv Ophthalmol*. 2020;12. doi:10.1177/2515841420950513
25. Vujosevic S, Torresin T, Berton M, Bini S, Convento E, Midena E. Diabetic macular edema with and without subfoveal neuroretinal detachment: two different morphologic and functional entities. *Am J Ophthalmol*. 2017;181:149–155. doi:10.1016/j.ajo.2017.06.026
26. Suci VI, Suci VI, Nicoara SD. Optical coherence tomography (angiography) biomarkers in the assessment and monitoring of diabetic macular edema. *J Diabetes Res*. 2020;2020:1–10. doi:10.1155/2020/6655021
27. Korobelnik JF, Lu C, Katz TA, et al. Effect of baseline subretinal fluid on treatment outcomes in VIVID-DME and Vista-DME studies. *Ophthalmol Retina*. 2019;3(8):663–669. doi:10.1016/j.oret.2019.03.015
28. Moon BG, Lee JY, Yu HG, et al. Efficacy and safety of a dexamethasone implant in patients with diabetic macular edema at tertiary centers in Korea. *J Ophthalmol*. 2016;2016:1–9. doi:10.1155/2016/9810270
29. Zur D, Iglicki M, Busch C, et al. OCT biomarkers as functional outcome predictors in diabetic macular edema treated with dexamethasone implant. *Ophthalmology*. 2018;125(2):267–275. doi:10.1016/j.ophtha.2017.08.031
30. Ota M, Nishijima K, Sakamoto A, et al. Optical coherence tomographic evaluation of foveal hard exudates in patients with diabetic maculopathy accompanying macular detachment. *Ophthalmology*. 2010;117(10):1996–2002. doi:10.1016/j.ophtha.2010.06.019
31. Channa R, Sophie R, Khwaja AA, et al. Factors affecting visual outcomes in patients with diabetic macular edema treated with ranibizumab. *Eye*. 2014;28(3):269–278. doi:10.1038/eye.2013.245
32. Eski Yucel O, Birinci H, Sullu Y. Outcome and predictors for 2-year visual acuity in eyes with diabetic macular edema treated with Ranibizumab. *J Ocul Pharmacol Ther*. 2019;35(4):229–234. doi:10.1089/jop.2018.0082
33. Sophie R, Lu N, Campochiaro PA. Predictors of functional and anatomic outcomes in patients with diabetic macular edema treated with Ranibizumab. *Ophthalmology*. 2015;122(7):1395–1401. doi:10.1016/j.ophtha.2015.02.036
34. Choovuthayakorn J, Tantraworasin A, Phinyo P, et al. Factors associated with 1-year visual response following intravitreal bevacizumab treatment for diabetic macular edema: a retrospective single center study. *Int J Retina Vitre*. 2021;7(1):1–10. doi:10.1186/s40942-021-00286-9
35. Jonas JB. Intravitreal triamcinolone acetonide: a change in a paradigm. *Ophthalmic Res*. 2006;38(4):218–245. doi:10.1159/000093796
36. Petersen A, Carlsson T, Karlsson JO, Jonhede S, Zetterberg M. Effects of dexamethasone on human lens epithelial cells in culture. *Mol Vis*. 2008;14:1344–1352.
37. Haller JA, Bandello F, Belfort JR, et al. Dexamethasone intravitreal implant in patients with macular edema related to branch or central retinal vein occlusion: twelve-month study results. *Ophthalmology*. 2011;118(12):2453–2460. doi:10.1016/j.ophtha.2011.05.014
38. Moisseiev E, Goldstein M, Waisbourd M, Barak A, Lowenstein A. Long-term evaluation of patients treated with dexamethasone intravitreal implant for macular edema due to retinal vein occlusion. *Eye*. 2013;27:65–71. doi:10.1038/eye.2012.226
39. Joshi L, Yaganti S, Gemenetzi M, et al. Dexamethasone implants in retinal vein occlusion: 12-month clinical effectiveness using repeat injections as-needed. *Br J Ophthalmol*. 2013;97(8):1040–1044. doi:10.1136/bjophthalmol-2013-303207
40. Querques L, Querques G, Lattanzio R, et al. Repeated intravitreal dexamethasone implant (Ozurdex®) for retinal vein occlusion. *Ophthalmologica*. 2013;229(1):21–25. doi:10.1159/000342160
41. Coscas G, Augustin A, Bandello F, et al. Retreatment with Ozurdex for macular edema secondary to retinal vein occlusion. *Eur J Ophthalmol*. 2014;24(1):1–9. doi:10.5301/ejo.5000376

Clinical Ophthalmology

Dovepress

Publish your work in this journal

Clinical Ophthalmology is an international, peer-reviewed journal covering all subspecialties within ophthalmology. Key topics include: Optometry; Visual science; Pharmacology and drug therapy in eye diseases; Basic Sciences; Primary and Secondary eye care; Patient Safety and Quality of Care Improvements. This journal is indexed on PubMed Central and CAS, and is the official journal of The Society of Clinical Ophthalmology (SCO). The manuscript management system is completely online and includes a very quick and fair peer-review system, which is all easy to use. Visit <http://www.dovepress.com/testimonials.php> to read real quotes from published authors.

Submit your manuscript here: <https://www.dovepress.com/clinical-ophthalmology-journal>