

# Neoadjuvant Radiation Therapy with Interdigitated High-Dose LRT for Voluminous High-Grade Soft-Tissue Sarcoma

Georges F Hatoum<sup>1,\*</sup>, H Thomas Temple<sup>2,\*</sup>, Silvio A Garcia<sup>1</sup>, Yi Zheng<sup>1,3</sup>, Fouad Kfoury<sup>4</sup>, Jill Kinley<sup>5</sup>, Xiaodong Wu<sup>1,3</sup>

<sup>1</sup>Department of Radiation Oncology, HCA Florida JFK Medical Center Comprehensive Cancer Institute, Lake Worth, FL, USA; <sup>2</sup>Department of Orthopedic Surgery, University of Miami Miller School of Medicine, Miami, FL, USA; <sup>3</sup>Department of Research and Development, Executive Medical Physics Associates, North Miami Beach, FL, USA; <sup>4</sup>Pharmacy Department, South Miami Hospital, South Miami, FL, USA; <sup>5</sup>Department of Clinical Research, HCA Florida JFK Medical Center, Atlantis, FL, USA

\*These authors contributed equally to this work

Correspondence: Xiaodong Wu, Executive Medical Physics Associates, 19470 NE 22nd Road, North Miami Beach, FL, 33179, USA, Tel +1 305 775 0333, Email [drxiaodongwu@yahoo.com](mailto:drxiaodongwu@yahoo.com)

**Purpose:** To report a case of large extremity soft tissue sarcoma (2933 cc), safely treated with a novel approach of interdigitating high-dose LATTICE radiation therapy (LRT) with standard radiation therapy as a neoadjuvant treatment to surgery.

**Patients and Methods:** Four sessions of high-dose LRT were delivered in a weekly interval, interdigitated with standard radiation therapy. The LRT plan consisted of 15 high-dose vertices receiving a dose >12 Gy per session, with 2–3 Gy to the peripheral margin of the tumor. The patient underwent surgical excision 2 months after the new regimen of induction radiation therapy.

**Results and Discussion:** The patient tolerated the radiation therapy regimen well. The post-operative assessment revealed a negative surgical margin and over 95% necrosis of the total tumor volume. The post-surgical wound complication was mitigated by outpatient wound care. Interdigitating multiple sessions of high-dose LATTICE radiation treatments with standard neoadjuvant radiation therapy as a neoadjuvant therapy for soft tissue sarcoma was feasible and did not incur additional toxicity in this clinical case. A phase-I/II trial will be conducted to further evaluate the toxicity and efficacy of the new treatment strategy with the intent to increase the rate of pathologic necrosis, which has been shown to positively correlate with the overall survival.

**Keywords:** sarcoma, SFRT, LATTICE radiotherapy, LRT, chemotherapy, surgery, necrosis

## Introduction

Soft Tissue Sarcomas (STS) are a heterogeneous group of tumors with varying clinical and pathologic characteristics. They collectively account for less than 1% of all adult malignancies and 15% of pediatric malignancies.<sup>1–3</sup> The tumor volumes are often large at the time of diagnosis, with extremities being the primary locations and abdomen the secondary.<sup>4,5</sup>

The therapeutic strategies of treating extremities STS are aimed at maximizing local tumor control and improving survival while preserving and maximizing limb function. Over the years, cumulated data from a wide range of clinical studies has firmly established the role of radiation therapy (RT) in the treatment management of STS, in either neoadjuvant or adjuvant setting to limb-sparing surgery, especially for the group of patients with large high-grade tumors,<sup>6–27</sup> although the optimal radiation-surgery sequence in terms of oncologic outcomes has not yet been rigorously defined.

From the cumulated clinical data, the National Comprehensive Cancer Network (NCCN) guidelines recommend either preoperative or postoperative RT for large (>5 cm) high-grade STS, but surgery with wide margins alone can be considered for smaller lower-grade tumors. The typical preoperative external beam RT (EBRT) dose has been 50 Gy in 1.8 to 2.0 Gy per fraction. Based on the individualized toxicity evaluation, RT boost might be used for patients with positive surgical margins.<sup>1</sup>

As technologies in radiation therapy have evolved and improved, intensity modulated radiation therapy (IMRT) with image guidance (IGRT) has become the preferred choice of EBRT, due to its capacity to reduce toxicity.<sup>28</sup>

The currently established margins of CTV (clinical target volume) for intermediate- to high-grade tumors are 3 to 4 cm beyond the GTV in the longitudinal (proximal and distal) directions, and 1.5 cm beyond the GTV in the radial directions, excluding uninvolved anatomic barriers to tumor spread (such as bone), and including peritumoral edema. An additional 5 mm of margins are added to CTV to form PTV (planning target volume), if image-guided IMRT techniques are used.<sup>29,30</sup>

Although surgery with radiotherapy can offer a cure for patients with primary soft tissue sarcomas, when nearly half of patients recur, the prognosis is poor, with an estimated median survival of 12 to 15 months, and with only palliative treatment options available.<sup>31</sup> This trend becomes progressively more critical for larger (>5cm) and high-grade tumors. Despite the consistent efforts of further improving treatment outcome of primary STS, the rarity of the disease inevitably resulted in the comparatively few novel therapeutic breakthroughs. The implementation of IMRT and IGRT, although associated with lower toxicity, has not demonstrated improvement in disease control and survival.<sup>30</sup> The strategy of adding chemotherapy to the neoadjuvant schedule also has not shown consistent advantages, while imposing additional chemotherapy-related toxicities.<sup>27,32–36</sup> In recent years the developments in sarcoma treatment have been principally focused on cytotoxic, targeted, epigenetic, and immune therapy agents, with inconsistent clinical outcomes.<sup>37</sup>

As the battle against STS continues, clinicians and researchers are looking at indications and directions from which new advances may bring about better clinical outcomes. One such particular indicator is the rate of pathologic necrosis induced by neoadjuvant therapies. Eilber et al first reported improved outcomes associated with near-complete necrosis rates.<sup>38</sup> The 5- and 10-year local recurrence rates for patients with >95% pathologic necrosis were 6% and 11%, respectively compared to 17% and 23% for patients with less than 95% pathologic necrosis. The 5- and 10-year survival rates for the patients with >95% pathologic necrosis were 80% and 71%, respectively compared to 62% and 55% for the patients with less than 95% pathologic necrosis. MacDermid et al further reported similar results, showing a significant association between FFDM (freedom from distant metastasis) and treatment-induced necrosis; FFDM was 84.6% in those with  $\geq 90\%$  treatment-induced tumor necrosis vs 19.9% ( $p = 0.02$ ), compared to those with less necrosis.<sup>39</sup> More recent studies, RTOG 9514 and 0630 trials<sup>27</sup> and a retrospective international multicenter study<sup>40</sup> reported statistically significant positive correlation between high rate of neoadjuvant treatment-induced tumor necrosis and the overall survival.

Unfortunately, even with aggressive neoadjuvant therapeutic schedules such as chemo-radiotherapy, pathologic necrosis indices are generally low. MacDermid et al reported 50% of their cohort (34 patients) achieved treatment-induced tumor necrosis of  $\geq 90\%$ . Eilber et al reported 14% of their cohort (496 patients) achieved  $\geq 95\%$  treatment-induced tumor necrosis. Choong et al observed >80% necrosis in only 15 of 38 (39%) tumors following standard neoadjuvant RT.<sup>41</sup> The RTOG trials 0630 and 9514 reported 19.4% and 27.5% of patients with large high-grade STS achieved tumor necrosis of  $\geq 80\%$  respectively.<sup>27</sup> Bonvalot et al reported 22% of the 330 patients achieve tumor necrosis of  $\geq 95\%$ .<sup>40</sup>

Among the novel approaches to achieve higher rate of pathologic tumor necrosis is the addition of GRID radiotherapy to the standard RT in the neoadjuvant treatment. Snider et al reported the early results of the new strategy implemented at the University of Maryland Medical Center.<sup>42</sup> A single fraction of 15 Gy GRID therapy prescribed to Dmax (depth of maximum dose) was delivered prior to the conventionally fractionated RT of 45 to 50.4 Gy in 1.8–2.25 Gy/fraction. They reported six (35.3%) of the 17 patients with high-grade sarcoma achieved a pCR (pathologic complete response) with their regimen. They also reported a major wound complication in 34.6% of the study cohort (26 patients).

GRID radiation therapy technique was invented by Alban Köhler in 1930s to safely treat large tumors when only kV x-rays machines were available.<sup>43–46</sup> The GRID, a multi-perforated block, divides large field of radiation into an array of beam-lets with each having a diameter of about 1 cm, separated by 1–2 cm, resulting in a signature “Peak-Valley”, oscillating dose distribution.

In the modern era of megavoltage x-ray radiotherapy, GRID continued to be used for palliative treatment of bulky tumors with favorable clinical outcomes, and was coined Spatially Fractionated Radiotherapy (SFRT).<sup>47–60</sup>

The objectives and expectations of SFRT have evolved over time and can currently be categorized into three groups: 1. Delivering partial RT boost; 2. Mediating bystander/abscopal effects; 3. Combination of the first two. The objective-1 inherited the original principle of safe dose escalation with minimal toxicity by spatially segmenting the irradiated field.

The objective-2 has come from the new insights of modern radiobiology, with strong indications of underlying mechanisms including radiation-induced antitumor immunity and reperfusion, but awaiting for systemic confirmation.<sup>61–74</sup>

As a 3D extension of the technique, introduced in 2010, LATTICE radiotherapy (LRT) utilizes modern radiotherapy therapy systems and techniques such as IMRT, VMAT (Volumetric Arc Therapy), robotic convergent beams and the Bragg peaks of charged particle beams to deliver islands of high doses (vertices) within the tumor volume, with the typical peak-valley dose distribution, and avoiding high dose outside of tumor volume.<sup>75,76</sup> Keeping the essence of its 3D characteristics, LRT could be applied in various forms, from being the sole treatment, field-in-field simultaneous boost, integration with conventional RT, to having the vertices selectively placed in regions of differential biological significance.<sup>77–88</sup> Given the unique advantage of LRT over GRID in avoiding high doses to the surrounding normal tissues, it is a logical choice to use LRT for escalating boost dose further.

This report presents a clinical case of interdigitating multiple sessions of high-dose LRT with standard neoadjuvant RT for large high-grade STS, with the objective to increase pathologic necrosis without added toxicities.

## Patients and Methods

### Rational

Soft tissue sarcomas are inherently resistant to chemotherapy and relatively insensitive to radiation. To increase tumor necrosis, an aggressive amount of boost dose is needed. The early experience of using a single fraction of GRID RT as a boost to the standard RT regimen has indicated a moderate increase of treatment-induced tumor necrosis.<sup>42</sup> Further escalating the boost dose by applying more fractions of GRID RT would inevitably incur additional toxicity. Given the known advantage of LRT which could effectively limit the dose outside of tumor volume, we propose to use multiple sessions of high-dose LRT interdigitated with the standard EBRT (LRT↓EBRT) in the preoperative setting. More specifically, in the schedule of the standard EBRT, one out of every five fractions will be replaced by a LRT session, for example, delivering a session of LRT on Monday followed by 4 fractions of standard RT from Tuesday to Friday. For each LRT session, while delivering high dose ( $\geq 10$  Gy) to the vertices, the tumor periphery will be kept at or close to the standard RT fractional dose of 2.0 Gy, as such the total dose to the margin of PTV (planning target volume) stays the same as the standard induction EBRT. The primary goal of adding interdigitated multiple sessions of high-dose LRT is to achieve a higher rate of neoadjuvant treatment-induced tumor necrosis with negative surgical margins. No added toxicity will be anticipated with LRT, as high doses are exclusively enclosed within the main tumor volume.

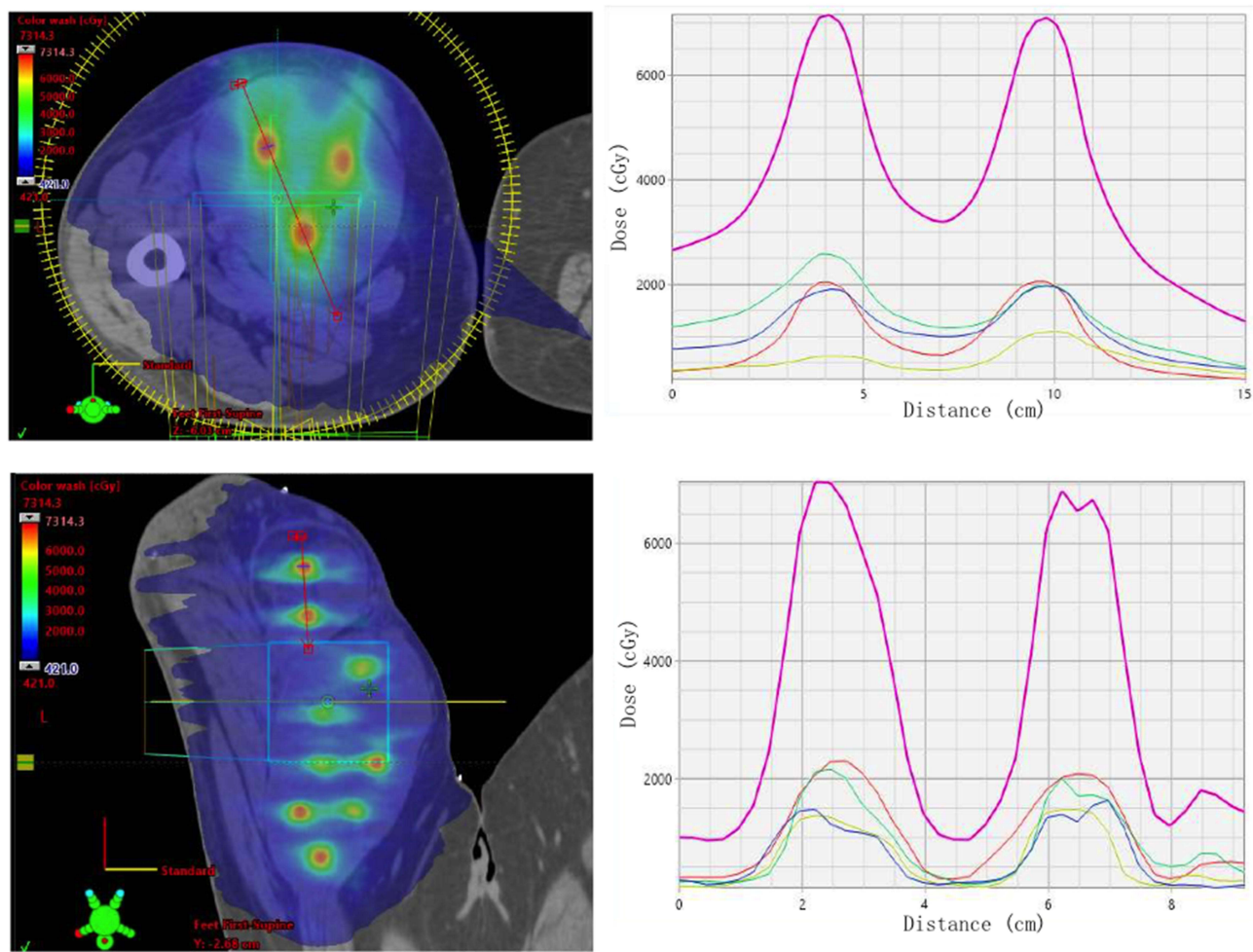
### Case Description

A 53-year-old white male was presented with a stage IIIB, (cT4N0M0, G3) high-grade liposarcoma of the medial left thigh, measuring 28×12×11 cm (2933 cc). Preoperative radiotherapy (without chemotherapy, due to the patient's refusal) followed by wide local excision was advised. If positive margins were observed, he would have been given a RT boost of 16–20 Gy in 8 to 10 fractions to the surgical bed.

Using the proposed new regimen for the preoperative RT, 50 Gy of VMAT in 2.0 Gy per fraction was planned for the PTV with 2.0 cm margin from the GTV in radial direction and 3.5 cm in superior/inferior direction, subtracting the nerves and the bones. Out of the 25 fractions of EBRT, 4 fractions were replaced by LRT. Using the methods previously described,<sup>75,76</sup> each LRT session delivered  $\geq 12$  Gy to the vertices within the tumor volume, interdigitated on a weekly basis. Eighteen vertices of 1.0–1.5 cm in diameters were created within the Lattice Volume  $V_L$  of 1370.0 cc, with an average separation (center to center) of 4.75 cm.

Four co-planar VMAT arcs were used to develop the LRT plan (Figure 1). Fifteen out of the eighteen vertices were activated by the optimization process, resulting in a total of 55.7 cc of vertices volume (1.9% of GTV) covered by 12 Gy; 17.5 cc of the vertices volume (0.6% of GTV) covered by 15 Gy; and the maximum dose to the vertices of 18.3 Gy, per session. The valley to peak dose ratio (VPDR)<sup>76</sup> of the  $V_L$  was 0.20.

The VMAT technique was also used for the standard EBRT, consisting of 4 arcs, covering the PTV with 42Gy in 2 Gy per fraction.



**Figure 1** LRT plan. Upper left: dose distribution in an axial plane. Upper right: peak-valley dose profiles defined by the red line across the two dose vertices. Lower left: dose distribution in a coronal plane. Lower right: peak-valley dose profiles defined by the red line across the two dose vertices. The dose profiles contain individual arcs (lower 4 curves) and combined-arcs (upper curve).

The patient received the whole course of radiation treatment over 36 days in 2020 with daily CBCT (cone-beam CT) guidance. The LRT↓EBRT delivering sequence is presented in [Figure 2](#).

The patient tolerated the LRT↓EBRT well, and underwent surgical excision 66 days after the completion of the neoadjuvant LRT↓EBRT.

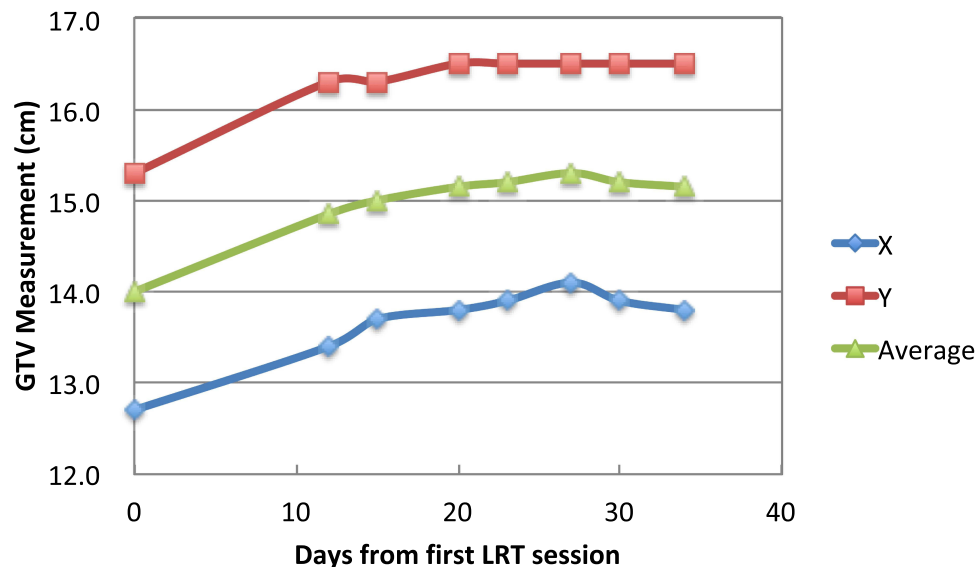
**Results**

Based on the CBCT assessment, the tumor growth was controlled three weeks after the initiation of RT ([Figure 3](#)). As the tumor size in longitudinal direction exceeded the maximum field of view of the CBCT, only the sizes in radial direction were recorded.

| RT Mode     | Treatment Fractions |   |   |   |   |   |   |   |   |    |    |    |    |    |    |  |    |    |    |    |    |    |    |    |    |
|-------------|---------------------|---|---|---|---|---|---|---|---|----|----|----|----|----|----|--|----|----|----|----|----|----|----|----|----|
| EBRT (VMAT) |                     | 2 | 3 | 4 | 5 |   | 7 | 8 | 9 | 10 |    | 12 | 13 | 14 | 15 |  | 17 | 18 | 19 | 20 | 21 | 22 | 23 | 24 | 25 |
| LRT (VMAT)  | 1                   |   |   |   |   | 6 |   |   |   |    | 11 |    |    |    | 16 |  |    |    |    |    |    |    |    |    |    |

**Figure 2** LRT↓EBRT delivery sequence.

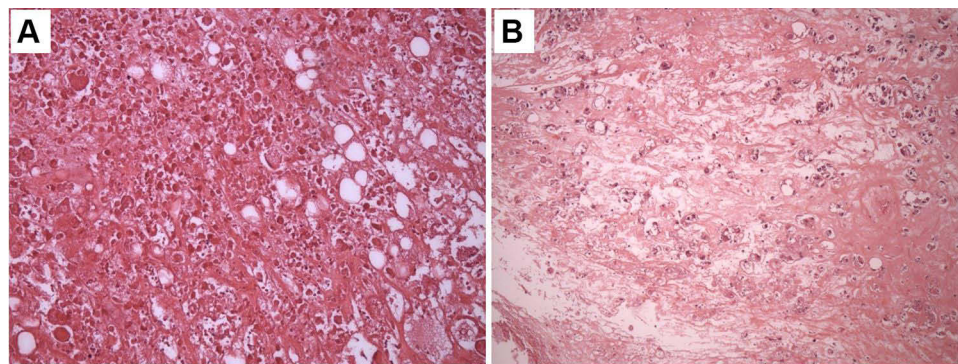




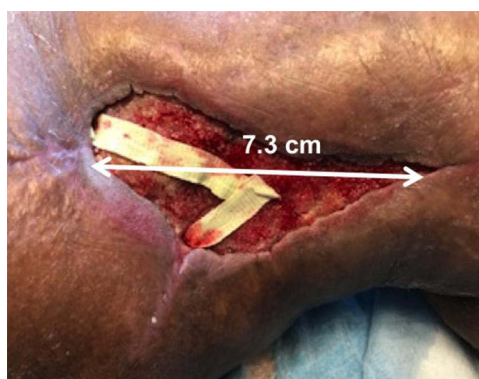**Figure 3** Tumor size changes over the course of induction RT. X: maximal lateral dimension; Y: maximal vertical dimension.

The final pathology report revealed negative surgical margins and showed a pathologic necrosis rate of over 95%. As the representative H&E histomicrographs, **Figure 4A** (200X) shows tumor ghost cells (devoid of nuclei with area demonstrating infiltrating lymphocytes); **Figure 4B** (100X) shows extensive fibrosis and tumor cells undergoing apoptosis with occasional infiltrating lymphocytes. No obvious viable tumor cells are seen in these two H&E slides. No post-operative RT was indicated, based on the NCCN guidelines.<sup>1</sup>

The patient experienced post-operative complication of wound dehiscence with abscess, and received outpatient care and aggressive wound management including negative pressure therapy in conjunction with Ciprofloxacin to treat the open wound (**Figure 5**), which had considerable drainage but improved over time and ultimately contracted and closed after two months without further operative management, flap coverage or a split thickness skin graft. Despite the size of this tumor, the toxicity did not reach the level of major wound complication, defined in the randomized trial of the National Cancer Institute of Canada (NCIC)<sup>15,17,18</sup> as a secondary operation under general or regional anesthesia for wound repair, or wound management without secondary operation, including an invasive procedure without general or regional anesthesia (mainly aspiration of seroma), readmission for wound care such as intravenous antibiotics, or persistent deep packing for 120 days or longer.



**Figure 4** H&E Histomicrographs. **(A)** (200X) shows tumor ghost cells (devoid of nuclei with area demonstrating infiltrating lymphocytes). **(B)** (100X) shows extensive fibrosis and tumor cells undergoing apoptosis with occasional infiltrating lymphocytes. No obvious viable tumor cells are seen in both H&E slides.



**Figure 5** Tumor bed two weeks post surgery.

The patient was found to have developed a large metastasis in the right lung three months after the surgery and was treated with palliative radiation therapy. The patient subsequently succumbed to progression of the disease 5 months after the surgery. No local recurrence was observed.

## Discussion

Due to the spurious and generally poor response of STS to conventional chemotherapy and radiation therapy, for patients who fail surgery with neoadjuvant therapy, the options of further treatment are limited and are mostly palliative or involving amputation for local control.<sup>1,31</sup> Reevaluating current strategies of neoadjuvant therapy and exploring new approaches to further reduce local recurrence and distant metastasis is therefore of paramount value.<sup>89</sup>

Following the evidence of direct correlation between high rate of neoadjuvant treatment-induced necrosis and FFDM (freedom from distant metastasis), in a single institution study, a single session of SFRT in the form of 2D GRID was used as a boost to the conventional EBRT.<sup>42</sup> With the moderately improved necrosis rate, a 34.6% of major wound complication (per NCIC definition) was reported. To further increase the rate of pathologic necrosis, we proposed to increase the number of SFRT sessions using high-dose LATTICE RT (LRT), interdigitated with the standard EBRT (LRT↓EBRT). With the physical advantages of LRT, no additional toxicities are anticipated.

The case presented herein demonstrated the procedural logistics, feasibility and the safety of the proposed regimen. For the tumor of this size (2933 cc, 28 cm in maximal dimension), with LRT↓EBRT alone as neo-adjuvant therapy, the result of negative surgical margin and over 95% of necrosis is an encouraging positive indication of justification.

Due to the advance of the local disease reflected by its size, the observed post-surgical complication required aggressive management, but it did not reach the level of major wound complication, and the fact that the high percentage of necrosis in this case did not prevent the distant metastasis could also be easily understood. The progression of the disease that resulted in 5 months of post-surgical survival did not allow for observation of longer term of tumor control and toxicities, although the disease was controlled locally until patient's death.

A Phase-I/II clinical trial is underway, in which, we further propose to reduce the CTV margin to 0.5 cm, leaving the task of eradicating microscopic disease to chemotherapy and/or the anticipated bystander/abscopal effects mediated by the high-dose LRT. Since LRT↓EBRT will be delivered by the conventional schedule (daily fractionation), harvesting RT-induced antitumor immunity within the main tumor volume is unlikely. However, with reduced daily dose outside of the gross tumor volume, the therapeutic effect on microscopic extension through bystander/abscopal mechanism would be logically probable. With a smaller CTV margin, the radiation-related toxicity such as dermatitis and wound complications in general could be further reduced.

Novel treatment techniques to further improve clinical outcomes of STS have been limited. SFRT has gained attention with increasing intensity in the recent years, due to its potential unconventional effects,<sup>58–60,87,88</sup> and might contribute to the advances on the long road of our endeavor to battle STS. In particular, since the benefits of adding chemotherapy to neo-adjuvant treatment has not been demonstrated consistently, the proposed LRT↓EBRT alone as induction therapy may

present a valuable alternative in achieving the similar objectives, ie, increasing pathologic necrosis rate and subsequently reducing local recurrence and distant metastasis. If proven effective, this technique could merge with the broader front of the management of STS including marginally resectable and unresectable, in which novel approaches of combining various fractionation RT schemes with other treatment modalities including hyperthermia and chemotherapy have been actively proposed and investigated.<sup>90,91</sup>

## Disclosure

1. The written informed consent has been provided by the patient's next of kin to have the case details and all accompanying images published.
2. This research was supported in part by HCA Healthcare where the clinical care of this case was provided. The approval of publication was obtained from HCA Healthcare. The views expressed in this publication represent those of the authors and do not necessarily represent the official views of HCA Healthcare or any of its affiliated entities.
3. Xiaodong Wu is the primary inventor of US Patent No. 8,395,131: Method of 3D Lattice Radiotherapy.

## References

1. National Comprehensive Cancer Network. NCCN clinical practice guidelines in oncology: soft tissue sarcoma, version 1.2022; 2022.
2. Gronchi A, Miah AB, Dei Tos AP, et al; ESMO Guidelines Committee, EURACAN and GENTURIS. Soft tissue and visceral sarcomas: ESMO-EURACAN-GENTURIS clinical practice guidelines for diagnosis, treatment and follow-up☆. *Ann Oncol*. 2021;32(11):1348–1365. PMID: 34303806. doi:10.1016/j.annonc.2021.07.006
3. Siegel RL, Miller KD, Jemal A. Cancer statistics, 2016. *CA Cancer J Clin*. 2016;66(1):7–30. doi:10.3322/caac.21332
4. Pisters PWT, Weiss M, Maki R. Soft-tissue sarcomas. In: Haller DG, Wagman LD, Camphausen C, Hoskins WJ, editors. *Cancer Management: A Multidisciplinary Approach Medical, Surgical, & Radiation Oncology*. 14 ed. UBM Medica LLC; 2011.
5. Mann GB, Lewis JJ, Brennan MF. Adult soft tissue sarcoma. *Aust N Z J Surg*. 1999;69:336–343. doi:10.1046/j.1440-1622.1999.01568.x
6. Rosenberg SA, Tepper J, Glatstein E, et al. The treatment of soft-tissue sarcomas of the extremities: prospective randomized evaluations of (1) limb-sparing surgery plus radiation therapy compared with amputation and (2) the role of adjuvant chemotherapy. *Ann Surg*. 1982;196:305–315. doi:10.1097/00000658-198209000-00009
7. Leibel SA, Tranbaugh RF, Wara WM, et al. Soft tissue sarcomas of the extremities. Survival and patterns of failure with conservative surgery and postoperative irradiation compared to surgery alone. *Cancer*. 1982;50(6):1076–1083. doi:10.1002/1097-0142(19820915)50:6<1076::AID-CNCR2820500610>3.0.CO;2-U
8. abbatucci JS, Boulter N, de Ranieri J, et al. Local control and survival in soft tissue sarcomas of the limbs, trunk walls and head and neck: a study of 113 cases. *Int J Radiat Oncol Biol Phys*. 1986;12:579–586. doi:10.1016/0360-3016(86)90066-0
9. Wilson AN, Davis A, Bell RS, et al. Local control of soft tissue sarcoma of the extremity: the experience of a multidisciplinary sarcoma group with definitive surgery and radiotherapy. *Eur J Cancer*. 1994;30A:746–751. doi:10.1016/0959-8049(94)90286-0
10. Fein DA, Lee WR, Lanciano RM, et al. Management of extremity soft tissue sarcomas with limb-sparing surgery and postoperative irradiation: do total dose, overall treatment time, and the surgery-radiotherapy interval impact on local control? *Int J Radiat Oncol Biol Phys*. 1995;32:969–976. doi:10.1016/0360-3016(95)00105-8
11. Cheng EY, Dusenbery KE, Winters MR, Thompson RC. Soft tissue sarcomas: preoperative versus postoperative radiotherapy. *J Surg Oncol*. 1996;61:90–9939.
12. Pisters PW, Harrison LB, Leung DH, et al. Long-term results of a prospective randomized trial of adjuvant brachytherapy in soft tissue sarcoma. *J Clin Oncol*. 1996;14(3):859–868. doi:10.1200/JCO.1996.14.3.859
13. Yang JC, Chang AE, Baker AR, et al. Randomized prospective study of the benefit of adjuvant radiation therapy in the treatment of soft tissue sarcomas of the extremity. *J Clin Oncol*. 1998;16:197–203. doi:10.1200/JCO.1998.16.1.197
14. Alektiar KM, Velasco J, Zelefsky MJ, et al. Adjuvant radiotherapy for margin-positive high-grade soft tissue sarcoma of the extremity. *Int J Radiat Oncol Biol Phys*. 2000;48(4):1051–1058. doi:10.1016/S0360-3016(00)00753-7
15. O'Sullivan B, Davis AM, Turcotte R, et al. Preoperative versus postoperative radiotherapy in soft-tissue sarcoma of the limbs: a randomised trial. *Lancet*. 2002;359(9325):2235–2241. doi:10.1016/S0140-6736(02)09292-9
16. Alektiar KM, Leung D, Zelefsky MJ, et al. Adjuvant brachytherapy for primary high-grade soft tissue sarcoma of the extremity. *Ann Surg Oncol*. 2002;9(1):48–56. doi:10.1245/aso.2002.9.1.48
17. O'Sullivan B, Davis A, Turcotte R, et al. Five-year results of a randomized Phase III trial of pre-operative vs post-operative radiotherapy in extremity soft tissue sarcoma [abstract]. *J Clin Oncol*. 2004;22(14\_Suppl):Abstract9007. doi:10.1200/jco.2004.22.90140.9007
18. Davis AM, O'Sullivan B, Turcotte R, et al. Late radiation morbidity following randomization to preoperative versus postoperative radiotherapy in extremity soft tissue sarcoma. *Radiother Oncol*. 2005;75(1):48–53. doi:10.1016/j.radonc.2004.12.020
19. Muhic A, Hovgaard D, Mork Petersen M, et al. Local control and survival in patients with soft tissue sarcomas treated with limb sparing surgery in combination with interstitial brachytherapy and external radiation. *Radiother Oncol*. 2008;88(3):382–387. doi:10.1016/j.radonc.2008.06.002
20. Jebsen NL, Trovik CS, Bauer HC, et al. Radiotherapy to improve local control regardless of surgical margin and malignancy grade in extremity and trunk wall soft tissue sarcoma: a Scandinavian sarcoma group study. *Int J Radiat Oncol Biol Phys*. 2008;71:1196–1203. doi:10.1016/j.ijrobp.2007.11.023
21. Alektiar KM, Brennan MF, Healey JH, Singer S. Impact of intensity-modulated radiation therapy on local control in primary soft-tissue sarcoma of the extremity. *J Clin Oncol*. 2008;26:3440–3444. doi:10.1200/JCO.2008.16.6249

22. Kim B, Chen YL, Kirsch DG, et al. An effective preoperative three-dimensional radiotherapy target volume for extremity soft tissue sarcoma and the effect of margin width on local control. *Int J Radiat Oncol Biol Phys*. 2010;77:843–850. doi:10.1016/j.ijrobp.2009.06.086
23. Koshy M, Rich SE, Mohiuddin MM. Improved survival with radiation therapy in high-grade soft tissue sarcomas of the extremities: a SEER analysis. *Int J Radiat Oncol Biol Phys*. 2010;77(1):203–209. PMID: 19679403; PMCID: PMC3812813. doi:10.1016/j.ijrobp.2009.04.051
24. Alektiar KM, Brennan MF, Singer S. Local control comparison of adjuvant brachytherapy to intensity-modulated radiotherapy in primary high-grade sarcoma of the extremity. *Cancer*. 2011;117(14):3229–3234. doi:10.1002/cncr.25882
25. Beane JD, Yang JC, White D, et al. Efficacy of adjuvant radiation therapy in the treatment of soft tissue sarcoma of the extremity: 20-year follow-up of a randomized prospective trial. *Ann Surg Oncol*. 2014;21(8):2484–2489. doi:10.1245/s10434-014-3732-4
26. Gingrich AA, Bateni SB, Monjazeb AM, et al. Neoadjuvant radiotherapy is associated with R0 resection and improved survival for patients with extremity soft tissue sarcoma undergoing surgery: a national cancer database analysis. *Ann Surg Oncol*. 2017;24(11):3252–3263. doi:10.1245/s10434-017-6019-8
27. Wang D, Harris J, Kraybill W, et al. Pathologic complete response and survival outcomes in patients with localized soft tissue sarcoma treated with neoadjuvant chemoradiotherapy or radiotherapy: long-term update of NRG oncology RTOG 9514 and 0630. *J Clin Oncol*. 2017;35:11012. doi:10.1200/JCO.2017.35.15\_suppl.11012
28. O'Sullivan B, Griffin AM, Dickie CI, et al. Phase 2 study of preoperative image-guided intensity-modulated radiation therapy to reduce wound and combined modality morbidities in lower extremity soft tissue sarcoma. *Cancer*. 2013;119(10):1878–1884. doi:10.1002/cncr.27951
29. Wang D, Bosch W, Roberge D, et al. RTOG sarcoma radiation oncologists reach consensus on gross tumor volume and clinical target volume on computed tomographic images for preoperative radiotherapy of primary soft tissue sarcoma of extremity in Radiation Therapy Oncology Group studies. *Int J Radiat Oncol Biol Phys*. 2011;81(4):e525–e528. PMCID: 3205346. doi:10.1016/j.ijrobp.2011.04.038
30. Wang D, Zhang Q, Eisenberg BL, et al. Significant reduction of late toxicities in patients with extremity sarcoma treated with image-guided radiation therapy to a reduced target volume: results of Radiation Therapy Oncology Group RTOG-0630 trial. *J Clin Oncol*. 2015;33(20):2231–2238. PMID: 25667281; PMCID: PMC4486342. doi:10.1200/JCO.2014.58.5828
31. Judson I, Verweij J, Gelderblom H, et al. Doxorubicin alone versus intensified doxorubicin plus ifosfamide for first-line treatment of advanced or metastatic soft-tissue sarcoma: a randomised controlled Phase 3 trial. *Lancet Oncol*. 2014;15:415–423. doi:10.1016/S1470-2045(14)70063-4
32. DeLaney TF, Spiro IJ, Suit HD, et al. Neoadjuvant chemotherapy and radiotherapy for large extremity soft-tissue sarcomas. *Int J Radiat Oncol Biol Phys*. 2003;56(4):1117–1127. PMID: 12829150. doi:10.1016/s0360-3016(03)00186-x
33. Kraybill WG, Harris J, Spiro IJ, et al. Long-term results of a phase 2 study of neoadjuvant chemotherapy and radiotherapy in the management of high-risk, high-grade, soft tissue sarcomas of the extremities and body wall: radiation Therapy Oncology Group Trial 9514. *Cancer*. 2010;116(19):4613–4621. PMID: 20572040; PMCID: PMC3780573. doi:10.1002/cncr.25350
34. Kraybill WG, Harris J, Spiro IJ, et al.; Radiation Therapy Oncology Group Trial 9514. Phase II study of neoadjuvant chemotherapy and radiation therapy in the management of high-risk, high-grade, soft tissue sarcomas of the extremities and body wall: radiation Therapy Oncology Group Trial 9514. *J Clin Oncol*. 2006;24(4):619–625. PMID: 16446334. doi:10.1200/JCO.2005.02.5577
35. Hazell SZ, Hu C, Alcorn SR, et al. Neoadjuvant chemoradiation compared with neoadjuvant radiation alone in the management of high-grade soft tissue extremity sarcomas. *Adv Radiat Oncol*. 2019;5(2):231–237. PMID: 32280823; PMCID: PMC7136634. doi:10.1016/j.adro.2019.08.015
36. Baldini EH, Le Cesne A, Trent JC. Neoadjuvant chemotherapy, concurrent chemoradiation, and adjuvant chemotherapy for high-risk extremity soft tissue sarcoma. *Am Soc Clin Oncol Educ Book*. 2018;38(38):910–915. PMID: 30231383. doi:10.1200/EDBK\_201421
37. Dancsok AR, Asleh-Aburaya K, Nielsen TO. Advances in sarcoma diagnostics and treatment. *Oncotarget*. 2017;8(4):7068–7093. PMID: 27732970; PMCID: PMC5351692. doi:10.18632/oncotarget.12548
38. Eilber FC, Rosen G, Eckardt J, et al. Treatment-induced pathologic necrosis: a predictor of local recurrence and survival in patients receiving neoadjuvant therapy for high-grade extremity soft tissue sarcomas. *J Clin Oncol*. 2001;19(13):3203–3209. PubMed: 11432887. doi:10.1200/JCO.2001.19.13.3203
39. MacDermed DM, Miller LL, Peabody TD, et al. Primary tumor necrosis predicts distant control in locally advanced soft-tissue sarcomas after preoperative concurrent chemoradiotherapy. *Int J Radiat Oncol Biol Phys*. 2010;76(4):1147–1153. PMID: 19577863; PMCID: PMC2931332. doi:10.1016/j.ijrobp.2009.03.015
40. Bonvalot S, Wunder J, Gronchi A, et al. Complete pathological response to neoadjuvant treatment is associated with better survival outcomes in patients with soft tissue sarcoma: results of a retrospective multicenter study. *Eur J Surg Oncol*. 2021;47(8):2166–2172. PMID: 33676792. doi:10.1016/j.ejso.2021.02.024
41. Choong PF, Nizam I, Ngan SY, et al. Thallium-201 scintigraphy--a predictor of tumour necrosis in soft tissue sarcoma following preoperative radiotherapy? *Eur J Surg Oncol*. 2003;29(10):908–915. PMID: 14624787. doi:10.1016/j.ejso.2003.09.003
42. Snider JW, Molitoris J, Shyu S, et al. Spatially Fractionated Radiotherapy (GRID) prior to standard neoadjuvant conventionally fractionated radiotherapy for bulky, high-risk soft tissue and osteosarcomas: feasibility, safety, and promising pathologic response rates. *Radiat Res*. 2020;194(6):707–714. PMID: 33064802. doi:10.1667/RADE-20-00100.1
43. Laissue JA, Blattmann H, Slatkin DN. Alban Köhler (1874–1947): Erfinder der Gittertherapie [Alban Köhler (1874–1947): inventor of grid therapy]. *Z Med Phys*. 2012;22(2):90–99. German.
44. Liberson F. The value of a multi-perforated screen in deep X-ray therapy: a preliminary report on a new method of delivering multiple erythema doses without permanent injury to the skin. *Radiology*. 1933;30(3):186–195.
45. Marks H. A new approach to the roentgen therapy of cancer with the use of a grid. *J Mt Sinai Hosp N Y*. 1950;17(1):46–48.
46. Marks H. Clinical experience with irradiation through a grid. *Radiology*. 1952;58(3):338–342. doi:10.1148/58.3.338
47. Mohiuddin M, Curtis DL, Grizos WT, Komarnicky L. Palliative treatment of advanced cancer using multiple nonconfluent pencil beam radiation. A pilot study. *Cancer*. 1990;66(1):114–118.
48. Mohiuddin M, Stevens JH, Reiff JE, Huq MS, Suntharagham N. Spatially fractionated (GRID) radiation for palliative treatment of advanced cancer. *Radiat Oncol Investig*. 1996;4:41–47. doi:10.1002/(SICI)1520-6823(1996)4:1<41::AID-ROI7>3.0.CO;2-M
49. Mohiuddin M, Fujita M, Regine WF, Megooni AS, Ibbott GS, Ahmed MM. High-dose spatially-fractionated radiation (GRID): a new paradigm in the management of advanced cancers. *Int J Radiat Oncol Biol Phys*. 1999;45(3):721–727. doi:10.1016/S0360-3016(99)00170-4
50. Kudrimoti M, Regine WF, Huhn JL, Meigooni AS, Ahmed M, Mohiuddin M. Spatially fractionated radiation therapy (SFR) in the palliation of large bulky (>8 cm) melanomas (abstr). *Int J Radiat Oncol Biol Phys*. 2002;54:342–343. doi:10.1016/S0360-3016(02)03646-5



51. Huhn JL, Regine WF, Valentino JP, Meigooni AS, Kudrimoti M, Mohiuddin M. Spatially fractionated GRID radiation treatment of advanced neck disease associated with head and neck cancer. *Technol Cancer Res Treat.* 2006;5(6):607–612. doi:10.1177/153303460600500608
52. Zhang H, Wang JZ, Mayr N, et al. Fractionated grid therapy in treating cervical cancers: conventional fractionation or hypofractionation? *Int J Radiat Oncol Biol Phys.* 2008;70(1):280–813. doi:10.1016/j.ijrobp.2007.08.024
53. Peñagaricano JA, Griffin R, Corry P, Moros E, Yan Y, Ratanatharathorn V. Spatially fractionated (GRID) therapy for large and bulky tumors. *J Ark Med Soc.* 2009;105(11):263–265.
54. Penagaricano JA, Moros EG, Ratanatharathorn V, Yan Y, Corry P. Evaluation of spatially fractionated radiotherapy (GRID) and definitive chemoradiotherapy with curative intent for locally advanced squamous cell carcinoma of the head and neck: initial response rates and toxicity. *Int J Radiat Oncol Biol Phys.* 2010;76(5):1369–1375. doi:10.1016/j.ijrobp.2009.03.030
55. Neuner G, Mohiuddin MM, Vander Walde N, et al. High-dose spatially fractionated GRID radiation therapy (SFGRT): a comparison of treatment outcomes with cerrobend vs. MLC SFGRT. *Int J Radiat Oncol Biol Phys.* 2012;82(5):1642–1649. doi:10.1016/j.ijrobp.2011.01.065
56. Mohiuddin M, Park H, Hallmeyer S, Richards J. High-dose radiation as a dramatic, immunological primer in locally advanced melanoma. *Cureus.* 2015;7(12):e417. doi:10.7759/cureus.417
57. Billena C, Khan AJ, Current A. Review of spatial fractionation: back to the future? *Int J Radiat Oncol Biol Phys.* 2019;104(1):177–187. doi:10.1016/j.ijrobp.2019.01.073
58. Yan W, Khan MK, Wu X, et al. Spatially fractionated radiation therapy: history, present and the future. *Clin Transl Radiat Oncol.* 2019;20:30–38. PMID: 31768424; PMCID: PMC6872856. doi:10.1016/j.ctro.2019.10.004
59. Zhang H, Wu X, Zhang X, et al. Photon GRID radiation therapy: a physics and dosimetry white paper from the Radiosurgery Society (RSS) GRID/LATTICE, microbeam and FLASH Radiotherapy Working Group. *Radiat Res.* 2020;194(6):665–677. PMID: 33348375. doi:10.1667/RADE-20-00047.1
60. Griffin RJ, Ahmed MM, Amendola B, et al. Understanding high-dose, ultra-high dose rate, and spatially fractionated radiation therapy. *Int J Radiat Oncol Biol Phys.* 2020;107(4):766–778. doi:10.1016/j.ijrobp.2020.03.028
61. Chakravarty PK, Alfieri A, Thomas EK, et al. Flt3-ligand administration after radiation therapy prolongs survival in a murine model of metastatic lung cancer. *Cancer Res.* 1999;59(24):6028–6032.
62. Sathishkumar S, Dey S, Meigooni AS, et al. The impact of TNF- $\alpha$  induction on therapeutic efficacy following high dose spatially fractionated (GRID) radiation. *Technol Cancer Res Treat.* 2002;1(2):141–147. doi:10.1177/153303460200100207
63. Sathishkumar S, Boyanovsky B, Karakashian AA, et al. Elevated sphingomyelinase activity and ceramide concentration in serum of patients undergoing high dose spatially fractionated radiation treatment: implications for endothelial apoptosis. *Cancer Biol Ther.* 2005;4(9):979–986. doi:10.4161/cbt.4.9.1915
64. Peters ME, Shareef MM, Gupta S, et al. Potential utilization of bystander/abscopal-mediated signal transduction events in the treatment of solid tumors. *Curr Signal Transduct Ther.* 2007;2(2):129–143. doi:10.2174/157436207780619509
65. Shareef MM, Cui N, Burikhanov R, et al. Role of tumor necrosis factor- $\alpha$  and TRAIL in high-dose radiation-induced bystander signaling in lung adenocarcinoma. *Cancer Res.* 2007;67(24):11811–11820. doi:10.1158/0008-5472.CAN-07-0722
66. Formenti SC, Demaria S. Systemic effects of local radiotherapy. *Lancet Oncol.* 2009;10:718–726. doi:10.1016/S1470-2045(09)70082-8
67. Ahmed MM, Hodge JW, Guha C, Bernhard EJ, Vikram B, Coleman CN. Harnessing the potential of radiation-induced immune modulation for cancer therapy. *Cancer Immunol Res.* 2013;1(5):280–284. doi:10.1158/2326-6066.CIR-13-0141
68. Kanagavelu S, Gupta S, Wu X, et al. In vivo effects of lattice radiation therapy on local and distant lung cancer: potential role of immunomodulation. *Radiat Res.* 2014;182(2):149–162. doi:10.1667/RR3819.1
69. Asur R, Butterworth KT, Penagaricano JA, Prise KM, Griffin RJ. High dose bystander effects in spatially fractionated radiation therapy. *Cancer Lett.* 2015;356(1):52–57. doi:10.1016/j.canlet.2013.10.032
70. Filatenkov A, Baker J, Mueller AM, et al. Ablative tumor radiation can change the tumor immune cell microenvironment to induce durable complete remissions. *Clin Cancer Res.* 2015;21:3727–3739. doi:10.1158/1078-0432.CCR-14-2824
71. Wennerberg E, Lhuillier C, Vanpouille-Box C, et al. Barriers to radiation-induced in situ tumor vaccination. *Front Immunol.* 2017;8:229. doi:10.3389/fimmu.2017.00229
72. Buchwald ZS, Wynne J, Nasti TH, et al. Radiation, immune checkpoint blockade and the abscopal effect: a critical review on timing, dose and fractionation. *Front Oncol.* 2018;8:612. doi:10.3389/fonc.2018.00612
73. Rodriguez-Ruiz ME, Vanpouille-Box C, Melero I, Formenti SC, Demaria S. Immunological mechanisms responsible for radiation-induced abscopal effect. *Trends Immunol.* 2018;39(8):644–655. doi:10.1016/j.it.2018.06.001
74. Markovsky E, Budhu S, Samstein RM, et al. An antitumor immune response is evoked by partial-volume single-dose radiation in 2 murine models. *Int J Radiat Oncol Biol Phys.* 2019;103(3):697–708. doi:10.1016/j.ijrobp.2018.10.009
75. Wu X, Ahmed MM, Wright J, Gupta S, Pollack A. On modern technical approaches of three-dimensional high-dose Lattice radiotherapy (LRT). *Cureus.* 2010;2(3):e9.
76. Wu X, Perez NC, Zheng Y, et al. The technical and clinical implementation of LATTICE Radiation Therapy (LRT). *Radiat Res.* 2020;194:737–746. doi:10.1667/RADE-20-00066.1
77. Amendola B, Perez N, Amendola MA, et al. Lattice radiotherapy with RapidArc for treatment of gynecological tumors: dosimetric and early clinical evaluations. *Cureus.* 2010;2(9):e15. doi:10.7759/cureus.15
78. Blanco Suarez JM, Amendola BE, Perez NC, Amendola M, Wu X. The use of Lattice Radiation Therapy (LRT) in the treatment of bulky tumors: a case report of a large metastatic mixed mullerian ovarian tumor. *Cureus.* 2015;7(11):e389. doi:10.7759/cureus.389
79. Amendola BE, Perez NC, Wu X, Blanco Suarez JM, Lu JJ, Amendola M. Improved outcome of treating locally advanced lung cancer with the use of Lattice Radiotherapy (LRT): a case report. *Clin Transl Radiat Oncol.* 2018;9:68–71. doi:10.1016/j.ctro.2018.01.003
80. Amendola BE, Perez NC, Wu X, Amendola MA, Qureshi IZ. Safety and efficacy of lattice radiotherapy in voluminous non-small cell lung cancer. *Cureus.* 2019;11(3):e4263. doi:10.7759/cureus.4263
81. Amendola BE, Perez NC, Mayr NA, Wu X, Amendola M. Spatially fractionated radiation therapy using lattice radiation in far-advanced bulky cervical cancer: a clinical and molecular imaging and outcome study. *Radiat Res.* 2020;194:724–736. doi:10.1667/RADE-20-00038.1
82. Pollack A, Chinae FM, Bossart E, et al. Phase I trial of MRI-guided prostate cancer Lattice Extreme Ablative Dose (LEAD) boost radiation therapy. *Int J Radiat Oncol Biol Phys.* 2020;107(2):305–315. Erratum in: *Int J Radiat Oncol Biol Phys.* 2020 Sep 1;108(1):328. PMID: 32084522; PMCID: PMC7424349. doi:10.1016/j.ijrobp.2020.01.052

83. Jiang L, Li X, Zhang J, et al. Combined high-dose LATTICE radiation therapy and immune checkpoint blockade for advanced bulky tumors: the concept and a case report. *Front Oncol.* **2021**;10:548132. PMID: 33643893; PMCID: PMC7907519. doi:10.3389/fonc.2020.548132
84. Duriseti S, Kavanaugh JA, Szymanski J, et al. LITE SABR M1: a phase I trial of lattice stereotactic body radiotherapy for large tumors. *Radiother Oncol.* **2022**;167:317–322. PMID: 34875286. doi:10.1016/j.radonc.2021.11.023
85. Dincer N, Ugurluer G, Korkmaz L, et al. Magnetic resonance imaging-guided online adaptive lattice stereotactic body radiotherapy in voluminous liver metastasis: two case reports. *Cureus.* **2022**;14(4):e23980. PMID: 35541303; PMCID: PMC9084247. doi:10.7759/cureus.23980
86. Tubin S, Gupta S, Grusch M, et al. Shifting the immune-suppressive to predominant immune-stimulatory radiation effects by SBRT-Partial Tumor Irradiation Targeting Hypoxic segment (SBRT-PATHY). *Cancers.* **2020**;13(1):50. PMID: 33375357; PMCID: PMC7795882. doi:10.3390/cancers13010050
87. Spalek MJ. Lattice radiotherapy: hype or hope? *Ann Palliat Med.* **2022**;11(11):3378–3381. PMID: 36267011. doi:10.21037/apm-22-1081
88. Wu X. Spatial-temporal modulation in radiation therapy. *Precis Radiat Oncol.* **2022**;1–3. doi:10.1002/pro6.1174
89. Spalek MJ, Kozak K, Czarnecka AM, Bartnik E, Borkowska A, Rutkowski P. Neoadjuvant treatment options in soft tissue sarcomas. *Cancers.* **2020**;12(8):2061. PMID: 32722580; PMCID: PMC7464514. doi:10.3390/cancers12082061
90. Spalek MJ, Borkowska AM, Telejko M, et al. The feasibility study of hypofractionated radiotherapy with regional hyperthermia in soft tissue sarcomas. *Cancers.* **2021**;13(6):1332. PMID: 33809547; PMCID: PMC8000962. doi:10.3390/cancers13061332
91. Spalek MJ, Kosela-Paterczyk H, Borkowska A, et al. Combined preoperative hypofractionated radiotherapy with doxorubicin-ifosfamide chemotherapy in marginally resectable soft tissue sarcomas: results of a phase 2 clinical trial. *Int J Radiat Oncol Biol Phys.* **2021**;110(4):1053–1063. PMID: 33600887. doi:10.1016/j.ijrobp.2021.02.019

## Cancer Management and Research

Dovepress

### Publish your work in this journal

Cancer Management and Research is an international, peer-reviewed open access journal focusing on cancer research and the optimal use of preventative and integrated treatment interventions to achieve improved outcomes, enhanced survival and quality of life for the cancer patient. The manuscript management system is completely online and includes a very quick and fair peer-review system, which is all easy to use. Visit <http://www.dovepress.com/testimonials.php> to read real quotes from published authors.

Submit your manuscript here: <https://www.dovepress.com/cancer-management-and-research-journal>