

# A Comprehensive Retrospective Analysis of EVO/EVO+ Implantable Collamer Lens: Evaluating Refractive Outcomes in the Largest Single Center Study of ICL Patients in the United States

Camila Albo<sup>1</sup>, Taj Nasser<sup>2</sup>, David Thomas Szykarski<sup>2</sup>, Ngoc Nguyen<sup>3</sup>, Brett Mueller<sup>2,4</sup>, Lauren Libfraind<sup>2</sup>, Gregory Parkhurst<sup>2</sup>

<sup>1</sup>Department of Ophthalmology, University of Texas Health San Antonio, San Antonio, TX, USA; <sup>2</sup>Department of Ophthalmology, Parkhurst NuVision, San Antonio, TX, USA; <sup>3</sup>Department of Ophthalmology, Medical City Plano, Plano, TX, USA; <sup>4</sup>Department of Ophthalmology, Mueller Vision, Fort Worth, TX, USA

Correspondence: Taj Nasser, Department of Ophthalmology, Parkhurst NuVision, 9725 Datapoint Dr Ste 106, San Antonio, TX, 78229, USA, Tel +1 210-585-2020, Email tajnasserm@gmail.com

**Purpose:** We evaluate visual outcomes in patients with EVO/EVO+™ (posterior chamber phakic intraocular lens with a central port) within approved United States (US) age and refractive range indications.

**Patients and Methods:** This single-center retrospective study evaluated one-month, single-center postoperative data for 225 eyes meeting inclusion criteria and undergoing EVO/EVO+ implantation from April to October 2022. Data included lens size (mm), lens power (diopters of spherical and cylindrical power), preoperative best corrected visual acuity, preoperative spherical equivalent from manifest refraction, achieved postoperative uncorrected visual acuity, postoperative refraction, intraocular pressure (mmHg), and adverse events.

**Results:** A total of 225 eyes underwent EVO/EVO+ Implantable Collamer Lens (ICL) implantation from April to October 2022, with 51.5% receiving toric lenses. The most common ICL size was 12.6mm (56.4%), followed by 13.2mm (27.5%), 12.1mm (15.1%), and 13.7mm (0.9%). Among patients with preoperative BCVA of 20/20 or better (149 eyes), 95.2% achieved postoperative UCVA of 20/20 or better, and 99.3% achieved UCVA of 20/25 or better at postoperative month one. About 75% of eyes were within a spherical equivalent target of  $\pm 0.50$  D and 94% within  $\pm 1.00$  D. Toric ICLs were implanted in 116 eyes (51.8%). Of these, anticipated residual cylinder  $>1$  diopter was seen in 21 eyes (18.1%) resulting in three rotations, three explants, and three laser vision correction (LVC) enhancements. The postoperative adjustment rate (including rotations, exchanges, and LVC enhancement) was minimal (4.8%). Incidence of major adverse events was 0%.

**Conclusion:** Our study, the largest US single-center analysis of EVO/EVO+ ICL implantation, demonstrates strong early results and infrequent adverse events, supporting ICL safety and effectiveness. High predictability and favorable visual outcomes, including 20/20 or better, highlight the reliability of this technology. Despite study limitations, our findings underscore this technology's effectiveness. Future research should refine patient criteria and assess long-term outcomes in this evolving landscape.

**Plain language summary:** This research study aimed to investigate the outcomes of the EVO/EVO+ Implantable Collamer Lens (ICL), a potential alternative to laser vision correction procedures for people with refractive errors such as myopia, with and without astigmatism. One of the goals was to study how effective and safe the EVO ICL is by analyzing a large group of patients (225 eyes, 113 patients) who had undergone implantation of these lenses at a single practice in the US.

We examined postoperative vision, complication rates, and percentage of patients that required a secondary procedure for a visual enhancement. One hundred percent of patients whose vision was correctable to 20/20 in either eye preoperatively achieved 20/20 vision or better without correction at one month postoperatively. Among eyes that were correctable to 20/20 preoperatively, 95% achieved 20/20 or better without correction postoperatively and 99% of eyes achieved 20/25 or better.

EVO ICL offers great visual outcomes and is an effective treatment option for the treatment of myopia with and without astigmatism. This procedure has a low risk for complications, indicating its safety. By providing this comprehensive evaluation, we hope to give people considering incorporating the EVO ICL surgery into their practice a better understanding of the safety and effectiveness of the procedure. Ultimately, our study aims to improve patient outcomes and enhance the overall quality of care in the field of refractive surgery.

**Keywords:** refractive surgery, visual outcomes, postoperative complications, myopia, astigmatism

## Introduction

Uncorrected refractive errors, including myopia, hyperopia, and astigmatism, are the primary cause of visual impairment and the second most common cause of blindness worldwide.<sup>1,2</sup> The evolution of refractive surgery has seen significant advancements in recent years, with the introduction of new forms of laser vision correction and novel surgical techniques including intraocular devices designed to address refractive errors. Among these innovations, the EVO and EVO+ Visian Implantable Collamer Lenses™ and STAAR Surgical Inc. (posterior chamber phakic intraocular lens with a central port), introduced in 2011 and 2015, respectively, have been documented as an effective and safe option for vision correction.<sup>3–7</sup> These lenses have gained considerable attention as a refractive surgery option due to their potential advantages, such as excellent optical quality, removability, and minimal induction of dry eye symptoms, especially for individuals with thin corneas, high myopia, or irregular corneal topography.<sup>8–10</sup> In March 2022, the United States Food and Drug Administration (US-FDA) granted approval for the EVO/EVO+ Sphere and Toric ICL lenses.<sup>11</sup> These lenses are specifically indicated for individuals aged 21–45 years seeking correction or reduction of myopia with and without astigmatism, including patients with a spherical equivalent (SE) of –3.0 D to –20.0 D at the spectacle plane, as well as for individuals with myopic astigmatism with a SE of –3.0 D to –20.0 D, and astigmatism of 1.0 D to 4.0 D at the spectacle plane.<sup>12</sup>

The existing body of research has provided encouraging evidence regarding the safety and effectiveness of the EVO ICL in improving visual acuity, as reviewed by Wannapanich et al.<sup>13</sup> However, questions regarding the predictability, stability, and long-term visual outcomes of the EVO ICL, as well as potential complications and their incidence rates, need to be further addressed to establish a comprehensive understanding of this refractive surgery technique. While smaller-scale studies have shown promising results, the absence of more comprehensive evaluations in a large cohort of ICL patients within the US impedes a thorough understanding of the technique's efficacy, safety, and long-term outcomes within this population.

In this study, we aim to bridge this knowledge gap by presenting the largest retrospective single-center analysis of the EVO/EVO+ ICL in the US to date, examining refractive outcomes and the overall effectiveness of this lens in correcting a wide range of refractive errors. By analyzing a substantial number of patients who underwent ICL implantation, we intend to provide a comprehensive assessment of the refractive outcomes achieved and identify factors influencing visual acuity improvement, predictability, and stability in a post-approval, real-world commercial setting. Additionally, we seek to investigate the occurrence of complications and secondary procedures, including postoperative visual disturbances, laser-assisted in situ keratomileusis (LASIK) enhancement, photorefractive keratectomy (PRK) enhancement, and ICL explantation, to gain insights into the safety profile of the EVO ICL. We hypothesize that the EVO ICL will demonstrate positive refractive outcomes with a low incidence of complications, positioning it as a viable option for individuals seeking refractive correction.

## Materials and Methods

### Patients

This was a single-practice retrospective analysis of 225 ICL procedures for myopia with or without astigmatism using the EVO and EVO+ lens performed at Parkhurst NuVision between April 2022 and October 2022 by four surgeons. Informed consent for surgery and institutional review board approval was obtained (Advarra Institutional Review Board (Columbia, USA)). The study complied with the tenets of the Declaration of Helsinki. Inclusion criteria were

patients who were deemed candidates for ICL surgery during this time period (including off-label indications) who also had sufficient follow-up data up to postoperative month one (POM 1) visit with manifest refraction. Subjects were excluded if they had any prior ocular surgery, active or uncontrolled autoimmune diseases, systemic disease likely to affect wound healing such as diabetes and severe atopy, or if they were pregnant or nursing. Study data included lens size (mm), lens power (diopters of spherical and cylindrical power), preoperative best corrected visual acuity, preoperative spherical equivalent from manifest refraction, achieved postoperative uncorrected visual acuity, postoperative refraction, intraocular pressure (mmHg), and adverse events.

The lens power closest to the postoperative plano target was selected based on the individual's age. For patients greater than 20 years old, the target spherical equivalent was +0.30 D, gradually decreasing to plano until age 45. Patients desiring blended vision were excluded from the study group. If available, the EVO+ lens was used; otherwise, the EVO lens was used.

## Surgical Protocol

The surgical approach for lens implantation displayed a shared methodology among all surgeons in this center. The patients were administered dilating agents. After topical anesthesia, surgery was initiated by creating an entry point aligned with the steepest axis of the corneal cylinder, alternatively temporal placement depending on surgeon preference. To accomplish this, a 3.0-mm keratome blade was employed. Notably, no astigmatic interventions, such as limbal relaxing incisions, were executed. The ICL was inserted with the use of an injector cartridge (STAAR Surgical) after placement of an ophthalmic viscosurgical device (OcuCoat, Bausch & Lomb, Rochester, NY) into the anterior chamber. The ICL was placed in the posterior chamber, and the viscosurgical device was completely washed out of the anterior chamber with a balanced salt solution. The patients did not undergo preoperative or intraoperative peripheral iridectomies. Sequential bilateral surgery was performed for all cases with completely separate sterile instrument sets, and medications from separate lot numbers were used. An immediate postoperative examination was conducted 1 hour after surgery to ensure proper intraocular pressure and secure sutureless wound closure. Patients were monitored after surgery at postoperative day one (POD 1), postoperative week one (POW 1), and postoperative month one (POM 1). Study data included lens size, lens power, manifest refraction, achieved postoperative uncorrected visual acuity, intraocular pressure, and adverse events.

## Statistical Analysis

Postoperative data from the POM 1 visit was used for analysis, if available. Student's t-tests were used to calculate the statistical significance of any changes in IOP. Microsoft Excel 2023 (Version 16.74. Microsoft Corporation, Redmond, WA, USA) was used for data entry and statistical analysis. A p-value <0.05 was defined as statistically significant. To assess the clinical disparities among the groups, UDVA and refractive data were employed for comparisons when deemed suitable.

## Results

### Demographics

During the study period, 225 eyes received EVO/EVO+ ICL implantation and met inclusion criteria. Toric lenses accounted for 116 eyes (51.6%). The most common ICL size was 12.6mm (56.4%), followed by 13.2mm (27.6%), 12.1mm (15.1%), and 13.7mm (0.9%). The mean spherical ICL power was -9.14 D with a range from -3.50 D to -17.50 D. The mean cylindrical ICL power was 2.35 D with a range from 1.00 D to 4.00 D (Table 1).

### Outcomes

One hundred percent of patients whose vision was correctable to 20/20 in either eye preoperatively achieved 20/20 vision or better without correction at one month postoperatively. Among 149 eyes that were correctable to 20/20 or better preoperatively, 95.1% achieved 20/20 or better without correction postoperatively and 99.3% of eyes achieved 20/25 or better at postoperative month one.

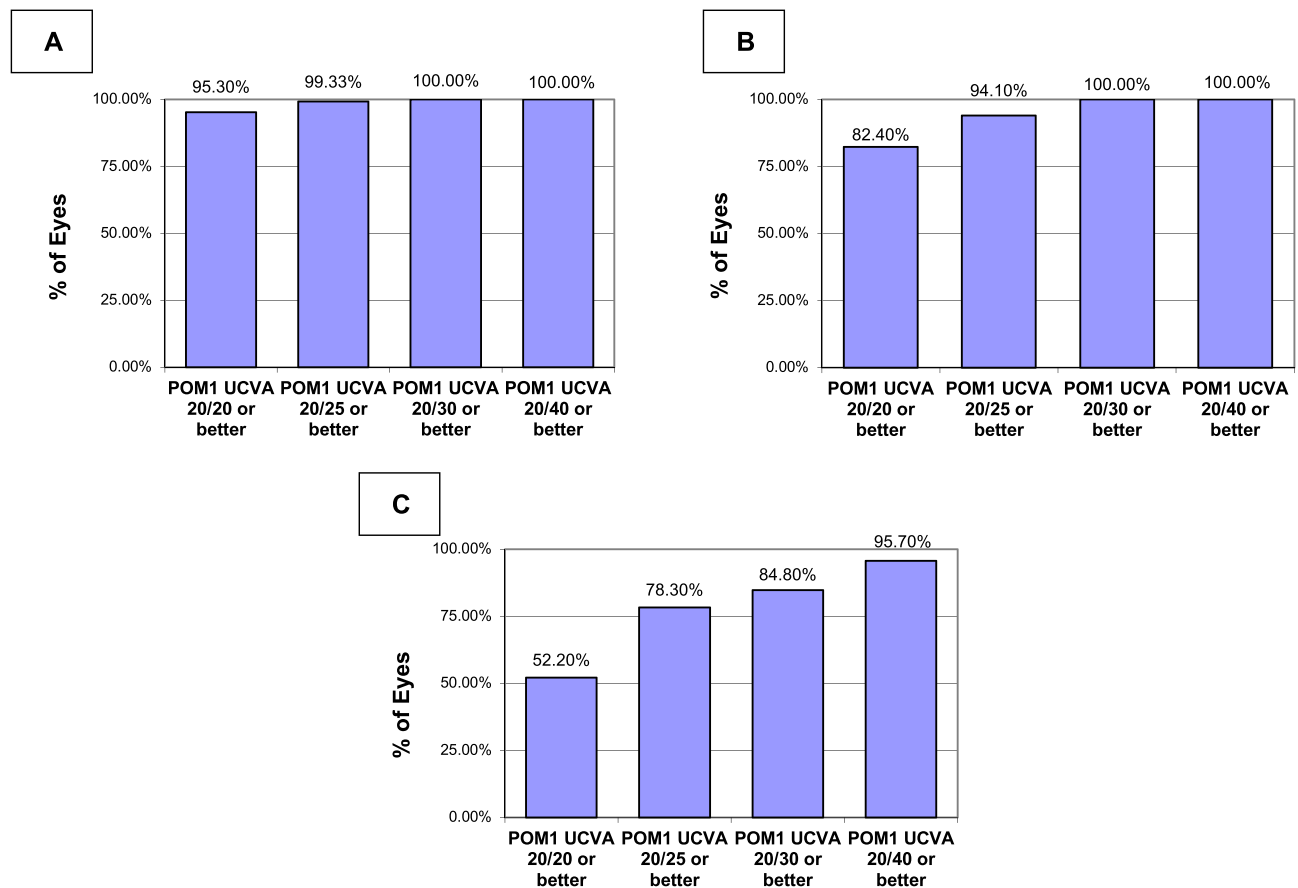
In all eyes, regardless of preoperative BVCA, 84.4% achieved 20/20 or better UCVA and 99.2% of all eyes achieved 20/40 or better. In patients with preoperative BCVA 20/25 (34 eyes), 32 eyes (94.1%) had a POM 1 UCVA 20/25 or

**Table 1** Study demographics and ICL Characteristics

Eyes (Patients)	229 (116)
Toric lens, n (%)	121 (52.84)
ICL size mm, n (%)	
12.1	35 (15.28)
12.6	130 (56.77)
13.2	62 (27.07)
13.7	2 (0.87)
Spherical power (D)	
Mean (SD)	−9.14 (3.05)
Median	−9.00
Min, Max	−3.50, −17.50
Cylindrical power (D)	
Mean (SD)	2.35 (0.97)
Median	2.00
Min, Max	1.00, 4.00
Postoperative adjustments, n (%)	
LASIK enhancement	4 (1.75)
PRK enhancement	1 (0.44)
ICL explantation	2 (0.87)
ICL rotation	3 (1.31)
ICL exchange	1 (0.44)

**Abbreviations:** n, sample size; %, percentage of all eyes; mm, millimeters; LASIK, laser-assisted in situ keratomileusis; ICL, implantable collamer lens; D, diopters; SD, standard deviation; PRK, photorefractive keratectomy.

better and 100% had a POM 1 UCVA 20/30 or better (Figure 1). Patients with preoperative BCVA 20/30 or worse, 24 eyes (52.2%) reached POM 1 UCVA 20/20 or better, 36 eyes (78.3%) reached POM 1 UCVA 20/25 or better, 39 eyes (84.8%) reached POM 1 UCVA 20/30 or better, and 44 eyes (95.7%) reached POM 1 UCVA 20/40 or better. One month after surgery, 75.1% of eyes were within a spherical equivalent of  $\pm 0.50$  D and 94% of eyes were within a spherical equivalent of  $\pm 1.00$  D of target (Figure 2). Toric ICL was implanted in 116 eyes (51.6%). Of these, residual cylinder  $>1$  diopter of anticipated was seen in 21 eyes (18.1%) with 3 of these requiring rotation, 1 requiring ICL exchange, and 3 requiring laser vision correction (LVC) enhancement (Figure 3). Among all study eyes, the rate of postoperative adjustment (including ICL rotation, exchange, and LVC enhancement) was minimal (4.8%). Of note, 5 eyes with postoperative astigmatism  $\geq 1.0$  D had either stable keratoconus with history of cross-linking or high degree of astigmatism ( $\geq 4.0$ D) pre-operatively, both off-label (Figure 3). The average IOP showed no clinically meaningful change from the preoperative to postoperative visits. The mean IOP measurement was 16.6 preoperatively and decreased postoperatively to 14.1 (POD 1), 15.6 (POW 1), and 15.1 (POM 1) (Table 2).



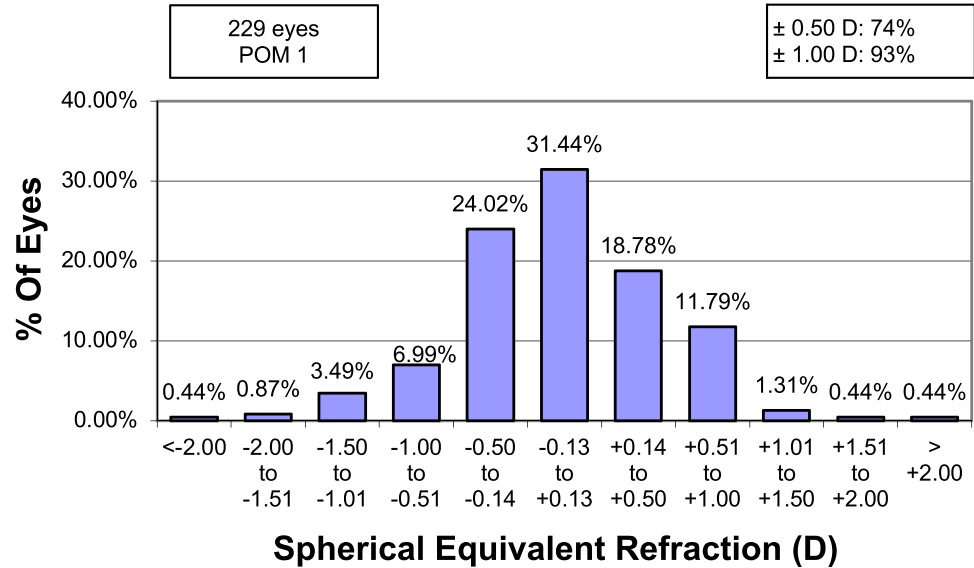
**Figure 1** Postoperative Month One Uncorrected Visual Acuity. Achieved uncorrected visual acuity (UCVA) at postoperative month one among patients with a preoperative best corrected visual acuity (BCVA) of 20/20 or better, n= 149 (A), 20/25, n= 34 (B), and 20/30 or worse, n= 46 (C). 95.30% of eyes with preoperative BCVA 20/20 had postoperative UCVA 20/20 (A).

**Abbreviations:** BCVA, best corrected visual acuity; POM1, postoperative month one; UCVA, uncorrected visual acuity; n, number of eyes, %, percentage.

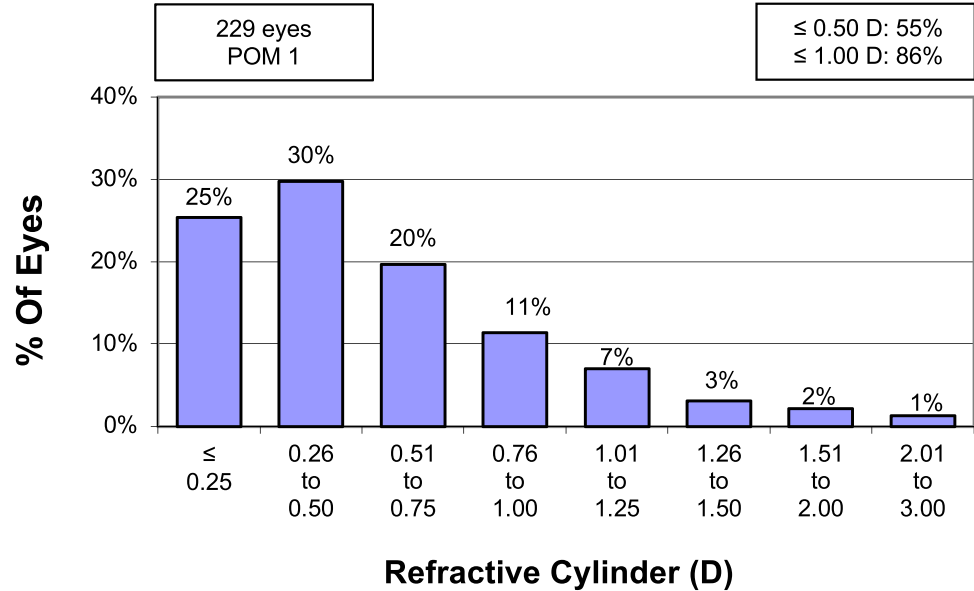
## Adverse Events

A total of 8 out of 225 eyes (4.8%) required enhancement by either cornea-based refractive surgery or toric ICL rotation. Four eyes (4/225 eyes, 1.7%, two subjects) underwent LASIK enhancement, one eye underwent PRK enhancement (0.44%), three eyes underwent ICL rotation (1.31%), and two eyes (0.87%) underwent ICL explantation due to persistent bilateral idiopathic anterior uveitis.

Four eyes (4/225 eyes, 1.75%, two subjects) underwent LASIK enhancement. The first patient was hyperopic with a post-ICL residual manifest refraction of 1.00/-0.25/029 in the right eye and 1.50/0/0 in the left eye. The vault size was on the higher end of the spectrum but still acceptable LVC vs ICL exchange was discussed, and LASIK was decided on to treat the residual hyperopia. The patient was 20/20 without correction at distance after LASIK enhancement. The second patient was also symptomatic to residual hyperopic astigmatism with a post-ICL residual manifest refraction of 1.00/-0.50/149 in the right eye and 1.00/-0.75/160 in the left eye. Post-LASIK uncorrected distance visual acuity was 20/20-1 in the right eye and 20/20-2 PH 20/20 in the left eye. One eye underwent PRK enhancement (0.44%). This patient had a known history of amblyopia in that eye and was aware of visual limitations. ICL rotation calculations predicted improvement in residual manifest refraction with an ICL rotation of 11–12 degrees CCW from the current position. The current toric marking was 179 with the ideal toric marking between 167 and 168 degrees. The patient elected to proceed with PRK enhancement instead of an ICL rotation with improvement in visual acuity to 200/25-2 PH 20/20-1. IOP and vault size remained stable Three eyes underwent ICL rotation (1.31%). Of these, the first patient's ICL vault size was good, but the lens was tilted on ultrasound. Ultrasound also showed a small ciliary body cyst. The patient had improvement in vision to 20/20 with a stable IOP. The other two ICL rotations were performed for both eyes of one patient given symptomatic glare in dim settings. The right eye



**Figure 2** Postoperative Month One Spherical Equivalent Refractive Accuracy. Accuracy of spherical equivalent refractive correction at postoperative month one. 74% of eyes were within  $\pm 0.50$  D and 93% of eyes were within  $\pm 1.00$  D of emmetropia.  
**Abbreviations:** POM I, postoperative month one; D, diopters; %, percentage.



**Figure 3** Postoperative Month One Residual Refractive Cylinder. Among the 229 study eyes, 55% of eyes had 0.50 D or less of residual cylinder and 86% of eyes had 1.00 D or less residual cylinder.  
**Abbreviations:** POM I, postoperative month one; D, diopters; %, percentage.

ICL rotation axis was changed from 171 to 177. The left eye ICL rotation axis was changed from 158 to 169. The patient had marked improvement in visual acuity to 20/25+1 PH 20/20 in the right eye and 20/20-1 in the left eye. The vault size remained adequate with a normal IOP. One eye underwent ICL exchange for a smaller size. The initial 12.6 lens size was exchanged for a 12.1 lens size to ensure best fit for the patient’s vault size. IOP remained normal before and after the ICL exchange. Two eyes (1 patient) underwent ICL explantation due to persistent bilateral idiopathic anterior uveitis.

Incidence of cataract, endophthalmitis, toxic anterior segment syndrome, pigment dispersion, any form of glaucoma, retinal detachment, endothelial cell loss leading to corneal decompensation, sympathetic ophthalmia, and traumatic rupture of the globe at the incision site were all 0% in this study. No other major adverse events were reported.



**Table 2** Intraocular Pressure Measurements Remained Stable During the Perioperative Study Period

IOP	N (%)	Mean	Median	Standard Deviation
Preoperative	208 (90.83)	16.6	17.0	4.02
POD 1	227 (99.13)	14.1	14.0	3.68
POW 1	148 (64.63)	15.6	15.0	4.07
POM 1	214 (93.45)	15.1	15.0	4.16

**Abbreviations:** N, number of eyes; %, percentage of all eyes; IOP, intraocular pressure; POD 1, postoperative day; POW 1, postoperative week one; POM 1, postoperative month one.

## Discussion

The evolution of refractive surgery has brought various options for patients desiring vision correction. Among them, the EVO/EVO+ ICL has offered a revolutionary approach that accommodates diverse patient needs and refractive challenges.<sup>14</sup> This retrospective analysis from a single-center private practice accentuates their effectiveness, safety, and potential benefits. This retrospective analysis, rooted in data from a single-center private practice, underscores the potential of this technology which promises greater customization for patients. While the results are promising, they also highlight the continuous journey of innovation in the realm of ophthalmology. Our findings contribute to the growing body of evidence regarding the effectiveness and safety of these innovative lenses in addressing various refractive errors and enhancing overall visual quality.

Traditional corneal refractive procedures like LASIK, laser-assisted lenticular extraction (LALEX), and photorefractive keratectomy (PRK) have certain limitations, particularly for individuals with thin corneas, high myopia, or irregular corneal topography.<sup>15</sup> In such cases, ICL provides an alternative, preserving the corneal structure. ICLs rest securely in the sulcus, thereby avoiding any alterations to the cornea's integrity. This positioning offers an added advantage as it does not compromise corneal biomechanics or expose the eye to potential surface-related complications. Furthermore, the removable nature of ICL implantation offers a unique benefit, allowing for adjustments, exchange, or removal if required, thereby providing a safety net not typically available with corneal reshaping procedures. The biocompatible materials used in ICLs, combined with their minimally invasive placement, make them a favorable option for addressing a spectrum of refractive errors while maintaining the eye's structural and physiological integrity.

Subgroup analysis based on pre-operative BCVA showed the vast majority of patients maintained the same visual acuity range postoperatively, with a significant proportion of patients gaining 1 or more lines of vision. This improvement is often attributed to the high-quality optics of the ICL, which can avoid the induction of higher-order aberrations, and the closer proximity to the nodal point of the eye, leading to sharper vision. This is consistent with prior studies that have demonstrated effectiveness of the ICL, leading to a gain in lines of vision.<sup>16</sup>

Our study observed excellent postoperative visual acuity with a significant number achieving UCVA of 20/20 or better. This aligns with prior reports on ICL outcomes.<sup>17</sup> The predictability of this lens implantation is further underscored by the stability of refraction outcomes.<sup>18</sup> The refractive accuracy of post-implantation was corroborated by a reduced standard deviation in postoperative spherical equivalent values. Additionally, our examination highlighted a consistent reduction in postoperative astigmatic errors, emphasizing the ICL's capability to address cylindrical refractive discrepancies effectively. Collectively, these observations bolster the assertion that ICL implantation offers not only precision but also repeatability, merging both safety and effectiveness in refractive correction.

In our analysis, we aimed to provide an evaluation of the short-term safety profile associated with ICL implantation. Earlier ICL models posed safety concerns including endothelial cell loss, cataract formation and narrowed iridocorneal angles.<sup>19–21</sup> However, the EVO version, with improved design which removes the need for preoperative peripheral iridotomy, seems to mitigate such complications.<sup>15</sup> Our study is in line with other recent evidence and demonstrates an excellent safety profile of the EVO ICL. We did not observe any incidence of cataract, endophthalmitis, toxic anterior segment syndrome, pigment dispersion, any form of glaucoma, retinal detachment, endothelial cell loss leading to

corneal decompensation, sympathetic ophthalmia, traumatic rupture of the globe at the incision site, or infectious keratitis. It is important to note that no cases of postoperative angle closure were noted with EVO ICL in this study.

In recent years, the stability and safety of intraocular pressure (IOP) following EVO ICL implantation have garnered significant attention in ophthalmological research. The EVO ICL design incorporates features to maintain the natural flow of aqueous humor, ensuring stable IOP postoperatively.<sup>22</sup> This is to not only ensure rotational stability but also eliminates the need for preoperative peripheral iridotomy, reducing potential associated complications.<sup>23</sup> Our study observed that the average IOP post-implantation remained within normal parameters at various postoperative timeframes, without notable spikes. Lisa et al emphasized that IOP remained stable across several postoperative intervals, suggesting a satisfactory safety profile.<sup>24</sup> Further supporting these findings, Kamiya et al concluded that the EVO ICL effectively shows stable IOP long term at 5 year follow-up, which showcases its reliability.<sup>25</sup>

Comparing our results with corneal refractive surgeries, especially for high myopia, indicates ICL's potential superiority in extreme cases.<sup>26</sup> The ICL appears to demonstrate similar effectiveness as wavefront-guided LASIK in postoperative higher order aberrations and contrast sensitivity postoperatively.<sup>27</sup> Contrast sensitivity is a pivotal aspect of visual function, going beyond mere visual acuity to reflect real-world visual experiences. This has been studied where ICL implantation exhibited commendable performance in terms of simulated night vision, outpacing the results from wavefront-optimized LASIK.<sup>28</sup> This finding accentuates the growing evidence that ICL can offer a holistic enhancement in vision, emphasizing both clarity and the ability to distinguish between varying shades of light. ICL also preserves corneal integrity. The biomechanical stability of the cornea post-ICL implantation offers a distinct advantage, particularly for those at an elevated risk for keratectasia.<sup>29</sup> While our study focused on visual outcomes in patients with EVO/EVO+, we recognize additional areas for potential exploration in subsequent research. Comprehensive astigmatic analyses, encompassing the flattening effect, summated vector mean of individual incision sites, and the mean magnitude of surgically induced astigmatism (SIA) for all incisions as a group would help refine our understanding of surgical outcomes. The work by Yoon et al serves as a noteworthy example in a similar context.<sup>30</sup> Their exploration of astigmatic and uncorrected visual acuity outcomes provides a foundation for our understanding and underscores the significance of adopting standardized approaches to incisional analysis.

Our study possesses several key strengths that contribute significantly to the field of cataract, refractive, and anterior segment surgery. Firstly, it stands as the largest single-center retrospective study conducted in the United States, evaluating postoperative outcomes following EVO/EVO+ ICL implantation. Moreover, the potential variability of outcomes attributed to surgical technique is minimized, as all patients underwent the procedure performed by the same surgical team at a single facility. However, it is important to acknowledge that the retrospective nature of our study does introduce potential biases, and results might not generalize across all clinical settings.

## Conclusion

In conclusion, our study, the largest single-center retrospective analysis of EVO/EVO+ ICL implantation in the United States to date, demonstrates promising early postoperative results with high predictability and favorable visual acuity outcomes. Safety profiles are positive, adverse events are infrequent, and the study benefits from a consistent surgical technique. While the short-term follow-up and retrospective nature of the study present as limitations, our findings support the effectiveness and safety of EVO ICL implantation, further establishing it as a valuable option for refractive correction. Future research, including prospective studies, should focus on long-term outcomes and refining patient selection criteria, acknowledging the dynamic landscape of refractive surgery. Patient-centric care remains at the forefront, requiring ongoing research, feedback, and adaptability. The findings from this analysis not only contribute to the growing body of knowledge but also pave the way for further studies to validate and expand upon the effectiveness and safety of the EVO ICL.

## Acknowledgments

The authors would like to acknowledge the doctors and staff at Parkhurst NuVision including Anthony Vanrachack, OD, Alexandra Wiechmann, OD, Thomas Nettleton, OD, Darcy Seaton, OD, FAAO, Lily Arendt, OD, Amanda Groenhuyzen, OD, Noelle Abraham, OD, and Tyson Gibbons, OD, for the unwavering dedication and exemplary care provided in this clinical practice.



## Funding

This study was supported by an unrestricted research grant from STAAR Surgical. The views expressed in this article are solely those of the authors.

## Disclosure

G. Parkhurst is a consultant for Alcon Laboratories, Inc.; Johnson & Johnson Vision; Carl Zeiss Meditec; LensAR; Novartis Pharmaceuticals Corporation; and STAAR Surgical. He has received research support from Alcon Laboratories, Inc.; Johnson and Johnson Vision; LensAR; STAAR Surgical; Glaukos; Novartis; Ocular Therapeutix; Sight Sciences; and Sun Pharmaceutical Industries.

B. Mueller is a consultant for Alcon Laboratories, Inc.; Johnson & Johnson Vision; and STAAR Surgical. He has received research support from Alcon Laboratories, Inc. The authors report no other conflicts of interest in this work.

## References

- Naidoo KS, Leasher J, Bourne RR, et al. Global vision impairment and blindness due to uncorrected refractive error, 1990–2010. *Optometry Vision Sci.* 2016;93(3):227–234. doi:10.1097/OPX.0000000000000796
- Varma R, Vajaranant TS, Burkemper B, et al. Visual impairment and blindness in adults in the United States: demographic and geographic variations from 2015 to 2050. *JAMA Ophthalmol.* 2016;134(7):802–809. doi:10.1001/jamaophthalmol.2016.1284
- Kamiya K, Shimizu K, Igarashi A, et al. Posterior chamber phakic intraocular lens implantation: comparative, multicentre study in 351 eyes with low-to-moderate or high myopia. *Br J Ophthalmol.* 2018;102(2):177–181. doi:10.1136/bjophthalmol-2017-310164
- Packer M. Evaluation of the EVO/EVO+ Sphere and Toric Visian ICL: six month results from the United States food and drug administration clinical trial. *Clin Ophthalmol.* 2022;1541–1553. doi:10.2147/OPTH.S369467
- Group LiToMS. United States Food and Drug Administration clinical trial of the Implantable Collamer Lens (ICL) for moderate to high myopia: three-year follow-up. *Ophthalmology.* 2004;111(9):1683–1692. doi:10.1016/j.ophtha.2004.03.026
- Lisa C, Alfonso JF, Alfonso-Bartolozzi B, Fernández-Vega L, Pérez-Vives C, Montés-Micó R. Collagen copolymer posterior chamber phakic intraocular lens supported by the ciliary sulcus to treat myopia: one-year follow-up. *J Cataract Refract Surg.* 2015;41(1):98–104. doi:10.1016/j.jcrs.2014.05.036
- Moshirfar M, Bundogji N, Tukan AN, et al. Toric implantable collamer lens for the treatment of myopic astigmatism. *Clin Ophthalmol.* 2021;2893–2906. doi:10.2147/OPTH.S321095
- Sanders DR, Vukich JA. Comparison of implantable contact lens and laser assisted in situ keratomileusis for moderate to high myopia. *Cornea.* 2003;22(4):324–331. doi:10.1097/00003226-200305000-00009
- Jeong A, Rubin GS, Allan BD. Quality of life in high myopia: implantable Collamer lens implantation versus contact lens wear. *Ophthalmology.* 2009;116(2):275–280. doi:10.1016/j.ophtha.2008.09.020
- Schallhorn S, Tanzer D, Sanders DR, Sanders ML. Randomized prospective comparison of Visian toric implantable collamer lens and conventional photorefractive keratectomy for moderate to high myopic astigmatism. *J Refract Surg.* 2007;23(9):853–867. doi:10.3928/1081-597X-20071101-01
- Packer M. The EVO ICL for Moderate Myopia: results from the US FDA Clinical Trial. *Clin Ophthalmol.* 2022;3981–3991. doi:10.2147/OPTH.S393422
- EVO/EVO+ VISIAN implantable collamer lens – P030016/S035. Available from: <https://www.fda.gov/medical-devices/recently-approved-devices/evoevo-visian-implantable-collamer-lens-p030016s035>. Accessed June 27, 2023.
- Wannapanich T, Kasetsuwan N, Reinprayoon U. Intraocular Implantable Collamer Lens with a Central Hole Implantation: safety, Efficacy, and Patient Outcomes. *Clin Ophthalmol.* 2023;969–980. doi:10.2147/OPTH.S379856
- Packer M. The Implantable Collamer Lens with a central port: review of the literature. *Clin Ophthalmol.* 2018;12:2427–2438. doi:10.2147/OPTH.S188785
- Zhang Y, Shen Q, Jia Y, et al. Clinical Outcomes of SMILE and FS-LASIK Used to Treat Myopia: a Meta-analysis. *J Refract Surg.* 2016;32(4):256–265. doi:10.3928/1081597X-20151111-06
- Parkhurst G, Psolka M, Kezirian G. Phakic intraocular lens implantation in United States military warfighters: a retrospective analysis of early clinical outcomes of the Visian ICL. *J Refract Surg.* 2011;27(7):473–481. doi:10.3928/1081597X-20110106-03.
- Shimizu K, Kamiya K, Igarashi A, Kobashi H. Long-Term Comparison of Posterior Chamber Phakic Intraocular Lens With and Without a Central Hole (Hole ICL and Conventional ICL) Implantation for Moderate to High Myopia and Myopic Astigmatism: consort-Compliant Article. *Medicine (Baltimore).* 2016;95(14):e3270. doi:10.1097/MD.00000000000003270.
- Igarashi A, Shimizu K, Kamiya K. Eight-year follow-up of posterior chamber phakic intraocular lens implantation for moderate to high myopia. *Am J Ophthalmol.* 2014;157(3):532–9.e1. doi:10.1016/j.ajo.2013.11.006.
- Sanders D. Anterior subcapsular opacities and cataracts 5 years after surgery in the Visian implantable collamer lens FDA trial. *J Refract Surg.* 2008;24(6):566–570. doi:10.3928/1081597X-20080601-04.
- Huang D, Schallhorn SC, Sugar A, et al. Phakic intraocular lens implantation for the correction of myopia: a report by the American Academy of Ophthalmology. *Ophthalmology.* 2009;116(11):2244–2258. doi:10.1016/j.ophtha.2009.08.018.
- Guber I, Mouvet V, Bergin C, Perritaz S, Othenin-Girard P, Majo F. Clinical Outcomes and Cataract Formation Rates in Eyes 10 Years After Posterior Phakic Lens Implantation for Myopia. *JAMA Ophthalmol.* 2016;134(5):487–494. doi:10.1001/jamaophthalmol.2016.0078.
- Shimizu K, Kamiya K, Igarashi A, Shiratani T. Early clinical outcomes of implantation of posterior chamber phakic intraocular lens with a central hole (Hole ICL) for moderate to high myopia. *Br J Ophthalmol.* 2012;96(3):409–412. doi:10.1136/bjophthalmol-2011-300148.

23. Senthil S, Choudhari NS, Vaddavalli PK, Murthy S, Reddy JC, Garudadri CS. Etiology and Management of Raised Intraocular Pressure following Posterior Chamber Phakic Intraocular Lens Implantation in Myopic Eyes. *PLoS One*. 2016;11(11):e0165469. doi:10.1371/journal.pone.0165469.
24. Lisa C, Naveiras M, Alfonso-Bartolozzi B, Belda-Salmerón L, Montés-Micó R, Alfonso JF. Posterior chamber collagen copolymer phakic intraocular lens with a central hole to correct myopia: one-year follow-up. *J Cataract Refract Surg*. 2015;41(6):1153–1159. doi:10.1016/j.jcrs.2014.10.030.
25. Kamiya K, Shimizu K, Igarashi A, et al. Posterior chamber phakic intraocular lens implantation: comparative, multicentre study in 351 eyes with low-to-moderate or high myopia. *Br J Ophthalmol*. 2018;102(2):177–181. doi:10.1136/bjophthalmol-2017-310164.
26. Jiang Z, Wang H, Luo DQ, Chen J. Optical and visual quality comparison of implantable collamer lens and femtosecond laser assisted laser in situ keratomileusis for high myopia correction. *Int J Ophthalmol*. 2021;14(5):737–743. doi:10.18240/ijo.2021.05.15
27. Igarashi A, Kamiya K, Shimizu K, Komatsu M. Visual performance after implantable collamer lens implantation and wavefront-guided laser in situ keratomileusis for high myopia. *Am J Ophthalmol*. 2009;148(1):164–70.e1. doi:10.1016/j.ajo.2009.02.001.
28. Parkhurst G. A prospective comparison of phakic collamer lenses and wavefront-optimized laser-assisted in situ keratomileusis for correction of myopia. *Clin Ophthalmol*. 2016;10:1209–1215. doi:10.2147/OPTH.S106120
29. Randleman JB, Woodward M, Lynn MJ, Stulting RD. Risk assessment for ectasia after corneal refractive surgery. *Ophthalmology*. 2008;115(1):37–50. doi:10.1016/j.ophtha.2007.03.073
30. Nam D, Yoon J, Kim KH, Lee J. Surgically induced astigmatism after 3.0 mm temporal and nasal clear corneal incisions in bilateral cataract surgery. *Indian J Ophthalmol*. 2013;61(11):645. doi:10.4103/0301-4738.119341

## Clinical Ophthalmology

Dovepress

### Publish your work in this journal

Clinical Ophthalmology is an international, peer-reviewed journal covering all subspecialties within ophthalmology. Key topics include: Optometry; Visual science; Pharmacology and drug therapy in eye diseases; Basic Sciences; Primary and Secondary eye care; Patient Safety and Quality of Care Improvements. This journal is indexed on PubMed Central and CAS, and is the official journal of The Society of Clinical Ophthalmology (SCO). The manuscript management system is completely online and includes a very quick and fair peer-review system, which is all easy to use. Visit <http://www.dovepress.com/testimonials.php> to read real quotes from published authors.

Submit your manuscript here: <https://www.dovepress.com/clinical-ophthalmology-journal>