

# Upadacitinib for Alopecia Areata in Different Backgrounds: A Case Series

Xin He<sup>1,2</sup>, Dongyue Yang<sup>1,2</sup>, Lingyao Lai<sup>1,2</sup>, Jing Lang<sup>1,2</sup>, Kebo Wei<sup>1,2</sup>, Min Xiao<sup>1</sup>

<sup>1</sup>Department of Dermatology, Hospital of Chengdu University of Traditional Chinese Medicine, Chengdu, Sichuan Province, People's Republic of China; <sup>2</sup>School of Clinical Medicine, Chengdu University of Traditional Chinese Medicine, Chengdu, Sichuan Province, People's Republic of China

Correspondence: Min Xiao, Email [xiaomin@cdutcm.edu.cn](mailto:xiaomin@cdutcm.edu.cn)

**Abstract:** Alopecia Areata is a hair disorder influenced by factors such as genetics, immune system, and environmental triggers. The pathogenesis of this condition is still unclear, leading to unsatisfactory current treatments and causing a large number of patients to suffer from it. Janus kinase inhibitors are a new class of drugs that have emerged in recent years and are expected to be promising therapeutic tools for alopecia areata. We report five patients with varying backgrounds and severity of alopecia areata. All of them had received conventional therapy without success. Five patients took Upadacitinib at a dose of 15 mg once daily, and all of them achieved satisfactory efficacy. No adverse events were observed during the treatment of 5 patients.

**Keywords:** upadacitinib, alopecia areata, JAK inhibitors, JAK-STAT

## Introduction

Alopecia Areata (AA) is a prevalent inflammatory non-scarring alopecia condition.<sup>1</sup> It is currently considered a follicle-specific autoimmune disease resulting from a combination of genetic and environmental factors. The disease often presents as a sudden onset of round, flaky alopecia on the scalp with clear borders and localized smooth skin in the affected area, often without accompanying symptoms. In severe cases, there may be complete hair loss, including eyebrow, axillary, and pubic hair, leading to generalized or total baldness. This condition impacts the appearance and typically affects young and middle-aged individuals, often imposing a significant psychological and economic burden on patients. Traditional treatments include the topical and intradermal injection of glucocorticoids, topical minoxidil, and systemic use of glucocorticoids and immunosuppressants, among others. The clinical efficacy of these treatments varies greatly among individuals. The use of glucocorticoids and immunosuppressants has many side effects, leading to some patients still experiencing recurrent episodes of baldness after treatment. Fortunately, in recent years, studies have reported a number of new treatments for this disease, including oral Janus kinase inhibitors (JAK inhibitors, JAKi), antihistamines, compounded glycyrrhizin, and phototherapy.<sup>2</sup>

Current research suggests that the development of this disease is associated with cytokines such as interferon (IFN), interleukin (IL), and CD8+ T cells.<sup>3</sup> The JAK-STAT signaling pathway is a common downstream signaling pathway for cytokines such as interferon and some interleukins (3). Therefore, regulating Janus kinase in the JAK-STAT signaling pathway may offer new insights and methods for treating AA. Numerous studies and clinical trials have shown that first-generation JAK inhibitors, such as Baricitinib and Tofacitinib, have demonstrated significant clinical efficacy for AA. However, their adverse effects are also noteworthy, and the FDA has issued a black box warning for medication safety. As a second-generation JAK inhibitor, Upadacitinib offers a higher level of selective inhibition of JAK1 and a better safety profile compared to first-generation drugs. It may potentially be a superior solution for the treatment of AA.<sup>4</sup> Therefore, we treated five patients with diverse backgrounds using a regimen of Upadacitinib extended-release tablets at a dosage of 15 mg orally once daily. The severity and treatment effect of each patient were assessed before and after treatment using the SALT (Severity of Alopecia Tool) method,<sup>5</sup> as recommended by the evaluation guidelines of the American Academy of Dermatology in the United States.

Case Information

Case 1: Male, 48 years old. The patient has experienced repeated hair loss from the scalp, eyebrows, and beard for the past 6 years. Currently, the patient has lost hair, eyebrows, and beard, revealing the scalp with visible follicle openings. Some of the nails were visible as pits, and there was no obvious damage to the toenails. The SALT score was 100. Additionally, the patient has experienced recurrent generalized itching for 40 years. Currently, scattered papules and brown hyperpigmentation are visible all over the body, particularly on the extremities. Despite trying various treatments (Table 1), the symptoms of hair loss and generalized itchy skin persisted. Complete the relevant auxiliary examinations, including blood routine, liver and kidney function, fecal routine, mycobacterium tuberculosis spot test, and carcinoembryonic antigen, which did not show any obvious abnormalities. Cellular immunity (relative counts): The percentage of natural killer cells is 27.93%, and the CD4+/CD8+ ratio is 2.79. The total immunoglobulin E level is 1890 IU/mL. Markers of infection include positive results for hepatitis B virus surface antigen, hepatitis B virus core antibody, hepatitis B virus e antibody, and hepatitis B virus pre-S1 antigen. The hepatitis B virus DNA assay yielded a result of < 1.00E+02 IU/mL. Diagnosis: 1. Generalized Baldness 2. Atopic Dermatitis 3. Viral Hepatitis B. The patient was informed about the risks associated with the medication and was instructed to have regular check-ups for oncology, hepatitis B, and other infectious markers, and to follow up in the hepatology clinic. After excluding contraindications in August 2022, the patient began taking oral Upadacitinib extended-release tablets at a dose of 15 mg once daily. The patient's before and after treatment hair photos and dermoscopic photos are shown in Figure 1.

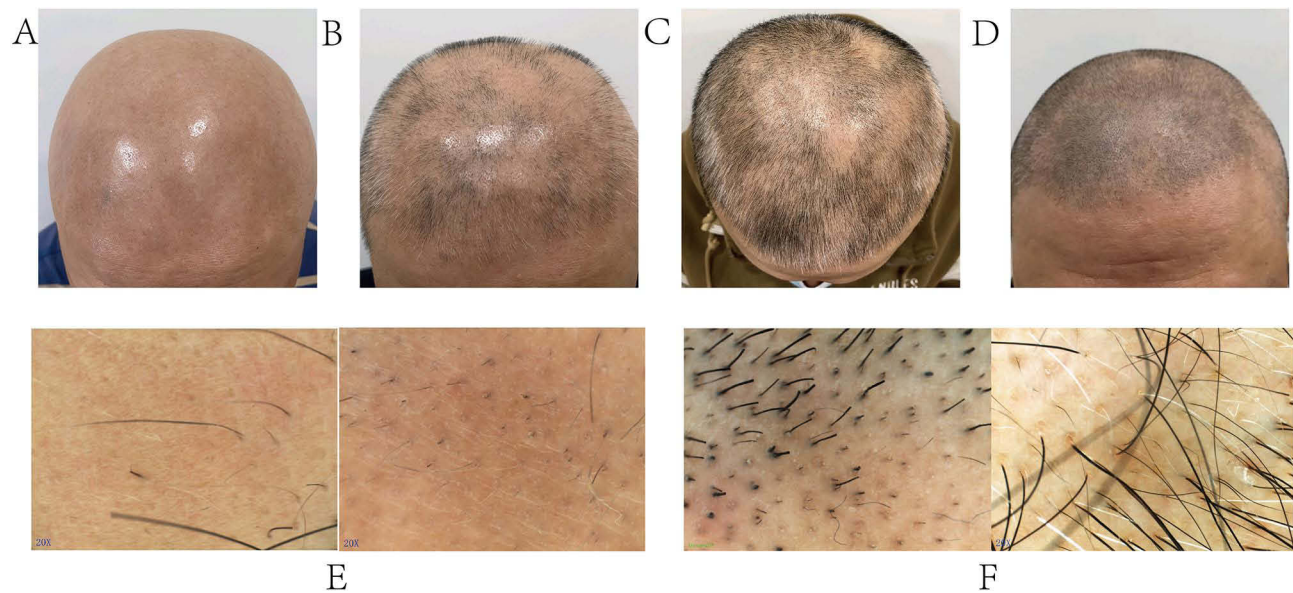
One month after taking the medication, a follow-up visit revealed regrowth of fine hair and eyebrows. The SALT score was 69.7. Two months later, the SALT score was 46. During the follow-up visit three months after starting the medication, the SALT score was 17.3. No abnormalities were found in the review of relevant safety indicators. Six months after taking the medication, the patient did not exhibit any noticeable hair loss on the scalp, with a SALT score of 0, and did not experience any itching on the entire body.

Case 2: Male, 20 years old, the patient who has experienced recurring hair and eyebrow loss for the past 5 years. The SALT score was 100. Multiple treatments had been applied to her (Table 1). But the patient has not yet experienced significant improvement. Before administering medication, it is important to conduct relevant auxiliary examinations. The antinuclear antibody test showed a positive result of 1:320. The infection markers, blood routine, liver and kidney function, tuberculin test and other necessary tests did not reveal any abnormalities. After excluding absolute contraindications in February 2022, the patient began taking oral Upadacitinib extended-release tablets at a dose of 15 mg once daily.

Table 1 Basic Information of 5 Patients of AA Treated with Upadacitinib

	Patient 1	Patient 2	Patient 3	Patient 4	Patient 5
Genders	M	M	F	M	F
Age(Years)	48	20	42	40	51
History of AA(Years)	6	5	3	10	3
Comorbidities	AD, Hepatitis B	None	None	None	None
Previous therapies	Antihistamines, TCS, Minoxidil, Micro needle therapy, TCM	Glucocorticoid (injected into skin lesions), Micro needle therapy, TCM	TCS, Glucocorticoid (injected into skin lesions), TCM	Glucocorticoid (injected into skin lesions), Minoxidil	Glycyrrhizin, Vit B, Minoxidil, Glucocorticoid (injected into skin lesions)
Upadacitinib duration(Months)	6	6	6	3	6
SALT (0/1/2/3/6 month)	100/69.7/46/17.3/0	100/81.4501/19.8/0	834/61.4/37.5/6.7/0	100/71.9/42.1/26.8/-	70.3/58.2/39.6/14.7/0
Side effect	None	None	None	None	None

**Abbreviations:** AA, Alopecia Areata; M, Male; F, Female; AD, Atopic Dermatitis; TCS, Topical glucocorticoids; TCM, Traditional Chinese Medicine; Vit B, Vitamin B; SALT, Severity of Alopecia Tool.



**Figure 1** Photos of Patient 1's hair and skin under the dermoscope. (A-D) These photos were taken before treatment, 1 month, 2 months and 3 months after treatment. It can be seen that the patient's hair is gradually growing back and the area of hair loss is gradually decreasing in size. (E and F) These photographs were taken under a dermatoscope before and 2 months after treatment, showing the patient's hair regrowth post-treatment.

One month after taking the medication, the SALT score was 81.4. Two months after taking the medication, the SALT score was 50.1. Three months after starting the medication, the SALT score was 19.8. Reexamination of relevant safety indicators did not reveal any significant abnormalities. Six months after taking the drug, the patient did not experience significant hair loss, with a SALT score of 0.

Case 3: Female, 42 years old. The patient has been experiencing recurrent flaky scalp alopecia for 3 years. The SALT score is 83.4. The hair-pulling test was positive. The patient had previously received ineffective treatment (Table 1). Relevant auxiliary examinations were completed: thyroglobulin antibody 134 IU/mL, 25-hydroxyvitamin D: 7.81 ng/mL, and there were no abnormality in blood routine, liver and kidney function, infection markers, carcinoembryonic antigen + alpha-fetoprotein, mycobacterium tuberculosis spot test, and anti-nuclear antibody. After excluding contraindications, the patient began taking oral Upadacitinib extended-release tablets at a dose of 15 mg once daily in February 2023.

One month after starting the medication, the SALT score dropped to 61.4. Two months later, the SALT score was 37.5. Three months after starting the medication, the SALT score was 6.7. Upon reexamining the relevant safety indicators, no obvious abnormalities were found. Six months after taking the drug, the SALT score was 0.

Case 4: Male, 40 years old. The patient has experienced hair loss for 10 years. The SALT score was 100. The patient had previously undergone diverse treatment (Table 1), but neither showed significant improvement. The patient still suffered recurrent hair loss. Complete related auxiliary tests: urine routine: occult blood 1+ (20 cells/ $\mu$ L), glucose 1+ (5.6 mmol/L), protein 1+ (0.3 g/L), epithelial cells 7/ $\mu$ L; stool routine: weakly positive for occult blood; 25-hydroxyvitamin D assay: 15.44 ng/mL; antithyroid peroxidase antibody 197 IU/mL; liver and kidney functions revealed a slight increase in transaminases. Blood routine + whole blood C-reactive protein, blood sedimentation, coagulation tetrograms, alpha-fetoprotein + carcinoembryonic antigen, mycobacterium tuberculosis spot test, infection markers, liver and kidney function + electrolytes, hepatitis B virus DNA and chest CT did not show apparent abnormalities. Due to the patient's slightly elevated transaminases and abnormal results of stool and urine tests, we requested regular reexamination of liver and kidney function as well as stool and urine tests for monitoring purposes. After excluding absolute contraindications, the patient was started on oral Upadacitinib extended-release tablets (15mg) once daily in May 2023.

One month after starting the medication, the SALT score was 71.9. Two months after starting the medication, the SALT score was 42.1. Three months after starting the medication, the SALT score was 26.8. The patient was lost to follow-up six months after starting the drug, and no further information could be obtained.

Case 5: Female, 51 years old. The patient has experienced hair and eyebrow loss for 3 years, which has worsened over the past 6 months. The hair-pulling test was positive, with a SALT score of 70.3. The patient had a history of alopecia areata 10 years ago, which was treated and resolved. She had been treated with a few kinds of treatment without significant improvement (Table 1). Complete relevant auxiliary tests: liver and kidney function: urea 2.18 mmol/L, creatinine 39.7  $\mu$ mol/L, alanine aminotransferase 60 U/L, methionine aminotransferase 40 U/L, glutamate dehydrogenase 34.4 U/L; 25-hydroxyvitamin D 14.04 ng/mL; blood routine, thyroid function, infection markers, stool routine, DIC test, blood sedimentation, immunoglobulin E, alpha-fetoprotein, carcinoembryonic antigen, electrocardiogram, and chest X-ray showed no abnormalities. Due to the patient's mild abnormalities in liver and kidney function tests, we recommended regular monitoring of their liver and kidney function. After excluding contraindications, the patient began taking Upadacitinib extended-release tablets, 15 mg once daily, in May 2023.

One month after taking the medication, the hair pulling test was negative, and the SALT score was 58.2. Two months after starting the medication, the SALT score was 39.6 points. Three months after starting the medication, the SALT score was 14.7. Upon reexamination, the relevant safety indicators did not reveal any significant abnormalities. Six months after taking the drug, the SALT score was 0.

Basic Information of 5 Patients are shown in Table 1.

## Discussion

Genetic, environmental, and immune factors, particularly those related to T lymphocytes and cytokines, may play a crucial role in the pathogenesis of AA.<sup>3</sup> Although the pathogenesis of AA cannot be fully clarified at present, this lack of understanding has resulted in the absence of highly specific and satisfactory preventive and therapeutic methods for AA.<sup>6,7</sup> AA is primarily characterized by patchy hair loss, and in severe cases, there may even be complete loss of hair, eyebrows, pubic hair, and other body hair all over the body, resulting in generalized or total baldness. Although the systemic effects of these clinical manifestations on internal organs are not clear, they seriously damage the appearance of patients. Additionally, AA has a chronic course, is prone to recurrent episodes, and is prevalent in young and middle-aged women, leading to significant physical, psychological, and economic burdens for patients. Therefore, we believe that AA is particularly important in the treatment of halting hair loss as soon as possible and promoting new hair growth to restore appearance. Animal experiments in mice have revealed that the pathogenesis of AA involves the activation of CD8<sup>+</sup>NKG2D<sup>+</sup> T cells to produce INF- $\gamma$ , with the involvement of JAK1 and JAK3. The activation of follicular epithelial cells by INF- $\gamma$ , mediated by JAK1 and JAK2, leads to an increase in the level of IL-15. IL-15, in turn, binds to specific receptors on the surface of CD8<sup>+</sup>NKG2D<sup>+</sup> T cells, resulting in an elevation of INF- $\gamma$  levels mediated by JAK1 and JAK3. The presence of INF- $\gamma$  may cause the breakdown of the immune immunity mechanism of the hair follicle, making the hair follicle vulnerable to attack by the auto-immune system. This can result in the clinical manifestation of hair loss.<sup>8,9</sup> The positive feedback pathway thus formed may lead to difficulties in breaking the cycle with conventional topical and oral anti-inflammatory treatments, resulting in poor therapeutic efficacy and recurrent of AA. Therefore, using JAK inhibitors to block the JAK signaling pathway and disrupt the positive feedback loop may emerge as a new strategy for treating AA.

JAK inhibitors are effective in downregulating INF- $\gamma$  signaling by inhibiting JAK activity. This has been confirmed by previous animal experiments and clinical observations.<sup>10</sup> Upadacitinib is an oral JAK1 inhibitor that has been found to have significant efficacy in treating rheumatoid arthritis, moderate-to-severe atopic dermatitis, and ankylosing spondylitis.<sup>11</sup> Baricitinib, Tofacitinib, Ruxolitinib have been used for AA treatment and achieved good efficacy in the past,<sup>12–15</sup> but the reports on Upadacitinib for AA are still rare. A case of childhood alopecia areata from Poland was reported to have a satisfactory outcome after twelve weeks of treatment with Upadacitinib. No adverse safety events were observed during or after the treatment.<sup>16</sup> In a retrospective case study of patients with alopecia areata, it was found that alopecia areata significantly improved in all three adult patients after 3–8 months of oral Upadacitinib.<sup>17</sup> Upadacitinib demonstrated efficacy and safety in the treatment of alopecia areata in a larger, longer follow-up retrospective study



involving 25 patients.<sup>18</sup> Based on reported cases and studies to date, Upadacitinib has a dual therapeutic effect in patients with atopic dermatitis and alopecia areata.<sup>19</sup> Although some of these cases were for the treatment of atopic dermatitis, improvement in the presence of alopecia areata in the patients was also observed.<sup>20–22</sup>

We reported five patients with diverse backgrounds and varying severity of AA. They had all undergone various conventional therapies before receiving treatment with Upadacitinib, but had not achieved satisfactory results. After using Upadacitinib, all five patients achieved satisfactory results, with four of them reaching a SALT score of 0 after six months of medication.

Patient 4 was lost to follow-up after three months of taking the medication, so there was no information available about his subsequent treatment status. However, Patient 4's SALT score showed significant improvement after three months of medication compared to the baseline period. (16–18). Improvement in both atopic dermatitis and AA has been reported in patients with concurrent atopic dermatitis and AA using Upadacitinib.<sup>21,23,24</sup> Patient 1, who had atopic dermatitis combined with AA, had both conditions controlled with Upadacitinib. It may be possible to provide limited clinical evidence supporting the dual role of Upadacitinib in controlling atopic dermatitis and AA. Patient 1 was found to have viral hepatitis B. Although there have been reported side effects related to the reactivation of the hepatitis B virus with Upadacitinib,<sup>11</sup> patient 1 had his hepatitis B DNA monitored before and after treatment, and no abnormalities were detected. He was also asked to follow up with the hepatologist's clinic to monitor his hepatitis B condition while taking Upadacitinib. All five patients underwent blood count, liver and kidney function, infection marker, tuberculosis infection, and tumor history or tumor marker examinations before starting Upadacitinib. Upadacitinib was administered only after excluding contraindications, and no significant abnormalities were found in the safety indexes of blood routine as well as liver and kidney function after three months of administration.

In conclusion, we have found that satisfactory results can be achieved quickly in the treatment of AA with Upadacitinib, particularly in patients who have not responded to conventional therapy. However, the use of Upadacitinib for the treatment of AA is still considered off-label, and its administration must be closely monitored for potential adverse reactions, including infection, tuberculosis, and tumors. Secondly, further investigation is needed to assess the effectiveness of Upadacitinib treatment for AA, determine how to reduce the dosage once the treatment is effective, and establish the timing for discontinuation of the drug in order to reveal the results.

## Conclusion

Although Upadacitinib is not currently approved for the treatment of AA, our current study based on five clinical cases shows that Upadacitinib has demonstrated efficacy in improving the condition of AA. However, it is worth noting that the effectiveness and safety of Upadacitinib have yet to be demonstrated in larger, rigorous, multicenter, randomized controlled trials. The current use of this drug for treating AA raises concerns about off-label use and high costs.

## Data Sharing Statement

The data that support the findings of this study are available from the corresponding author upon reasonable request.

## Consent Statement

All patients in this study signed an informed consent form and agreed to the use of Upadacitinib before receiving the drug. Additionally, they all consented to provide their case information and photographic images for the study. The publication of case and image information does not require institutional approval.

## Author Contributions

All authors made a significant contribution to the work reported, whether that is in the conception, study design, execution, acquisition of data, analysis and interpretation, or in all these areas; took part in drafting, revising or critically reviewing the article; gave final approval of the version to be published; have agreed on the journal to which the article has been submitted; and agree to be accountable for all aspects of the work.

## Funding

This study was funded by the State Administration of Traditional Chinese Medicine through the Second National Famous Traditional Chinese Medicine Doctor's (TCM) Workshop Development Project (Grant No. GuoZhongYiYaoRenJiaoFa [2022] No. 5).

## Disclosure

All authors have no conflicts of interest in this work.

## References

- Pratt CH, King LE Jr, Messenger AG, Christiano AM, Sundberg JP. Alopecia areata. *Nature Rev Dis Primers*. 2017;3:17011. doi:10.1038/nrdp.2017.11
- Ramírez-Marín HA, Tosti A. Emerging drugs for the treatment of alopecia areata. *Expert Opinion on Emerging Drugs*. 2022;27(4):379–387. doi:10.1080/14728214.2022.2149735
- Zhou C, Li X, Wang C, Zhang J. Alopecia Areata: an Update on Etiopathogenesis, Diagnosis, and Management. *Clin Rev Allergy Immunol*. 2021;61(3):403–423. doi:10.1007/s12016-021-08883-0
- Dahabreh D, Jung S, Renert-Yuval Y, Bar J, Del Duca E, Guttman-Yassky E. Alopecia Areata: current Treatments and New Directions. *Am J Clin Dermatol*. 2023;24(6):895–912. doi:10.1007/s40257-023-00808-1
- Olsen EA, Hordinsky MK, Price VH, et al. Alopecia areata investigational assessment guidelines--Part II. National Alopecia Areata Foundation. *J Am Acad Dermatol*. 2004;51(3):440–447. doi:10.1016/j.jaad.2003.09.032
- Mikhaylov D, Pavel A, Yao C, et al. A randomized placebo-controlled single-center pilot study of the safety and efficacy of apremilast in subjects with moderate-to-severe alopecia areata. *Arch Dermatological Res*. 2019;311(1):29–36. doi:10.1007/s00403-018-1876-y
- Tosti A, Iorizzo M, Botta GL, Milani M. Efficacy and safety of a new clobetasol propionate 0.05% foam in alopecia areata: a randomized, double-blind placebo-controlled trial. *J Eur Acad Dermatol Venerol*. 2006;20(10):1243–1247. doi:10.1111/j.1468-3083.2006.01781.x
- Strazzulla LC, Wang EHC, Avila L, et al. Alopecia areata: disease characteristics, clinical evaluation, and new perspectives on pathogenesis. *J Am Acad Dermatol*. 2018;78(1):1–12. doi:10.1016/j.jaad.2017.04.1141
- Divito SJ, Kupper TS. Inhibiting Janus kinases to treat alopecia areata. *Nature Med*. 2014;20(9):989–990. doi:10.1038/nm.3685
- Xing L, Dai Z, Jabbari A, et al. Alopecia areata is driven by cytotoxic T lymphocytes and is reversed by JAK inhibition. *Nature Med*. 2014;20(9):1043–1049. doi:10.1038/nm.3645
- Upadacitinib. *LiverTox: Clinical and Research Information on Drug-Induced Liver Injury*. National Institute of Diabetes and Digestive and Kidney Diseases; 2012.
- Kennedy Crispin M, Ko JM, Craiglow BG, et al. Safety and efficacy of the JAK inhibitor tofacitinib citrate in patients with alopecia areata. *JCI Insight*. 2016;1(15):e89776. doi:10.1172/jci.insight.89776
- Jabbari A, Sansaricq F, Cerise J, et al. An Open-Label Pilot Study to Evaluate the Efficacy of Tofacitinib in Moderate to Severe Patch-Type Alopecia Areata, Totalis, and Universalis. *J Investigative Dermatol*. 2018;138(7):1539–1545. doi:10.1016/j.jid.2018.01.032
- Mackay-Wiggan J, Jabbari A, Nguyen N, et al. Oral ruxolitinib induces hair regrowth in patients with moderate-to-severe alopecia areata. *JCI Insight*. 2016;1(15):e89790. doi:10.1172/jci.insight.89790
- Jabbari A, Dai Z, Xing L, et al. Reversal of Alopecia Areata Following Treatment With the JAK1/2 Inhibitor Baricitinib. *EBioMedicine*. 2015;2(4):351–355. doi:10.1016/j.ebiom.2015.02.015
- Kolez K, Żychowska M, Sawińska E, Reich A. Alopecia Universalis in an Adolescent Successfully Treated with Upadacitinib-A Case Report and Review of the Literature on the Use of JAK Inhibitors in Pediatric Alopecia Areata. *Dermatol therapy*. 2023;13(3):843–856. doi:10.1007/s13555-023-00889-0
- Johnston LA, Poelman SM. Upadacitinib for management of recalcitrant alopecia areata: a retrospective case series. *JAAD case reports*. 2023;35:38–42. doi:10.1016/j.jdc.2023.02.019
- Flora A, Kozera E, Frew JW. Treatment of alopecia areata with the janus kinase inhibitor upadacitinib: a retrospective cohort study. *J Am Acad Dermatol*. 2023;89(1):137–138. doi:10.1016/j.jaad.2022.12.056
- Chiricozzi A, Balato A, Fabbrocini G, et al. Beneficial effects of upadacitinib on alopecia areata associated with atopic dermatitis: a multicenter retrospective study. *J Am Acad Dermatol*. 2023;89(6):1251–1253. doi:10.1016/j.jaad.2023.05.001
- Asfour L, Getsos Colla T, Moussa A, Sinclair RD. Concurrent chronic alopecia areata and severe atopic dermatitis successfully treated with upadacitinib. *Int J Dermatol*. 2022;61(11):e416–e417. doi:10.1111/ijd.16316
- Cantelli M, Martora F, Patruno C, Nappa P, Fabbrocini G, Napolitano M. Upadacitinib improved alopecia areata in a patient with atopic dermatitis: a case report. *Dermatologic Therapy*. 2022;35(4):e15346. doi:10.1111/dth.15346
- Uchida H, Kamata M, Watanabe A, et al. Improvement of severe alopecia areata after 9-month baricitinib treatment followed by subsequent use of upadacitinib in a patient with atopic dermatitis. *J Dermatol*. 2023;50(11):e392–e393. doi:10.1111/1346-8138.16893
- Walls B, Reguiai Z. Dual efficacy of upadacitinib in a patient with concomitant severe atopic dermatitis and alopecia areata. *Ann de dermatologie et de venerologie*. 2023;150(4):281–283. doi:10.1016/j.annder.2023.03.010
- Gambardella A, Licata G, Calabrese G, De Rosa A, Alfano R, Argenziano G. Dual Efficacy of Upadacitinib in 2 Patients With Concomitant Severe Atopic Dermatitis and Alopecia Areata. *Dermatitis*. 2021;32(1s):e85–e86. doi:10.1097/der.0000000000000780

**Clinical, Cosmetic and Investigational Dermatology****Dovepress****Publish your work in this journal**

Clinical, Cosmetic and Investigational Dermatology is an international, peer-reviewed, open access, online journal that focuses on the latest clinical and experimental research in all aspects of skin disease and cosmetic interventions. This journal is indexed on CAS. The manuscript management system is completely online and includes a very quick and fair peer-review system, which is all easy to use. Visit <http://www.dovepress.com/testimonials.php> to read real quotes from published authors.

Submit your manuscript here: <https://www.dovepress.com/clinical-cosmetic-and-investigational-dermatology-journal>