

Factors associated with visual recovery after sub-Tenon injection of triamcinolone acetonide in diabetic macular edema

Hiroko Kawashima
Kenichi Mizukawa
Junichi Kiryu

Department of Ophthalmology,
Kawasaki Medical School,
Okayama, Japan

Background: The purpose of this retrospective chart review was to evaluate factors associated with improvement of visual acuity after a single sub-Tenon injection of triamcinolone acetonide in patients with diabetic macular edema.

Methods: We reviewed the medical records for 63 consecutive eyes with diabetic macular edema treated by sub-Tenon injection of triamcinolone acetonide and assessed at 2 months postoperatively. We evaluated changes in morphology, foveal photoreceptor status, and parafoveal cystic change, and also measured the central retinal thickness and macular volume. The association of these factors with improvement of vision (logarithm of the minimum angle of resolution, logMAR) was investigated.

Results: Eyes were classified as having cystoid macular edema (CME, $n = 52$), serous retinal detachment ($n = 24$), or diffuse diabetic macular edema ($n = 4$). In eyes with CME, the mean logMAR of visual acuity improved significantly ($P = 0.003$) from 0.35 ± 0.31 at baseline to 0.29 ± 0.29 after 2 months. However, there was no significant improvement of visual acuity in the eyes with serous retinal detachment or diffuse diabetic macular edema after sub-Tenon injection of triamcinolone acetonide ($P = 0.549$ and $P = 0.545$, respectively). The central retinal thickness and macular volume were both reduced significantly after sub-Tenon injection of triamcinolone acetonide in eyes with CME and serous retinal detachment. However, improvement of visual acuity in the eyes with CME was not correlated with the reduction of central retinal thickness or macular volume. Parafoveal cystic changes showed significant improvement after sub-Tenon injection of triamcinolone acetonide in eyes with CME. Photoreceptor status was significantly associated with the visual prognosis in eyes with CME, but not in eyes with serous retinal detachment.

Conclusion: Visual acuity improved significantly after sub-Tenon injection of triamcinolone acetonide without photoreceptor recovery in eyes with CME. Improvement of parafoveal cystic changes in the eyes with CME suggests that bipolar cells or their accessory cells might have displayed functional recovery.

Keywords: diabetic macular edema, triamcinolone acetonide, sub-Tenon injection, cystoid macular edema, external limiting membrane

Introduction

Diabetic macular edema is one of the major causes of visual loss in patients with diabetic retinopathy. Although treatment of diabetic macular edema is mainly based on laser photocoagulation,¹ this achieves limited results in patients with diffuse diabetic macular edema caused by extensive breakdown of the inner blood-retinal barrier.² The efficacy of intravitreal injection of bevacizumab,^{3,4} intravitreal injection of triamcinolone acetonide,⁵ and sub-Tenon injection of triamcinolone acetonide⁶⁻⁸ for

Correspondence: Hiroko Kawashima
Department of Ophthalmology,
Kawasaki Medical School,
577 Matsushima, Kurashiki,
Okayama 701-0192, Japan
Tel +818 6462 1111
Fax +818 6463 0923
Email kmsganka@med.kawasaki-m.ac.jp

diabetic macular edema has been reported. The mechanism by which triamcinolone acetonide improves diabetic macular edema is still unknown. Although sub-Tenon injection of triamcinolone acetonide is less effective than intravitreal injection of triamcinolone acetonide,⁹ it is still used for the treatment of diabetic macular edema because of the low incidence of adverse effects,^{10,11} including cataract, glaucoma, and endophthalmitis.

Optical coherence tomography (OCT)¹² can be used to make a diagnosis of diabetic macular edema and to evaluate morphological changes of each retinal layer. Time-domain OCT has been used for morphological classification of diabetic macular edema into three types,^{13–15} which are diffuse retinal thickening, cystoid macular edema (CME), and serous retinal detachment. In this study, we also classified diabetic macular edema into these three types using spectral-domain OCT (SD-OCT), and evaluated the photoreceptor response to sub-Tenon injection of triamcinolone acetonide by assessing the photoreceptor inner and outer segment junction (IS/OS)¹⁶ and external limiting membrane.¹⁷

At the foveal center, we can only analyze the outer retina because there is no ganglion cell layer, inner plexiform layer, or inner nuclear layer. To evaluate the influence of edema caused by breakdown of the inner and outer blood-retinal barrier, we assessed the correlation between visual acuity measured as the logarithm of the minimum angle of resolution (logMAR) value and parafoveal cystic changes, as well as changes in the photoreceptor layer at the fovea.

Accordingly, we analyzed the response of each type of diabetic macular edema to sub-Tenon injection of triamcinolone acetonide based on changes of the photoreceptor status and parafoveal cystic changes 2 months after sub-Tenon injection of triamcinolone acetonide, and evaluated the relationship between visual acuity and these parameters in order to investigate the influence of treatment on the inner and outer retina.

Materials and methods

Sixty-three eyes with diabetic macular edema from 43 patients who received a sub-Tenon injection of triamcinolone acetonide between November 2008 and June 2011 at Kawasaki Medical School Hospital were retrospectively evaluated, including 34 eyes (54.0%) of 24 men and 29 eyes (46.0%) of 19 women. The mean age of the patients was 57.4 ± 14.4 (range 25–90) years. One patient had type 1 diabetes mellitus and the remaining 42 had type 2 diabetes mellitus with diabetic retinopathy; 19 eyes (30.1%) had moderate nonproliferative diabetic retinopathy, 34 eyes

(54.0%) had severe nonproliferative diabetic retinopathy, and 10 eyes (15.9%) had proliferative diabetic retinopathy. Mean HbA_{1c}^{18,19} was $7.3\% \pm 1.4\%$. Fifteen patients (34.9%) received insulin treatment and the remaining 28 patients (65.1%) received other hypoglycemic agents.

Patients who had tractional retinal detachment, epiretinal membrane, vitreous hemorrhage, retinal ischemia, or prior vitrectomy were excluded. Those who had received intravitreal bevacizumab, intravitreal injection of triamcinolone acetonide, sub-Tenon injection of triamcinolone acetonide, or panretinal photocoagulation within the previous 3 months were also excluded,¹⁸ as were patients who had undergone macular focal and/or grid laser photocoagulation.²⁰

All patients underwent a complete eye examination, including measurement of visual acuity with a Japanese standard decimal visual acuity chart, measurement of intraocular pressure, noncontact lens fundus biomicroscopy, and OCT,¹² at each follow-up visit. Best-corrected visual acuity data were converted to logMAR values for statistical analysis.

Initial treatment was a single 1.0 mL sub-Tenon injection of triamcinolone acetonide 40 mg (Kenacort-A®; Bristol-Myers Co, Tokyo, Japan), which was done at the first visit (baseline) under sterile conditions with topical anesthesia. All of the patients were given detailed information about the treatment and provided their written informed consent. The study was performed in accordance with the tenets of the Declaration of Helsinki and with the approval of the institutional review board of Kawasaki Medical School Hospital (approval 826).

Evaluation by SD-OCT (RTVue-100®; Optovue Inc, Fremont, CA) was performed at the first visit and 2 months after sub-Tenon injection of triamcinolone acetonide, using 6 mm line scans centered on the foveal center. Image quality was assessed from the signal strength index,^{21,22} and images with a signal strength index < 40 were excluded. Horizontal and vertical images 6 mm in diameter passing through the fovea were obtained for each patient. Disruption of the IS/OS and external limiting membrane was analyzed within a region 1 mm in diameter (radius 500 μ m) centered on the foveola. Two experienced observers masked to visual acuity reviewed the OCT images, consistent with previous publications.^{23,24}

Central retinal thickness²⁵ was defined as the mean retinal thickness measured from the vitreoretinal interface to the outer boundary of the retinal pigment epithelium at the central macular area (a region 1 mm in diameter [radius 500 μ m] centered on the foveal center) using built-in software (Macula Map 6 mm). Macular volume was also

calculated automatically within the 1 mm diameter area. The foveal outer retinal thickness²⁶ (without cystoid spaces, distance between the vitreoretinal interface and the outer boundary of the sensory retina at the foveola; with cystoid spaces, distance between the base of the cystoid space and the outer boundary of the sensory retina at the foveola) was measured manually using built-in calipers on both vertical and horizontal OCT images, and the values were averaged. Serous retinal detachment was defined as an elevation of the sensory retina, with an optically clear space at the fovea. We also manually measured the height of serous retinal detachment²⁷ (from the outer boundary of the sensory retina to the inner boundary of the retinal pigment epithelium at the foveola) for the subjects in whom serous retinal detachment was recognized. The height of serous retinal detachment was defined as the average distance on vertical and horizontal OCT images.

Within the parafoveal region (radius 500–1500 μm centered on the foveola), we also evaluated cystic changes of the inner nuclear layer, outer plexiform layer, and outer nuclear layer, according to a previously reported method.²⁶ It has been reported that the cystic changes primarily occur in the outer plexiform layer and then extend to involve the other layers.²⁸ We did not differentiate the outer plexiform layer from the outer nuclear layer within the parafovea, because the outer nuclear layer was much thinner than the outer plexiform layer on SD-OCT, and parafoveal cystic changes appeared to affect primarily the outer plexiform layer, in agreement with the findings of pathomorphologic studies.^{29,30} Therefore, we classified parafoveal cystic changes into three patterns; which were cystic changes of the inner nuclear layer, the outer plexiform layer/outer nuclear layer, or the inner nuclear layer + outer plexiform layer/outer nuclear layer.

We classified the microscopic features of macular edema and cystic changes into three types for comparison with logMAR visual acuity data. Within the fovea (radius 500 μm), we evaluated the presence of CME and serous retinal detachment, which were often recognized simultaneously. CME was defined by cystic changes at the fovea and was sometimes associated with minimal serous retinal detachment, while serous retinal detachment was defined by serous detachment of the retina at the fovea and was sometimes associated with localized cystic changes. Diffuse edema was defined as diffuse retinal thickening without CME or serous retinal detachment at the fovea. Eyes of this type usually had good visual acuity, and eyes with a logMAR value ≤ 0.15 were not treated with sub-Tenon injection of triamcinolone acetonide.

For statistical analysis, the results were expressed as the mean \pm standard deviation or as the number and percentage. Differences between two or three groups were assessed by the unpaired *t*-test or by analysis of variance with post hoc multiple comparison by Fisher's least squares difference test after confirming that the data had a normal distribution. The Mann-Whitney U test and the Kruskal-Wallis test were used for nonparametric data. Within-group differences (baseline versus after sub-Tenon injection of triamcinolone acetonide) were assessed using the paired *t*-test or the Wilcoxon signed rank test. McNemar's test was used to compare baseline and post treatment data on the frequency of IS/OS disruption, disruption of the external limiting membrane, and parafoveal cystic changes. Correlations between parameters were investigated by Pearson's correlation coefficient analysis or by calculating Spearman's rank correlation coefficients. In all analyses, $P < 0.05$ was considered to indicate statistical significance. Analyses were performed using StatMate version 3.19 for Windows (Graphpad Software, La Jolla, CA).

Results

Fifty-two eyes (82.5%) had CME, 24 eyes (38.1%) had serous retinal detachment, and four eyes (6.4%) had diffuse diabetic macular edema (without CME or serous retinal detachment) at the fovea. The overall logMAR visual acuity was 0.33 ± 0.30 and there was a weak positive correlation between logMAR visual acuity and central retinal thickness ($418 \pm 111 \mu\text{m}$, $r = 0.256$, $P = 0.043$ by Spearman's analysis). During the follow-up period, no treatable increases in intraocular pressure were observed.

Cystoid macular edema

Mean baseline logMAR visual acuity showed significant improvement after sub-Tenon injection of triamcinolone acetonide (Table 1). In eyes that had CME without serous retinal detachment, mean baseline logMAR visual acuity (0.34 ± 0.34) also improved significantly after sub-Tenon injection of triamcinolone acetonide (0.30 ± 0.32 , $P = 0.043$, Wilcoxon's test).

Mean baseline logMAR visual acuity of eyes that had CME without serous retinal detachment and showed IS/OS disruption was significantly higher (0.42 ± 0.31 , $n = 23$) than that of eyes with an intact IS/OS (0.21 ± 0.35 , $n = 12$, $P = 0.040$, Mann-Whitney U test). After sub-Tenon injection of triamcinolone acetonide, mean logMAR visual acuity of eyes with IS/OS disruption was also significantly higher (0.40 ± 0.34) than that of eyes with an intact IS/OS (0.10 ± 0.15 , $P = 0.006$, Mann-Whitney U test).

Table 1 Changes in logMAR VA, CRT, foveal outer retinal thickness, and macular volume in 52 eyes with CME at the fovea

Parameters				P value [§]
logMAR VA (all 52 eyes)				
Baseline	0.35 ± 0.31			
After STTA	0.29 ± 0.29			0.003
ELM				
	Intact (n = 36)	Disrupted (n = 16) (30.8%)		
Baseline	0.30 ± 0.31	0.47 ± 0.30		0.032
After STTA	0.23 ± 0.28	0.43 ± 0.28		0.001
Δ	-0.07 ± 0.20	-0.04 ± 0.25		0.639
Parafoveal cystic changes				
	INL (n = 9)	OPL/ONL (n = 11)	INL + OPL/ONL (n = 32)	
Baseline	0.48 ± 0.41	0.13 ± 0.21 [#]	0.39 ± 0.29	0.022
After STTA	0.37 ± 0.42	0.13 ± 0.15	0.32 ± 0.27	0.109
Δ	-0.12 ± 0.31	-0.01 ± 0.14	-0.06 ± 0.21	0.508
CRT (μm)				
Baseline	438 ± 108			
After STTA	333 ± 91			<0.001
Foveal outer retinal thickness (μm)				
Baseline	159 ± 75			
After STTA	171 ± 69			0.199
Macular volume (mm³)				
Baseline	0.34 ± 0.09			
After STTA	0.26 ± 0.07			<0.001
Age (years)	57.7 ± 14.4			-

Notes: Foveal outer retinal thickness was measured from the vitreoretinal interface or from the base of the cystoid space to the outer boundary of the sensory retina at the foveola. Values are presented as the mean ± standard deviation. [#]*P* = 0.022 versus INL, INL + OPL/ONL; [§]*P* value determined by the unpaired *t*-test or analysis of variance.

Abbreviations: logMAR, logarithm of the minimum angle of resolution; CRT, central retinal thickness; CME, cystoid macular edema; VA, visual acuity; STTA, sub-Tenon injection of triamcinolone acetonide; ELM, external limiting membrane; IS/OS, photoreceptor inner and outer segment junction; INL, inner nuclear layer; OPL/ONL, outer plexiform layer/outer nuclear layer.

However, there was no significant difference in improvement of visual acuity between eyes with an intact or disrupted IS/OS (*P* = 0.918, Welch's test). In eyes with CME and serous retinal detachment, we did not assess the status of the IS/OS because its integrity was unclear at the fovea.

Disruption of the external limiting membrane was also observed in 16 eyes (30.8%) with CME both at baseline and after sub-Tenon injection of triamcinolone acetonide (Table 1). The mean logMAR visual acuity was significantly higher in eyes with disruption of the external limiting membrane than in eyes with an intact external limiting membrane both at baseline and after sub-Tenon injection of triamcinolone acetonide (*P* = 0.032 and 0.001, respectively), but there was no significant difference in improvement of visual acuity after sub-Tenon injection of triamcinolone acetonide. In eyes that had CME without serous retinal detachment, baseline logMAR visual acuity was also significantly higher when there was disruption of the external limiting membrane (0.51 ± 0.30 , *n* = 10) than when the external limiting membrane was intact (0.28 ± 0.33 , *n* = 25, *P* = 0.034, Mann-Whitney U test). Figure 1A shows that eyes with an intact external limiting membrane had better

visual acuity both at baseline and after sub-Tenon injection of triamcinolone acetonide than eyes with disruption of the external limiting membrane.

The baseline logMAR visual acuity of eyes with parafoveal cystic changes affecting the outer plexiform layer/outer nuclear layer was significantly lower than that of eyes with changes in the inner nuclear layer or inner nuclear layer + outer plexiform layer/outer nuclear layer. At baseline, parafoveal cystic changes of the inner nuclear layer, outer plexiform layer/outer nuclear layer, and inner nuclear layer + outer plexiform layer/outer nuclear layer were seen in nine (17.3%), 11 (21.1%), and 32 (61.5%) eyes, respectively, versus 12 (23.1%), 18 (34.6%), and 16 (30.8%) eyes after sub-Tenon injection of triamcinolone acetonide. Parafoveal cystic changes resolved in six eyes after sub-Tenon injection of triamcinolone acetonide and parafoveal cystic changes at the inner nuclear layer + outer plexiform layer/outer nuclear layer decreased significantly after sub-Tenon injection of triamcinolone acetonide (*P* = 0.002, MacNemar's test).

Central retinal thickness and macular volume both decreased significantly after sub-Tenon injection of

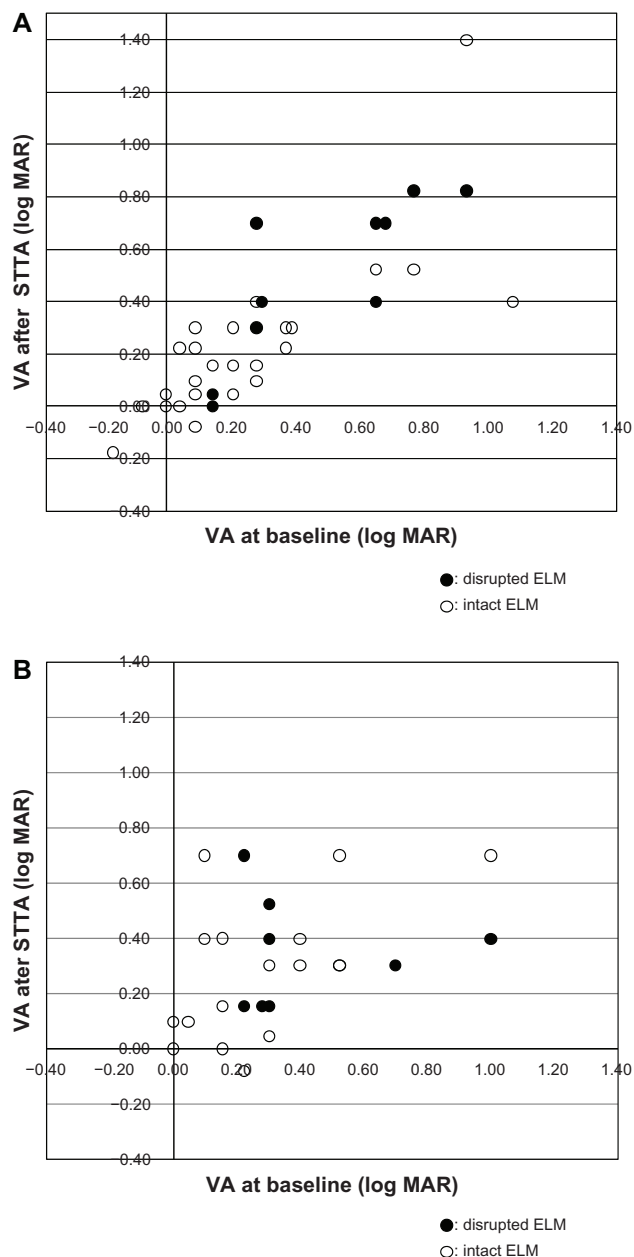


Figure 1 (A) Relationship between visual acuity (log MAR) at baseline and after sub-Tenon injection of triamcinolone acetonide (STTA) for cystoid macular edema (CME) in eyes without serous retinal detachment (SRD). Solid circles indicate the visual acuity (VA) of eyes with disruption of the external limiting membrane (ELM), and open circles indicate the VA of eyes with an intact ELM. The eyes with an intact ELM had better VA both at baseline and after STTA. **(B)** Relationship between visual acuity (log MAR) at baseline and after STTA in eyes with SRD (with or without CME).

Notes: Solid circles indicate the VA of eyes with disruption of the ELM, and open circles indicate the VA of the eyes with an intact ELM. There was no significant difference of VA at baseline or after STTA between the eyes with a disrupted and intact ELM.

Abbreviation: logMAR, logarithm of the minimum angle of resolution.

triamcinolone acetonide, but there was no correlation between visual acuity and central retinal thickness or macular volume ($P = 0.343, 0.344$, and $r = 0.134, 0.134$, respectively). Foveal outer retinal thickness did not change significantly after sub-Tenon injection of triamcinolone acetonide.

Serous retinal detachment

As shown in Table 2, mean logMAR visual acuity did not improve significantly after sub-Tenon injection of triamcinolone acetonide. Disruption of the external limiting membrane was observed in eight eyes (33.3%). Mean logMAR visual acuity was not significantly higher in eyes with disruption of the external limiting membrane than in eyes with an intact external limiting membrane both at baseline and after sub-Tenon injection of triamcinolone acetonide. There was also no significant difference in improvement of logMAR visual acuity after sub-Tenon injection. Figure 1B shows that there was no significant difference in the relationship of logMAR visual acuity either at baseline or after sub-Tenon injection of triamcinolone acetonide between eyes with a disrupted and intact external limiting membrane. Because there was only one eye with parafoveal cystic changes of the inner nuclear layer, we could not perform statistical evaluation. The central retinal thickness and the height of the serous retinal detachment both decreased significantly after sub-Tenon injection of triamcinolone acetonide ($P = 0.003$ and $P < 0.001$, respectively). However, there was no correlation between visual acuity and either central retinal thickness or serous retinal detachment with $P = 0.983, 0.981$, and $r = -0.04, 0.005$, respectively. The foveal outer retinal thickness did not change significantly after the sub-Tenon injection of triamcinolone acetonide.

Diffuse diabetic macular edema

There were only four eyes of this type. Mean logMAR visual acuity was 0.32 ± 0.17 at baseline and did not improve significantly after sub-Tenon injection of triamcinolone acetonide (0.38 ± 0.22 , $P = 0.545$, paired t -test). Disruption of the IS/OS was observed in two eyes, but disruption of the external limiting membrane was not observed. Mean baseline logMAR visual acuity was not significantly higher in eyes with IS/OS disruption (0.34 ± 0.26) than in eyes with an intact IS/OS (0.31 ± 0.16 , $P = 0.904$, unpaired t -test). Central retinal thickness was $299 \pm 67 \mu\text{m}$ at baseline and did not change significantly after sub-Tenon injection of triamcinolone acetonide ($268 \pm 49 \mu\text{m}$, $P = 0.065$, paired t -test).

Relationship between visual acuity and integrity of the external limiting membrane

Figure 1 shows the relationships between visual acuity and integrity of the external limiting membrane in eyes with

Table 2 Changes in logMAR VA, CRT, foveal outer retinal thickness, height of serous retinal detachment, and macular volume in 24 eyes with serous retinal detachment at the fovea

Parameters				P value ^s
logMAR VA (all 24 eyes)				
Baseline	0.32 ± 0.27			
After STTA	0.29 ± 0.22			0.549
ELM				
	Intact (n = 16)	Disrupted (n = 8) (33.3%)		
Baseline	0.27 ± 0.26	0.42 ± 0.28		0.219
After STTA	0.26 ± 0.23	0.35 ± 0.20		0.355
Δ	-0.02 ± 0.25	-0.07 ± 0.24		0.835
Parafoveal cystic changes				
	INL (n = 1)	OPL/ONL (n = 5)	INL + OPL/ONL (n = 18)	
Baseline	0.10	0.31 ± 0.30	0.34 ± 0.27	–
After STTA	0.70	0.22 ± 0.11	0.28 ± 0.23	–
Δ	0.60	-0.09 ± 0.21	-0.05 ± 0.26	–
CRT (μm)				
Baseline	446 ± 137			
After STTA	326 ± 134			0.003
Foveal outer retinal thickness (μm)				
Baseline	147 ± 47			
After STTA	154 ± 55			0.578
Height of SRD (μm)				
Baseline	152 ± 126			
After STTA	46 ± 62			<0.001
Macular volume (mm³)				
Baseline	0.35 ± 0.11			
After STTA	0.26 ± 0.11			0.002
Age (years)	50.9 ± 14.3			–

Notes: Values are presented as the mean ± standard deviation. ^sP value determined by the unpaired t-test or analysis of variance. Foveal outer retinal thickness was measured from the vitreoretinal interface or from the base of the cystoid space to the outer boundary of the sensory retina at the foveola.

Abbreviations: logMAR, logarithm of the minimum angle of resolution; CRT, central retinal thickness; SRD, serous retinal detachment; VA, visual acuity; STTA, sub-Tenon injection of triamcinolone acetonide; ELM, external limiting membrane; IS/OS, photoreceptor inner and outer segment junction; INL, inner nuclear layer; OPL/ONL, outer plexiform layer/outer nuclear layer.

CME and serous retinal detachment at baseline and 2 months after sub-Tenon injection of triamcinolone acetonide. Because the IS/OS was usually unclear and blurred at the fovea in eyes with serous retinal detachment, we could not confirm whether it was disrupted or only difficult to observe. Eyes with an intact external limiting membrane had better visual acuity both at baseline and after the sub-Tenon injection than eyes with disruption of the external limiting membrane (Figure 1A), but there was no significant difference in those relationships between disrupted and intact external limiting membrane.

Discussion

In this study, we found that the mean logMAR visual acuity improved after sub-Tenon injection of triamcinolone acetonide in eyes with CME but not in eyes with serous retinal detachment. This finding is consistent with the results of a previous study using intravitreal injection of triamcinolone acetonide.³¹

In eyes with CME, the baseline visual loss depends on the integrity of the photoreceptor layer.^{23,24} However, we found that visual acuity improved significantly after sub-Tenon injection of triamcinolone acetonide without recovery of IS/OS or disruption of the external limiting membrane, suggesting that different mechanisms may be involved, such as functional improvement of photoreceptors, bipolar cells, and ganglion cells.

Regarding parafoveal cystic changes, the baseline visual acuity of the eyes with parafoveal cystic changes in the outer plexiform layer/outer nuclear layer was significantly better than that of eyes with changes in the inner nuclear layer and inner nuclear layer + outer plexiform layer/outer nuclear layer. This result suggests that localized edema in the outer plexiform layer/outer nuclear layer caused less damage to the inner retina than widespread edema extending from the inner to outer retina. Interestingly, the logMAR visual acuity of eyes with parafoveal cystic changes in the inner nuclear layer was higher than that of eyes with changes in

the outer plexiform layer/outer nuclear layer, suggesting that damage to the inner retina was more severe than damage to the outer retina. There were 32 eyes with parafoveal cystic changes of the inner nuclear layer + outer plexiform layer/outer nuclear layer (61.5%) at baseline and this decreased to 16 eyes (30.8%) at 2 months after sub-Tenon injection of triamcinolone acetonide. There were 52 eyes with parafoveal cystic changes at baseline, decreasing to 46 eyes after 2 months. These results suggest that the widespread edema of the inner retina was improved by 2 months after sub-Tenon injection of triamcinolone acetonide. In other words, disturbance to the function of bipolar cells and other inner retinal cells induced by intracellular and intercellular accumulation of fluid in the inner retina was improved by sub-Tenon injection of triamcinolone acetonide over the short term.

In patients with serous retinal detachment, damage to the photoreceptor layer may be more severe than in patients with diffuse diabetic macular edema because the external limiting membrane is not disrupted in patients with this condition. On the other hand, logMAR visual acuity showed no significant difference between eyes with an intact and disrupted external limiting membrane at baseline, indicating a role of factors other than morphological damage to the photoreceptors. Although central retinal thickness, height of serous retinal detachment, and macular volume all decreased significantly after sub-Tenon injection of triamcinolone acetonide, visual acuity did not improve. This suggests that sub-Tenon injection of triamcinolone acetonide decreases edema in serous retinal detachment, but that photoreceptor damage was not improved, at least in the short term.

This study had several limitations, because it was retrospective, had a small sample size, and was not randomized. The logMAR visual acuity of eyes with diffuse diabetic macular edema was not very high, so most of these eyes did not receive sub-Tenon injection of triamcinolone acetonide even though edema (retinal thickening) was observed. Thus, we cannot deny a bias against enrolling eyes with diffuse diabetic macular edema.

In this study, we analyzed the relationship between parameters of the retinal microarchitecture and baseline visual loss, as well as the relationship between these parameters and visual acuity after sub-Tenon injection of triamcinolone acetonide. The findings made it possible to predict the prognosis of morphological types of diabetic macular edema. Photoreceptor status was significantly associated with visual prognosis in eyes with CME but not in eyes with serous retinal detachment. Visual acuity improved significantly after sub-Tenon injection of triamcinolone acetonide without

photoreceptor recovery in eyes with CME. Improvement of parafoveal cystic changes in the eyes with CME suggests that bipolar cells or their accessory cells might have displaced functional recovery. Eyes with serous retinal detachment showed improvement of edema but little improvement of visual loss. Sub-Tenon injection of triamcinolone acetonide is an effective and relatively safe treatment for eyes with CME due to diabetic macular edema, at least over the short term.

Disclosure

The authors have no individual or family investments, stocks, or business ownership exceeding 1% of a company's worth; consulting, retainers, patents, or other commercial interests in the products or companies described in this article. There is no involvement in the marketing of any product, drug, instrument, or piece of equipment discussed in the manuscript that could cause or be perceived to be a conflict of interest.

References

1. Early Treatment Diabetic Retinopathy Study Research Group. Photocoagulation for diabetic macular edema. Early treatment diabetic retinopathy study report number 1. *Arch Ophthalmol*. 1985;103(12):1796–1806.
2. Zhang X, Bao S, Lai D, Rapkins RW, Gillies MC. Intravitreal triamcinolone acetonide inhibits breakdown of the blood-retinal barrier through differential regulation of VEGF-A and its receptors in early diabetic rat retinas. *Diabetes*. 2008;57(4):1026–1033.
3. Bonini-Filho M, Costa RA, Calucci D, Jorge R, Melo LA, Scott IU. Intravitreal bevacizumab for diabetic macular edema associated with severe capillary loss: one-year results of a pilot study. *Am J Ophthalmol*. 2009;147(6):1022–1030.
4. Song JH, Lee JJ, Lee SJ. Comparison of the short-term effects of intravitreal triamcinolone acetonide and bevacizumab injection for diabetic macular edema. *Korean J Ophthalmol*. 2011;25(3):156–160.
5. Gibran SK, Khan K, Jungkim S, Cleary PE. Optical coherence tomographic pattern may predict visual outcome after intravitreal triamcinolone for diabetic macular edema. *Ophthalmology*. 2007;114(5):890–894.
6. Yalcinbayir O, Geliskan O, Kaderli B, Avci R. Intravitreal versus subtenon posterior triamcinolone injection in bilateral diffuse diabetic macular edema. *Ophthalmologica*. 2011;225(4):222–227.
7. Diabetic Retinopathy Clinical Research Network. Randomized trial of peribulbar triamcinolone acetonide with and without focal photocoagulation for mild diabetic macular edema: a pilot study. *Ophthalmology*. 2007;114(6):1190–1196.
8. Choi YJ, Oh IK, Oh JR, Huh K. Intravitreal versus posterior subtenon injection of triamcinolone acetonide for diabetic macular edema. *Korean J Ophthalmol*. 2006;20(4):205–209.
9. Cellini M, Pazzaglia A, Zamparini E, Leonetti P, Campos EC. Intravitreal vs subtenon triamcinolone acetonide for the treatment of diabetic cystoid macular edema. *BMC Ophthalmol*. 2008;8:5.
10. Ozdek S, Bahceci UA, Gurelik G, Hasanreisoglu B. Posterior subtenon and intravitreal triamcinolone acetonide for diabetic macular edema. *J Diabetes Complications*. 2006;20(4):246–251.
11. Chew EY, Glassman AR, Beck RW, et al. Ocular side effects associated with peribulbar injections of triamcinolone acetonide for diabetic macular edema. *Retina*. 2011;31(2):284–289.
12. Diabetic Retinopathy Clinical Research Network. Relationship between optical coherence tomography-measured central retinal thickness and visual acuity in diabetic macular edema. *Ophthalmology*. 2007;114(3):525–536.

13. Otani T, Kishi S, Maruyama Y. Patterns of diabetic macular edema with optical coherence tomography. *Am J Ophthalmol.* 1999;127(6):688–693.
14. Ozdek SC, Erdinc MA, Gurelik G, Aydin B, Bahceci U, Hasanreisoglu B. Optical coherence tomographic assessment of diabetic macular edema: comparison with fluorescein angiographic and clinical findings. *Ophthalmologica.* 2005;219(2):86–92.
15. Kim BY, Smith SD, Kaiser PK. Optical coherence tomographic patterns of diabetic macular edema. *Am J Ophthalmol.* 2006;142(3):405–412.
16. Shin HJ, Lee SH, Chung H, Kim HC. Association between photoreceptor integrity and visual outcome in diabetic macular edema. *Graefes Arch Clin Exp Ophthalmol.* 2012;250(1):61–70.
17. Uji A, Murakami T, Nishijima K, et al. Association between hyperreflective foci in the outer retina, status of photoreceptor layer, and visual acuity in diabetic macular edema. *Am J Ophthalmol.* 2012;153(4):710–717.
18. Gaucher D, Fortunato P, LeCleire-Collet A, et al. Spontaneous resolution of macular edema after panretinal photocoagulation in florid proliferative diabetic retinopathy. *Retina.* 2009;29(9):1282–1288.
19. Do DV, Shah SM, Sung JU, Haller JA, Nguyen QD. Persistent diabetic macular edema is associated with elevated hemoglobin A1c. *Am J Ophthalmol.* 2005;139(4):620–623.
20. Lee CM, Olk RJ. Modified grid laser photocoagulation for diffuse diabetic macular edema. Long-term visual results. *Ophthalmology.* 1991;98(10):1594–1602.
21. Schuman JS. Spectral domain optical coherence tomography for glaucoma (an AOS thesis). *Trans Am Ophthalmol Soc.* 2008;106:426–458.
22. Garas A, Vargha P, Hollo G. Reproducibility of retinal nerve fiber layer and macular thickness measurement with the RTVue-100 optical coherence tomograph. *Ophthalmology.* 2010;117(4):738–746.
23. Maheshwary AS, Oster SF, Yuson RM, Cheng L, Mojana F, Freeman WR. The association between percent disruption of the photoreceptor inner segment-outer segment junction and visual acuity in diabetic macular edema. *Am J Ophthalmol.* 2010;150(1):63–67.
24. Otani T, Yamaguchi Y, Kishi S. Correlation between visual acuity and foveal microstructural changes in diabetic macular edema. *Retina.* 2010;30(5):774–780.
25. Wolf-Schnurrbusch UE, Ceklic L, Brinkmann CK, et al. Macular thickness measurements in healthy eyes using six different optical coherence tomography instruments. *Invest Ophthalmol Vis Sci.* 2009;50(7):3432–3437.
26. Murakami T, Nishijima K, Sakamoto A, Ota M, Horii H, Yoshimura N. Association of pathomorphology, photoreceptor status, and retinal thickness with visual acuity in diabetic retinopathy. *Am J Ophthalmol.* 2011;151(2):310–317.
27. Gaucher D, Sebah C, Erginay A, et al. Optical coherence tomography features during the evolution of serous retinal detachment in patients with diabetic macular edema. *Am J Ophthalmol.* 2008;145(2):289–296.
28. Tso MO. Pathology of cystoid macular edema. *Ophthalmology.* 1982;89:902–915.
29. Yanoff M, Fine BS, Brucker AJ, Eagle RC Jr. Pathology of human cystoid macular edema. *Surv Ophthalmol.* 1984;28 Suppl:S505–S511.
30. Gass JD. Muller cell cone, an overlooked part of the anatomy of the fovea centralis. Hypotheses concerning its role in the pathogenesis of macular hole and foveomacular retinoschisis. *Arch Ophthalmol.* 1999;117(6):821–823.
31. Shimura M, Yasuda K, Nakazawa T, et al. Visual outcome after intravitreal triamcinolone acetonide depends on optical coherence tomographic patterns in patients with diffuse diabetic macular edema. *Retina.* 2011;31(4):748–754.

Clinical Ophthalmology

Publish your work in this journal

Clinical Ophthalmology is an international, peer-reviewed journal covering all subspecialties within ophthalmology. Key topics include: Optometry; Visual science; Pharmacology and drug therapy in eye diseases; Basic Sciences; Primary and Secondary eye care; Patient Safety and Quality of Care Improvements. This journal is indexed on

Submit your manuscript here: <http://www.dovepress.com/clinical-ophthalmology-journal>

Dovepress

PubMed Central and CAS, and is the official journal of The Society of Clinical Ophthalmology (SCO). The manuscript management system is completely online and includes a very quick and fair peer-review system, which is all easy to use. Visit <http://www.dovepress.com/testimonials.php> to read real quotes from published authors.