

# Stargardt's disease in two Nigerian siblings

Tunji S Oluleye  
Akinsola Sunday Aina  
Tarela Frederick Sarimiye  
Segun Isaac Olaniyan

Retinal and Vitreous Unit, University  
College Hospital, Ibadan, Nigeria

**Abstract:** Stargardt's disease is an inherited macular dystrophy that is transmitted in an autosomal recessive or dominant pattern. The disorder is typically characterized by impairment of central vision, with onset around the first 10–20 years of life. Stargardt's disease is rare in sub-Saharan Africa. This is probably the first reported case in the subregion. We present two siblings with the disease. Presentation, pathophysiology, and management modalities are discussed.

**Keywords:** Stargardt's disease, macular dystrophy, retinal, Nigerians

## Case presentation

A 37-year-old Nigerian trailer mechanic presented to the eye clinic of the University College Hospital, Ibadan, with gradual blurring of vision and difficulty reading and identifying peoples' faces in both eyes over 10 years. Two out of his seven other siblings were reported to have similar complaints. One of the affected siblings presented for examination. The other family members did not show up for evaluation. Ocular examination showed unaided visual acuity of 6/36, N48 in both eyes (OU). There was no significant improvement with refraction. The anterior segment examination was not remarkable. Intraocular pressure was 14 mmHg in both eyes. Dilated funduscopy showed macular atrophy and a beaten-bronze appearance with surrounding yellow white flecks in both eyes (Figure 1). The systemic examination was not remarkable. The patient's sister, OA, a 43-year-old, presented with similar history. Ocular findings included a visual acuity of 6/36 and similar ophthalmoscopic findings (Figure 1). An assessment of Stargardt's macular dystrophy was made.

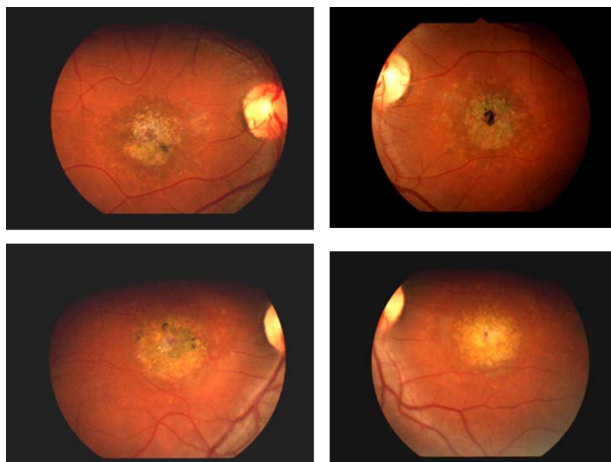
## Discussion

Stargardt's macular degeneration was first reported in 1901 by German ophthalmologist Karl Stargardt, from whom the disease gets its name.<sup>1</sup> The degeneration starts in childhood, but the symptoms may not be apparent until age 30–40 years. Progressive central visual loss occurs due to photoreceptor damage,<sup>2</sup> and color-vision defects are associated with this disease.

## Pathophysiology

The inheritance of Stargardt's disease can be autosomal recessive or dominant.<sup>3</sup> The most common form of Stargardt's disease is the recessive form caused by mutations in the *ABCA4* (formerly ABCR) gene on chromosome 1p21-p13. The genetic

Correspondence: Tunji S Oluleye  
Retinal and Vitreous Unit, Department  
of Ophthalmology, University College  
Hospital, PMB 5116, Ibadan, Nigeria  
Tel +234 802 326 5594  
Fax +234 2 241 3545  
Email t\_oluleye@yahoo.co.uk



**Figure 1** Fundus photos of patient (upper) and sister OA (lower) showing similar macular atrophy with surrounding white flecks.

defect manifests in the visual phototransduction cycle. The mutations cause the production of a dysfunctional protein (the adenosine triphosphate-binding cassette transporter), producing defective transport of *N*-retinylidene-phosphatidylethanolamine from the disk space to the cytoplasm of rods and cones. This leads to a buildup of a toxic metabolite lipofuscin, which then causes the photoreceptor and retinal pigment epithelial cells to degenerate by way of membrane permeability, lysosomal dysfunction, and the detachment of proapoptotic proteins, leading to a cell-death pathway.<sup>4</sup> Central vision loss occurs, while peripheral vision usually is retained.<sup>5</sup>

## Clinical presentation

Symptoms include wavy vision, blind spots, blurriness, impaired color vision, and difficulty adapting to dim lighting. Children first notice difficulty in reading, complaining of gray, black, or hazy spots in the center of their vision. They report that a longer length of time is needed to adjust between light and dark environments. Onset of symptoms usually is between 10 and 20 years of age.<sup>6</sup> Our patients presented with poor central vision dating back 10 years. The duration may be more than 10 years.

On funduscopy, the fovea may be normal or show nonspecific mottling. The classical oval, “snail-slime,” or “beaten-bronze” foveal appearance may be surrounded by yellow-white flecks, which is suggestive of Stargardt’s disease. In some cases, a geographic atrophy with bull’s eye configuration may be seen.<sup>7</sup> The two patients presented with the classical findings, as shown in Figure 1. One needs to bear in mind the phenotypic variability in the *ABCA4* retinopathy, as described by Burke et al.<sup>8</sup>

Investigations supporting the diagnosis include fundus photo/autofluorescence showing loss of posterior pole autofluorescence and fluorescein angiography with a “dark choroid” from blockage of choroidal fluorescence by deposits of lipofuscin.<sup>9</sup> The focal or pattern electroretinogram is preferred to a full-field electroretinogram. Studies showed normal full-field electroretinogram in early stages of the disease.<sup>10</sup> The visual field will show a central scotoma. The Amsler grid is a readily available tool for demonstrating a central scotoma.

Treatment includes supportive measures, such as low-vision devices, photochromic lenses, and genetic counseling. Embryonic stem cell therapy is undergoing consideration.<sup>11</sup> Our patients were reviewed and given low-vision devices. Follow-up retinal examinations will be carried out on the other siblings.

## Conclusion

Stargardt’s disease causes significant visual loss. Families of patients need adequate education and regular exams, especially the younger age-groups. Genetic counseling is important. The so-called rare diseases may be common in sub-Saharan Africa, and detailed retinal examination is important in patients presenting with poor central vision.

## Acknowledgment

We appreciate the Juvenile Open-Angle Glaucoma Study Group for the use of their retinal camera.

## Disclosure

The authors report no conflicts of interest in this work.

## References

1. Stargardt K. Über familiäre, progressive Degeneration in der Makulagegend des Auges. *Graefes Arch Clin Exp Ophthalmol*. 1909;71: 534–550.
2. Allikmets R. Stargardt disease: from gene discovery to therapy. In: Tombran-Tink J, Barnstable CJ, editors. *Retinal Degenerations: Biology, Diagnostics, and Therapeutics*. Totowa (NJ): Humana; 2007:105–118.
3. Zhang K, Kniazeva M, Hutchinson A, Han M, Dean M, Allikmets R. The ABCR gene in recessive and dominant Stargardt diseases: a genetic pathway in macular degeneration. *Genomics*. 1999;60:234–237.
4. Koeneke RK. The gene for Stargardt disease, ABCA4, is a major retinal gene: a mini-review. *Ophthalmic Genet*. 2003;24:75–80.
5. Boon CJF, Klevering BJ, Keunen JEE, Hoyng CB, Theelen T. Fundus autofluorescence imaging of retinal dystrophies. *Vision Res*. 2008;48: 2569–2577.
6. Fishman GA. Electrophysiologic testing in disorders of the retina, optic nerve and visual pathway. In: Fishman GA, editor. *The Electroretinogram*, 2nd ed. Singapore: Foundation of the American Academy of Ophthalmology; 2001:54–56.
7. Zhang K, Garibaldi DC, Kniazeva M, et al. A novel mutation in the ABCR gene in four patients with autosomal recessive Stargardt disease. *Am J Ophthalmol*. 1999;128(6):720–724.

8. Burke TR, Tsang SH, Zernant J, Smith RT, Allikmets R. Familial discordance in Stargardt disease. *Mol Vis*. 2012;18:227–233.
9. Delori FC, Staurenghi G, Arend O, Dorey CK, Goger DG, Weiter JJ. In vivo measurement of lipofuscin in Stargardt's disease – fundus flavimaculatus. *Invest Ophthalmol Vis Sci*. 1995;36:2327–2331.
10. Rotenstreich Y, Fishman GA, Anderson RJ. Visual acuity loss and clinical observations in a large series of patients with Stargardt disease. *Ophthalmology*. 2003;110:1151–1158.
11. Schwartz SD, Hubschman JP, Heilwell G, Franco-Cardenas V, et al. Embryonic stem cell trials for macular degeneration: a preliminary report. *Lancet*. 2012;379:713–720.

### International Medical Case Reports Journal

Dovepress

### Publish your work in this journal

The International Medical Case Reports Journal is an international, peer-reviewed open-access journal publishing original case reports from all medical specialties. Previously unpublished medical posters are also accepted relating to any area of clinical or preclinical science. Submissions should not normally exceed 2,000 words or

4 published pages including figures, diagrams and references. The manuscript management system is completely online and includes a very quick and fair peer-review system, which is all easy to use. Visit <http://www.dovepress.com/testimonials.php> to read real quotes from published authors.

Submit your manuscript here: <http://www.dovepress.com/international-medical-case-reports-journal-journal>