

# Vancomycin-resistant *Staphylococcus hominis* endophthalmitis following cataract surgery

Jun Yeon Won<sup>1</sup>  
Moosang Kim<sup>2</sup>

<sup>1</sup>Department of Otolaryngology,  
School of Medicine, Kangwon National  
University, Chuncheon, Korea;

<sup>2</sup>Department of Ophthalmology,  
School of Medicine, Kangwon  
National University, Chuncheon,  
Korea

**Abstract:** We report a case of acute postoperative endophthalmitis caused by vancomycin-resistant *Staphylococcus hominis*, treated at our hospital. An 80-year-old male presented 2 days after uncomplicated phacoemulsification and posterior chamber intraocular lens implantation, with a 24-hour history of progressive visual loss and redness in the operated (right) eye. On examination, best corrected visual acuity was counting fingers. Anterior segment examination revealed conjunctival injection, chemosis, corneal edema, and hypopyon. B-scan ultrasonography showed vitreous opacification, but no retinal detachment. Acute postoperative endophthalmitis was diagnosed. We performed vitrectomy with vancomycin in the irrigating solution, intraocular lens removal, and silicone oil tamponade. Culture of the vitreous grew *Staphylococcus hominis*. Antibiotic susceptibility testing showed the isolate was sensitive to trimethoprim/sulfamethoxazole and teicoplanin but resistant to ciprofloxacin, moxifloxacin, levofloxacin, cefazolin, and vancomycin. At 3 months, the visual acuity of the silicone oil-treated eye was 20/400.

**Keywords:** endophthalmitis, *Staphylococcus hominis*, vancomycin

## Introduction

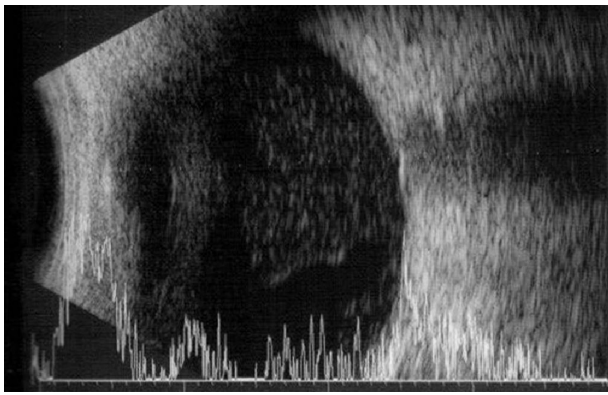
The incidence of infectious endophthalmitis after cataract surgery has been estimated to range from 0.07% to 0.13%.<sup>1</sup> To our knowledge, there are no reports of vancomycin resistance to *Staphylococcus hominis* following endophthalmitis. We report a case of acute postoperative endophthalmitis caused by vancomycin-resistant *S. hominis* treated at our hospital.

## Case report

An 80-year-old male presented 2 days after an uncomplicated phacoemulsification and implantation of a posterior chamber intraocular lens (IOL) (C-flex®; Rayner, Hove, UK), with a 24-hour history of progressive visual loss and redness in the operated (right) eye. Preoperative best-corrected visual acuity (BCVA) was 20/200 in the right eye. Past medical history was significant for hypertension, atrial fibrillation, and prostate cancer. On examination, the BCVA was counting fingers. Anterior segment examination revealed conjunctival injection, chemosis, corneal edema, and hypopyon (2 mm size). B-scan ultrasonography showed vitreous opacification but no retinal detachment (Figure 1). Acute postoperative endophthalmitis was diagnosed.

A vitreous biopsy was performed immediately, with an intravitreal injection of vancomycin 1.0 mg/0.1 mL and ceftazidime 2.25 mg/0.1 mL. Approximately 3 hours after the vitreous biopsy and intravitreal injection of antibiotics, an operating room

Correspondence: Moosang Kim  
Baengnyeong-ro 156, Chuncheon-Si,  
Gangwon-Do Kangwon National  
University Hospital 200-722, Korea  
Tel +82 33 258 2014  
Fax +82 2 966 7340  
Email kimmoo-79@hanmail.net



**Figure 1** B-scan ultrasonography demonstrated vitreous opacities but no retinal detachment.

became available, and we performed 23-gauge pars plana vitrectomy (PPV), using vancomycin in the irrigating solution, and IOL removal with the capsular bag. During the vitrectomy, we saw severe vitreous opacification and a thick exudative membrane that covered the entire retina. After delicate vitrectomy-like shaving, we could see the disc and major vessel arcade faintly. The vitreous humor obtained during the vitrectomy and IOL were sent to the laboratory for smear and culture test. Finally, we finished surgery after fluid–air exchange and silicone oil tamponade.

Culture of the vitreous grew *S. hominis*. Antibiotic susceptibility testing (microbroth dilution MIC test) showed that the isolate was sensitive to trimethoprim/sulfamethoxazole (MIC sensitive [S]  $\leq 2/38$ ) and teicoplanin (S  $\leq 4$ ) but resistant to ciprofloxacin (MIC resistant [R]  $> 2$ ), moxifloxacin (R  $> 4$ ), levofloxacin (R  $> 4$ ), cefazolin (R  $> 8$ ), and vancomycin (R = 8–16). Postoperatively, the patient was treated with 2% teicoplanin eye drops, topical fortified vancomycin, and prednisolone acetate eye drops.

At 3 months, the visual acuity of the silicone oil-treated eye was 20/400.

## Discussion

*S. hominis* is normally found on human skin and is usually harmless but can sometimes cause infections in people with abnormally weak immune systems. Most, if not all, strains are susceptible to penicillin, erythromycin, and novobiocin, but a divergent strain, *S. hominis* subsp. *novobiosepticus* (*SHN*), was found recently.<sup>2</sup> This strain was named so because of its unique resistance to novobiocin and its failure to produce acid aerobically, from trehalose and glucosamine. The *S. hominis* strains are also somewhat resistant to methicillin and gentamicin, and most strains are resistant to

erythromycin, clindamycin, chloramphenicol, trimethoprim/sulfamethoxazole, and ciprofloxacin as well. The SHN strain seems to have thickened cell walls, and this tendency may be the result of a genetic background that also allows for vancomycin resistance.<sup>3</sup>

The SHN is so similar to the original *S. hominis* that a MicroScan system (Dade Behring, West Sacramento, CA, USA) is needed to differentiate the *S. hominis* and SHN in the clinical microbiology laboratory.<sup>4</sup> However, unfortunately, our hospital did not have this equipment.

Another point must be considered. Previously, Iyer et al reported that patients with *S. hominis* endophthalmitis have a subacute onset and are asymptomatic.<sup>5</sup> However, the present case had an acute-onset postoperative endophthalmitis. In our case, a high-virulence organism and *S. hominis* may have presented as a mixed infection, and thus, it is possible that only *S. hominis* was cultured instead of the high-virulence organism.

Asaoka studied the role of coagulase-negative staphylococci (CNS) in outer eye infections.<sup>6</sup> Their results indicated that of 57 strains of CNS, only three (5.3%) strains belonged to *S. hominis*. Furthermore, these CNS were resistant to aminoglycoside and macrolide antibiotics, which are commonly used as eye drops for ocular infectious diseases. However, Asaoka suggested that ocular CNS infections can occur in immunologically compromised host patients.

At 3 months, the visual acuity of the silicone oil-treated eye was 20/400. Although rare, we report that acute-onset, postoperative *S. hominis* endophthalmitis can occur in an immunocompetent patient.

## Conclusion

We present a case of acute-onset, postoperative vancomycin-resistant *S. hominis* endophthalmitis managed with intravitreal antibiotics injection, PPV, IOL removal and silicone oil tamponade.

## Disclosure

The authors report no conflicts of interest in this work.

## References

- Jager RD, Aiello LP, Patel SC, Cunningham ET Jr. Risks of intravitreal injection: a comprehensive review. *Retina*. 2004;24(5):676–698.
- Kloos WE, George CG, Olgiate JS, et al. *Staphylococcus hominis* subsp. *novobiosepticus* subsp. nov, a novel trehalose- and N-acetyl-D-glucosamine-negative, novobiocin- and multiple-antibiotic-resistant subspecies isolated from human blood cultures. *Int J Syst Bacteriol*. 1998;48 Pt 3:799–812.
- Fitzgibbon JE, Nahvi MD, Dubin DT, John JF Jr. A sequence variant of *Staphylococcus hominis* with a high prevalence of oxacillin and fluoroquinolone resistance. *Res Microbiol*. 2001;152(9):805–810.

4. Palazzo IC, d'Azevedo PA, Secchi C, Pignatari AC, Darini AL. *Staphylococcus hominis* subsp. *novobiosepticus* strains causing nosocomial bloodstream infection in Brazil. *J Antimicrob Chemother.* 2008;62(6):1222–1226.
5. Iyer MN, Wirostko WJ, Kim SH, Simons KB. *Staphylococcus hominis* endophthalmitis associated with a capsular hypopyon. *Am J Ophthalmol.* 2005;139(5):930–932.
6. Asaoka I. Role of *Staphylococcus epidermidis* in outer eye infections. *Nihon Ganka Gakkai Zasshi.* 1989;93(3):351–357. Japanese.

### Clinical Ophthalmology

Dovepress

### Publish your work in this journal

Clinical Ophthalmology is an international, peer-reviewed journal covering all subspecialties within ophthalmology. Key topics include: Optometry; Visual science; Pharmacology and drug therapy in eye diseases; Basic Sciences; Primary and Secondary eye care; Patient Safety and Quality of Care Improvements. This journal is indexed on

Submit your manuscript here: <http://www.dovepress.com/clinical-ophthalmology-journal>

PubMed Central and CAS, and is the official journal of The Society of Clinical Ophthalmology (SCO). The manuscript management system is completely online and includes a very quick and fair peer-review system, which is all easy to use. Visit <http://www.dovepress.com/testimonials.php> to read real quotes from published authors.