

Carotid ultrasound assessment of patients with coronary artery disease: a useful index for risk stratification

Roman Komorovsky
Alessandro Desideri

Cardiovascular Research Foundation,
S Giacomo Hospital, Castelfranco
Veneto, Italy

Abstract: Carotid disease is a common finding in patients with coronary artery disease (CAD) and its presence is associated with worse clinical outcomes. Intima-media thickness provides incremental value over traditional risk factors in predicting cardiovascular events; however, it does not predict the absence of CAD or its extent and severity. The presence of carotid plaques is associated with an increased risk of cardiovascular events in patients with CAD regardless of the treatment strategy (medical therapy alone or myocardial revascularization). Hence, we advocate the screening of patients with diagnosed CAD for carotid atherosclerosis. The prognostic impact of ultrasound characteristics of carotid plaques on cardiovascular outcomes of patients with CAD remains controversial.

Keywords: intima-media thickness, carotid plaques, coronary artery disease, ultrasound

Introduction

The coexistence of carotid and coronary artery disease (CAD) is a challenge to cardiologists, vascular and cardiothoracic surgeons, and neurologists. Patients with coexistent narrowing of carotid and coronary arteries represent a particularly high-risk group and to date there has been no consensus with regard to their management. Carotid endarterectomy in these patients is associated with an increased incidence of perioperative myocardial infarction (Biller et al 1998), and coronary artery bypass grafting is accompanied by an elevated risk of neurological injury (Jones et al 1984).

Epidemiological data

While in a general adult population the prevalence of carotid stenosis approaches 4% (Mathiesen, Joakimsen, et al 2001), in patients with coronary artery disease it can reach 30%–70% (Kallikazaros et al 1999; Held et al 2001; Komorovsky et al 2004; Lombardo et al 2004). For those undergoing coronary artery bypass grafting, the prevalence of >50% narrowing of at least one internal carotid artery is thought to be around 20%, and >70% carotid stenosis is found in 2%–12% of cases (Schwartz et al 1995; Evangelopoulos et al 2000).

Carotid artery disease as a marker of increased risk of cardiovascular events

Carotid artery disease, even in its preclinical stage (intima-media thickness [IMT] ≥ 1 mm and non-obstructive [$< 50\%$] carotid plaques), has been associated with CAD and an increased risk of cardiovascular events.

Correspondence: Roman Komorovsky
Cardiovascular Research Foundation,
Ospedale S Giacomo, 31033
Castelfranco Veneto (TV), Italy
Tel +39 0423 732 306
Fax +39 0423 732 301
Email roman_komor@yahoo.com

Intima-media thickness

For the far (posterior) wall of the carotid artery, this index can be easily measured by ultrasound as the distance between the leading edge of the luminal echo (first bright line) and the leading edge of the media-adventitia echo (second bright line). For the near (anterior) wall, IMT is measured as the distance between the trailing edge of the first bright line and the trailing edge of the second bright line (Pignoli et al 1986; Iglesias del Sol 2001). In clinical trials, IMT has been used as a surrogate end point for evaluating the progression of atherosclerosis (de Groot et al 1998; Pitt et al 2000).

The use of IMT for assessment of cardiovascular event risk has, however, a number of limitations. Although IMT has been shown to be a strong predictor of incident myocardial infarction in overall population aged ≥ 55 years (van der Meer et al 2004), and there is a good correlation between increased IMT and the presence of CAD, IMT is not a good predictor of its extent and severity and cannot predict the absence of significant CAD. Furthermore, IMT does not appear to have predictive value in populations with high prevalence of CAD, or in younger age groups where the prevalence is low (Adams et al 1995; Held et al 2001). Therefore, the American Heart Association Prevention V Conference (Greenland et al 2000) did not recommend routine IMT measurements in patients with low or high risk of cardiovascular disease, but stated that this may be appropriate in patients at intermediate risk of CAD (based on Framingham risk assessment). This means that if in a patient at intermediate risk of coronary event (6%–20% risk in 10 years) the carotid IMT of ≥ 1 mm is detected, he/she may be stratified as a high-risk patient and receive high-risk treatment accordingly.

The assessment of IMT in various laboratories is not standardized. In some studies only the common carotid artery IMT has been considered (Held et al 2001; Cuomo et al 2002), in others, along with the common carotid artery IMT, the IMT in carotid bifurcation (bulb), and internal carotid artery has been measured (Iglesias del Sol et al 2001). Thereafter the results have been either averaged (Haluska et al 2004; Yildiz et al 2004) or the greatest IMT values have been used for analysis (Iglesias del Sol A et al 2001; Crouse et al 2002). These methodological differences limit the interpretation of results. Moreover, a relatively large proportion of variation in repeated measurements over time is likely to be due to measurement error. Most studies suggest, however, that the common carotid artery is the

preferable site for the measurement of IMT because it is tubular and can be aligned perpendicular to the transducer beam. Reproducibility and yield of the common carotid artery IMT is therefore superior to that of IMT of the carotid bifurcation or internal carotid artery (Howard et al 1993; Crouse et al 1995).

Recent consensus (Touboul et al 2004) concluded that there is no need “to treat” IMT values or to monitor IMT values in individual patients. IMT measurements are not recommended to predict events on an individual level, but may be used in clinical trials as a surrogate end point on a group level. The recommended standardized methods for IMT measurements are supposed to improve the power of studies incorporating IMT values and to facilitate the merging of databases for meta-analyses.

Carotid plaques

Carotid plaques in various studies have been defined either as distinct areas “with an IMT exceeding twice that of neighboring sites” (Held et al 2001, p 64) or “focal widenings of the vessel wall of $> 50\%$ relative to adjacent segments” (Hollander et al 2002, p 2873), or a “lesion with a focal IMT of 1.1 mm or more, with a localized protrusion of the vessel wall into the lumen (Honda et al 2004, p 1178). In another study, a cut-off point of 1.3 mm was used for a focal thickening of the IMT complex to be considered as a plaque (Kablak-Ziembicka et al 2004). According to the consensus statement (Touboul et al 2004), a plaque is defined as a focal structure that encroaches into the arterial lumen of at least 0.5 mm or 50% of the surrounding IMT value or demonstrates a thickness of ≥ 1.5 mm as measured from the media-adventitia interface to the intima-lumen interface. Obstructive plaques (causing $> 50\%$ lumen diameter narrowing) cause blood flow acceleration at the stenosis site and a peak systolic velocity > 125 cm/sec in the internal carotid artery is an indicator of its hemodynamically significant narrowing (Grant et al 2003). The presence of obstructive carotid plaques is associated with increasing risk of cerebrovascular events by atheroembolism, as the severity of the stenosis increases (NASCET 1991), and increased risk of cardiac death and myocardial infarction (Held et al 2001).

The risk associated with the presence of non-obstructive carotid plaques remains a controversial problem. Like IMT, these plaques reflect the overall atherosclerotic burden, and, as compared with IMT, better predict cardiovascular death and nonfatal myocardial infarction (Held et al 2001).

Table 1 Ultrasonographic classifications of carotid plaques

Gray-Weale (1988) and Geroulakos (1993)	Johnson (1985)	Reilly (1983)	ECPS (1995)
Type 1: predominantly echolucent with a thin echorich cap	Soft (low level echoes)	Heterogeneous (high, medium, and low level echoes)	Echolucent heterogeneous
Type 2: dominantly echolucent lesions with small areas of echogenicity	Soft (low level echoes)	Heterogeneous (high, medium, and low level echoes)	Echolucent heterogeneous
Type 3: dominantly echogenic lesions with small (<25%) areas of echolucency	Dense (high level echoes)	Heterogeneous (high, medium, and low level echoes)	Intermediate
Type 4: echorich homogeneous	Dense (high level echoes)	Homogeneous (medium or high level echoes)	Echorich homogeneous
Type 5: plaques with acoustic shadowing caused by calcification	Calcified	Homogeneous (medium or high level echoes)	Echorich homogeneous

The risk of ischemic events related to carotid plaques is also much associated with their histological morphology. Plaque echogenicity as assessed by B-mode ultrasound has been shown to correlate with histological findings. Echolucent plaques consist of a thin fibrous echogenic cap overlying a lipid core with high macrophage content and, sometimes, zones of hemorrhage. When the cap is thinner than 5–10 μ it may not be detected by ultrasound. Echogenic plaques consist of dense fibrous tissue and their echogenicity increases with increasing amounts of collagen. The presence of calcifications results in high echoes in corresponding areas with acoustic shadowings (Goes et al 1990; ECPS Group 1995). Several classifications have been proposed to group carotid plaques according to their appearance on ultrasound (Table 1).

Echolucent and heterogeneous plaques are described as the most vulnerable, rupture-prone lesions and have been associated with neurovascular symptoms and an increased risk of ischemic stroke (Polak et al 1998; Grønholdt, Norderstgaard, et al 2001; Mathiesen, Bønaa, et al 2001; Tegos et al 2001). Echogenic plaques are most frequently associated with asymptomatic status (AbuRahma et al 2002). In a general population, the ratio of subjects with echolucent plaques to subjects with echogenic plaques is approximately 1:2 (Joakimsen et al 1999; Zureik et al 2003). Echolucent plaques dominate in patients with symptomatic carotid disease, while asymptomatic patients usually have echogenic plaques (Steffen et al 1989). It should be noted, however, that carotid plaques are dynamic structures that change in composition over a period of time. Patients with recent symptoms are more likely to have echolucent plaques compared with patients with earlier symptoms (ECPS 1995).

In patients evaluated for chest pain and in those with acute coronary syndromes, there is a stepwise increase in

the number with carotid disease with the increasing severity of CAD (Kallikazaros et al 1999; Komorovsky et al 2005). A gradual increase in the proportion of echogenic carotid plaques was observed with the increase of the extent of CAD, while the proportion of echolucent carotid plaques remained unchanged (Figure 1) (Komorovsky et al 2005). This could reflect the natural development of more organized and calcified plaques in more advanced stages of atherosclerosis.

Recently, Lombardo et al (2004) classified carotid plaques as complex (those with irregular surface and/or heterogeneous echogenicity involving >50% of the plaque area, including echolucent, mobile, and ulcerated plaques) and simple (plaques with smooth surface and a homogeneous hyperechoic structure involving >50% of the plaque area). They demonstrated that complex carotid plaques are more prevalent in patients with unstable angina pectoris

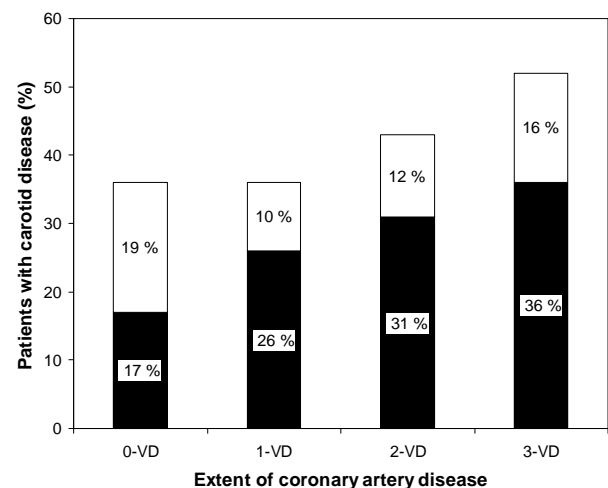


Figure 1 Distribution of echolucent and echogenic carotid plaques according to the extent of coronary artery disease in the entire study population. Data adapted from Komorovsky et al (2005). **Abbreviations:** VD, vessel disease. **NOTE:** black bars = echogenic carotid plaque group; white bars = echolucent carotid plaque group.

compared with patients with stable angina. As in a general population, the ratio between complex and simple carotid plaques in patients with CAD is approximately 1:2 (Lombardo et al 2004); however, this ratio seems to grow with the increasing instability of patients due to the increased prevalence of complex carotid plaques (Lombardo et al 2004). These results are complementary to the recent findings, which showed that acute coronary syndrome patients with multiple complex coronary plaques had more either echolucent or echogenic carotid plaques and carotid calcifications compared with patients who only had a single complex coronary plaque (Kato et al 2003).

The prognostic relevance of ultrasound characteristics of carotid plaques for cardiovascular events is somewhat controversial. In one of the studies it was demonstrated that in patients undergoing endarterectomy because of >50% or >70% stenosis, the echolucency of the removed carotid plaques was associated with the risk of myocardial infarction and stroke combined (Liapis et al 2002). Another study showed that a combined end point of death, myocardial infarction, or stroke was significantly more frequent in hypertensive patients with echolucent carotid plaques compared with comparable patients with echo-rich carotid plaques. Moreover, the multiple risk intervention program was beneficial in patients with echolucent carotid plaques, but not in those with echogenic carotid plaques (Schmidt et al 2003). Finally, Honda et al (2004) showed that echolucent carotid plaques predict coronary plaque complexity and the development of future coronary complications in patients with stable coronary artery disease. These studies, however, have some potential limitations. In the studies of Liapis et al (2002) and Schmidt et al (2003), the combined end points were used, and therefore, conclusions with regard to cardiovascular events only could not be made. Honda et al (2004) compared patients with echolucent carotid plaques with patients without carotid disease and patients with echogenic carotid plaques taken together. Such combination masked the risk associated with echogenic carotid plaques. Moreover, the overall prevalence of carotid disease in stable CAD patients was very high (79%), as was the prevalence of echolucent carotid plaques (52%).

Conversely, it has been shown that in patients with acute coronary syndromes, either echogenic or echolucent carotid plaques are associated with lower event-free survival regardless of the treatment strategy (conservative treatment or myocardial revascularization) (Komorovsky et al 2005). However, the presence of echogenic carotid plaques appeared to be an independent predictor of cardiac death

and nonfatal myocardial infarction in these patients. Echogenic carotid plaques, when associated with complex coronary lesions, were associated with a particularly poor long-term event-free survival (Komorovsky et al 2005). One of the links that explain the associations between echogenic carotid plaques and cardiac events might be increased arterial stiffness, which is observed in patients with echogenic carotid plaques (Zureik et al 2003) and which, by itself, is associated with adverse cardiovascular outcomes (Boutouyrie et al 2002). Echogenic carotid plaques might also reflect the total burden of calcium and of atherosclerosis, including that of the coronary arteries (Nossen et al 2001). The amount of coronary calcium and the fast progression of coronary calcifications, revealed by electron beam tomographic and multidetector scanning, has been previously associated with a greater risk of cardiovascular events (O'Rourke et al 2000; Keelan et al 2001). Finally, carotid calcifications may also reflect a diffuse coronary disease. The extent of non-obstructive atherosclerotic lesions has been found to be a strong predictor of coronary events, independent of severity and the number of flow-limiting coronary lesions (Bigi et al 2003).

These data, however, do not completely resolve the existing controversy. Recent observations have suggested that inflammation may be a possible link between coronary and carotid plaque instability (Lombardo et al 2004). Complex carotid plaques were detected more frequently in patients with CAD and elevated serum C-reactive protein (>3 mg/L) compared with patients with normal C-reactive protein levels. It may be that the degree of generalized inflammation, as reflected by C-reactive protein level, determines the echolucent plaque instability and the associated adverse outcomes. Moreover, higher interleukin-6 and high-sensitivity C-reactive protein levels have been recently shown to be associated with lower echogenicity of carotid plaques (Yamagami et al 2004). These data are in contradiction with the previous studies, which failed to demonstrate significant associations between echolucency of carotid plaques and acute phase reactants such as fibrinogen (Kofoed et al 2003), C-reactive protein, orsomucoid (Grønholdt, Silesen, et al 2001), and intracellular adhesion molecule-1 (Okulla et al 2002). Although the acute phase reactants reflect the general inflammation and may not be significantly modulated by changes in the carotid arteries (Grønholdt, Silesen, et al 2001), we suggest that echolucent plaques in patients with inflammation might have a different risk than echolucent plaques without evident signs of inflammation. In support of this, there is increasing

evidence that acute phase reactants, especially C-reactive protein, are not just the markers of inflammation but also active participants of the formation process of atherosclerotic plaques (Zwaka et al 2001; Fu and Borensztajn 2002).

Clinical implications

A high prevalence of carotid disease in patients with CAD and the associated risks imply that screening for carotid atherosclerosis should be considered in all patients with diagnosed CAD. The detection of carotid disease may modify treatment strategy of these patients; eg, more aggressive medical therapy in case of subclinical carotid atherosclerosis, combined coronary and carotid surgery for patients with critical stenoses in both territories, and staged operations.

Conclusions

1. Intima-media thickness may be used for cardiovascular risk assessment in patients at intermediate risk of CAD.
2. The presence of carotid plaques is associated with an increased risk of cardiovascular events in patients with CAD, regardless of the treatment strategy (medical therapy alone or myocardial revascularization).
3. The prognostic relevance of ultrasound characteristics of carotid plaques in patients with CAD, possibly in association with inflammatory markers, needs to be further clarified.

References

- AbuRahma AF, Wulu JT, Crotty B. 2002. Carotid plaque ultrasonic heterogeneity and severity of stenosis. *Stroke*, 33:1772–5.
- Adams M, Nakagomi A, Keech A, et al. 1995. Carotid intima-media thickness is only weakly correlated with the extent and severity of coronary artery disease. *Circulation*, 92:2127–34.
- Bigi R, Cortigiani L, Colombo P, et al. 2003. Prognostic and clinical correlates of angiographically diffuse non-obstructive coronary lesions. *Heart*, 89:1–5.
- Biller J, Feinberg WM, Castaldo JE, et al. 1998. Guidelines for carotid endarterectomy: a statement for healthcare professionals from a Special Writing Group of the Stroke Council, American Heart Association. *Circulation*, 97:501–9.
- Boutouyrie R, Tropeano AI, Asmar R, et al. 2002. Aortic stiffness is an independent predictor of primary coronary events in hypertensive patients: a longitudinal study. *Hypertension*, 39:10–15.
- Crouse JR III, Craven TE, Hagaman AP, et al. 1995. Association of coronary disease with segment-specific intimal-medial thickening of the extracranial carotid artery. *Circulation*, 92:1141–7.
- Crouse JR III, Tang R, Espeland MA, et al. 2002. Associations of extracranial carotid atherosclerosis progression with coronary status and risk factors in patients with and without coronary artery disease. *Circulation*, 106:2061–6.
- Cuomo S, Guarini P, De Michele M, et al. 2002. Increased carotid intima-media thickness in children-adolescents with a parental history of premature myocardial infarction. *Eur Heart J*, 23:1345–50.
- de Groot E, Jukema JW, Montauvan van Swijndregt AD, et al. 1998. B-mode ultrasound assessment of pravastatin treatment effect on carotid and femoral artery walls and its correlations with coronary arteriographic findings: a report of the Regression Growth Evaluation Stain Study (REGRESS). *J Am Coll Cardiol*, 31:1561–7.
- [ECPS] European Carotid Plaque Study Group. 1995. Carotid artery plaque composition—relationship to clinical presentation and ultrasound B-mode imaging. *Eur J Vasc Endovasc Surg*, 10:23–30.
- Evangelopoulos N, Trenz MT, Beckman A, et al. 2000. Simultaneous carotid endarterectomy and coronary artery bypass grafting in 313 patients. *Cardiovasc Surg*, 8:31–40.
- Fu T, Borensztajn J. 2002. Macrophage uptake of low-density lipoprotein bound to aggregated C-reactive protein: possible mechanism of foam-cell formation in atherosclerotic lesions. *Biochem J*, 366:195–201.
- Geroulakos G, Ramaswami G, Nicolaidis A, et al. 1993. Characterization of symptomatic and asymptomatic carotid plaques using high-resolution real-time ultrasonography. *Br J Surg*, 80:1274–7.
- Goes E, Janssens W, Mailliet B, et al. 1990. Tissue characterization of atheromatous plaques. Correlation between ultrasound image and histological findings. *J Clin Ultrasound*, 18:611–17.
- Grant EG, Benson CB, Moneta GL, et al. 2003. Carotid artery stenosis: gray-scale and Doppler US diagnosis—Society of Radiologists in Ultrasound Consensus Conference. *Radiology*, 229:340–6.
- Gray-Weale AC, Graham JC, Burnett JR, et al. 1988. Carotid artery atheroma: comparison of preoperative B-mode ultrasound appearance with carotid endarterectomy specimen pathology. *J Cardiovasc Surg*, 29:676–81.
- Greenland P, Abrams J, Aurigemma GP, et al. 2000. Prevention Conference V: beyond secondary prevention: noninvasive tests of atherosclerotic burden: Writing Group III. *Circulation*, 101:E16–22.
- Grønholdt ML, Norderstgaard BG, Schroeder TV, et al. 2001. Ultrasonic echolucent carotid plaques predict future strokes. *Circulation*, 104:68–73.
- Grønholdt ML, Silesen H, Wiebe BM, et al. 2001. Increased acute phase reactants are associated with levels of lipoproteins and increased carotid plaque volume. *Eur J Vasc Endovasc Surg*, 21:227–34.
- Haluska BA, Fathi R, Jeffries L, et al. 2004. Noninvasive tests for arterial structure, function, and compliance: do they identify risk or diagnose disease? *J Am Soc Echocardiogr*, 17:195–204.
- Held C, Hjemdahl P, Eriksson SV, et al. 2001. Prognostic implications of intima-media thickness and plaques in the carotid and femoral arteries in patients with stable angina pectoris. *Eur Heart J*, 22:62–72.
- Hollander M, Bots ML, Iglesias del Sol A. 2002. Carotid plaques increase the risk of stroke and subtypes of cerebral infarction in asymptomatic elderly. The Rotterdam Study. *Circulation*, 105:2872–7.
- Honda O, Sugiyama S, Kugiyama K, et al. 2004. Echolucent carotid plaques predict future coronary events in patients with coronary artery disease. *J Am Coll Cardiol*, 43:1177–84.
- Howard G, Sharrett AR, Heiss G, et al. 1993. Carotid artery intima-media thickness distribution in general populations as evaluated by B-mode ultrasound. ARIC investigators. *Stroke*, 24:1297–304.
- Iglesias del Sol A, Moons KGM, Hollander M, et al. 2001. Is carotid intima-media thickness useful in cardiovascular disease assessment? The Rotterdam Study. *Stroke*, 32:1532–8.
- Joakimsen O, Bønaa KH, Mathiesen EB, et al. 2000. Prediction of mortality by ultrasound screening of a general population for carotid stenosis. The Tromsø Study. *Stroke*, 31:1871–6.
- Joakimsen O, Bønaa KH, Stensland-Bugge E, et al. 1999. Age and sex differences in the distribution and ultrasound morphology of carotid atherosclerosis. The Tromsø Study. *Arterioscler Thromb Vasc Biol*, 19:3007–13.
- Johnson JM, Kennelly MM, Decesare D. 1985. Natural history of asymptomatic carotid plaque. *Arch Surg*, 120:1010–12.
- Jones E, Craver J, Michalic R, et al. 1984. Combined carotid and coronary artery operations: when are they necessary? *J Thorac Cardiovasc Surg*, 87:7–16.

- Kablak-Ziembicka A, Tracz W, Przewlocki T, et al. 2004. Association of increased carotid intima-media thickness with the extent of coronary artery disease. *Heart*, 90:1286–90.
- Kallikazaros I, Tsioufis C, Sideris S, et al. 1999. Carotid artery disease as a marker for the presence of severe coronary artery disease in patients evaluated for chest pain. *Stroke*, 30:1002–7.
- Kato M, Dote K, Habara S, et al. 2003. Clinical implications of carotid artery remodelling in acute coronary syndrome: ultrasonographic assessment of positive remodelling. *J Am Coll Cardiol*, 42:1026–32.
- Keelan PC, Bielak LF, Ashai K, et al. 2001. Long-term prognostic value of coronary calcification detected by electron-beam computed tomography in patients undergoing coronary angiography. *Circulation*, 104:412–17.
- Kofoed SC, Wittrup HH, Sillesen H, et al. 2003. Fibrinogen predicts ischaemic stroke and advanced atherosclerosis but not echolucent, rupture-prone carotid plaques. The Copenhagen City Heart Study. *Eur Heart J*, 24:567–76.
- Komorovsky R, Desideri A, Coscarelli S, et al. 2004. Impact of carotid arterial narrowing on outcomes of patients with acute coronary syndromes. *Am J Cardiol*, 93:1552–5.
- Komorovsky R, Desideri A, Coscarelli S, et al. 2005. Predictive value of associations between carotid and coronary artery disease in patients with acute coronary syndromes. *Am J Cardiol*, 95:116–19.
- Liapis CD, Kasikis JD, Dimitroulis DA, et al. 2002. The impact of the carotid plaque type on restenosis and future cardiovascular events: a 12-year prospective study. *Eur J Vasc Endovasc Surg*, 24:239–44.
- Lombardo A, Biasucci LM, Lanza GA, et al. 2004. Inflammation as a possible link between coronary and carotid plaque instability. *Circulation*, 109:3158–63.
- Mathiesen EB, Bønaa KH, Joakimsen O, et al. 2001. Echolucent plaques are associated with high risk of ischemic cerebrovascular events in carotid stenosis: the Tromsø Study. *Circulation*, 103:2171–5.
- Mathiesen EB, Joakimsen O, Bønaa KH, et al. 2001. Prevalence and risk factors associated with carotid artery stenosis: the Tromsø Study. *Cerebrovasc Dis*, 12:44–50.
- [NASCET] North American Symptomatic Carotid Endarterectomy Trial Collaborators. 1991. Beneficial effect of carotid endarterectomy in symptomatic patients with high-grade stenosis. *N Engl J Med*, 325:445–53.
- Nossen J, Vierzigmann T, Weiss W, et al. 2001. Kalzifizierte Plaques der extrakraniellen hirnersorgenden Gefäße im Vergleich mit traditionellen Risikofaktoren als Prediktor für relevante Koronararterienstenosen. *Herz*, 26:454–60.
- Okulla T, Gass S, Böhme K, et al. 2002. Circulating adhesion molecules in patients with internal carotid artery stenosis. *Cerebrovasc Dis*, 14: 9–14.
- O'Rourke RA, Brundage BH, Froehlicher VF, et al. 2000. American College of Cardiology/American Heart Association Expert Consensus Document on electron-beam computed tomography for the diagnosis and prognosis of coronary artery disease. *Circulation*, 101:126–40.
- Pignoli P, Tremoli E, Poli A, et al. 1986. Intimal plus medial thickness of the arterial wall: a direct measurement with ultrasound imaging. *Circulation*, 74:1399–406.
- Pitt B, Byington RP, Furberg CD, et al. 2000. Effect of amlodipine on the progression of atherosclerosis and the occurrence of clinical events. *Circulation*, 102:1503–10.
- Polak JF, Shemanski L, O'Leary DH, et al. 1998. Hypoechoic plaque at US of the carotid artery: an independent risk factor for incident stroke in adults aged 65 years or older: Cardiovascular Health Study. *Radiology*, 208:649–54.
- Reilly LM, Lusby RJ, Hughes L, et al. 1983. Carotid plaque histology using real-time ultrasonography: clinical and therapeutic implications. *Am J Surg*, 146:188–93.
- Schmidt C, Fagerberg B, Wirkstand J, et al; RIS Study Group. 2003. Multiple risk factor intervention reduces cardiovascular risk in hypertensive patients with echolucent plaques in the carotid artery. *J Intern Med*, 253:430–8.
- Schwartz LB, Bridgman AH, Kieffer RW, et al. 1995. Asymptomatic carotid artery stenosis and stroke in patients undergoing cardiopulmonary bypass. *J Vasc Surg*, 21:359–64.
- Steffen CM, Gray-Weale AC, Byrne KE, et al. 1989. Carotid artery atheroma: ultrasound appearance in symptomatic and asymptomatic vessels. *Aust N J Surg*, 59:529–34.
- Tegos TJ, Kalomiris KJ, Sabetai MM, et al. 2001. Significance of sonographic tissue and surface characteristics of carotid plaques. *Am J Neuroradiol*, 22:1605–12.
- Touboul PJ, Hennerici MG, Meairs S, et al. 2004. Mannheim intima-media thickness consensus. *Cerebrovasc Dis*, 18:346–9.
- van der Meer IM, Bots LM, Hofman A, et al. 2004. Predictive value of noninvasive measures of atherosclerosis for incident myocardial infarction. The Rotterdam Study. *Circulation*, 109:1089–94.
- Yamagami H, Kitagawa K, Nagai Y, et al. 2004. Higher levels of interleukin-6 are associated with lower echogenicity of carotid artery plaques. *Stroke*, 35:677–81.
- Yildiz A, Tepe S, Oflaz H, et al. 2004. Carotid atherosclerosis is a predictor of coronary calcification in chronic haemodialysis patients. *Nephrol Dial Transplant*, 19:885–91.
- Zureik M, Bureau JM, Temmar M, et al. 2003. Echogenic carotid plaques are associated with aortic arterial stiffness in subjects with subclinical carotid atherosclerosis. *Hypertension*, 41:519–27.
- Zwaka TP, Hombacz V, Torzewski J. 2001. C-reactive protein-mediated low density lipoprotein uptake by macrophages: implications for atherosclerosis. *Circulation*, 103:1194–7.