

Cardiac angiosarcoma: utility of [¹⁸F]fluorodeoxyglucose positron emission tomography–computed tomography in evaluation of residue, metastases, and treatment response

Handan Tokmak¹
Nurhan Demir²
Mehmet Onur Demirkol³

¹Department of Nuclear Medicine and Molecular Imaging, American Hospital, Nişantaşı, Istanbul, ²Internal Medicine Department, Cerrahpaşa Medical Faculty, Istanbul University, Istanbul, ³Department of Nuclear Medicine and Molecular Imaging, Koç University, Istanbul, Turkey

Abstract: Cardiac angiosarcomas are a rare form of malignancy. The majority of cases arise from the right atrium as mural masses. These tumors have extremely aggressive behavior, with early clinical symptoms that vary depending on location, size, and extent of the tumor. Most of these patients have a very short survival time. Surgical therapy is considered the best choice of therapy approach in cardiac angiosarcoma patients with nonmetastatic disease, even though the disease is rarely cured. Advanced diagnostic techniques facilitate accurate, noninvasive assessments of cardiac sarcomas. We report a case of a 62-year-old man with cardiac angiosarcoma who had multiple distant metastases that were revealed by [¹⁸F]fluorodeoxyglucose positron emission tomography–computed tomography imaging.

Keywords: primary cardiac angiosarcoma, FDG PET/CT imaging, noninvasive assessment of cardiac sarcomas

Introduction

Sarcoma is the most common primary malignancy of the heart and pericardium. Primary cardiac sarcomas are rare entities,^{1–3} with an autopsy prevalence of 0.001%–0.28%.³ Pathologic subtypes of primary cardiac sarcoma are angiosarcoma fibrosarcoma, rhabdomyosarcoma, malignant schwannoma, and mesothelioma. Frequency rate decreases in adults.

Angiosarcoma frequency is less than 1% among sarcomas. Of all angiosarcomas, a primary angiosarcoma of the heart and the great vessels accounts for only 3%.⁴ Most of cardiac angiosarcomas (80%) originate from right atrium as mural masses. Extension to the pericardium and encasement of the heart may be seen, and usually fills the entire cardiac chamber. The aggressive behavior of cardiac angiosarcomas causes early symptoms and a very short survival rate. Clinical presentation of sarcomas varies depending on the location, size, and extent of the tumor. Advanced diagnostic techniques facilitate accurate, noninvasive assessment of cardiac sarcomas.⁵

Diagnostic workup usually includes standard echo contrast-enhanced computed tomography (CT), magnetic resonance imaging, and angiography. In the literature, a few case reports have demonstrated the diagnostic contribution of [¹⁸F]fluorodeoxyglucose (FDG) positron emission tomography (PET)–CT in the evaluation of the malignant nature of disease and staging before deciding on the therapy approach.^{6,7}

Correspondence: Handan Tokmak
Department of Nuclear Medicine and
Molecular Imaging, American Hospital,
20 Güzelbahçe Sokak, Nişantaşı,
Istanbul 34365, Turkey
Tel +90 212 444 3777 ext 2586
Fax +90 212 311 2190
Email handantokmak@gmail.com

Even though cardiac angiosarcoma is rarely cured, surgical therapy is considered the best choice of therapy in nonmetastatic disease.⁸ Complete or partial surgical resection of primary or metastatic cardiac sarcoma can provide significant hemodynamic improvement, successful palliation, and prolonged survival.^{9,10} Chemotherapy and postsurgical adjuvant radiotherapy have not proven consistently beneficial. However, all treatment choices after surgical resection can ameliorate symptoms with a varied response.¹¹

Case report

Herein, we report the case of a 62-year-old man who had previously undergone tumor resection for primary high-grade cardiac angiosarcoma (Figure 1) at a university hospital 4 months previously. The patient was referred to the Nuclear Medicine Department for ¹⁸F-FDG PET-CT imaging to assess residual and/or metastatic disease.

The tumor was surgically approached by medial sternotomy, but complete tumor resection was not possible because of the extensive tumor infiltration. Palliative intervention consisting of partial excision of the tumor mass was aimed at releasing the right ventricular outflow tract.

PET-CT scans revealed a residual or relapsed mass in the right atrium, with significantly increased uptake of ¹⁸F-FDG (maximum standardized uptake value of 12). The mass extended to the mitral valve, septum, and left ventricle and infiltrated to the pericardium and adjacent mediastinum (Figure 2). The mass encased and almost completely replaced the atrial wall and nearly filled the entire cardiac chamber. Increased activity in the sternum

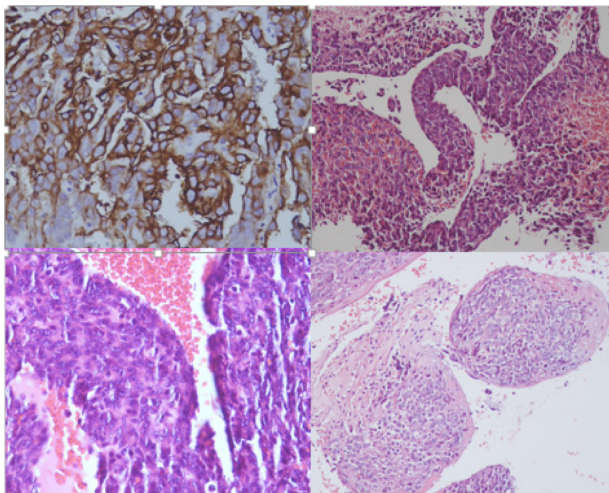


Figure 1 Histopathology findings.

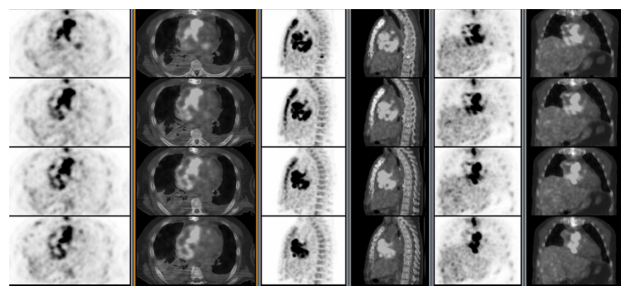


Figure 2 ¹⁸F-FDG PET-CT image showing the tumor mass in the right atrium. **Abbreviations:** CT, computed tomography; FDG, fluorodeoxyglucose; PET, positron emission tomography.

was concomitant with sternotomy. PET-CT images also revealed multiple distant metastasis in the lung, liver, and bones (Figure 3). Despite receiving subsequent aggressive therapy, including radiotherapy, the patient died 8 months later.

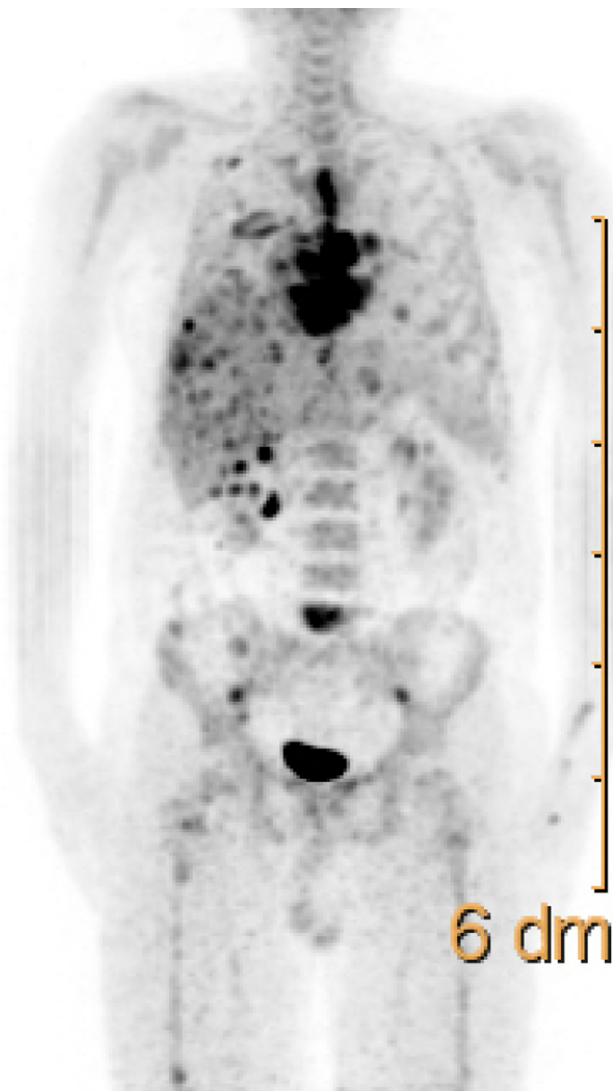


Figure 3 Maximum intensity projection image ¹⁸F-FDG PET-CT shows multiple distant metastasis in the lung, liver and bones. **Abbreviations:** CT, computed tomography; FDG, fluorodeoxyglucose; PET, positron emission tomography; dm, mean decimeter.

Conclusion

Angiosarcoma is a very aggressive malignant neoplasm with a short fatal clinical process, despite new, cutting edge, treatment modalities, such as extensive surgery, radiotherapy, and chemotherapy.¹² Nowadays, through advanced diagnostic technology, such as high-resolution CT, dynamic magnetic resonance imaging, and PET-CT, clinicians are able to diagnose in a shorter time, which allows for more effective radical surgical resection. ¹⁸F-FDG PET-CT seems to be an effective and feasible imaging modality to evaluate primary or postsurgical residue and/or relapse and metastases of the tumor.

Disclosure

The authors report no conflicts of interest in this work.

References

1. Reynen K. Frequency of primary tumors of the heart. *Am J Cardiol.* 1996;77:107.
2. Silverman NA. Primary cardiac tumors. *Ann Surg.* 1980;191:127–138.
3. Barreiro M, Renilla A, Jimenez JM, et al. Primary cardiac tumors: 32 years of experience from a Spanish tertiary surgical center. *Cardiovasc Pathol.* 2013;22:424–427.
4. Lantz DA, Dougherty TH, Lucca MJ. Primary angiosarcoma of the heart causing cardiac rupture. *Am Heart J.* 1989;118:186–188.
5. Yuan SM, Shinfeld A, Lavee J, Kuperstein R, Haizler R, Raanani E. Imaging morphology of cardiac tumours. *Cardiol J.* 2009;16:26–35.
6. Hori Y, Funabashi N, Miyauchi H, et al. Angiosarcoma in the right atria demonstrated by fusion images of multislice computed tomography and positron emission tomography using F-18 fluoro-deoxyglucose. *Int J Cardiol.* 2007;123:e15–e17.
7. Higashiyama S, Kawabe J, Hayashi T, et al. Effectiveness of preoperative PET examination of huge angiosarcoma of the heart. *Clin Nucl Med.* 2009;34:99–102.
8. Truong PT, Jones SO, Martens B, et al. Treatment and outcomes in adult patients with primary cardiac sarcoma: the British Columbia Cancer Agency experience. *Ann Surg Oncol.* 2009;16:3358–3365.
9. Reardon MJ, Walkes JC, Benjamin R. Therapy insight: malignant primary cardiac tumors. *Nat Clin Pract Cardiovasc Med.* 2006;3:548–553.
10. Furukawa N, Gummert J, Börgermann J. Complete resection of undifferentiated cardiac sarcoma and reconstruction of the atria and the superior vena cava: case report. *J Cardiothorac Surg.* 2012;7:96.
11. Kakizaki S, Takagi H, Hosaka Y. Cardiac angiosarcoma responding to multidisciplinary treatment. *Int J Cardiol.* 1997;62:273–275.
12. Look Hong NJ, Pandalai PK, Hornick JL, et al. Cardiac angiosarcoma management and outcomes: 20-year single-institution experience. *Ann Surg Oncol.* 2012;19(8):2707–2715.

Vascular Health and Risk Management

Dovepress

Publish your work in this journal

Vascular Health and Risk Management is an international, peer-reviewed journal of therapeutics and risk management, focusing on concise rapid reporting of clinical studies on the processes involved in the maintenance of vascular health; the monitoring, prevention and treatment of vascular disease and its sequelae; and the involvement of

metabolic disorders, particularly diabetes. This journal is indexed on PubMed Central and MedLine. The manuscript management system is completely online and includes a very quick and fair peer-review system, which is all easy to use. Visit <http://www.dovepress.com/testimonials.php> to read real quotes from published authors.

Submit your manuscript here: <http://www.dovepress.com/vascular-health-and-risk-management-journal>