

# Bilateral permanent concentric visual field defect secondary to severe pre-eclampsia

Mehmet Citirik  
Tulay Simsek  
Orhan Zilelioglu

SB Ankara Ulucanlar Eye Education  
and Research Hospital, Ankara, Turkey

**Purpose:** To present a patient with bilateral permanent concentric visual field defect secondary to severe pre-eclampsia.

**Case report:** A forty-year-old woman presented to the ophthalmology department with partial visual field defect affecting her both eyes. She gave a history of emergent uterine curettage for severe uncontrolled pre-eclampsia in the 24th week of her second gestation which was 10 years before. Two days after the procedure, the patient complained of peripheral visual field defect in her both eyes which persisted until her last presentation. Her best-corrected visual acuity, color vision, intraocular pressures, and anterior segment examination findings were normal bilaterally. Fundus examination showed a normal optic nerve head with reduction of arteriole to vein ratio in both eyes. Humphrey Field Analyzer revealed a bilateral concentric visual field defect. Visual Evoked Potentials (VEP) and Electroretinography (ERG) were within normal limits in both eyes. Cranial magnetic resonance imaging (MRI) was normal.

**Discussion:** Herein, we presented a case of permanent concentric visual field defect which developed as a complication of severe uncontrolled pre-eclampsia. To the best of our knowledge; such a case has not been reported to date.

**Keywords:** pregnancy, pre-eclampsia, concentric visual field defect

## Introduction

Pre-eclampsia is characterized by the presence of hypertension, edema, and proteinuria and usually ensues after the second half of gestation (Sheth and Mieler 2001). Pre-eclampsia may progress to eclampsia which is characterized by seizures (Sheth and Mieler 2001). Approximately 5% of obstetric patients develop toxemia of pregnancy (Sheth and Mieler 2001; Pritchard et al 1985). In some patients, pregnancy-induced hypertension occurs in the setting of underlying hypertension. Although a small proportion of patients continue to suffer from chronic hypertension, pregnancy-induced hypertension usually resolves 1 to 5 months after delivery (Sunness 1988). In the course of a normal pregnancy, significant retinal vascular changes do not occur (Pritchard et al 1985; Sheth and Mieler 2001). However, retinal vascular changes in toxemia of pregnancy are commonly identified (Sunness 1988). Hypertension causes diminution of retinal arterioles in their diameter (Albert and Dryja 1989). In acute severe hypertension, as seen in toxemia of pregnancy, clinical changes initially appear as focal spasms. Chronic hypertension usually causes arteriolar sclerotic changes which results in slowly progressive and diffuse arteriolar luminal narrowing (Sheth and Mieler 2001).

Wide speculation exists about the degree and pathogenetic mechanisms of visual field changes that may occur in pregnant women. Visual field loss patterns in pregnant women include bitemporal loss, concentric constriction, and enlarged blind spots (Albert and Dryja 1989). Proposed mechanisms are equally diverse and include changes in the pituitary gland that may affect the optic chiasm (Erdheim and Stumme 1969). Also, visual field defects may occur due to serous retinal detachment, retinal

Correspondence: Mehmet Citirik  
Fakülteler Mh. Yazgan Sk. No: 34/12 06590  
Cebeci, Ankara, Turkey  
Tel +90 312 362 3222  
Fax +90 312 312 4827  
Email: mcitirik@hotmail.com

hemorrhage, optic nerve head edema, and involve the central nervous system. These visual field changes were shown to be reversible at ten days postpartum (Sunness 1988).

We describe a patient with bilateral permanent concentric visual field defect secondary to severe pre-eclampsia.

## Case report

A forty-year-old woman suffering from bilateral persistent visual field defect with duration of 10 years admitted to our clinic. Her best-corrected visual acuity was 20/20 OD and 20/20 OS. Color vision and anterior segment examination findings were bilaterally normal. Intraocular pressures with applanation were 15 mmHg OD and 14 mmHg OS respectively. The fundus examination disclosed a normal optic nerve head with reduction of arteriole to vein ratio in both eyes. None of the family members were known to have similar ocular or systemic findings. Her blood pressure was 130/80 mmHg. Clinical and laboratory investigations were within normal limits indicating no systemic disorder.

Her automated visual field examination with Humphrey Field Analyzer revealed a bilateral concentric visual field defect (Figure 1). A repeated Humphrey Field Analysis which performed 4 weeks later was confirmatory. The same concentric visual field defect was present in her visual field examination which was performed 10 years before.

Electrophysiological testing was carried out to reveal any subclinical damage of the optic nerve. The results of both visual evoked potentials (VEP) and electroretinography (ERG) were within normal limits in both eyes (Figure 2). Cranial and orbital magnetic resonance imaging (MRI) showed no pathology (Figure 3).

The patient reported that her complaints started 10 years ago after emergent uterine curettage performed for severe uncontrolled pre-eclampsia in the 24th week of her second

gestation. She indicated that partial visual field loss started 2 days after the procedure and persisted without improvement till now. She patient admitted to hospital for bitemporal headache and generalized edema at that time. Systemic blood pressure was 180/110 mmHg and urinary protein level was found to be elevated. Therefore, emergent uterine curettage was performed.

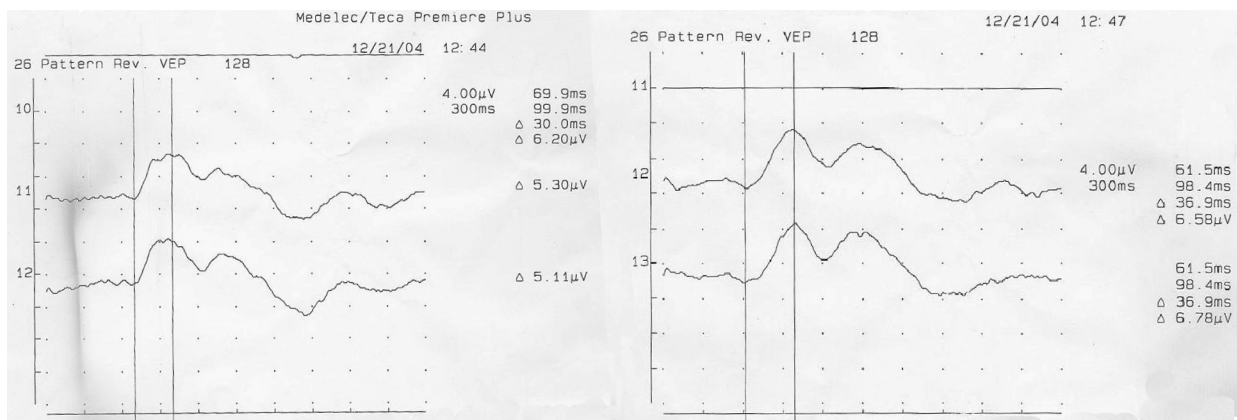
## Discussion

Toxemia of pregnancy refers to both pre-eclampsia and eclampsia (Sunness 1988). Visual disturbances are experienced by 25% to 50% of these patients (Dieckmann 1952). Blindness in women with pre-eclampsia/eclampsia is rare and can be due to involvement of the occipital cortex or retina (Carpenter et al 1953; Goodlin et al 1983). Blindness is usually transient and resolves completely within a few hours, but it may last longer (Arulkumaran et al 1985). The other possibility is retinal detachment due to severe hypertension resulting in blindness; however, this condition is usually unilateral (Bosco 1961). Serous retinal detachment may occur in 2%–10% patients with toxemia of pregnancy, usually shortly before or immediately after childbirth (Fastenberg et al 1980).

Retinopathy of varying severity is present in a majority of pre-eclamptic patients (Sunness 1988). Although statistically significant differences in retinal arterial caliber and number of focal constricted areas are observed in women who had mild and severe pre-eclampsia. The earliest fundus manifestations include reversible focal arteriolar spasm (Albert and Dryja 1989). Arteriolar narrowing and focal arteriolar constrictions have been loosely correlated with the diastolic blood pressure (Jaffe and Schatz 1987). Sometimes there are associated intraretinal hemorrhages, exudates, and nerve fiber layer infarcts (Jaffe and Schatz 1987). Disc edema evolves with the onset of malignant hypertension.

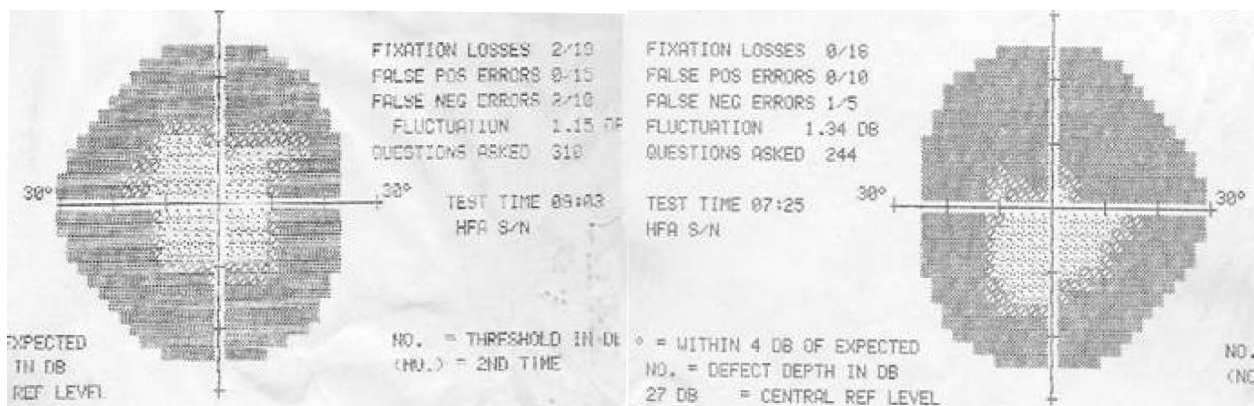

Figure 1 Humphrey Field Analyzer of patient shows concentric visual field defect.



**Figure 2** Visual evoked potentials (VEP) of patient is within normal limits.

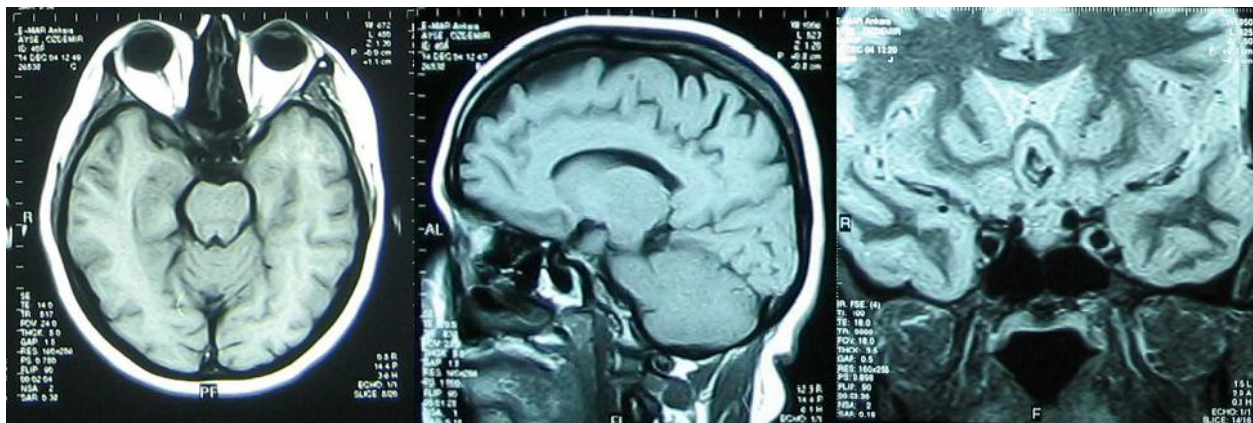There are five patterns of field defects resulting from visual pathway lesions: central or centrocecal scotoma; arcuate or altitudinal scotoma; nasal wedge scotoma; generalized depression; and hemianopia. A process that affects the macula or optic nerve may result in a central scotoma. A more extensive lesion of the papulomacular bundle or optic nerve produces a scotoma involving fixation and the physiologic blind spot and is designated a centrocecal scotoma. Involvement of nerve fiber bundles produces an arcuate scotoma that extends from the blind spot to the horizontal meridian. An altitudinal defect may involve the superior or inferior portion of the visual field. Any lesion involving the nasal retinal nerve fibers produces a wedge scotoma. Generalized depression is a nonlocalizing defect that may be produced by a variety of causes, including cataract, diffuse retinal disease, and optic nerve compression (Keltner et al 1994).

Visual evoked potentials are a sensitive and objective tool for detecting toxic effects on the optic nerve. In optic

nerve diseases both amplitude and latency are affected, with a decrease in amplitude and an increase in latency (Kanski 1999). In the presented case, electrophysiological tests were interpreted as normal.

The concentric visual fields could be the result of a further retinal disease. An ERG would be necessary to rule out such a disease. The results of ERG were within normal limits in both eyes in our patient.

Acute ischemic optic neuropathy, as a result of impairment of the blood supply to the prelaminar portion of the optic nerve head is another type of blindness associated with pre-eclampsia (Beck et al 1980). It is characterized by sudden and profound visual loss. The disc is pale and swollen with small splinter-shaped hemorrhages on its margin. Within months, swelling resolves and optic disc becomes atrophic. Retrobulbar neuritis has been described during pregnancy and may be an underlying manifestation of multiple sclerosis which is often exacerbated by gravidity (Hagedorn 1937). Our patient did not present with sudden visual loss and had



**Figure 3** MRI of patient is within normal limits (Axial section—Sagittal section—Coronal section).

a normal MRI excluding diagnoses of acute ischemic optic atrophy and retrobulbar neuritis.

Cortical blindness is one of the complications of severe pre-eclampsia and in these cases cranial computerized tomography characteristically demonstrates hypodense areas in the occipital lobes (Lau et al 1987). Normal MR imaging makes cortical blindness unlikely in our case.

Posterior reversible leukoencephalopathy syndrome (PRES) is characterized predominantly by white matter edema affecting the occipital and posterior parietal lobes of the brain (Garg 2001). It is characterized by transitory neurological disturbances including altered mental status, seizures, headache and blurred vision. There may be abnormalities of vision such as hemianopia, visual neglect, and cortical blindness (Hinchev et al 1996). Our patient reported that her complaint started 10 years ago just after the emergent uterine curettage which was performed for severe uncontrolled pre-eclampsia in the 24th week of her second gestation. Her automated visual field examination revealed a bilateral concentric visual field defect which is not typical in PRES. Additionally, PRES has not been described previously after the emergent uterine curettage and is usually considered to be a reversible condition (Hinchev et al 1996). Our patient reported that her complaint persisted until her last admission with remaining stable. Delay in initiating the appropriate treatment may result in permanent damage to the brain (Bakshi 1998). However, cranial and orbital MRI of our patient showed no pathology.

There are numerous reports about the visual defects that occurred in normal pregnancy consisting bitemporal visual loss, concentric constriction, and enlarged blind spots (Goodlin et al 1983; Carpenter et al 1953). Herein, we presented a case of permanent concentric visual field constriction developing after severe pre-eclampsia which has not been described previously. Although postpartum visual field defects heal completely with time, our patient's visual field defect persisted for 10 years. It is possible that the length of time

between onset of symptoms and MRI examination has resulted in a radiologic resolution without clinical resolution.

## References

- Albert DM, Dryja TP. 1989. The eye. In: Cotran RS, Kumar V, Robbins SL (eds). *Robbins Pathologic Basis of Disease*, 4th ed. Philadelphia: WB Saunders, pp. 1451–68.
- Arulkumaran S, Gibb DMF, Rauff M, et al. 1985. Transient blindness associated with pregnancy induced hypertension. *Br J Obstet Gynaecol*, 92:847–49.
- Bakshi R, Bates VE, Mechtler LL, et al. 1998. Occipital lobe seizures as major clinical manifestations of reversible posterior leukoencephalopathy syndrome: magnetic resonance imaging findings. *Epilepsia*, 39:295–9.
- Beck RW, Gamel JW, Willcourt RJ, et al. 1980. Acute ischemic optic neuropathy in severe pre-eclampsia. *Am J Ophthalmol*, 90:342–6.
- Bosco, JAS. 1961. Spontaneous nontraumatic retinal detachments in pregnancy. *Am J Obstet Gynaecol*, 82:208–12.
- Carpenter F, Kava HL, Plotkin D. 1953. The development of total blindness as a complication of pregnancy. *Am J Obstet Gynaecol*, 66:641–7.
- Dieckmann WJ. 1952. *The toxemias of pregnancy*. Ed2, St Louis: CV Mosby, pp. 240–9.
- Erdheim J, Stumme E. 1969. *Über die Schwangerschaftsveränderung der Hypophyse*. Clinical Neuro-Ophthalmology. Baltimore: Williams and Wilkins, Ed3, pp. 2124–5.
- Fastenberg DM, Fetkenhour CL, Choromokos E, et al. 1980. Choroidal vascular changes in toxemia of pregnancy. *Am J Ophthalmol*, 89:362–8.
- Garg RK. 2001. Posterior leukoencephalopathy syndrome. *Postgrad Med J*, 77:24–8.
- Goodlin RC, Strieb E, Sun SF, et al. 1983. Cortical blindness as the initial symptom in severe pre-eclampsia. *Am J Obstet Gynaecol*, 147:841–2.
- Hagedorn A. 1937. The chiasmal syndrome end retrobulbar neuritis in pregnancy. *Am J Ophthalmol*, 20:690.
- Hinchev J, Chaves C, Appignani B, et al. 1996. A reversible posterior encephalopathy syndrome. *N Engl J Med*, 334:494–500.
- Jaffe G, Schatz H. 1987. Ocular manifestations of pre-eclampsia. *Am J Ophthalmol*, 103:309–15.
- Kanski JJ. 1999. *Clinical Ophthalmology*. 4th ed. Butterworth and Heinemann, p 591.
- Keltner JL, Johnson CA, Spurr JO, et al. 1994. Visual field profile of optic neuritis: one year follow-up in the Optic Neuritis Treatment Trial. *Arch Ophthalmol*, 112:946–53.
- Lau SPC, Chan FL, Yu YL, et al. 1987. Cortical blindness in toxemia of pregnancy: Findings on computed tomography. *Br J Radiol*, 60:347.
- Pritchard JA, MacDonald PC, Grant NF. 1985. *Williams Obstetrics*. Norwalk, Appleton-Century-Crofts, Ed 17, pp. 119–37, 201–5.
- Sheth BP, Mieler WF. 2001. Ocular complications of pregnancy. *Curr Opin Ophthalmol*, 12:455–63.
- Sunness JS. 1988. The pregnant woman's eye. *Survey Ophthalmol*, 32:219–38.