

# Varicella zoster virus-associated anterior uveitis in a seronegative adult without a history of chickenpox

Izumi Mine  
Sho Ishikawa  
Masaru Takeuchi

Department of Ophthalmology,  
National Defense Medical College,  
Tokorozawa City, Saitama, Japan

**Aim:** The aim of this report was to present a case of varicella zoster virus (VZV)-associated anterior uveitis, which developed in an adult who was seronegative for anti-VZV antibodies.

**Case presentation:** A 66-year-old male patient was referred to the National Defense Medical College, Tokorozawa City, Japan with iridocyclitis in his right eye. On examination, intraocular pressure was 30 mmHg in the right eye, and biomicroscopy revealed ciliary injection, corneal epithelial edema, mutton fat keratic precipitates, flare, and infiltrating cells in the anterior chamber. Serological tests were negative for anti-VZV antibodies, but VZV-DNA copies of  $1.28 \times 10^7$  copies/mL were detected by quantitative reverse transcriptase polymerase chain reaction using the aqueous humor obtained from the right eye. Iridocyclitis was reduced by administration of oral valaciclovir in addition to corticosteroid eye drops, and serum anti-VZV antibodies were first detected after 4 months' administration. When ocular inflammation was resolved after 6 months, VZV-DNA could not be detected in the aqueous humor any more.

**Conclusion:** VZV-associated uveitis may develop in an adult with undetectable serum anti-VZV antibodies. Multiplex polymerase chain reaction of the aqueous humor is the key investigation necessary for the diagnosis in such cases.

**Keywords:** varicella zoster virus, VZV, zoster sine herpette, multiplex polymerase chain reaction, uveitic glaucoma

## Introduction

Reactivation of latent varicella zoster virus (VZV) infection may cause anterior uveitis.<sup>1</sup> Ocular manifestations are usually described as unilateral iridocyclitis with mutton-fat keratic precipitates, elevation of intraocular pressure, and late sectorial iris atrophy.<sup>2</sup> VZV-associated anterior uveitis with skin lesions along the first branch of the trigeminal nerve is called herpes zoster ophthalmicus (HZO), although HZO can present without any eye problems (anterior uveitis and/or keratitis); HZO without skin lesions is known as zoster sine herpette (ZSH).<sup>3</sup> In these cases, serum anti-VZV antibodies are detected, which allow confirmation of prior VZV infection.<sup>1</sup> We report a case of ZSH in an adult who was seronegative for anti-VZV antibodies at presentation.

## Case presentation

A 66-year-old man was referred to our hospital, the National Defense Medical College, Tokorozawa City, Japan from an ophthalmology clinic with a 1-week history of visual disturbance in his right eye. There was no ocular history of trauma, inflammation, or medication. His family history and medical history for systemic diseases were unremarkable. At presentation, the best corrected visual acuity was 20/30 in the right eye and 20/15 in the left eye. Intraocular pressure (IOP) was 30 mmHg in the right eye

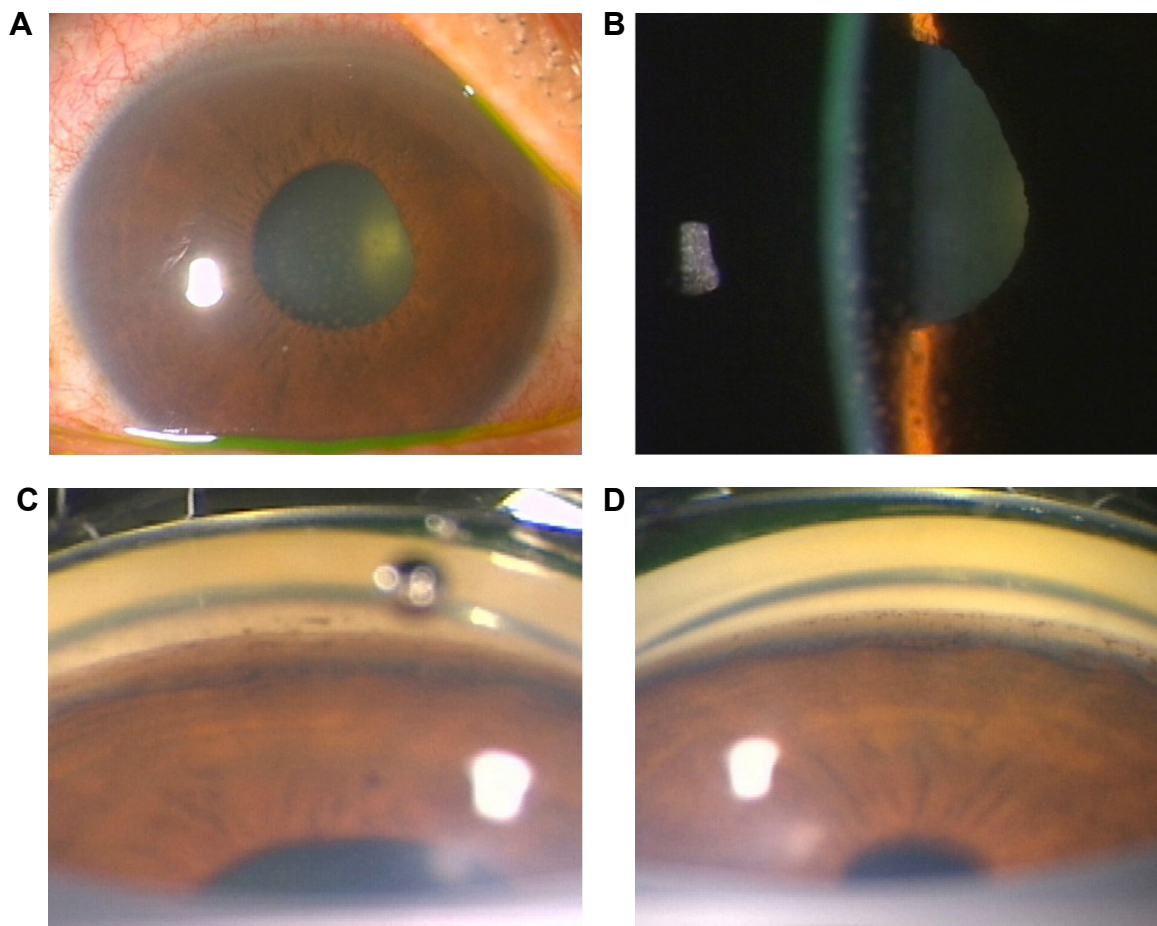
Correspondence: Masaru Takeuchi  
Department of Ophthalmology, National  
Defense Medical College,  
3-2 Namiki, Tokorozawa City,  
Saitama, 359-8513, Japan  
Tel +81 4 2992 1511  
Fax +81 4 2995 5332  
Email masatake@ndmc.ac.jp

and 14 mmHg in the left eye. Biomicroscopy revealed ciliary injection, corneal epithelial edema, mutton-fat keratic precipitates, flare, and infiltrating cells in the anterior chamber of the right eye (Figure 1A and B). In addition, pigmentation of trabecular pigment band in the angle was increased in the right eye compared with the left eye (Figure 1C and D). Although mild opacity and cell infiltration in the anterior vitreous of the right eye were present, retinitis or retinal vasculitis was not observed. No abnormalities were found in the left eye.

In addition to the laboratory blood tests, the multiplex polymerase chain reaction (PCR) for human herpes viruses (HHVs) 1 through 8, of the aqueous humor from the right eye was performed, and treatment with topical 0.1% betamethasone, mydriatic (0.1% phenylephrine and 0.1% tropicamide), and 0.005% latanoprost for ocular hypertension was initiated. The serological tests were negative for syphilis and anti-herpes simplex virus, as well as anti-VZV antibodies. However, VZV-DNA was

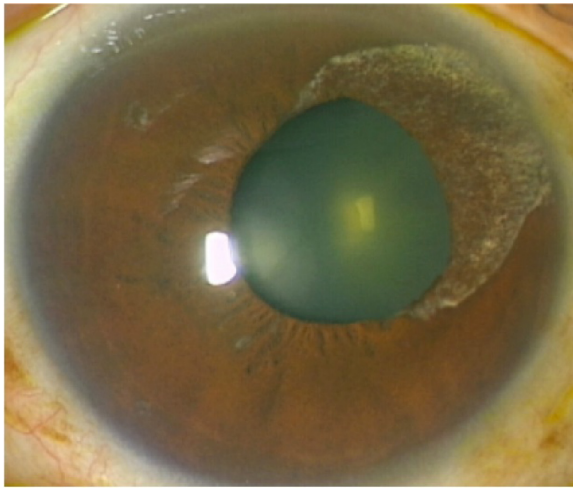
detected by multiplex PCR in the aqueous humor obtained from the right eye, and quantitative real-time PCR revealed VZV-DNA copies of  $1.28 \times 10^7$  copies/mL. Although the patient had not been vaccinated for VZV, there was no history of chickenpox in childhood or later, and serum anti-VZV antibodies were not detected. However, ZSH was diagnosed since the clinical findings were compatible with VZV-associated anterior uveitis and skin lesions were absent, thus excluding HZO.

We initiated medical treatment for VZV with oral valacyclovir 1,500 mg three times a day for 1 month, in addition to the topical treatment. Ocular inflammation resolved gradually, and IOP decreased to lower than 21 mmHg. VZV-DNA in the aqueous humor was reduced to  $4.08 \times 10^4$  copies/mL at 3 months after the first visit, and serum anti-VZV antibodies were first detected after 4 months. Distorted pupil and fan-shaped iris atrophy, which are characteristics of VZV iridocyclitis, appeared at the upper nasal iris (Figure 2). Ocular inflammation was not observed at 6 months, and VZV-DNA



**Figure 1** Ocular findings at presentation.

**Notes:** (A and B) Ciliary injection, corneal epithelial edema, mutton-fat keratic (A), and infiltrating cells in the anterior chamber of the right eye (B); (C and D) pigmentation of the trabecular pigment band in the angle was increased in the right eye (C) compared with the left eye (D).



**Figure 2** Ocular findings observed after treatment was started.  
**Note:** Distorted pupil and fan-shaped iris atrophy were observed.

was not detected from the aqueous humor. Written informed consent was obtained from the patient for publication of this case report and accompanying images.

## Discussion

VZV is transmitted through respiratory droplets. An initial viremia is followed by viral spread to the skin, the eye, and then the sensory ganglia throughout the body, where the virus establishes latency. Primary infection of VZV manifests as a generalized vascular rash (chicken pox) caused by inhaled virus particles, and thereafter the virus may reside dormant in sensory nerve ganglia for many years.<sup>4</sup> Ocular diseases such as keratitis, anterior uveitis, and acute retinal necrosis are secondary clinical manifestations of VZV infection as well as herpes zoster, and serum anti-VZV antibodies are in principle positive when ocular disease develops.<sup>3</sup> In the present case, although serum anti-VZV antibodies were negative, the clinical findings such as unilateral iridocyclitis with mutton-fat keratic precipitates and elevated IOP were compatible with the characteristics of VZV-associated anterior uveitis. A definitive diagnosis was made isolating the VZV DNA in the aqueous humor with multiplex PCR and quantitative real time PCR. Thus, the multiplex PCR and quantitative real time PCR results were key to arriving at the correct diagnosis in this case.

Thus, multiplex PCR and quantitative real time PCR are definitely useful for the diagnosis in this type of case. VZV-DNA was detected in the aqueous humor in larger number of copies at presentation, which decreased and disappeared along with the improvement of ocular inflammation by valaciclovir treatment. Since serum anti-VZV

antibodies, fan-shaped iris atrophy, and distorted pupil emerged thereafter, the diagnosis based on multiplex PCR was confirmed clinically.

Since it has been reported that microdendritic keratitis, nummular keratitis, disciform keratitis, mucous plaque keratitis, sclerokeratitis, and iridocyclitis may occur during primary infection of VZV, although with less frequency,<sup>5</sup> this case might be atypical ZSH developed following primary VZV infection that did not clinically manifest systemic varicella symptoms. However, most cases of primary VZV infection are mild, or are not recognized as chickenpox.<sup>4</sup> In addition, anti-VZV antibodies in the present case were tested by complement fixation test which is less sensitive than enzyme immunoassay.<sup>6</sup> Therefore, in this case, we cannot exclude a possibility of prior infection with VZV before the development of ocular manifestations.

## Conclusion

ZSH may develop in an adult without serum anti-VZV antibodies and without a history of chickenpox. In such cases, multiplex PCR using aqueous humor is useful for a definitive diagnosis.

## Author contributions

IM participated in treatment of the patient, analysis and interpretation of data, and drafted the manuscript. SI participated in diagnosis and treatment of the patient, designed the structure of the manuscript, and critically revised the manuscript for important intellectual content. MT participated in analysis and interpretation of data, and critically revised the manuscript for important intellectual content. All authors have given final approval of the version to be published. All authors agree to be accountable for all aspects of the work in ensuring that questions related to the accuracy or integrity of any part of the work are appropriately investigated and resolved. All authors read and approved the final manuscript.

## Disclosure

The authors report no conflicts of interest in this work.

## References

1. Liesegang TJ. Herpes zoster virus infection. *Curr Opin Ophthalmol.* 2004;15(6):531–536.
2. Kido S, Sugita S, Horie S, et al. Association of varicella zoster virus load in the aqueous humor with clinical manifestations of anterior uveitis in herpes zoster ophthalmicus and zoster sine herpette. *Br J Ophthalmol.* 2008; 92(4):505–508.
3. Liesegang TJ. Herpes zoster ophthalmicus: natural history, risk factors, clinical presentation, and morbidity. *Ophthalmology.* 2008; 115(2 Suppl):S3–S12.

4. Arvin AM. Varicella-zoster virus. *Clin Microbiol Rev.* 1996;9(3):361–381.
5. Pavan-Langston D. Viral disease of the ocular anterior segment: basic science and clinical disease. In: Smolin G, Foster CS, Azar DT, Dohlman CH, editors. *Smolin and Thoft's The Cornea: Scientific Foundations and Clinical Practice*. 4th ed. Philadelphia: Lippincott Williams and Wilkins; 2005:297–393.
6. Forghani B, Schmidt NJ, Dennis J. Antibody assays for varicella-zoster virus: comparison of enzyme immunoassay with neutralization, immune adherence hemagglutination, and complement fixation. *J Clin Microbiol.* 1978;8(5):545–552.

## Clinical Ophthalmology

Dovepress

### Publish your work in this journal

Clinical Ophthalmology is an international, peer-reviewed journal covering all subspecialties within ophthalmology. Key topics include: Optometry; Visual science; Pharmacology and drug therapy in eye diseases; Basic Sciences; Primary and Secondary eye care; Patient Safety and Quality of Care Improvements. This journal is indexed on

Submit your manuscript here: <http://www.dovepress.com/clinical-ophthalmology-journal>

PubMed Central and CAS, and is the official journal of The Society of Clinical Ophthalmology (SCO). The manuscript management system is completely online and includes a very quick and fair peer-review system, which is all easy to use. Visit <http://www.dovepress.com/testimonials.php> to read real quotes from published authors.