

RETRACTED ARTICLE: The gastroprotective effects of hydroalcoholic extract of *Monolluma quadrangula* against ethanol-induced gastric mucosal injuries in Sprague Dawley rats

Ibrahim Abdel Aziz Ibrahim¹
 Mahmood Ameen Abdulla²
 Maryam Hajrezaie²
 Ammar Bader³
 Naiyer Shahzad¹
 Saeed S Al-Ghamdi¹
 Ahmad S Gushash⁴
 Mohadeseh
 Hasanpourghadi⁵

¹Department of Pharmacology and Toxicology, Faculty of Medicine, Umm Al-Qura University, Makkah, Saudi Arabia; ²Department of Biomedical Science, Faculty of Medicine, University of Malaya, Kuala Lumpur, Malaysia; ³Department of Pharmacognosy, Faculty of Pharmacy, Umm Al-Qura University, Makkah, Saudi Arabia; ⁴College of Arts and Sciences in Baljurashi, Albaha University, Baljurashi, Saudi Arabia; ⁵Cell Biology and Drug Discovery Laboratory, Department of Pharmacology, Faculty of Medicine, University of Malaya, Kuala Lumpur, Malaysia

Abstract: *Monolluma quadrangula* (Forsk.) Plowen is used in Saudi traditional medicines to treat gastric ulcers. The hydroalcoholic extract of *M. quadrangula* (MHAE) was used in an in vivo model to investigate its gastroprotective effects against ethanol-induced acute gastric lesions in rats. Five groups of Sprague Dawley rats were used. The first group was treated with 10% Tween 20 as a control. The other four groups included rats treated with absolute ethanol (5 mL/kg) to induce an ulcer, rats treated with 20 mg/kg omeprazole as a reference drug, and rats treated with 150 or 300 mg/kg MHAE. One hour later, the rats were administered absolute ethanol (5 mL/kg) orally. Animals fed with MHAE exhibited a significantly increased pH, gastric wall mucus, and thickening of the gastric mucosa, as well as a decreased area of gastric mucosal damage. Histology confirmed the results; extensive destruction of the gastric mucosa was observed in the ethanol control group, and the lesions penetrated deep into the gastric mucosa with leukocyte infiltration of the submucosal layer and edema. However, gastric protection was observed in rats pretreated with plant extracts. Periodic acid–Schiff staining of the gastric wall revealed a remarkably intensive uptake of magenta color in the experimental rats pretreated with MHAE compared to the ulcer control group. Immunohistochemistry staining revealed an upregulation of the Hsp70 protein and a downregulation of the Bax protein in rats pretreated with MHAE compared to the control rats. Gastric homogenate showed significantly increased catalase and superoxide dismutase, and the level of malondialdehyde (MDA) was reduced in the rats pretreated with MHAE compared to the control group. In conclusion, MHAE exhibited a gastroprotective effect against ethanol-induced gastric mucosal injury in rats. The mechanism of this gastroprotection included an increase in pH and gastric wall mucus, an increase in endogenous enzymes, and a decrease in the level of MDA. Furthermore, protection was given through the upregulation of Hsp70 and the downregulation of Bax proteins.

Keywords: *Monolluma quadrangula*, gastroprotective, Hsp70, superoxide dismutase, catalase, malondialdehyde, gastric ulcer

Introduction

Peptic ulcer is a multifactorial disease that involves endogenous and exogenous factors, including an imbalance between offensive factors (pepsin and hydrochloric acid) and defensive factors (mucus and bicarbonate).¹ The main causes of gastric ulcers are stress, infection with *Helicobacter pylori*, the administration of steroidal and nonsteroidal anti-inflammatory drugs, tobacco smoking, alcohol intake, and some types of gastrinomas.^{2,3}

Correspondence: Mahmood Ameen Abdulla
 Department of Biomedical Science,
 Faculty of Medicine, University of Malaya,
 50603 Kuala Lumpur, Malaysia
 Tel/fax +603 7967 6604
 Email ammeen@um.edu.my

Many factors are associated with the pathogenesis of gastric ulcer, including inhibition of cell proliferation, synthesis of prostaglandins, and changes in the blood flow and motility of the gastric mucosa.⁴ Currently, treating a gastric ulcer requires a combination of drugs, all of which exhibit side effects and incur additional costs, even though medical advances in treatments have progressed and expanded.²

The discovery of natural drugs of plant origin is mainly based on ethnopharmacological data.^{5,6} This knowledge is essential in developing countries as an alternative to expensive and inaccessible synthetic medicine. In Saudi Arabia, the use of medicinal plants has deep roots linked to traditions. Although vast progress has been made in this country, a good percentage of the population still uses medicinal plants for various ailments. Workers have reported the use of medicinal plants as a remedy for ailments, including gastric ulcer. Rodents have often been used as a model in the medical field. Rodent and human gastrointestinal tracts share many biological, histological, and genetic features.^{7–13}

The selection of the plant was based on ethnopharmacological information. *Monolluma quadrangula* (Forssk.) Plowes (syn. *Caralluma quadrangula* [Forssk.] R. Br.) is a succulent plant belonging to the family *Apocynaceae*. The fresh plant is eaten to treat gastric ulcers and diabetes and is also used as appetite suppressant.¹⁴ Other species of *Caralluma* are known to be active against gastric ulcers. Among them is the hydroalcoholic extract, *Caralluma arabica*, which is active at a dose of 200–400 mg/kg in different experimental gastric ulcer models, including indomethacin, phenylbutazone, 80% ethanol, and cold-restraint stress.¹⁵ This plant was able to reduce gastric acidity and secretion and increase mucin production.^{15,16} *Caralluma* spp. are rich in terpenols, steroidal glycosides, pregnane glycosides, flavonoid derivatives, and magastigmane glycosides.^{17,18,19} To the best of our knowledge, no studies have been performed to evaluate the protective effect of *M. quadrangula* on gastric ulcer. Therefore, we performed this investigation in order to study the antiulcer effects of hydroalcoholic extract of *M. quadrangula* (MHAE) on ethanol-induced gastric mucosal injury in rats and its possible mechanism of action, particularly its antioxidant properties.

Materials and methods

Omeprazole

Omeprazole (a well-known antiulcer drug) was used as the positive control and was purchased from the pharmacy in the Umm Al-Qura University, Makkah. The drug was dissolved in 10% Tween 20 (10%, v/v) and was administered orally to the rats at a dosage of 20 mg/kg body weight (5 mL/kg).^{20,21}

Preparation of plant extractions

The plant material was gathered in Wadi Thee Ghazal near Taif, Saudi Arabia, in October 2012. No permission was required to collect the plant, and the field studies did not involve endangered or protected species. The identification of the plant was performed by one of the authors. A voucher specimen (SA-MA 1/2013) was conserved in alcohol at the herbarium of the Pharmacognosy Lab, Faculty of Pharmacy, Umm Al-Qura University. The hydroalcoholic extract of *M. quadrangula* (MHAE) was prepared by maceration of 50 g of dry and powdered plant material in 1000 mL of a 50% hydroalcoholic solvent (50% ethanol + 50% distilled water). Then, the extract was dried using a rotary evaporator.

Animal ethical issues

This study was approved by the Ethics Committee for Animal Experimentation of the Faculty of Medicine, University of Malaya, Malaysia (Ethic No. P/01/05/2014/MAA (a) (R)), and the National Academy of Science's Guide for the Care and Use of Laboratory Animals.^{22,23} A standard laboratory environment was provided for the rodents. They were kept at a temperature of 25°C±2°C in a 12-hour light–dark cycle in the animal house at the Faculty of Medicine, University of Malaya, Kuala Lumpur, Malaysia.

Acute toxicity test

A total of 36 healthy Sprague Dawley rats (18 males and 18 females) were distributed evenly into three groups and labeled as the vehicle (distilled water) and 2 and 5 g/kg body weight of MHAE, respectively.²⁴ The rodents were fasted during the night (food but not water) preceding dosing. After administration of the drug, the animals were kept under observation for 30 minutes and 2, 4, 24, and 48 hours, for the beginning of toxicological or clinical signs. After 15 days, all animals were sacrificed. Serum biochemical, histological (kidney and liver), and hematological factors were evaluated.^{13,25}

Induction of acute gastric injuries in rats by absolute ethanol

Twenty-four Sprague Dawley male rats (200–250 g) had access to water 2 hours before the experiment and were fasted 24 hours before the experiment.²⁶ The randomly selected animals were distributed into five groups. Each group contained six rats, and they were housed individually in cages. A wide-mesh wire bottom was used to prevent coprophagy.²⁷

The group treated with 10% Tween 20 was the normal control group. The ulcer control group was orally administered absolute ethanol (5 mL/kg). A dose of 20 mg/kg omeprazole was orally administered to the reference group. MHAE was given to

the two experimental groups at dosages of 150 and 300 mg/kg (5 mL/kg).¹³ Absolute ethanol (5 mL/kg) was given to all of the animals 1 hour after the pretreatment dose.²⁸ An overdose of xylazine and ketamine anesthesia was used to kill the animals after 1 hour, and their stomachs were excised immediately.²⁷

Measurement of gastric acid content (pH)

Stomachs were opened along the greater curvature, and the gastric contents were collected, centrifuged, and analyzed in order to measure the pH of the gastric juice from the supernatant using a 0.1 N NaOH solution and a precise digital pH meter.²⁹

Content measurement of gastric mucus

The stomachs of the rats were rinsed with normal saline, and the gastric mucus was wiped gently using a glass slide. A precise electronic balance was used to indicate the weight of the collected mucus.³⁰

Assessment of the gastroprotective effects of MHAE

Microscopic evaluation of the gastric lesions

The gastric mucosal ulcer induced by ethanol appeared as elongated bands of acute hemorrhagic lesions parallel to the long axis of the stomach.³¹ The gastric mucosa of each rat was studied for any sign of damage under a dissecting stereomicroscope. The size (width and length) of the ulcer areas (UA) (mm) was calculated using a planimeter (10×10 mm).³² UAs (×1.8 magnification). We measured the UA as a number of small squares and counted each 2 mm² (width and length) of each ulcer band. After counting all lesions, the sum of the area of each stomach was calculated by the equation wherein the sum of the small squares $\times 1.8 = UA$ (mm²).³² The percentage of inhibition (I%) was calculated according to Abdulla et al⁸:

$$I\% = \left[\frac{UA_{\text{control}} - UA_{\text{treated}}}{UA_{\text{control}}} \right] \times 100\%$$

Histology of gastric tissue

Buffered formalin (10%) was used to preserve the open stomach after cutting the glandular portion into small slices. Gastric specimens were processed by an automated tissue processing machine (Leica, Wetzlar, Germany) and were embedded in paraffin wax. The gastric tissue was then sectioned at a thickness of 5 μ m and stained with hematoxylin and eosin.^{26,33} Light microscopy was used to assess the tissue sections for any histopathological deviations, such as hemorrhage, edema, necrosis, and congestion. Mucosal glycoproteins were also assessed by staining the gastric tissue with periodic acid–Schiff (PAS) stains.³⁴

Immunohistochemical evaluation

The immunohistochemical staining of Bax and Hsp70 proteins was performed according to the manufacturer's protocol (Dako Cytomation, Carpinteria, CA, USA). Xylene and graded alcohol were used to de-paraffinize the slides heated in a hot-air oven. Then, 10 mM boiled sodium citrate buffer was used for antigen retrieval. The slides were then incubated for 15 minutes with biotinylated primary antibodies, namely Hsp70 (1:500) or Bax (1:200), and then secondary labeling with streptavidin conjugated to horseradish peroxidase was performed. The slides were soaked with 3,3'-diaminobenzidine substrate chromogen and then washed and stained with hematoxylin.

Western blot analysis

Total protein was extracted from tissue homogenates using a protein extraction buffer (Pierce, Waltham, MA, USA). With some optimizing modifications, the Western blot assay was performed as described previously.³⁴ Then, 30 μ g protein sample was electrophoresed in one dimension through sodium dodecyl sulfate-polyacrylamide gel (12%) electrophoresis (25 mA for 2 hours). Diffused proteins were then transferred to a polyvinylidene difluoride membrane (Pierce) using Trans-Blot SD semidry transfer cell (Bio-Rad Laboratories Inc., Hercules, CA, USA) at 15 V and 95 mA for 1 hour. Blocker™ Casein (Pierce) was used for 1 hour (room temperature) to block the membrane. Then, the membrane was washed twice with Tris-buffered saline/Tween 20. The membrane was stored overnight (4°C) with the respective primary antibodies (Santa Cruz Biotechnology, Dallas, TX, USA; Abcam, Cambridge, UK). A monoclonal mouse β -actin antibody (1:1,000; Santa Cruz Biotechnology) was used as a loading control. Then, after a 1-hour incubation (at room temperature) with goat anti-mouse and goat anti-rabbit secondary antibodies conjugated with alkaline phosphatase (i-DNA, Coralville, IA, USA; 1:1,000), the membrane was washed again with Tris-buffered saline/Tween 20. The nitro-blue tetrazolium and 5-bromo-4-chloro-3'-indolyphosphate (Santa Cruz Biotechnology) solution was used to visualize the blotting of the targeted proteins. The Western blot analysis was developed for the Hsp70 (Assay Designs, Ann Arbor, MI, USA; 1:1,000) and Bax (Assay Designs, Ann Arbor, MI, USA; 1:1,000) apoptotic proteins. The Western blot images were quantified and processed by ImageJ software (Bethesda, MD, USA).

Gastric tissue homogenate preparation

The glandular portions of the gastric tissue were excised and washed with ice-cold normal saline. Using a homogenizer

(Polytron; Eschbach, Germany), half of the stomach was homogenized in ice-cold phosphate-buffered saline (0.1 mol/L) containing a mammalian protease inhibitor cocktail.¹³ The homogenates were centrifuged at 4,500 rpm for 15 minutes at 4°C. The biological activities of the gastric homogenate supernatant were measured.

Biological activities of gastric homogenate Evaluation of superoxidase, catalase, and lipid peroxidation activities

One of the lipid peroxidation indicators is oxidative stress, which can be assessed by the malondialdehyde (MDA) tissue level. The MDA level of the gastric tissue homogenate was measured using a Cayman's TBARS assay kit (Cayman Chemical Co., Ann Arbor, MI, USA). The catalase (CAT) activity was measured using a Cayman's CAT assay kit based on the manufacturer's protocol (Cayman Chemical Co.). A Cayman's assay kit was used to measure superoxide dismutase (SOD) activity according to the manufacturer's protocol (Cayman Chemical Co.).

Protein concentration measurement

The protein concentration (mg/mL tissue) in the gastric homogenate of the rats was measured according to the biuret reaction procedure explained by Gornall et al.³⁶

Statistical analysis

The values are represented as the mean \pm standard deviation. Differences were calculated between groups using one-way analysis of variance software and Tukey's post hoc multiple comparison test. A value of $P < 0.05$ was considered significant.

Results

Acute toxicity test

All of the rats (36/36) were healthy, and none of them showed signs of morbidity or mortality throughout the 2-week duration. The histology of the liver and kidneys showed no hepatotoxicity or nephrotoxicity (Figure 1). Serum biochemical parameters were within normal range (Tables 1 and 2 and Figure 1).

Effect of MHAЕ on the macroscopic appearance of the gastric mucosa in ethanol-induced gastric mucosal lesions in rats

Macroscopically, the normal control group exhibited no injury to the gastric mucosa. The areas of the gastric mucosal ulcers were significantly higher in the ulcer control group. Serious injuries to the mucosal capillaries and vascular permeability were greater compared with the groups pretreated

with omeprazole or MHAЕ, which showed gastric protection. Rats pretreated with the low (60.93%) and high dosage (71.51%) of MHAЕ or omeprazole showed a significant reduction in gastric mucosal lesion formation and flattening of the gastric mucosal folds compared to the ulcer control group (Table 3 and Figure 2).

Effects of MHAЕ on the gastric content pH and gastric wall mucus in ethanol-induced gastric mucosal lesions in rats

Rats pretreated with omeprazole (reference control group) or MHAЕ had a significantly higher gastric content pH compared to the ulcer control group (Table 3).

The ulcer control group exhibited a significant decrease in gastric wall mucus content compared to animals pretreated with omeprazole or MHAЕ (Table 3). The effect of MHAЕ revealed a significant increase in the gastric wall mucus content (Table 3).

Effect of MHAЕ on the gastric mucosal histology in ethanol-induced gastric mucosal injuries

Effect of MHAЕ on the histology of gastric mucosal lesions

The ulcer control group presented remarkably extensive injuries to the gastric mucosa, which deeply penetrated into the gastric epithelium. There was extensive submucosal layer edema with leukocyte infiltration (Figure 3). Animals pretreated with omeprazole or MHAЕ showed remarkably far better protection of the gastric mucosa compared to the ulcer control group. It was followed by a decrease in mucosal injuries and submucosal edema with leukocyte infiltration (Figure 3).

Effect of MHAЕ on the gastric mucosal glycoprotein histology in ethanol-induced gastric mucosal injuries

PAS staining was used to evaluate glycoprotein production in the gastric epithelium. Rats pretreated with omeprazole or MHAЕ showed a remarkably increased intensity of PAS staining of the gastric mucosa compared with the ulcer control group. This shows that MHAЕ has the ability to protect against the glycoprotein content reduction induced by ethanol (Figure 4).

Effect of MHAЕ on the immunohistochemical staining (Hsp70 and Bax proteins) of gastric mucosa in ethanol-induced gastric mucosal injuries

Animals pretreated with omeprazole or MHAЕ exhibited a remarkable overexpression of the Hsp70 protein.

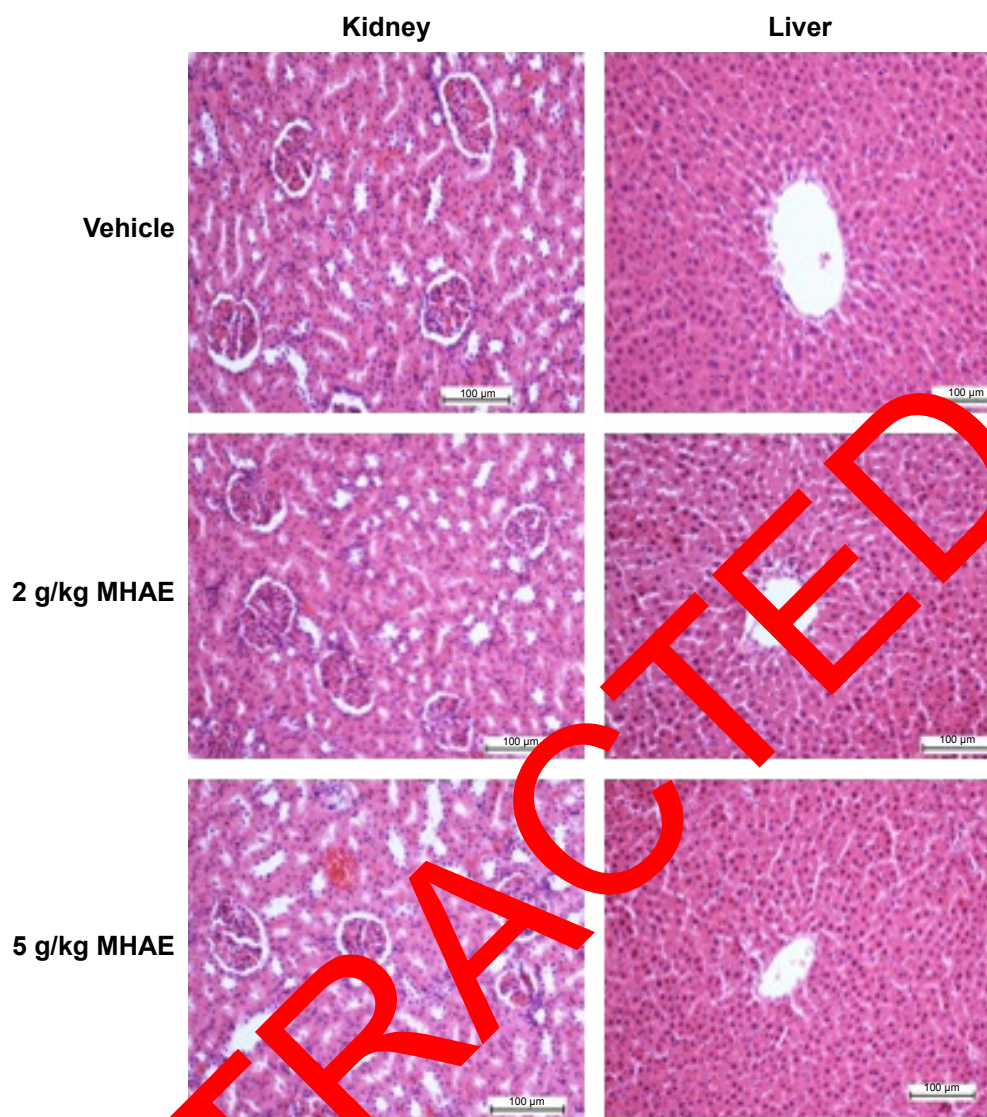


Figure 1 Histological investigation of acute toxicity analysis.

Note: Effect of MHAE on histological sections of the liver and kidneys in an acute toxicity test (H&E stain).

Abbreviations: MHAE, hydroalcoholic extract of *Monolluma quadrangula*; H&E, hematoxylin and eosin.

Table 1 Effects of MHAE on the renal function test in rats

Dose	Sodium (mmol/L)	Potassium (mmol/L)	Chloride (mmol/L)	CO ₂ (mmol/L)	Anion gap (mmol/L)	Urea (mmol/L)	Creatinine (µmol/L)
Vehicle (10% Tween 20)	141.87±1.17	4.91±0.26	104.77±1.42	24.08±1.13	18.19±0.90	5.55±0.68	32.35±1.33
MHAE (2 g/kg)	143.12±1.25	5.28±0.18	105.59±1.28	22.68±1.15	18.48±0.85	6.23±0.74	34.26±1.40
MHAE (5 g/kg)	139.23±0.40	5.33±0.29	104.28±0.16	23.11±0.89	18.14±0.75	5.67±0.43	35.02±1.31

Notes: Values are expressed as the mean ± SEM. There are no statistically significant differences between the measurements of the different groups. Significance was set at $P < 0.05$.

Abbreviations: MHAE, hydroalcoholic extract of *Monolluma quadrangula*; SEM, standard error of the mean.

Table 2 Effects of MHAE on the liver function test in rats

Dose	Total protein (g/L)	Albumin (g/L)	Globulin (g/L)	TB (µmol/L)	CB (µmol/L)	AP (IU/L)	ALT (IU/L)	AST (IU/L)	GGT (IU/L)
Vehicle (10% Tween 20)	61.51±1.28	9.25±0.48	51.08±1.54	2.18±0.17	1.00±0.00	153.33±4.22	49.25±1.71	172.09±6.09	3.25±0.19
MHAE (2 g/kg)	58.72±1.35	8.63±0.50	49.39±1.71	2.13±0.18	1.00±0.00	155.02±4.08	48.43±1.85	178.16±5.18	3.57±0.22
MHAE (5 g/kg)	62.09±0.56	9.04±0.33	50.49±0.93	2.04±0.23	1.00±0.00	153.16±5.11	51.47±3.19	175.22±5.79	3.72±1.17

Notes: Values are expressed as the mean ± SEM. There are no significant differences between groups. Significance was set at $P < 0.05$.

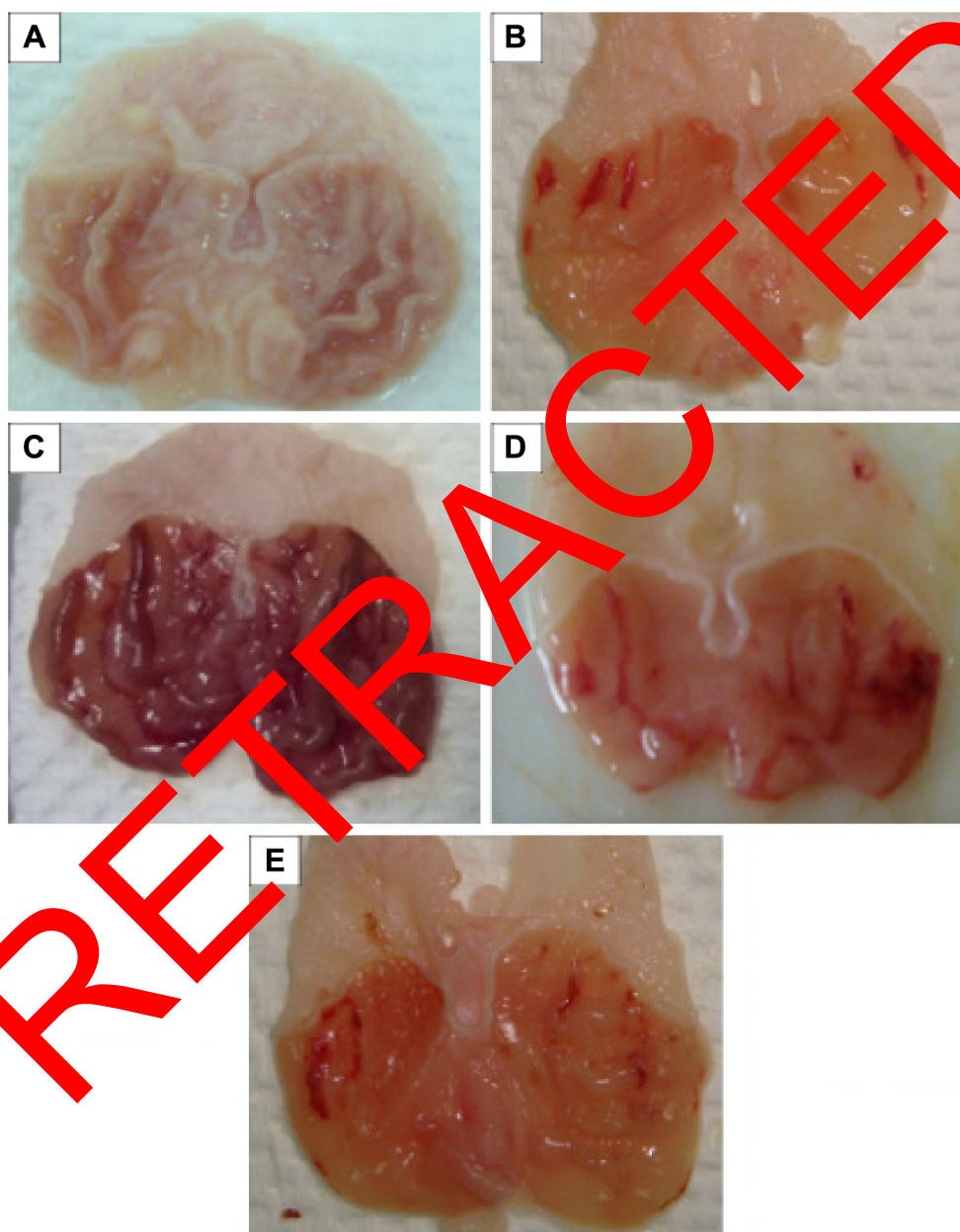
Abbreviations: MHAE, hydroalcoholic extract of *Monolluma quadrangula*; TB, total bilirubin; CB, conjugated bilirubin; AP, alkaline phosphatase; ALT, alanine aminotransferase; AST, aspartate aminotransferase; GGT, γ-glutamyl transferase; SEM, standard error of the mean.

Table 3 Effects of MHAЕ on pH, mucus, ulcer areas, and % inhibition

Animal's group	Pretreatment	pH of stomach	Mucus weight (g)	Ulcer areas (mm) ²	Inhibition of ulcer areas (%)
1	10% Tween 20	4.61±0.03	3.12±0.86	–	–
2	Absolute ethanol (5 mL/kg)	1.68±0.73	1.08±1.33	755.17±12.86	–
3	Omeprazole (20 mg/kg)	6.81±1.35*	5.46±1.38*	185.52±6.51*	75.43
4	MHAЕ 150 mg	4.63±0.64*	4.59±0.65*	295.05±9.25*	60.93
5	MHAЕ 300 mg	5.11±0.87*	5.11±0.82*	215.13±7.38*	71.51

Notes: All data are expressed as the mean ± SEM. *P<0.05 was considered significantly different. All values were compared with the ulcer control group.

Abbreviations: MHAЕ, hydroalcoholic extract of *Monolluma quadrangula*; SEM, standard error of the mean.

**Figure 2** Gastric mucosal macroscopic evaluation.

Notes: Effect of MHAЕ on the macroscopic appearance of the gastric mucosa in the ethanol-induced gastric mucosal injuries in rats. (A) The normal control group showed no injury to the gastric mucosa. (B) The ulcer control group showed severe hemorrhagic bands in the gastric mucosa. (C) The omeprazole group revealed mild hemorrhagic injuries and flattening of the gastric mucosa. (D) Rats pretreated with 150 mg/kg MHAЕ showed mild-to-moderate gastric mucosal injuries and flattening. (E) Rats pretreated with 300 mg/kg MHAЕ showed mild mucosal injuries and flattening.

Abbreviation: MHAЕ, hydroalcoholic extract of *Monolluma quadrangula*.

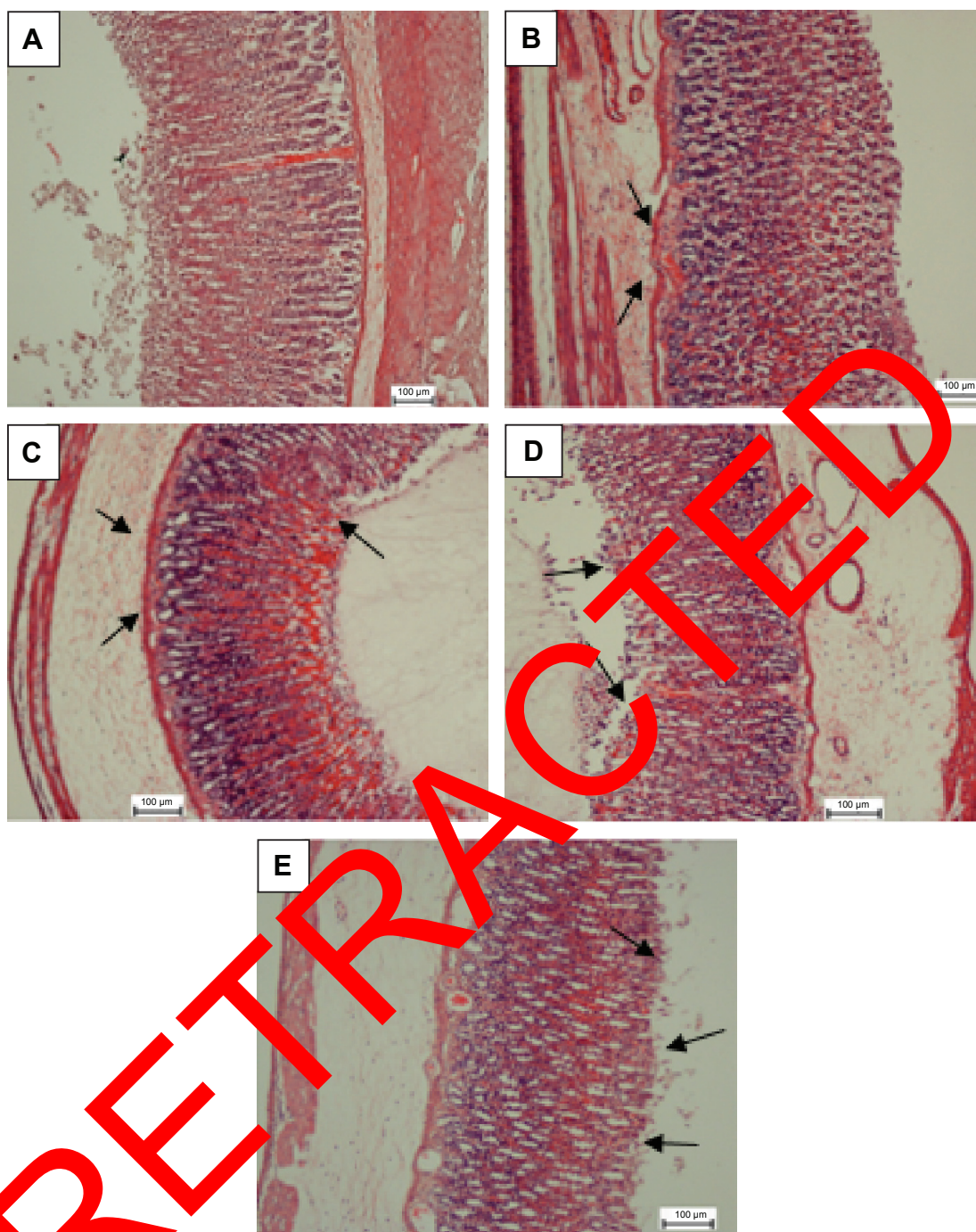


Figure 3 H&E evaluation of the gastric mucosa.

Notes: MHAE effect on the gastric mucosa histology in ethanol-induced gastric mucosal injury in rats. (A) The normal control group. (B) The ulcer control group exhibited a remarkably severe disruption to the gastric mucosa, which deeply penetrated into the mucosa with extensive edema and leukocyte infiltration of the submucosal layer. (C) The omeprazole group shows comparably mild disruption of gastric mucosa with mild edema and leukocytes infiltration of the submucosal layer. (D) Rats pretreated with 150 mg/kg showed mild-to-moderate gastric mucosa disruption with edema and leukocyte infiltration of the submucosal layer. (E) Rats pretreated with 300 mg/kg displayed mild disruption of the gastric mucosa with edema and leukocyte infiltration of the submucosal layer (H&E stain). The arrows show the H&E evaluation of the gastric mucosa.

Abbreviations: H&E, hematoxylin and eosin; MHAE, hydroalcoholic extract of *Monolluma quadrangula*.

The expression of Hsp70 protein in the groups pretreated with MHAE was upregulated compared to the downregulation of the Hsp70 protein in the ulcer control group (Figure 5). Immunostaining of Bax protein in rats pretreated with MHAE

showed a remarkable downregulation of the Bax protein. In animals pretreated with MHAE, the expression of Bax protein showed a downregulation compared to the ulcer control group (Figure 6).

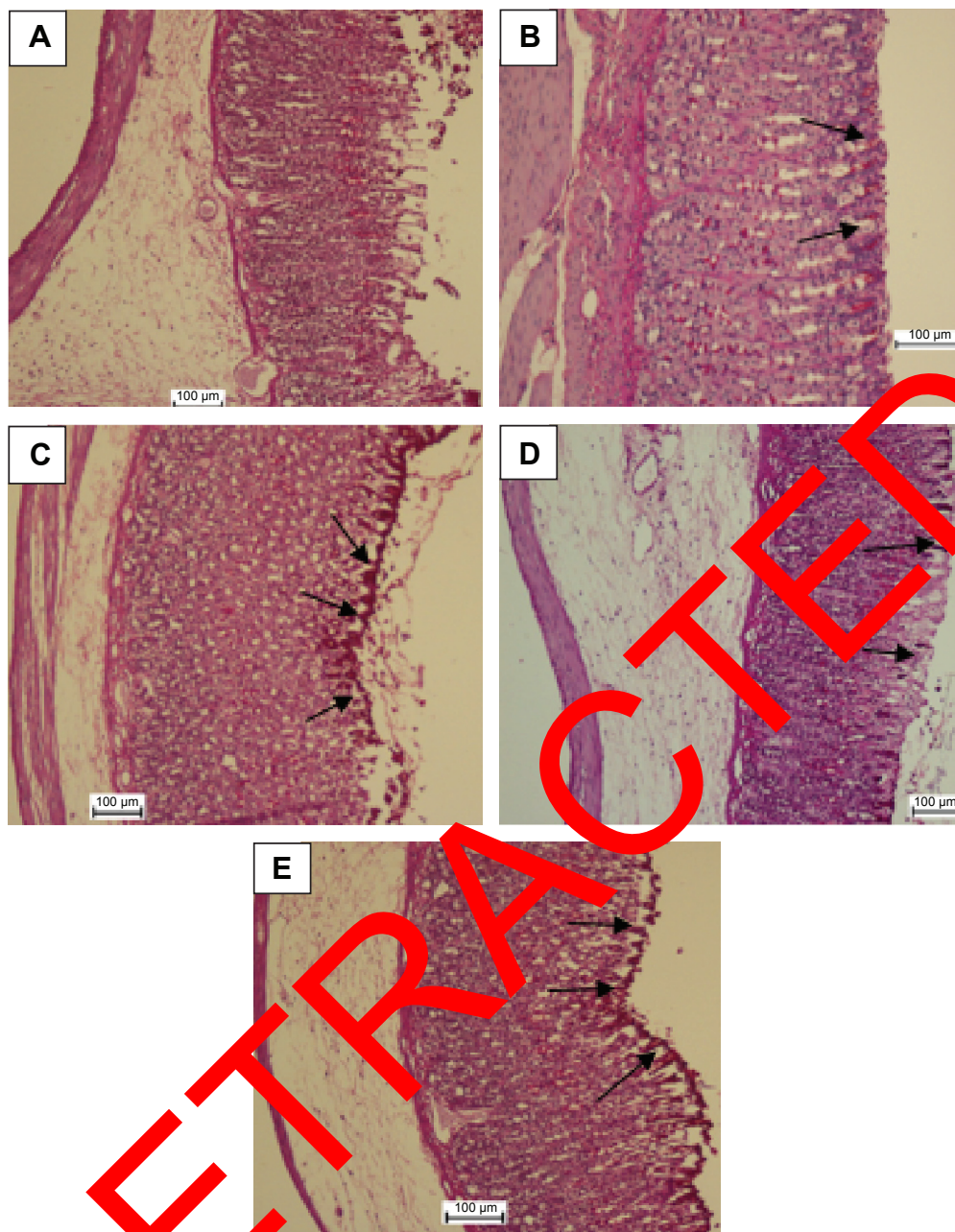


Figure 4 PAS staining evaluation.

Notes: MHAЕ effect on gastric mucosal glycoprotein – PAS staining in ethanol-induced gastric hemorrhagic injuries in rats. **(A)** The normal control group. **(B)** The ulcer control group. **(C)** Rats pretreated with 20 mg/kg omeprazole. **(D)** Rats pretreated with 150 mg/kg MHAЕ. **(E)** Rats pretreated with 300 mg/kg MHAЕ. The arrows show the gastric mucosal glycoprotein production.

Abbreviations: PAS, Periodic acid–Schiff; MHAЕ, hydroalcoholic extract of *Monolluma quadrangula*.

Western blot assay

Along with the Western blot results, the immunohistochemistry results confirmed that the control group and the groups treated with MHAЕ had increased expression level of Hsp70 protein in comparison with the ulcer control group. The ulcer control group presented a decline in the expression of Hsp70 compared with the normal control group, but the expression of Bax protein increased significantly in the groups pretreated with MHAЕ (Figure 7).

Effects of MHAЕ on the SOD and CAT activities and the MDA level of the gastric homogenate in ethanol-induced gastric mucosal damage in rats

In the gastric homogenate, SOD and CAT activities were significantly lower in the ulcer control group compared to the animals pretreated with omeprazole or MHAЕ (Table 4). The MDA level in the gastric homogenate was significantly

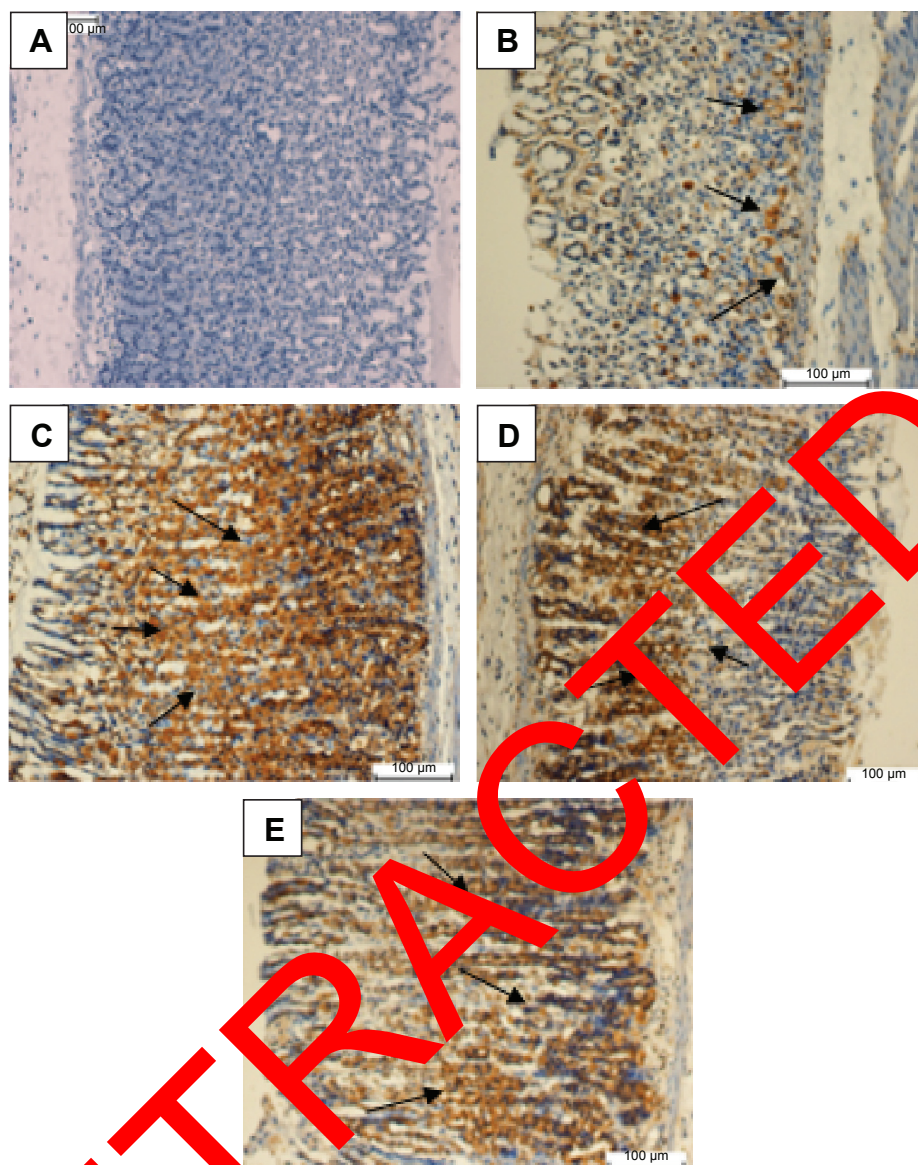


Figure 5 Evaluation of Hsp70 protein expression in gastric tissue.

Notes: The effect of MHAЕ on the expression of Hsp70 in ethanol-induced gastric mucosal injury in rats. **(A)** The normal control group. **(B)** The ulcer control group. **(C)** Rats pretreated with 200 mg/kg omeprazole. **(D)** Rats pretreated with 150 mg/kg MHAЕ. **(E)** Rats pretreated with 300 mg/kg MHAЕ (Hsp70 staining). The arrows show the level of Hsp70 protein expression.

Abbreviation: MHAЕ: hydroalcoholic extract of *Monolluma quadrangula*.

higher in the ulcer control group compared to rats pretreated with omeprazole or MHAЕ (Table 4).

Effects of MHAЕ on protein concentrations

There was a significant reduction in protein concentrations in the gastric homogenate in the ulcer control group compared to the rats pretreated with omeprazole or MHAЕ (Table 4).

Discussion

The acute toxicity trial showed no signs of noxiousness or demise in the applied dosage of MHAЕ. An oral intake of ethanol is destructive to the stomach tissue, which instigates

local damage to the stomach mucosa barrier and arouses changes in the vasculature.³⁷ A discharge of mucus is an important defense to protect stomach tissue from any deformation by stopping direct contact with the gastrointestinal enzymes.³⁸

Drinking absolute ethanol creates hemorrhagic wounds, mucosal friability, and extensive submucosal edema and causes injury to the epithelial cells of the gastric layer.³⁹ Drinking ethanol also decreases the protein concentration due to epithelial cell devastation.³⁶ However, ingesting MHAЕ led to an increased protection of epithelial cells, which was followed by a significant halt in the decreasing protein

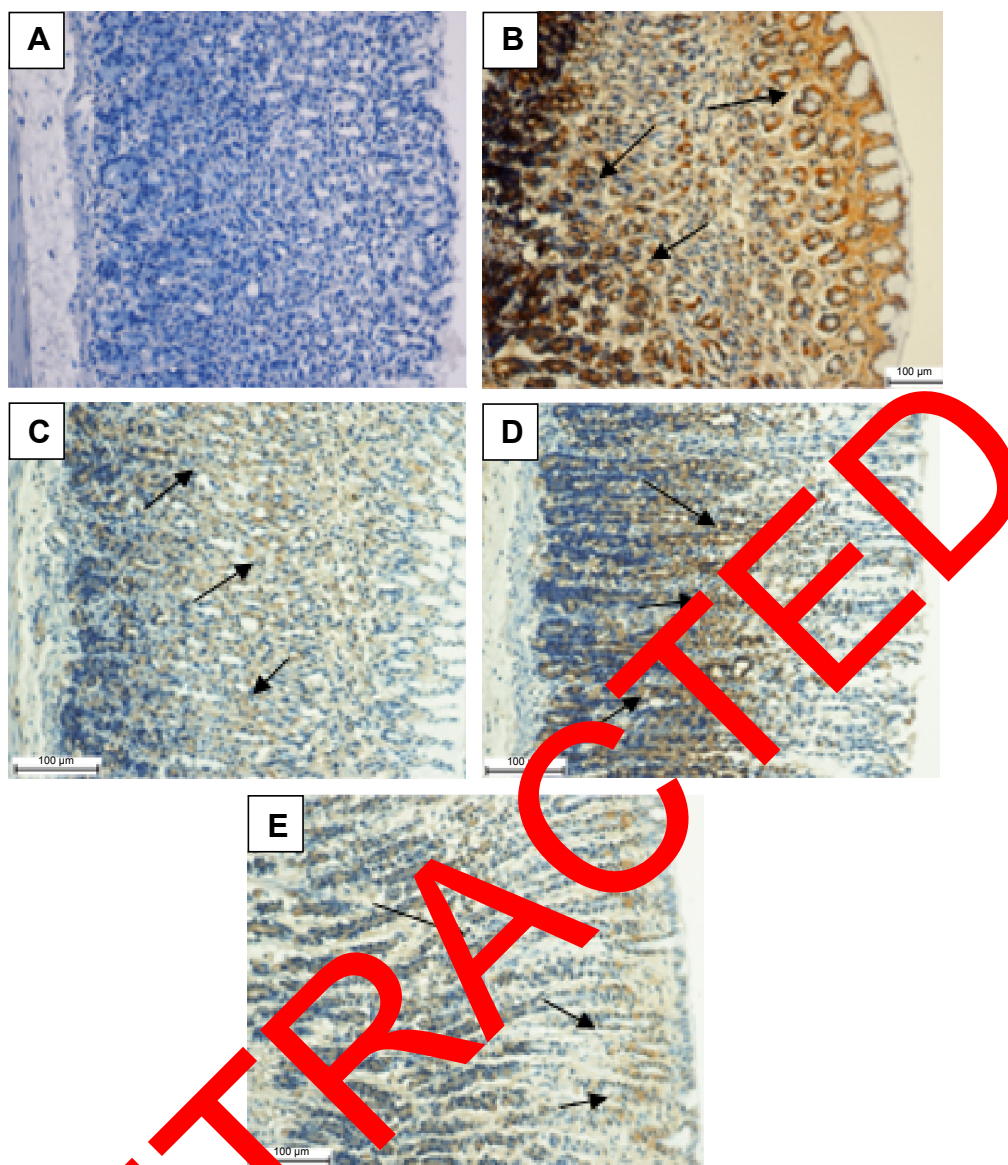


Figure 6 Evaluation of Bax protein expression in gastric tissue.

Notes: Effect of MHAE on the expression of Bax in ethanol-induced gastric mucosal injury in rats. (A) The normal control group. (B) The ulcer control group. (C) Rats pretreated with 20 mg/kg omeprazole. (D) Rats pretreated with 150 mg/kg MHAE. (E) Rats pretreated with 300 mg/kg MHAE (Bax staining). The arrows show the level of Bax protein expression.

Abbreviation: MHAE, hydroalcoholic extract of *Monolluma quadrangula*.

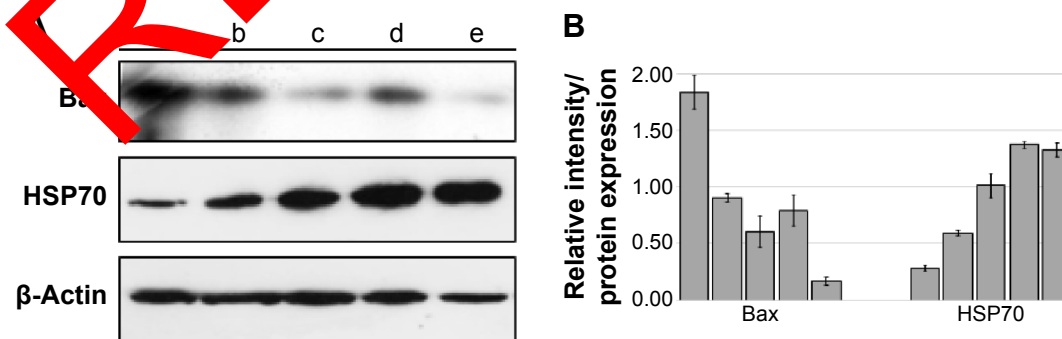


Figure 7 Western blot of Hsp70 and Bax.

Notes: (A) Western blot of (a) the normal control group, (b) ulcer control group. (c) rats pretreated with 20 mg/kg omeprazole, (d) rats pretreated with 150 mg/kg MHAE, and (e) rats pretreated with 300 mg/kg MHAE. (B) Relative intensity of each protein which was normalized with β-actin's intensity. Data were mean ± SD of two independent experiments ($P < 0.05$).

Abbreviations: MHAE, hydroalcoholic extract of *Monolluma quadrangula*; SD, standard deviation.

Table 4 Effects of MHAЕ on SOD, CAT, and MDA in ethanol-induced gastric ulcers in rats

Animal's group	Pretreatment	SOD (U/g)	CAT (nM/min/mL)	MDA (μ mol/g tissue)	Protein
1	10% Tween 20	6.01 \pm 1.68	91 \pm 1.99	10.67 \pm 1.09	14.73 \pm 0.23
2	Absolute ethanol (5 mL/kg)	4.06 \pm 0.33	61.88 \pm 2.59	23.55 \pm 2.08	10.56 \pm 0.55
3	Omeprazole (20 mg/kg)	12.58 \pm 1.75*	138.25 \pm 3.45*	11.95 \pm 1.15*	15.83 \pm 0.68*
4	150 mg MHAЕ	7.91 \pm 1.14*	98.85 \pm 1.36*	15.02 \pm 1.17*	13.50 \pm 0.59*
5	300 mg MHAЕ	10.05 \pm 1.37*	111.08 \pm 0.98*	13.19 \pm 1.13*	14.37 \pm 0.71*

Notes: All data are expressed as the mean \pm SEM. * P <0.05 was significantly different. All values were compared with the ulcer control group.

Abbreviations: MHAЕ, hydroalcoholic extract of *Monolluma quadrangula*; SOD, superoxide dismutase; CAT, catalase; MDA, malondialdehyde; SEM, standard error of the mean.

concentration. Omeprazole usage is very effective in curing gastrointestinal disorders in both acid- and nonacid-related models due to its effect as an acid inhibitor, a proton pump, and a mucosal defense.^{24,31,40,41}

As a result of flattening of the stomach's tissue folds, the resulting wider area can interact with agents. Furthermore, less gastric motility leads to a lower percentage of gastric mucosal damage.^{9,42} In the current study, treatment with MHAЕ exhibited a protective effect by decreasing gastric motility.

Oxidative stress in tissue produces agents such as superoxide and hydroxyl radicals, which play a significant role in disease progression. Therefore, eliminating these radicals is effective in preventing injury.⁴³ Keeping radicals at the proper level and increasing the levels of antioxidant enzymes, such as SOD and CAT, are both effective methods for preventing ulcers by rapidly converting the peroxy radical into biologically safe substances, such as water.⁴⁴

As a result of cell membrane damage, morphological and biochemical changes in gastric tissue increase the levels of lipid peroxidation.⁴⁵ In this study, treatment of the rats with MHAЕ caused a significant elevation in the levels of SOD and CAT and also decreased the expression of MDA.

Ethanol elicited mucosal congestion at the edges of the protective mucosal layer, indicating that necrosis and ulceration are occurring.³⁹ Long ethanol changes the features of the gastric tissue, and causes hemorrhages, edema, loss of epithelial cells and inflammatory infiltration.^{46,47} Histological evaluation of the stomach tissue showed that MHAЕ had an effective role against gastric damage caused by ethanol. In the PAS staining, which is an indicator of mucopolysaccharide secretion, the current study established that MHAЕ amplified the content of glycoprotein in the mucosa of the stomach, which was shown in a previous study.⁷

Apoptosis plays a significant role in decreasing gastric mucosal injuries caused by several different issues.^{48,49} The immunohistochemistry analysis of Hsp70 and Bax proteins in rats treated with MHAЕ showed an upregulation and downregulation, respectively, compared to the ethanol control group. A lower level of Bax expression as a proapoptotic factor is a sign of apoptosis. The expression of Hsp70 protein,

which is increased in response to stress, plays an important role in decreasing protein denaturation in the cell. Ethanol causes hemorrhagic mucosal damage, and the Hsp70 protein plays a defensive role through mitochondria and by stimulation of the apoptotic pathway. In this experiment, the expression levels of Hsp70 and Bax were confirmed through Western blotting.

Conclusion

Our study proved that the MHAЕ has an antiulcer effect against ethanol-induced gastric lesions in experimental rats. The gastroprotective effect of this potent medicinal plant could be associated with its free radical-scavenging activity, its ability to increase the endogenous activities of SOD and CAT antioxidants while reducing the level of MDA, and its ability to upregulate Hsp70 and downregulate Bax protein. The gastroprotective role of the MHAЕ could also be due to its stimulation of an anti-apoptotic pathway.

Acknowledgment

The authors would like to thank the RP043A/15HTM UMRG grant from University of Malaya for supporting this project.

Disclosure

The authors report no conflicts of interest in this work.

References

- Hoogerwerf WA, Pasricha PJ. Pharmacotherapy of gastric acidity, peptic ulcers, and gastroesophageal reflux disease. In: Brunton LL, Lazo JS, Parker KL, editors. *Goodman & Gilman's The Pharmacological Basis of Therapeutics*. 11th ed. New York: McGraw-Hill Medical Publishing Division; 2006:967–981.
- Stewart DJ, Ackroyd R. Peptic ulcers and their complications. *Surgery*. 2011;29:491–495.
- Ibrahim A, Qader SW, Abdulla M, et al. Effects of Pithecellobium jiringa ethanol extract against ethanol-induced gastric mucosal injuries in Sprague-Dawley rats. *Molecules*. 2012;17:2796–2811.
- Ibrahim A, Kamisah Y, Nafeeza M, et al. Modulation of gastric motility and gastric lesion formation in stressed rats given enteral supplementation of palm vitamin E and α -tocopherol. *Int Med J*. 2011;18:47–52.
- De Felice A, Bader A, Leone A, et al. New polyhydroxylated triterpenes and anti-inflammatory activity of *Salvia hiersosolymitana*. *Planta Med*. 2006;72:643–649.

6. Bader A, Giner R, Martini F, et al. Modulation of COX, LOX and NFκB activities by Xanthium spinosum L. root extract and ziniolide. *Fitoterapia*. 2013;91:284–289.
7. Hajrezaie M, Murain S, Karimian H, et al. Biochanin A gastroprotective effects in ethanol-induced gastric mucosal ulceration in rats. *PLoS One*. 2015;10:e0121529. doi:10.1371/journal.pone.0121529.
8. Abdulla M, Mohd Ali H, Abdul-Aziz A, et al. Evaluation of the anti-ulcer activities of Morus alba extracts in experimentally-induced gastric ulcer in rats. *Biomed Res India*. 2009;20:35–39.
9. Wasman S, Abdulla M, Chua L, et al. Antioxidant and gastroprotective activities of *Andrographis paniculata* (Hempedu Bumi) in Sprague Dawley rats. *Indian J Exp Biol*. 2011;49:767–772.
10. Indran M, Abdulla M, Kuppusamy U. Protective effect of Carica papaya L leaf extract against alcohol induced acute gastric damage and blood oxidative stress in rats. *West Indian Med J*. 2008;57:323–326.
11. Al Batran R, Al-Bayaty F, Abdulla M, et al. Gastroprotective effects of Corchorus olitorius leaf extract against ethanol-induced gastric mucosal hemorrhagic lesions in rats. *J Gastroenterol Hepatol*. 2013;28:1321–1329.
12. Moghadamtousi S, Rouhollahi E, Karimian H, et al. Gastroprotective activity of Annona muricata leaves against ethanol-induced gastric injury in rats via Hsp70/Bax involvement. *Drug Des Devel Ther*. 2014;28:2099–2111.
13. Nordin N, Salama S, Golbabapour S, et al. Anti-ulcerogenic effect of methanolic extracts from Eucosanthellum pulchrum (King) Heusden against ethanol-induced acute gastric lesion in animal models. *PLoS One*. 2014;9:e11925.
14. Gushash S. *Plants in the Mountains of Sarat and Hejaz*. Madinah, Saudi Arabia: Sarawat Designer and Printers; 2006.
15. Zakaria M, Islam M, Radhakrishnan R, et al. Anti-gastric ulcer and cytoprotective properties of Caralluma arabica. *Pharm Biol*. 2002;40:225–230.
16. Dutta AK, Chacko A, Balekuduru A, Sahu MK, Gangadharan SK. Trends in epidemiology of peptic ulcer disease in India over two decades. *Indian J Gastroenterol*. 2012;31:111–115.
17. Braca A, Bader A, Morelli I, et al. New pregnane glycosides from Caralluma negevensis. *Tetrahedron*. 2002;58:5837–5845.
18. Bader A, Braca A, De Tommasi N, et al. Further constituents from Caralluma negevensis. *Phytochemistry*. 2003;62:1177–1281.
19. Abdalla HM, Osman AM, Almehdar H, Abdel-Sattar M. Acylated pregnane glycosides from Caralluma quadrangulara. *Phytochemistry*. 2013;88:54–60.
20. Ismail F, Golbabapour S, Hassandarvish P, et al. Gastroprotective activity of Polygonum chinense aqueous leaf extract on ethanol-induced hemorrhagic mucosal lesions in rats. *Evid Based Complement Altern Med*. 2012;404012:9.
21. Al Sidahmed H, Hashim A, Amir J, et al. Pyrano-cycloartobioxanthone A, a novel gastroprotective compound from Mocaropus obtusus Jarret, against ethanol-induced acute gastric ulcers in vivo. *Phytomedicine*. 2013;20:834–843.
22. CHEMICALS DOFO. *OECD Guidelines for Testing of Chemicals*. 2005. ENV/JM/MONO(2005)5.
23. National Institute of Health. *Guide for the Care and Use of Laboratory Animals*. Washington DC: National Academies; 1985.
24. Rahim N, Hassandarvish P, Golbabapour S, et al. Gastroprotective effect of ethanolic extract of Curcuma xanthorrhiza leaf against ethanol-induced gastric mucosal lesions in Sprague-Dawley rats. *Biomed Res Int*. 2014;416409:10.
25. Hajrezaie M, Golbabapour S, Hassandarvish P, et al. Acute toxicity and gastroprotection studies of a new Schiff base derived copper (II) complex against ethanol-induced acute gastric lesions in rats. *PLoS One*. 2012;7:e51537.
26. Al Batran R, Al-Bayaty F, Al-Obaidi M, et al. In vivo antioxidant and antiulcer activity of Parkia speciosa ethanolic leaf extract against ethanol-induced gastric ulcer in rats. *PLoS One*. 2013;8:e64751.
27. Rouhollahi E, Moghadamtousi S, Hamdi O, et al. Evaluation of acute toxicity and gastroprotective activity of curcuma purpurascens BI. rhizome against ethanol-induced gastric mucosal injury in rats. *BMC Complement Altern Med*. 2014;14:378. doi:10.1186/1472-6882-14-378.
28. Qader S, Abdulla M, Chua L, et al. Pharmacological mechanisms underlying gastroprotective activities of the fractions obtained from Polygonum minus in Sprague Dawley rats. *Int J Mol Sci*. 2012;13:1481–1496.
29. Ketuly K, Hadi A, Golbabapour S, et al. Acute toxicity and gastroprotection studies with a newly synthesized steroid. *PLoS One*. 2013;8:e59296. doi:10.1371/journal.pone.0059296.
30. Wong J, Abdulla M, Raman J, et al. Gastroprotective effects of Lion's Mane mushroom Hericium erinaceus (Bull.:Fr.) Pers. (Aphyllphoromycetidae) extract against ethanol-induced ulcer in rats. *Evid Based Complement Altern Med*. 2013. doi:10.1155/2013/492976.
31. Golbabapour S, Gwaram N, Hassandarvish P, et al. Gastroprotection studies of Schiff base zinc (II) derivative complex against acute superficial hemorrhagic mucosal lesions in rats. *PLoS One*. 2013;8:e75036.
32. Taha M, Salga M, Mohd Ali H, et al. Gastroprotective activities of Turnera diffusa Willd. extract: revisited: role of arbutin. *J Ethnopharmacol*. 2012;142:273–280.
33. Hajrezaie M, Shams K, Zorofian M, Moghadamtousi S, et al. Chemoprevention of chemically aberrant foci by novel Schiff based dichlorido(2-methoxy-2-[[2-(piperazin-4-ium-1-yl)ethyl]iminomethyl]phenolate)Cd complex on azoxymethane-induced colorectal cancer in rats. *Cell Prolif*. 2015;5:123.
34. Golbabapour S, Hajrezaie M, Hassandarvish P, et al. Acute toxicity and gastroprotective effect of M. pruriens in ethanol-induced gastric mucosal injuries in rats. *Biomed Res Int*. 2013;974185:13.
35. Al Sidahmed H, Yahadah A, Syam M, et al. Gastroprotective effect of desferrioxamine B isolated from Mitrella kentii against ethanol-induced gastric mucosal hemorrhage in rats: possible involvement of glutathione, heat-shock protein-70, sulfhydryl compounds, nitric oxide, and anti-Helicobacter pylori activity. *BMC Complement Altern Med*. 2013;13:183.
36. Gornall AG, Bardawill CJ, David MM. Determination of serum proteins by means of the biuret reaction. *J Biol Chem*. 1949;177:751–766.
37. Ghosh M. Fundamentals of experimental pharmacology. *Indian J Pharmacol*. 2007;39:216.
38. Corne S, Morrissey S, Woods R. Proceedings: a method for the quantitative estimation of gastric barrier mucus. *J Physiol*. 1974;242:116P–117P.
39. Abdulla M, Fard A, Harita H. Evaluation of gastroprotective effects of Strobilanthes crispus leaf extract on ethanol-induced gastric mucosal injury in rats. *Sci Res Essays*. 2011;6:2306–2314.
40. Li XQ, Andersson TB, Ahlström M, et al. Comparison of inhibitory effects of the proton pump-inhibiting drugs omeprazole, esomeprazole, lansoprazole, pantoprazole, and rabeprazole on human cytochrome P450 activities. *Drug Metab Dispos*. 2004;32:821–827.
41. Schneeweiss S, Maclure M, Dormuth CR, et al. A therapeutic substitution policy for proton pump inhibitors: clinical and economic consequences. *J Clin Pharmacol*. 2006;79:379–388.
42. Abdulla M, Ahmed K, Al-Bayaty F, et al. Gastroprotective effect of Phyllanthus niruri leaf extract against ethanol-induced gastric mucosal injury in rats. *Afr J Pharm Pharmacol*. 2010;4:226–230.
43. Mofleh IA, Mofleh I, Alhaider A, et al. Gastroprotective effect of an aqueous suspension of black cumin Nigella sativa on necrotizing agents-induced gastric injury in experimental animals. *Saudi J Gastroenterol*. 2010;14:128.
44. Polat B, Suleyman H, Alp H. Adaptation of rat gastric tissue against indomethacin toxicity. *Chem Biol Interact*. 2010;186:82–89.
45. Gawł S, Wardas M, Niedworok E, et al. Malondialdehyde (MDA) as a lipid peroxidation marker. *Wiad Lek*. 2003;57:453–455.

46. Medeiros J, Gadelha G, Lima S, et al. Role of the NO/cGMP/KATP pathway in the protective effects of sildenafil against ethanol-induced gastric damage in rats. *Br J Pharmacol*. 2008;153:721–727.
47. Rios E, Rocha N, Venâncio E, et al. Mechanisms involved in the gastroprotective activity of esculin on acute gastric lesions in mice. *Chem Biol Interact*. 2010;188:246–254.
48. Rokutan K. Role of heat shock proteins in gastric mucosal protection. *J Gastroenterol Hepatol*. 2000;15:12–19.
49. Konturek P, Brzozowski T, Duda A, et al. Epidermal growth factor and prostaglandin E(2) accelerate mucosal recovery from stress-induced gastric lesions via inhibition of apoptosis. *J Physiol Paris*. 2001;95:361–367.

RETRACTED

Drug Design, Development and Therapy

Dovepress

Publish your work in this journal

Drug Design, Development and Therapy is an international, peer-reviewed open-access journal that spans the spectrum of drug design and development through to clinical applications. Clinical outcomes, patient safety, and programs for the development and effective, safe, and sustained use of medicines are a feature of the journal, which

has also been accepted for indexing on PubMed Central. The manuscript management system is completely online and includes a very quick and fair peer-review system, which is all easy to use. Visit <http://www.dovepress.com/testimonials.php> to read real quotes from published authors.

Submit your manuscript here: <http://www.dovepress.com/drug-design-development-and-therapy-journal>