

Anterior segment granuloma and optic nerve involvement as the presenting signs of systemic sarcoidosis

Marilita M Moschos¹
Yan Gueux-Crosier²

¹Department of Ophthalmology,
University of Athens, Athens, Greece;

²Jules Gonin Eye Hospital, University
of Lausanne, Lausanne, Switzerland

Purpose: To report a case with anterior and posterior nodules associated with systemic sarcoidosis.

Methods: A patient with decreased vision underwent complete ophthalmologic examination, ultrasound biomicroscopy, fluorescein and indocyanine green (ICG) angiography.

Results: The patient presented a nodule of the iris of the OS and of the optic nerves of both eyes. Chest computed tomography and tissue biopsy established the diagnosis.

Conclusions: Fluorescein and ICG angiography are the only objective exams to demonstrate the extent of ocular involvement in a patient with sarcoidosis.

Keywords: sarcoidosis, fluorescein angiography, indocyanine angiography

Case report

A 19-year-old black man noticed decreased vision in his OS for approximately 2 months. At presentation best-corrected visual acuity measured with a standard Snellen chart was 0.8 OS and 1.0 OD. Slit-lamp examination revealed the presence of a granulomatous nodule of the iris of the OS (Figure 1a), also detected by ultrasound biomicroscopy (UBM) (Figure 1b). Fundus examination showed a voluminous granuloma of the optic nerve of OS (Figure 2) and a granulomatous lesion of the OD, more visible on fluorescein angiography (Figure 3A, B), which shows optic disc leakage of OS and hyperfluorescence of OD. Multifocal choroidal lesions located in the posterior pole of the OS only visible with indocyanine green (ICG) were demonstrated (Figure 3C, D).

Systemic medical and laboratory work-up was performed in order to diagnose the granulomatous disease. Chest computed tomography showed hilar adenopathy. A tissue biopsy obtained from the nose proved the presence of noncaseating granuloma. The diagnosis of systemic sarcoidosis was established.

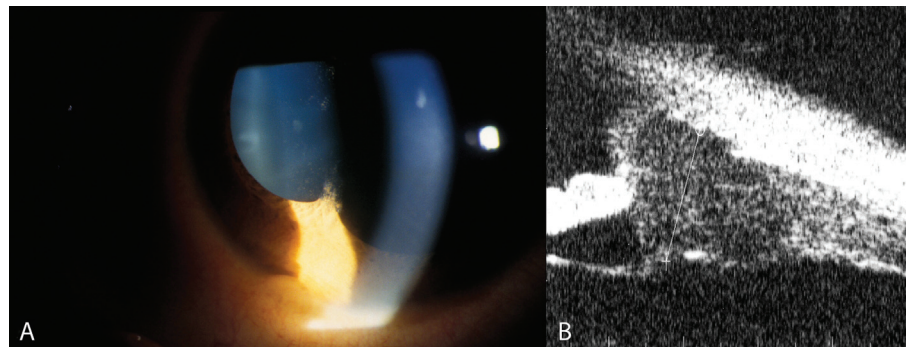


Figure 1 **A**, Large granuloma of the iris of OS. Keratic precipitates located on the lower part of corneal endothelium are also visible. **B**, Ultrasound biomicroscopy shows an homogenous, cystic-like lesion of the angle.

Correspondence: Marilita M Moschos
6, Ikarias street, Ekali, 14578, Athens,
Greece

Tel +30 69 4488 7319

Fax +30 21 0412 2139

Email moschosmarilita@yahoo.fr

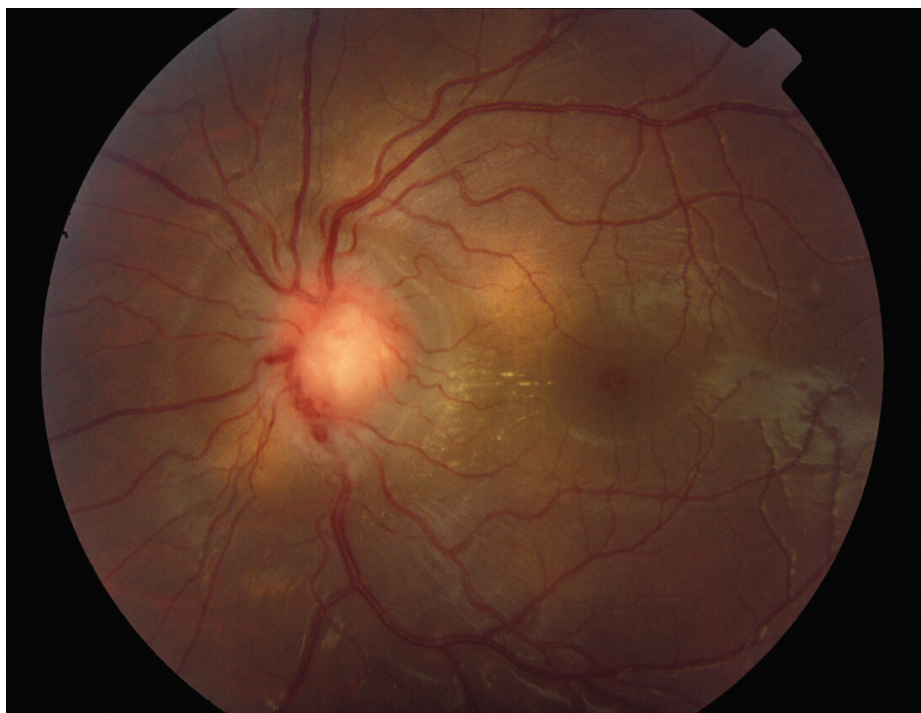

Figure 2 Fundus photograph OS shows the optic nerve granuloma caused by direct sarcoid tissue infiltration.

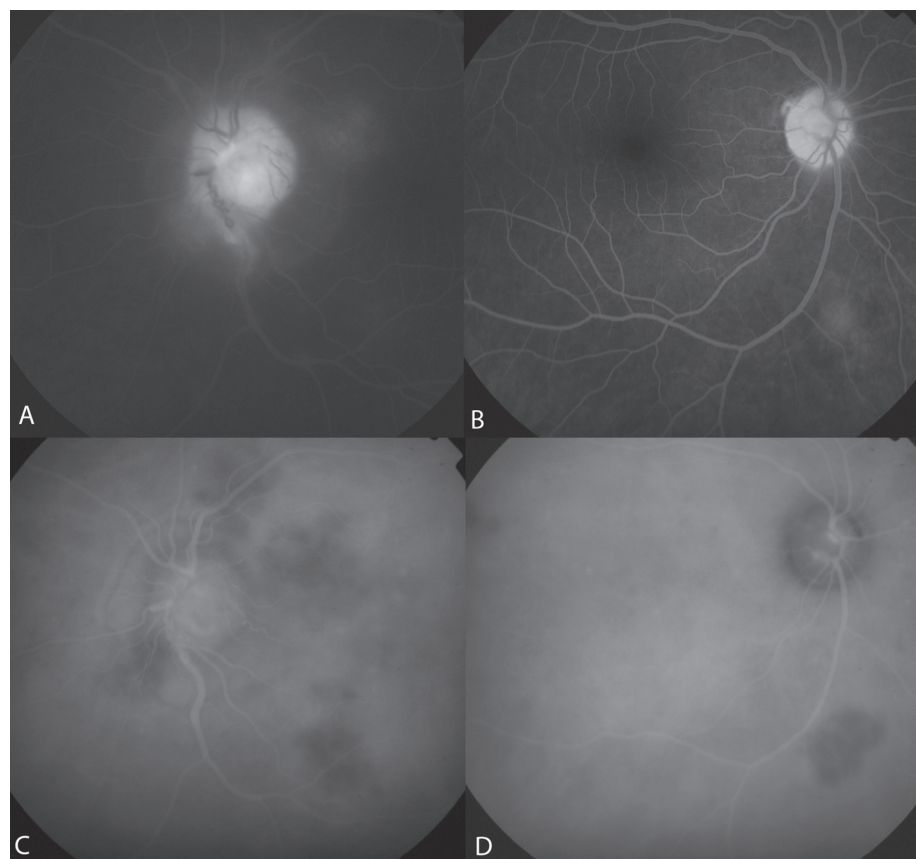

Figure 3 **A**, Late-phase fluorescein angiogram OS showing optic disc leakage secondary to uveitis. **B**, Late-phase fluorescein angiogram OD exhibits an hyperfluorescent area corresponding to the granuloma. **C**, Late-phase ICG angiogram OS reveals multiple choroidal hypofluorescent lesions of the posterior pole, optic disc leakage secondary to uveitis. **D**, Late-phase Indocyanine angiogram OD showing a single hypofluorescent area corresponding to the granuloma.

Sarcoidosis is a chronic multisystemic granulomatous disorder thought to result from an exaggerated cellular immune response to a variety of self antigens or nonself antigens (Newman et al 1997). The disease affects predominantly the lungs and thoracic lymph nodes, skin and eyes (Margolis 2007; Chan et al 2007). In this case report, the fluorescein angiography remains a standard technique for monitoring the posterior segment activity. However, only the ICG angiography was capable of demonstrating the widespread extent of choroidal involvement.

Disclosure

The authors report no financial support or conflicts of interest in this work.

References

- Chan SM, Hudson M, Weis E, et al. 2007. Anterior and intermediate uveitic cases referred to a tertiary centre in Alberta. *Can J Ophthalmol*, 42:860–4.
- Margolis. 2007. Sarcoidosis. *Curr Op Ophthalmol*, 18:470–5.
- Newman LS, Rose CS, Maier LA, et al. 1997. Sarcoidosis. *N Engl J Med*, 336:1223–34.

