

A review of results after implantation of a secondary intraocular lens to correct residual refractive error after cataract surgery

Kjell Gunnar Gundersen¹
Rick Potvin²

¹Ifocus Øyeklinikk AS, Haugesund, Norway; ²Science in Vision, Akron, NY, USA

Purpose: The purpose of this study was to provide clinical outcomes data related to secondary intraocular lens (IOL) implantation for the correction of residual refractive error after cataract surgery.

Patients and methods: A chart review was conducted to identify all eyes implanted with the monofocal spherical or toric AddOn[®] secondary IOL. Data were collated from charts where uncomplicated initial cataract surgery was completed. Measures of interest included the original IOL implanted, the postoperative refractive error (before secondary IOL implantation) and the associated corrected and uncorrected visual acuities (VAs). Postoperative data of interest included the residual refractive error, the best-corrected visual acuity (BCVA) and uncorrected visual acuity (UCVA).

Results: Refractive and VA data from 1 week to 3 months post-surgery were available for 46 of 70 eyes implanted with a secondary IOL by one surgeon at one practice between 4/15 and 3/17. There was a statistically significant improvement in UCVA of about 2 lines after surgery ($p < 0.01$), with no change in BCVA ($p = 0.94$). No eyes lost a line of BCVA. There was a statistically significant reduction in the absolute magnitude of the residual spherical equivalent refractive error ($p < 0.01$). In the 10 cases with a toric secondary IOL, there was a statistically significant reduction in refractive cylinder ($p < 0.01$).

Conclusion: The secondary IOL studied here appears to be a viable surgical option to correct residual refractive error after primary IOL implantation.

Keywords: AddOn, piggyback, toric, astigmatism, multifocal, secondary IOL

Plain language summary

In cataract surgery, the lens with the cataract is removed and a replacement lens is implanted. The replacement lens power can be selected such that many patients will not require spectacles for distance vision after the surgery. Some patients have a lens implanted that helps to provide vision at distance and close up – they expect to have good vision without glasses for driving and reading. Because the eye is a bit different in every person, determining the best power for the replacement lens is not always possible. Patients who need glasses after cataract surgery to see well at distance have a residual refractive error. Some patients would not mind wearing glasses to correct this, though others may want to undergo a second treatment to increase the likelihood of not needing glasses. This manuscript concerns treating residual refractive error using a specially designed second lens implanted on top of the first one. Results show that distance vision improves significantly after the second lens is implanted. While not conclusive, because the number of cases is small, the results here also suggest that the surgery is safe. Implanting a second lens appears to be a viable option for correcting residual refractive error after cataract surgery.

Correspondence: Kjell Gunnar Gundersen
Ifocus Øyeklinikk AS, Sørhauggata 111,
5527 Haugesund, Norway
Tel +47 52 80 8900
Email kg@ifocus.no

Introduction

Modern cataract surgery may be considered a refractive procedure; this is particularly the case when multifocal and/or toric intraocular lenses (IOLs) are being implanted. However, in a percentage of patients the refractive outcome can be suboptimal. The requirement for a secondary procedure to reduce residual refractive error after refractive lens exchange and multifocal IOL implantation has been reported to be as high as 24%.¹ This rate is likely partially attributed to patients' high expectations for excellent visual outcomes after implantation of such IOLs.² A conservative approach to treating this residual refractive error might include spectacles and/or contact lenses, but the patients do not achieve their goal of relying on less for such correction. Alternatively, there are various surgical methods to correct this residual refractive error; these include corneal laser refractive surgery (eg, LASIK or PRK), IOL exchange or an additional lens implanted in the sulcus. The choice of procedure is often left with the surgeon, considering the patients' needs and their ocular health.

Corneal refractive surgery, such as LASIK, has been shown to provide excellent results in cases of pseudophakic refractive errors, especially when the residual refractive error is myopia.^{3,4} However, one study reported that fewer than 50% of eyes treated with LASIK after cataract surgery had 20/20 or better VA.⁴ This may be because LASIK can exacerbate certain corneal conditions, such as dry eyes, which may be more common in the older cataract surgery population. In addition, corneal refractive procedures may negatively affect the aberrations of the eye, more so than with a lens-based procedure.⁴ LASIK may also be contraindicated in patients whose refractive error correction cannot be safely performed due to corneal pathology and/or thin corneal thickness.⁵ If a secondary correction is desired less than 3 months after the original cataract surgery, then corneal refractive surgery may also be contraindicated; it may take more time for postoperative corneal edema to fully resolve.⁴

IOL exchange is another surgical alternative to reduce residual refractive error. However, it may be contraindicated if removal of the previously implanted primary IOL is expected to be especially challenging, such as where the loss of the posterior capsule is likely or if zonular integrity is a concern. When compared with IOL exchange, one study noted that piggyback or secondary lens implantation in the sulcus had 15% and 10% more eyes with visual acuity (VA) of 20/20 or better and spherical equivalent refraction within 0.5D, respectively.⁵ This was attributed to the fact that piggyback lens implantation does not alter the refractive state of the eye, which may provide slightly more precise outcomes.⁵

Some possible complications after piggyback lens implantation include iris chafing or interlenticular opacification, both of which can be significantly minimized by placing the lens in the sulcus and using a lens that does not have sharp edges. Results after implantation of a second lens in the sulcus show good effectivity and safety.⁶⁻⁸

A secondary sulcus lens (sometimes referred to as piggyback or add-on lens) may offer benefits beyond correction of simple residual refractive error after monofocal primary lens implantation. For instance, implantation of a second lens in the sulcus in patients originally implanted with a multifocal lens in the bag has been demonstrated to safely provide improved visual outcomes.⁹⁻¹¹ If residual astigmatism is problematic, implantation of a toric lens in the sulcus has been previously demonstrated to be effective.¹²

Toric lenses have been used in more complicated post-keratoplasty cases, wherein high amounts of refractive astigmatism in pseudophakic patients were significantly reduced.¹³

The current manuscript provides a review of clinical outcomes with one model of secondary IOL, the A4 AddOn[®] IOL (1stQ GmbH, Mannheim, Germany). The AddOn secondary IOL is a hydrophilic acrylate lens with a 6 mm optic diameter and an overall diameter of 13.0 mm. It has four soft flexible haptics, a convex-concave optic and a square shape to improve stability in the sulcus, reduce edge light scatter and help maintain a constant distance between it and the posterior primary lens (Figure 1). The lens is available in monofocal, toric and multifocal designs; the latter was not considered in the current study. The lens is available in power from -10D to +10D for the monofocal and toric models and in cylinder powers from +1.0D to +1.1D are available.

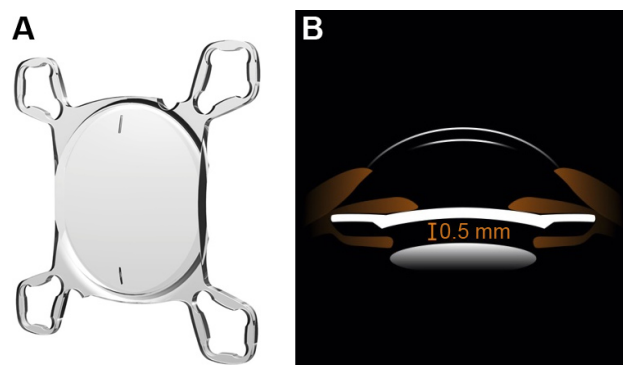


Figure 1 Design (A) and sulcus location (B) of the AddOn[®] secondary IOL. **Notes:** (A) AddOn IOL, toric marks visible. Haptics are designed for rotational stability in the sulcus. (B) Convex-concave optic design avoids IOL touch, reduces potential for iris chafing. Courtesy 1stQ GmbH, used with permission. **Abbreviation:** IOL, intraocular lens.

The only peer-reviewed study discussing this new secondary IOL (that we are aware of) was a study performed on postmortem pseudophakic human eyes.¹⁴ The results of the study suggested that the distance between the primary in-the-bag lens and the AddOn secondary lens was sufficient and predictable. The AddOn IOL was well aligned, though with some mild tilt in relation to the primary lens in a few cases, presumed due to compromised zonules.¹⁴

The purpose of the current study was to provide the first normative data related to the clinical performance of the AddOn secondary IOL when placed in the sulcus to correct residual refractive error (sphere and cylinder) in pseudophakic eyes.

Patients and methods

The Local Ethics Committee of Regionale komiteer for medisinsk og helsefaglig forskningsetikk, Norway, has advised the practice that ethics review for retrospective data analysis of de-identified data (ie, data with no protected health information) is not required. Patients in the practice are advised that their de-identified data may be used for clinical research purposes; they may permit or deny such use and their signed consent (if applicable) is retained in their patient file. No patient identifiers are included in the analyzed data.

A chart review for one surgeon in one clinical practice was conducted to identify all eyes implanted with the monofocal spherical or toric AddOn IOL in a 2-year period. Data were collated from charts where uncomplicated initial cataract surgery was completed. Measures of interest included the original IOL implanted, the postoperative refractive error (before secondary IOL implantation) and the associated corrected and uncorrected VAs. Postoperative data of interest included the time since secondary IOL implantation, the residual refractive error and the best-corrected visual acuity (BCVA) and uncorrected visual acuity (UCVA). VA data from 1 week to 3 months after secondary implantation were considered, with the latest VA data available for any given eye used for the analysis. VA data were converted to logMAR for the purposes of analysis.

The appropriate power for the AddOn secondary IOL was determined by the manufacturer. The manifest refraction, axial length, current keratometry and pseudophakic anterior chamber depth were provided, along with the target refraction and the initial IOL power and type (when known). A calculation for both IOL sphere and cylinder power was performed by 1stQ for all these patients. The surgeon was provided several lens powers around the target refraction, with the residual refraction for each power shown. The least-minus

refraction was chosen in the majority of cases, unless the expected hyperopic residual refraction was minimal.

Data were collated in Microsoft Excel and imported to Microsoft Access for preliminary review and data checking (both Microsoft Corporation, Redmond, WA, USA). Statistica version 13 was used for statistical analyses (Dell Inc., Tulsa, OK, USA). Statistical analyses of parametric variables were performed using analysis of variance, while categorical data were analyzed using appropriate non-parametric tests. In all cases, statistical significance was set to $\alpha=0.05$.

Results

A review of records from 4/15 to 3/17 was conducted to identify all eyes with secondary lens implantations with the IOL in question, yielding a total of 70 eyes. Of these, 49 included refractive and VA data in the range from 1 week to 3 months after secondary lens implantation. One eye of one patient had an epiretinal membrane, and significant posterior capsular opacification was noted in both eyes of another patient. Excluding these cases, the remaining 46 eyes were used for detailed analysis.

Table 1 contains a summary of the preoperative data related to these eyes. All but 2 eyes (44/46, 96%) had some type of multifocal IOL originally implanted. The refractive goal for all eyes, with one exception, was emmetropia.

Figure 2 shows the distribution of uncorrected and best-corrected distance logMAR VA before and after the secondary lens implantation. There was a statistically significant increase in UCVA after secondary IOL implantation, with an average change of almost 2 lines ($0.22\pm 0.12-0.04\pm 0.12$, $p<0.01$). Only 3 eyes had a UCVA more than 1 line worse than preoperative. One was due to planned myopia, one due to residual refractive astigmatism after a spherical secondary IOL implant and one related to residual refractive astigmatism due to misorientation of the secondary IOL (discussed later in the paper). IOL type (trifocal, EDOF or bifocal) was not a statistically significant co-factor ($p=0.88$).

There was no statistically significant difference in BCVA (-0.02 ± 0.07 at both time periods, $p=0.94$). Fourteen of 44 eyes (32%) with BCVA data had a loss of BCVA, but it was less than a logMAR line in all cases, and no eye had worse BCVA than logMAR 0.1 (20/25, 0.8 decimal) after secondary IOL implantation. Similarly, 11 eyes had a gain in BCVA; again, all changes were less than 1 logMAR line. IOL type (trifocal, EDOF or bifocal) was not a statistically significant co-factor ($p=0.65$).

Figure 3 shows the distribution of the spherical equivalent refraction (relative to target) for eyes before and after surgery.

Table 1 Preoperative summary

	n	Details	Notes
Cataract/refractive lens exchange	45	20/25	1 case referred, unknown
Age at original surgery (years)	46	57.1±8.7 (43 to 75)	
Axial length	46	23.59±1.93 (20.26 to 29.06)	
Time between surgeries (months)	46	17.3±19.2 (3 to 88)	Median 9 months
Spherical/toric secondary lens	46	36/10	All monofocal
Myopic/hyperopic secondary lens	46	19/25	2 astigmatism-only
Original implant lens types			
Extended depth of focus	21		
Trifocal	13		
Bifocal	9		
Other	3		
Secondary lens sphere power (D)		-0.27±1.11 (-2.5 to 1.5)	

Note: Data presented as mean ± standard deviation (range).

Abbreviation: n, number of eyes.

Three quarters (76%, 35/46) of postoperative eyes were within 0.50D of the intended target, while 57% (26/46) were within 0.25D of intended. Seven eyes had residual spherical equivalent refraction of -0.625D. The mean postoperative spherical equivalent refraction was -0.25D. The absolute reduction in residual spherical equivalent refractive error was statistically significant ($1.02±0.49-0.36±0.30$, $p<0.01$). IOL type (trifocal, EDOF or bifocal) was not a statistically significant co-factor ($p=0.58$).

There were 10 eyes treated with a toric secondary IOL, 8 of which included a spherical refractive change as well. All eyes preoperatively had 1.00D–2.25D of refractive astigmatism. After secondary IOL implantation, 60% of eyes (6/10) had 0.25D or less of residual refractive astigmatism and 70% (7/10) had 0.5D or less of residual refractive astigmatism. The reduction in refractive astigmatism was statistically significant ($1.35±0.36-0.42±0.47$, $p<0.01$).

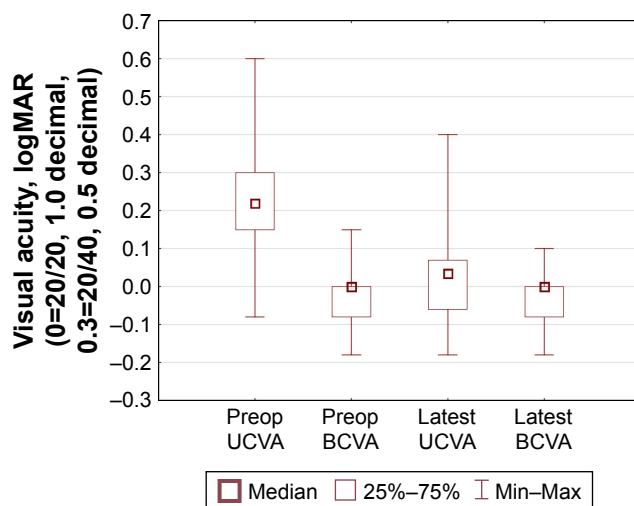


Figure 2 UCVA and BCVA before and after secondary IOL implantation.

Abbreviations: IOL, intraocular lens; Preop, preoperative; UCVA, uncorrected visual acuity; BCVA, best-corrected visual acuity.

Only 1 eye had more than 0.75D of residual refractive astigmatism. In this instance, the secondary IOL was observed to have rotated out of position. A realignment was attempted but the lens rotated again. A second realignment was not attempted due to concern with the stability of the zonules in this eye.

For the time period analyzed here, and to date, we have observed no case of hypertonia or hypotonia. There has also been no evidence of iris pigment dispersion after implantation of the secondary lenses and no cases of interlenticular opacification.

Discussion

Results with this secondary IOL implanted in the sulcus demonstrated improved UCVA with no significant change in best-corrected acuity. The type of primary IOL implanted in the bag did not have a significant effect on these outcomes; it appears that the performance of the secondary IOL is independent of what lens was used for the original surgery. This consistency is likely related to the predictable positioning of the secondary IOL, previously demonstrated in human cadaver eyes.¹⁴

After implantation of this new secondary IOL in the sulcus, the mean UCVA improved from about 20/30 preoperatively to about 20/20 postoperatively. There was no statistically or clinically significant change in BCVA preoperatively to postoperatively; BCVA was slightly better than 20/20. The final postoperative UCVA and BCVA appeared slightly better than have been reported in earlier studies looking at other secondary IOLs or LASIK. In those studies, the final UCVA was about 20/25 and the BCVA was not better than 20/20. These earlier studies did include patients with lower preoperative VA.^{4,5,9,12} A study by Venter et al¹¹ had similar UCVA and BCVA results to the ones shown in the current study. That study included 12-month follow-up,

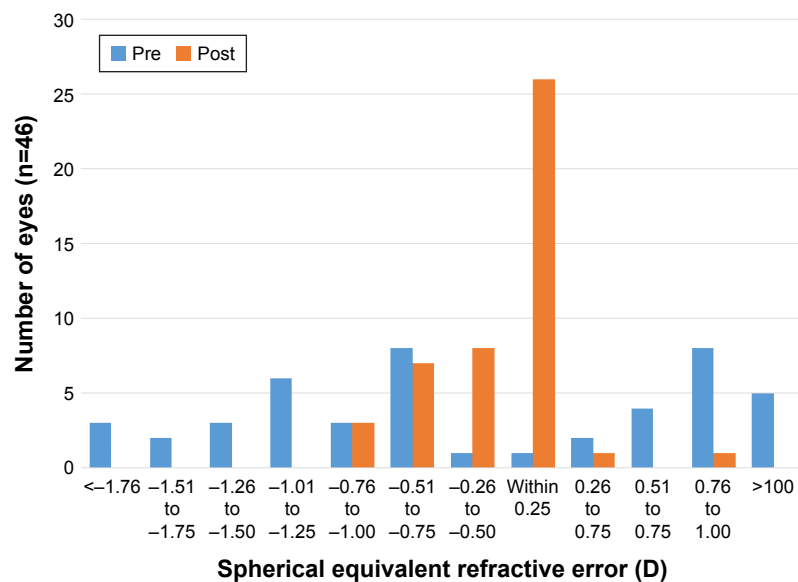


Figure 3 Spherical equivalent refraction before and after secondary IOL implantation.
Abbreviation: IOL, intraocular lens.

whereas the current study was limited to results available 1 week to 3 months postoperatively.

The spherical equivalent refraction was reduced from a mean of 1.02D–0.36D, with 57% and 76% of the eyes within 0.25D and 0.50D of the intended target, respectively. The percent of eyes within 0.50D is somewhat lower than that for other surgical solutions in other studies,^{4,5,7,11,12} likely a function of the high percentage of eyes in the current study with a residual spherical equivalent refractive error of –0.625D. All of the previous studies^{3–5,7,11,12} reported spherical equivalent refractions after at least 3 months postoperatively, which may also have been a factor. With a mean postoperative spherical equivalent refraction of –0.25D, an adjustment in the secondary IOL lens formula used to plan the final outcome might be warranted. However, it is worth noting that while the target for most eyes was emmetropia, there was a bias to using the “least minus” refraction; in other words, given a +0.15D or –0.15D calculated residual refraction for two IOL powers, the power yielding the –0.15D result would be chosen.

In the 10 cases who were implanted with a toric lens, the average astigmatism was reduced from 1.35D to 0.42D, where 6/10 eyes and 7/10 eyes had 0.25D and 0.5D or less of residual refractive astigmatism, respectively. This result is better than that reported by Kojima et al¹² where patients were implanted with a different sulcus toric lens and 5/8 eyes had 0.5D or less of residual astigmatism. The eyes in the study by Kojima et al had higher preoperative astigmatism (average of 2.63D) than in the current study.¹²

There was one case of residual refractive astigmatism that was a result of rotation of the toric IOL implanted. Concern

for zonular integrity precluded additional manipulation of the lens. Previous studies have demonstrated the need for good zonular integrity when a secondary sulcus IOL is being implanted.¹⁴

Concerns with secondary IOL implantation include the potential for hypertonia or hypotonia, interlenticular opacification as well as the possibility of iris chafing with subsequent pigment dispersion.¹⁵ These are usually associated with a specific material and/or lens design (eg, sharp edges).¹⁶ None of these was observed with the AddOn lens. In addition, there may be concerns with the size of the eye in which a secondary lens can be implanted; too small an eye may make implantation difficult and too large an eye may lead to instability of the secondary IOL. However, in the current study there was a wide range of axial lengths where secondary lens implantation was successful.

There are limitations in the current study. As it was based on a retrospective chart review, standard follow-up times were not always available, which might add to the variability of the results. A prospective study with standard follow-up times and procedures would help to corroborate the current findings. Another limitation is that endothelial cell counts were not measured, though endothelial compromise is more of a concern with anterior chamber secondary IOLs.

Conclusion

The secondary IOL studied here, implanted in the sulcus, appears to be a viable method to correct residual refractive error after primary IOL implantation.

Acknowledgments

IstQ provided funding to Science in Vision (Potvin) to assist with data management and manuscript preparation. Sarah Y Makari, OD, a consultant to Science in Vision, received compensation for providing writing assistance to the authors in preparation of the manuscript.

Disclosure

The authors report no conflicts of interest in this work.

References

- Alfonso JF, Fernández-Vega L, Montés-Micó R, Valcárcel B. Femtosecond laser for residual refractive error correction after refractive lens exchange with multifocal intraocular lens implantation. *Am J Ophthalmol*. 2008;146(2):244–250.
- Blaylock JF, Si Z, Aitchison S, Prescott C. Visual function and change in quality of life after bilateral refractive lens exchange with the ReSTOR multifocal intraocular lens. *J Refract Surg*. 2008;24(3):265–273.
- Fernández-Buenaga R, Alió JL, Pérez Ardoy AL, Quesada AL, Pinilla-Cortés L, Barraquer RI. Resolving refractive error after cataract surgery: IOL exchange, piggyback lens, or LASIK. *J Refract Surg*. 2013;29(10):676–683.
- Jin GJ, Merkley KH, Crandall AS, Jones YJ. Laser in situ keratomileusis versus lens-based surgery for correcting residual refractive error after cataract surgery. *J Cataract Refract Surg*. 2008;34(4):562–569.
- El Awady HE, Ghanem AA. Secondary piggyback implantation versus IOL exchange for symptomatic pseudophakic residual ametropia. *Graefes Arch Clin Exp Ophthalmol*. 2013;251(7):1861–1866.
- Gerten G, Kermani O, Schmiedt K, Farvili E, Foerster A, Oberheide U. Dual intraocular lens implantation: monofocal lens in the bag and additional diffractive multifocal lens in the sulcus. *J Cataract Refract Surg*. 2009;35(12):2136–2143.
- Hassan AH, Sayed KM, ElAgooz M, Elhawary AM. Refractive results: safety and efficacy of secondary piggyback Sensar™ AR40 intraocular lens implantation to correct pseudophakic refractive error. *J Ophthalmol*. 2016;2016:4505812.
- Kahraman G, Amon M. New supplementary intraocular lens for refractive enhancement in pseudophakic patients. *J Cataract Refract Surg*. 2010;36(7):1090–1094.
- Akaishi L, Tzelikis PF. Primary piggyback implantation using the ReSTOR intraocular lens: case series. *J Cataract Refract Surg*. 2007;33(5):791–795.
- Gundersen KG, Makari S, Ostenstad S, Potvin R. Retreatments after multifocal intraocular lens implantation: an analysis. *Clin Ophthalmol*. 2016;10:365–371.
- Venter JA, Oberholster A, Schallhorn SC, Pelouskova M. Piggyback intraocular lens implantation to correct pseudophakic refractive error after segmental multifocal intraocular lens implantation. *J Refract Surg*. 2014;30(4):234–239.
- Kojima T, Horai R, Hara S, et al. Correction of residual refractive error in pseudophakic eyes with the use of a secondary piggyback toric Implantable Collamer Lens. *J Refract Surg*. 2010;26(10):766–769.
- Thomas BC, Auffarth GU, Reiter J, Holzer MP, Rabsilber TM. Implantation of three-piece silicone toric additive IOLs in challenging clinical cases with high astigmatism. *J Refract Surg*. 2013;29(3):187–193.
- Reiter N, Werner L, Guan J, et al. Assessment of a new hydrophilic acrylic supplementary IOL for sulcus fixation in pseudophakic cadaver eyes. *Eye (Lond)*. 2017;31(5):802–809.
- Moshirfar M, McCaughey MV, Santiago-Caban L. Corrective techniques and future directions for treatment of residual refractive error following cataract surgery. *Expert Rev Ophthalmol*. 2014;9(6):529–537.
- Ramalho M, Vaz FT, Pedrosa C, et al. Secondary pigmentary glaucoma associated with 1-piece foldable intraocular lens in the ciliary sulcus. *J Cataract Refract Surg*. 2015;41(12):2765–2767.

Clinical Ophthalmology

Publish your work in this journal

Clinical Ophthalmology is an international, peer-reviewed journal covering all subspecialties within ophthalmology. Key topics include: Optometry; Visual science; Pharmacology and drug therapy in eye diseases; Basic Sciences; Primary and Secondary eye care; Patient Safety and Quality of Care Improvements. This journal is indexed on

Submit your manuscript here: <http://www.dovepress.com/clinical-ophthalmology-journal>

Dovepress

PubMed Central and CAS, and is the official journal of The Society of Clinical Ophthalmology (SCO). The manuscript management system is completely online and includes a very quick and fair peer-review system, which is all easy to use. Visit <http://www.dovepress.com/testimonials.php> to read real quotes from published authors.