

Optimal management of thumb basal joint arthritis: challenges and solutions

Christopher Higgenbotham¹
Alan Boyd¹
Michelle Busch¹
Dennis Heaton²
Thomas Trumble¹

¹Hand Institute, Bellevue Bone and Joint Physicians, Bellevue, School of Medicine, ²Pacific Northwest University, Yakima, WA, USA

Abstract: Up to 15% of the population older than 30 years suffers from symptomatic thumb carpometacarpal (CMC) osteoarthritis (OA), with the incidence increasing to ~33% in postmenopausal women. The thumb CMC joint has been reported as the most painful joint when compared to other hand joints affected by OA. It is therefore no surprise that this is a common chief complaint of patients and has a significant effect on work and life satisfaction. The purpose of this article was to review currently available literature to discuss nonoperative and operative techniques utilized to treat the various stages of thumb CMC arthritis. A variety of nonoperative and operative techniques have been described in the literature, each with its own benefits and pitfalls. This review concludes that while many treatment options exist, there remains no perfect treatment, but the goal of improving quality of life and patient satisfaction remains the same.

Keywords: CMC, arthritis, operative, nonoperative, treatment, review

Introduction: anatomy and biomechanics

The carpometacarpal (CMC) joint of the thumb is a saddle-shaped joint with liberal range of motion due to its lack of bony confinement. It is reliant on ligamentous stability, with the majority of its stability reliant on the beak, also known as the oblique, palmar, or volar ligament and the dorsal radial ligaments (Figure 1).¹⁻⁶ Laxity of the ligamentous stabilizers whether due to acute injury or inherent hypermobility leads to bony incongruity and changes in cartilage contact area and force transmitted to these areas.⁴⁻⁸ The thumb CMC joint experiences up to 13 times the force transmitted at the tip of the thumb.⁹ The anatomy of the thumb CMC joint, as well as the force transmitted through it, makes it extremely susceptible to osteoarthritis (OA). Although the volar oblique ligament that stabilizes the thumb metacarpal to the index has been recognized as a key factor in stabilizing the thumb, the dorsal radial ligaments are also a key factor in thumb stability, and their reconstruction is a major point of successful surgery. Up to 15% of the population older than 30 years suffers from symptomatic thumb CMC OA, with the incidence increasing to ~33% in postmenopausal women.^{5,9} The thumb CMC joint has been reported as the most painful joint when compared to other hand joints affected by OA. It is therefore no surprise that this is a common chief complaint of patients and has a significant effect on work and life satisfaction.¹⁰ The biomechanics of the joint stress the key ligaments, including the volar oblique ligament and the dorsal CMC ligaments. Diagnosis and treatment options available for this common entity depend on the stages of basal joint arthritis CMC joint:

Correspondence: Thomas Trumble
Hand Institute, 7283 Southeast 27th
Street, Avenue 254, Mercer Island, WA
98040, USA
Tel +1 206 947 4120
Email mail@thomastrumble.net

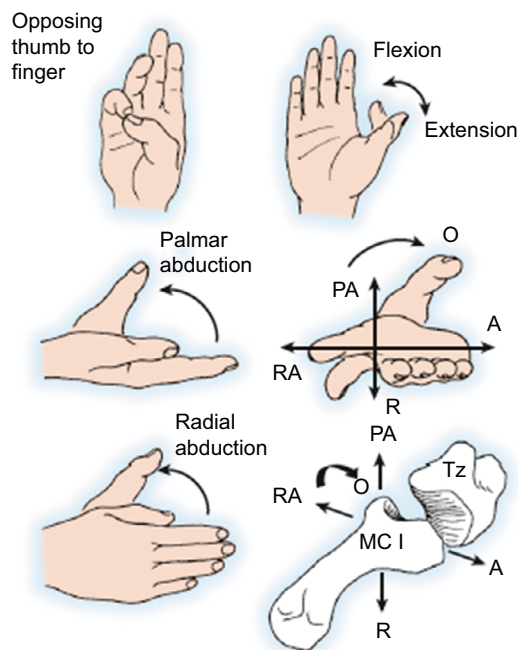


Figure 1 The saddle-shaped CMC joint allows for thumb rotation in multiple planes. **Abbreviations:** CMC, carpometacarpal; O, opposition; A, abduction; Tz, trapezium; R, retropulsion.

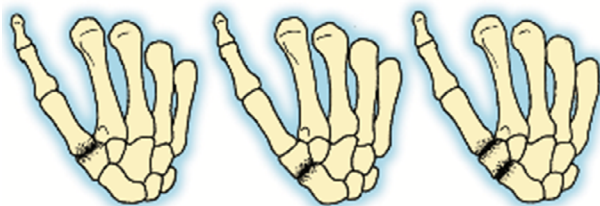

Figure 2 Basal joint arthritis can progress from isolated arthritis of the CMC joint (far left) to involve all the other joints of the trapezium (far right). **Abbreviation:** CMC, carpometacarpal.

- A: subluxation but only mild CMC joint space narrowing;
- B: isolated CMC arthritis (Figure 2);
- C: pantrapezial arthritis;
- D: pantrapezial arthritis + compensatory swan neck deformity of the thumb with hyperextension of the metacarpophalangeal (MCP) joint due to the dorsal subluxation of the CMC joint (Figure 3); and
- E: scaphoid–trapezium–trapezoid joint – just the scaphoid–trapezium joint involved or the scaphoid–trapezoid joint as well as CMC arthritis (Figure 2).

Presentation: symptoms and clinical examination and diagnostic studies

Patients often present with complaints of pain localized to the base of the thumb that is exacerbated when performing tasks such as opening a jar, turning a car key, and turning a door knob.^{4–6,10–12} This pain may be reproduced by resisted pinch and grip. On physical examination, patients will have

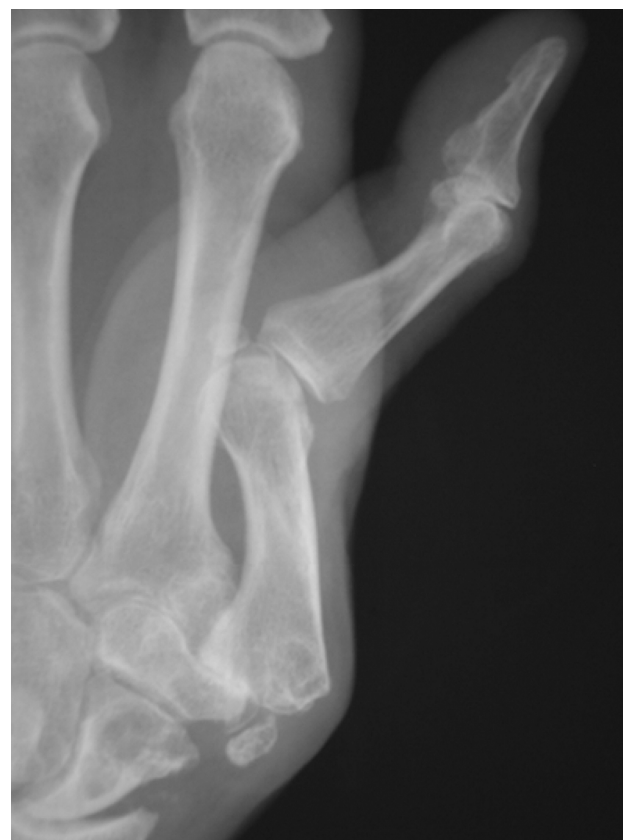

Figure 3 Chronic hyperextension of the thumb MCP joint occurs as a response to CMC joint subluxation and should be corrected when the thumb CMC joint is reconstructed. **Abbreviations:** MCP, metacarpophalangeal; CMC, carpometacarpal.

point tenderness at the thumb basal joint with swelling and crepitus when the basal joint is compressed – a positive grind test and a positive “hump” sign from dorsal CMC dislocation subluxation (Figures 2 and 3).^{5,8} It is important to rule out other disease processes that may cause pain in the same region, such as de Quervain’s tenosynovitis and conditions that often coexist with basal joint arthritis, i.e., carpal tunnel syndrome or trigger thumb.⁵

Plain X-rays are still the best study to evaluate and stage the arthritis. There are several historic staging systems, such as the Burton and Eaton staging systems, for thumb basal joint arthritis, but they are not reliable, and we prefer to rely on the practical and functional staging system presented earlier.^{2,4–8,10,13} However, Eaton staging is used only when describing radiologic findings throughout this review.

Nonoperative treatment

Conservative management of thumb CMC OA is continuing to evolve, as demonstrated by the unique studies presented by Bohr et al¹⁴ and Loibl et al.¹⁵

Bracing, activity modification, and the use of assistive devices such as key assist and jar openers improve the patients’

quality of life and their ability to perform activities of daily living. Steroid injections can be very helpful to reduce inflammation and symptoms in mildly symptomatic patients.¹⁶

Surgical treatment

The key principle is that each of the separate joints within the thumb basal joint with arthritis needs to be addressed along with the deforming forces of CMC joint subluxation and compensatory MCP swan neck deformity. Rigid implants can fail for a variety of reasons, such as bony erosion resulting in implant loosening or implant fracture (Figure 4).¹⁷

Although there are no randomized clinical studies to compare the results of simple trapeziectomy to trapeziectomy with ligament reconstruction with or without an interposition joint replacement,¹⁸ biomechanical studies confirm that the reconstruction of the basal joint has greater stability if the ligaments are reconstructed and the joint is replaced with some form of spacer (Figure 5A and B).¹⁹ While a small, medium length follow-up study by Belcher and Nicholl²⁰ determined no significant difference in patient satisfaction between ligament reconstruction and no ligament reconstruction, there have been no large randomized studies with long-term follow-up to determine whether patient satisfaction or functional outcome diminishes with longer follow-up. Furthermore, clinical studies demonstrate that interposition joint replacement arthroplasty results in less proximal migration of the thumb metacarpal.^{21,22}

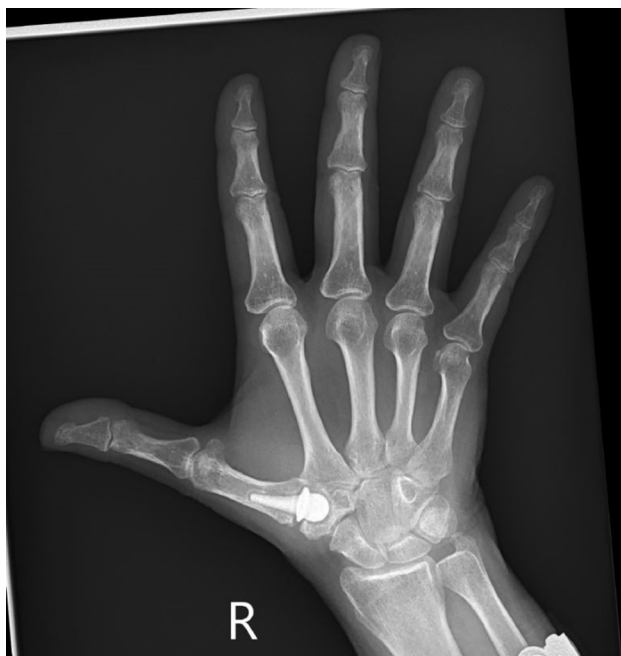

Figure 4 A rigid pyrocarbon implant spanning the basal first CMC joint gradually migrates proximally into the trapezium.
Abbreviation: CMC, carpometacarpal.

The surgeon needs to match the patient's age, clinical demands, and stage of disease with the best treatment option.^{1-4,6,7,10,21-23} Surgery should only be considered when the patient has exhausted all reasonable nonoperative interventions but continues to have pain and loss of function.

Early stage patients with isolated CMC joint disease and subluxation

Symptomatic early stage CMC osteo-arthritis is treated based on patient characteristics, such as activity level, and tailored to allow patients to return to their pretreatment lifestyle, or as near to their pretreatment life-style as possible.

1. For active patients with CMC joint subluxation and pain, ligament reconstruction can be very effective using either the flexor carpi radialis (FCR) as a tenodesis or the Tight-Rope implant (Arthrex, Inc., Naples, FL, USA; Figure 6A).^{6,12} Arthroscopy may be utilized in early stage thumb CMC OA not only to help improve symptoms and function but also to more accurately stage the extent of disease.^{3,5,22}
2. For active patients with a severe adduction contracture, a closing wedge extension osteotomy provides excellent correction of deformity and pain relief with increased pinch strength and does not burn any bridges for later arthroplasty (Figure 6B). In vitro analysis of this procedure by Koff et al³ using 15° osteotomy versus the more commonly used 30° osteotomy provided significant stability in all planes of motion and successfully changed the centroid of joint contact more dorsally without changing joint surface area contact.
3. Trapezio-metacarpal arthrodesis involves fusion of the CMC joint and is indicated in patients younger than 50 years who require a solid osseous fixation to accommodate high-impact activity, such as construction and other manual labor, especially if the arthritis was due to an injury, such as an old Rolando's fracture (Figure 6C).³ The main concern with the utilization of an arthrodesis is nonunion, and the tension band and Kirschner wire fixation provide a stable construct for the arthrodesis (Figure 6D).^{1,5,23} In addition, by fusing the thumb CMC joint, there is an inherent loss of range of motion that may lead to decreased patient satisfaction for long term, and subsequent scapo-trapezio-trapezoidal arthritis can be difficult to manage.

Late-stage but isolated CMC arthritis

As thumb CMC OA progresses into the later Eaton radiographic stages and as patients become more symptomatic

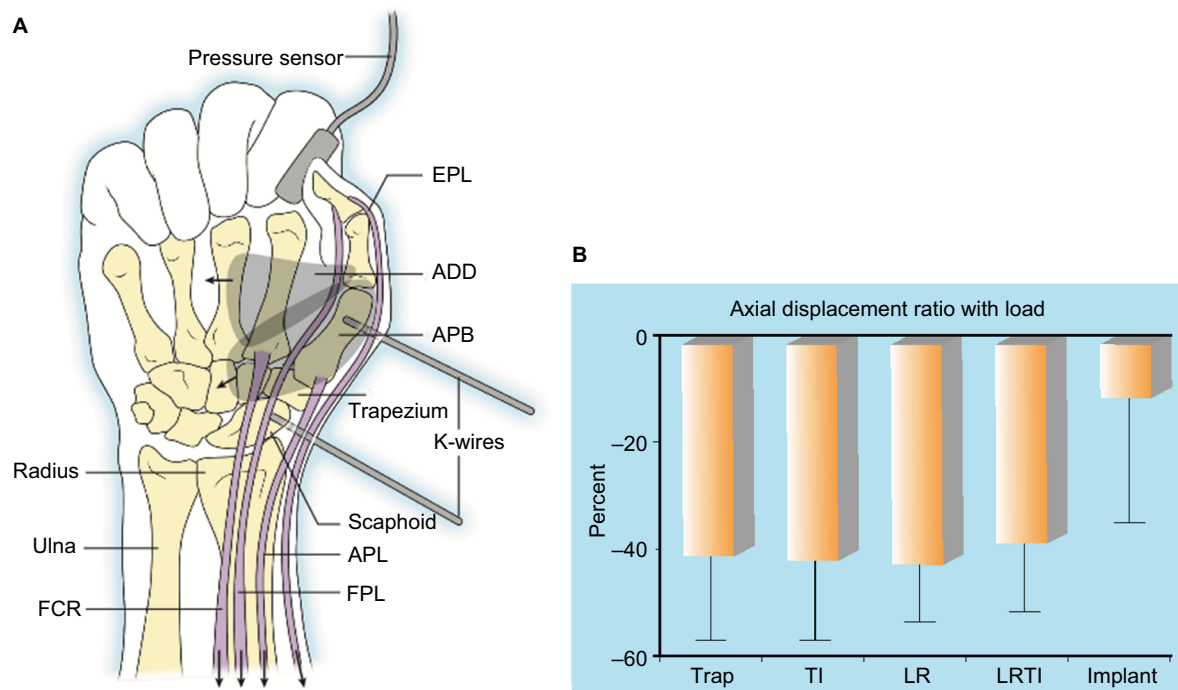


Figure 5 (A) In a cadaveric study to evaluate the effectiveness of joint replacement with and without ligament reconstruction, the thumb pinch was simulated by loading the tendons about the thumb. Reproduced from Luria S, Waitayawinyu T, Nemechek N, Huber P, Tencer AF, Trumble TE. Biomechanic analysis of trapeziectomy, ligament reconstruction with tendon interposition, and tie-in trapezium implant arthroplasty for thumb carpometacarpal arthritis: a cadaver study. *J Hand Surg.* 2007;32(5):697–706.¹⁹

(B) There was no increased stability from LRTI versus simple trapeziectomy, whereas joint replacement biomechanically improved joint stability ($p < 0.01$). Reproduced from Luria S, Waitayawinyu T, Nemechek N, Huber P, Tencer AF, Trumble TE. Biomechanic analysis of trapeziectomy, ligament reconstruction with tendon interposition, and tie-in trapezium implant arthroplasty for thumb carpometacarpal arthritis: a cadaver study. *J Hand Surg.* 2007;32(5):697–706.¹⁹

Abbreviations: LRTI, ligament reconstruction and tendon interposition; FCR, flexor carpi radialis; APL, abductor pollicis longus; K-wire, Kirschner wire; TI, tendon interposition; LR, ligament reconstruction; Trap, trapeziectomy; FPL, flexor pollicis longus; APB, abductor pollicis brevis muscle; ADD, adductor pollicis muscle; EPL, extensor pollicis longus.

with less relief from conservative treatment, the goals of surgery change when compared to techniques performed in the earlier stages of the disease. The goal in the later stages is removal of the arthritic joint. There is debate as to what procedures provide the best outcomes, and to date, there is very little evidence to support one technique over the other.

Hemitrapeziectomy can be performed when there is no evidence of pantrapezial, Eaton Stage IV OA. This can be performed arthroscopically, as mentioned earlier, or through an open procedure.^{3,5,13,27} Using allograft cartilage with an FCR tenodesis, good long-term results have been obtained in cases of isolated CMC arthritis (Figure 6E).^{21,22}

In a series of 77 thumbs with allograft cartilage interposition arthroplasty and ligament reconstruction with the FCR tendon in patients who were followed for an average of 58 months, the costochondral allograft maintained trapezial to metacarpal height ratio with only a 22% loss in height at the final radiographic follow-up.^{21,22} Range of motion, pinch strength, and grip strength were all well maintained. Park et al²⁴ demonstrated similar long-term outcomes with the same procedure.

Late-stage pantrapezial arthritis

Late stage CMC osteoarthritis can be challenging to treat due to the inherent instability of the deteriorated joint, but the treatment options available seek to decrease pain, improve function, and provide stability.

1. **Trapeziectomy:** it involves excision of the entire trapezium.^{1,3,21} Early treatment of symptomatic thumb CMC OA was to remove the trapezium and allowing the metacarpal to essentially float into the void created. Long-term results of simple trapeziectomy demonstrate excellent pain relief and maintenance of metacarpal range of motion but with significant proximal migration of the thumb CMC joint.^{3,34,35} This loss in height decreases the lever force of the metacarpal, resulting in a significant decrease in postoperative pinch strength.³⁴ Temporary pins and the use of a hematoma have been used to prevent the proximal metacarpal migration, but there are no comparison studies to document the effectiveness, and the pins can be extremely irritating and increase the risk of reflex sympathetic dystrophy (RSD).⁹ While pinch and

grip strength improve postoperatively, the metacarpal eventually subsides into the void, resulting in shortening of the metacarpal and some loss of the pinch and grip strength initially attained.²⁴

2. Ligament reconstruction and tendon interposition (LRTI) arthroplasty: trapeziectomy with LRTI arthroplasty involves drilling holes in the first metacarpal and weaving a segment of the FCR tendon through the metacarpal and then creating a tendinous ball utilizing the remaining segment of the tendon to create the interposition segment (Figure 6F).^{4,5,24-28} Park et al²⁴ published their experience with three different techniques for surgical treatment of thumb CMC OA. Park et al demonstrated that LRTI arthroplasty utilizing a segment of the FCR tendon autograft had longer operative times on average and lower preservation of strength at the final follow-up when compared to hematoma distraction arthroplasty and costochondral allograft

interposition arthroplasty with ligament reconstruction (Figure 6G).²⁴ Owing to reports of complications such as complex regional pain syndrome following the traditional trapeziectomy with LRTI arthroplasty, several alternative techniques have been described to provide similar stability and metacarpal height maintained by this procedure.^{5,20,29-35}

3. Trapeziectomy with joint replacement and ligament reconstruction: the use of an implant helps to prevent proximal subsidence of the metacarpal, especially when combined with ligament reconstruction using the TightRope implant to reconstruct the volar oblique ligament connecting the thumb to the index metacarpal (Figure 6H).^{18,21,22} The thumb implant is stabilized using a palmaris or a slip abductor pollicis longus tendon (Figure 6I, J, and K), as seen in this case of the collapsed LRTI case (Figure 6G) where the implant and ligament reconstruction regain the metacarpal height. Long-term

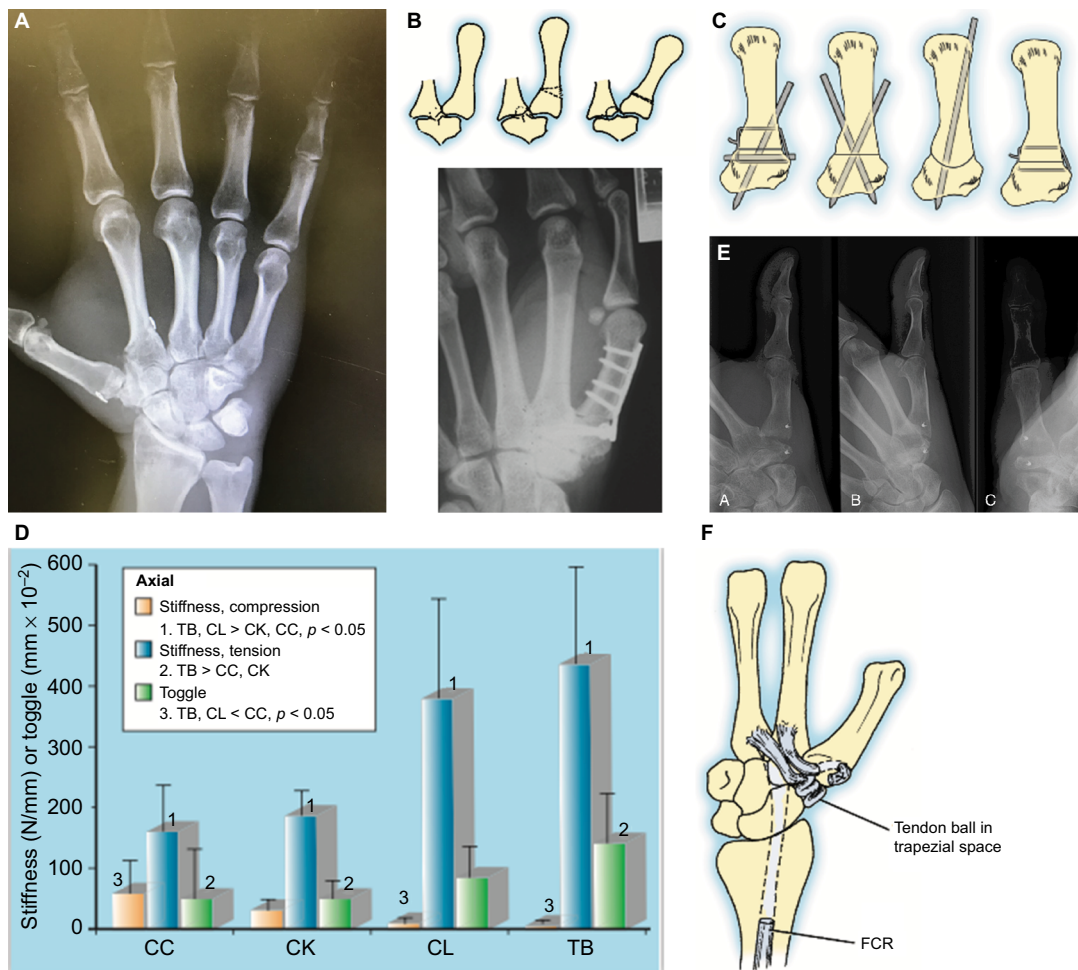


Figure 6 (Continued)

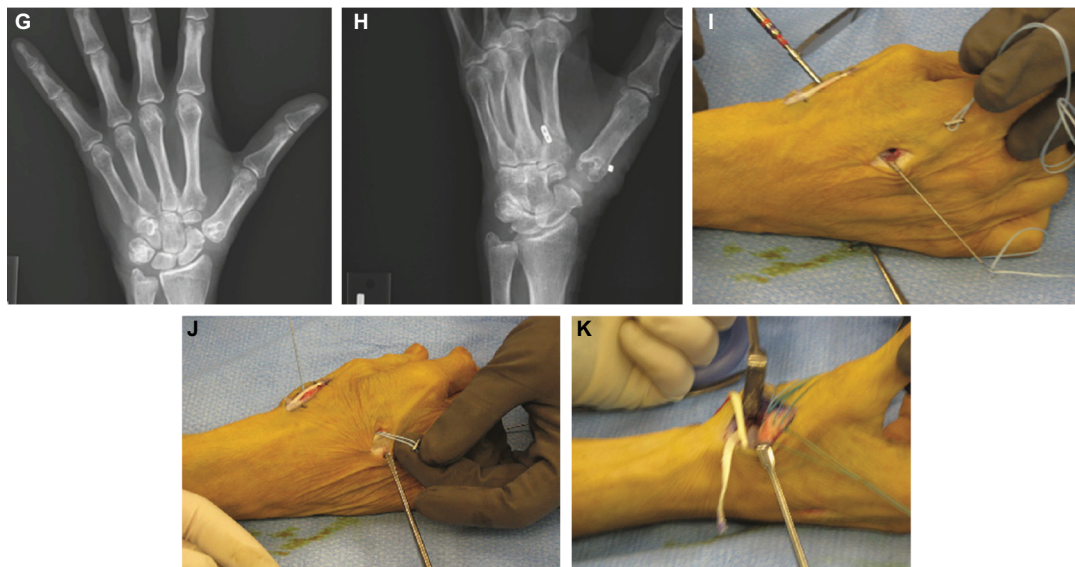


Figure 6 (A) This patient with early stage CMC joint arthritis and CMC subluxation is stabilized with a TightRope anchor (Arthrex, Inc., Naples, FL, USA) to reconstruct the unstable volar oblique ligament providing pain relief and increased pinch strength. (B) Diagram and radiograph showing the first metacarpal extension osteotomy. Reproduced with permission of the Licensor through PLSclear, from Wilson JN, Bossley CJ. Osteotomy in the treatment of osteoarthritis of the first carpometacarpal joint. *J Bone Joint Surg Br.* 1983;65(2):179–181; © 1983.³⁶ (C) The stability for fixation for a thumb CMC joint arthrodesis was evaluated biomechanically and the tension band and K-wires provided the most stable construct. Reproduced from Stokel EA, Tencer AF, Helen L. A biomechanical comparison of four methods of fixation of the trapeziometacarpal joint. *J Hand Surg.* 1994;19(1):86–92.²³ (D) Tension band fixation provided the greatest biomechanical stability for the arthrodesis. Reproduced from Stokel EA, Tencer AF, Helen L. A biomechanical comparison of four methods of fixation of the trapeziometacarpal joint. *J Hand Surg.* 1994;19(1):86–92.²³ (E) The AP, oblique and lateral position X-ray views show a CMC hemiarthroplasty with a costochondral allograft (to preserve the trapezium height) stabilized by an FCR tendon graft. Reproduced from Trumble T, Rafiqah G, Heaton D. Thumb carpometacarpal arthroplasty with ligament reconstruction and interposition costochondral arthroplasty. *J Wrist Surg.* 2013;2(3):220–227.²¹ (F) The FCR is released and then woven through the thumb metacarpal to stabilize the CMC joint. LRTI arthroplasty combines a suspension of the first metacarpal with an interposition in place of the trapezium. (G) This AP radiograph shows severe proximal migration of the thumb metacarpal after an LRTI. (H) After TightRope anchor and TIE-IN (Wright Medical, Memphis, TN, USA) implant placement, the deformity of the thumb is corrected. (I) A major breakthrough in basal joint arthroplasty for the thumb has been the use of the TightRope anchor to reconstruct the volar oblique ligament. An Arthrex suture passing wire can be drilled from the thumb metacarpal to the index metacarpal, or in this case, a 0.045-inch K-wire is drilled and then a cannulated 2.0 drill is used to create a pathway for the suture passing wire. (J) The FiberWire (Arthrex, Inc.) suture is passed through the two metacarpals. There is one button on the anchor, and the second button is added before tying the sutures to reconstruct the volar oblique ligament. (K) A tendon graft is obtained from the palmaris longus or the APL and passed around the FCR and then around the TIE-IN implant before suturing it onto itself to secure the implant and stabilize the thumb.

Abbreviations: CMC, carpometacarpal; K-wire, Kirschner wire; FCR, flexor carpi radialis; LRTI, ligament reconstruction and tendon interposition; CC, cup and cone; CK, crossed K-wires; CL, cerclage wires; TB, tension band; AP, anteroposterior.

outcome studies of silicone and titanium implants have demonstrated 84% good-to-excellent results without any correlation between the radiographic findings of bony erosion and subjective complaints.^{17,30}

Conclusion

The treatment of thumb basal joint arthritis has yet to be perfected. The goal is to provide pain relief while still preserving range of motion and strength. The key to treatment is maintaining the fulcrum action of the trapezium and the combined trapezium–metacarpal length, reducing the subluxation of the thumb metacarpal and correcting any swan neck deformity of the MCP joint by volar plate advancement versus MCP arthrodesis. The treatment for thumb CMC OA will continue to evolve, as we search for the ideal thumb arthroplasty.

Disclosure

The authors report no conflicts of interest in this work.

References

1. Chou FH, Irrgang JJ, Goitz RJ. Long-term follow-up of first metacarpal extension osteotomy for early CMC arthritis. *Hand (N Y).* 2014;9(4):478–483.
2. Gillis J, Calder K, Williams J. Review of thumb carpometacarpal arthritis classification, treatment and outcomes. *Can J Plast Surg.* 2011;19(4):134–138.
3. Koff MF, Shrivastava N, Gardner TR, Rosenwasser MP, Mow VC, Strauch RJ. An in vitro analysis of ligament reconstruction or extension osteotomy on trapeziometacarpal joint stability and contact area. *J Hand Surg Am.* 2006;31(3):429–439.
4. Matullo KS, Ilyas A, Thoder JJ. CMC arthroplasty of the thumb: a review. *Hand (N Y).* 2007;2(4):232–239.
5. Van Heest AE, Kallemeier P. Thumb carpal metacarpal arthritis. *J Am Acad Orthop Surg.* 2008;16(3):140–151.
6. Yao J, Park MJ. Early treatment of degenerative arthritis of the thumb carpometacarpal joint. *Hand Clin.* 2008;24(3):251–61, v–vi.
7. Gander B, Wollstein R. Surgical treatment for thumb CMC joint arthritis. *Curr Rheumatol Rev.* 2013;9(2):113–118.
8. Melville DM, Taljanovic MS, Scalapone LR, et al. Imaging and management of thumb carpometacarpal joint osteoarthritis. *Skeletal Radiol.* 2015;44(2):165–177.
9. Berger AJ, Meals RA. Management of osteoarthrosis of the thumb joints. *J Hand Surg Am.* 2015;40(4):843–850.

10. O'Brien VH, Giveans MR. Effects of a dynamic stability approach in conservative intervention of the carpometacarpal joint of the thumb: a retrospective study. *J Hand Ther.* 2013;26(1):44–51. quiz 2.
11. Bertozzi L, Valdes K, Vanti C, Negrini S, Pillastrini P, Villafane JH. Investigation of the effect of conservative interventions in thumb carpometacarpal osteoarthritis: systematic review and meta-analysis. *Disabil Rehabil.* 2015;37(22):2025–2043.
12. Yao J. Suture-button suspensionplasty for the treatment of thumb carpometacarpal joint arthritis. *Hand Clin.* 2012;28(4):579–585.
13. Berger AJ, Momeni A, Ladd AL. Intra- and interobserver reliability of the Eaton classification for trapeziometacarpal arthritis: a systematic review. *Clin Orthop Relat Res.* 2014;472(4):1155–1159.
14. Bohr S, Rennekampff HO, Pallua N. Cell-enriched lipospirate arthroplasty: a novel approach to first carpometacarpal joint arthritis. *Hand Surg.* 2015;20(3):479–481.
15. Loibl M, Lang S, Dendl LM, et al. Leukocyte-reduced platelet-rich plasma treatment of basal thumb arthritis: a pilot study. *Biomed Res Int.* 2016;2016:9262909.
16. Day CS, Gelberman R, Patel AA, Vogt MT, Ditsios K, Boyer MI. Basal joint osteoarthritis of the thumb: a prospective trial of steroid injection and splinting. *J Hand Surg Am.* 2004;29(2):247–251.
17. Krukhaug Y, Lie SA, Havelin LI, Furnes O, Hove LM, Hallan G. The results of 479 thumb carpometacarpal joint replacements reported in the Norwegian arthroplasty register. *J Hand Surg Eur Vol.* 2014;39(8):819–825.
18. Shuler MS, Luria S, Trumble TE. Basal joint arthritis of the thumb. *J Am Acad Orthop Surg.* 2008;16(7):418–423.
19. Luria S, Waitayawinyu T, Nemechek N, Huber P, Tencer AF, Trumble TE. Biomechanic analysis of trapeziectomy, ligament reconstruction with tendon interposition, and tie-in trapezium implant arthroplasty for thumb carpometacarpal arthritis: a cadaver study. *J Hand Surg Am.* 2007;32(5):697–706.
20. Belcher HJ, Nicholl JE. A comparison of trapeziectomy with and without ligament reconstruction and tendon interposition. *J Hand Surg Br.* 2000;25(4):350–356.
21. Trumble T, Rafiqah G, Heaton D. Thumb carpometacarpal arthroplasty with ligament reconstruction and interposition costochondral arthroplasty. *J Wrist Surg.* 2013;2(3):220–227.
22. Trumble TE, Rafiqah G, Gilbert M, Allan CH, North E, McCallister WV. Thumb trapeziometacarpal joint arthritis: partial trapeziectomy with ligament reconstruction and interposition costochondral allograft. *J Hand Surg Am.* 2000;25(1):61–76.
23. Stokel EA, Tencer AF, Driscoll HL, Trumble TE. A biomechanical comparison of four methods of fixation of the trapeziometacarpal joint. *J Hand Surg Am.* 1994;19(1):86–92.
24. Park MJ, Lichtman G, Christian JB, et al. Surgical treatment of thumb carpometacarpal joint arthritis: a single institution experience from 1995-2005. *Hand (NY).* 2008;3(4):304–310.
25. Bodin ND, Spangler R, Thoder JJ. Interposition arthroplasty options for carpometacarpal arthritis of the thumb. *Hand Clin.* 2010;26(3):339–50, v–vi.
26. Naram A, Lyons K, Rothkopf DM, et al. Increased complications in trapeziectomy with ligament reconstruction and tendon interposition compared with trapeziectomy alone. *Hand (NY).* 2016;11(1):78–82.
27. Vermeulen GM, Slijper H, Feitz R, Hovius SE, Moojen TM, Selles RW. Surgical management of primary thumb carpometacarpal osteoarthritis: a systematic review. *J Hand Surg Am.* 2011;36(1):157–169.
28. Wollstein R, Watson HK, Martin RT, Taieb A, Pankonin D, Carlson L. Long-term durability of tendon arthroplasty with excision of the trapezium in stage I osteoarthritis of the thumb CMC joint. *Ann Plast Surg.* 2009;62(4):358–360.
29. Aita MA, Alves RS, Longuino LF, Ferreira CH, Ikeuti DH, Rodrigues LM. Measurement of quality of life among patient undergoing arthroplasty of the thumb to treat CMC arthritis. *Rev Bras Ortop.* 2016;51(4):431–436.
30. Endress RD, Kakar S. Double tightrope for basilar thumb arthritis. *J Hand Surg Am.* 2014;39(12):2512–2516.
31. Kodama N, Takemura Y, Imai S, Matsusue Y. New option for surgical treatment of the trapeziometacarpal osteoarthritis: a case report. *Case Reports Plast Surg Hand Surg.* 2015;2(3–4):47–49.
32. Lee HJ, Kim PT, Deslivia MF, Jeon IH, Lee SJ, Nam SJ. Results of abductor pollicis longus suspension ligamentoplasty for treatment of advanced first carpometacarpal arthritis. *Clin Orthop Surg.* 2015;7(3):372–376.
33. Putnam MD, Meyer NJ, Baker D, Brehmer J, Carlson BD. Trapezium excision and suture suspensionplasty (TESS) for the treatment of thumb carpometacarpal arthritis. *Tech Hand Up Extrem Surg.* 2014;18(2):102–108.
34. Richard MJ, Lunich JA, Correll GR. The use of the Artelon CMC Spacer for osteoarthritis of the basal joint of the thumb. *J Hand Ther.* 2014;27(2):122–125. quiz 6.
35. Seetharaman M, Vitale MA, Desai K, Crowe JF. Extensor pollicis longus rupture after mini TightRope suspensionplasty. *J Wrist Surg.* 2016;5(2):143–146.
36. Wilson JN, Bossley CJ. Osteotomy in the treatment of osteoarthritis of the first carpometacarpal joint. *J Bone Joint Surg Br.* 1983;65(2):179–181.

Orthopedic Research and Reviews

Publish your work in this journal

Orthopedic Research and Reviews is an international, peer-reviewed, open access journal that focusing on the patho-physiology of the musculoskeletal system, trauma, surgery and other corrective interventions to restore mobility and function. Advances in new technologies, materials, techniques and pharmacological agents are particularly

Submit your manuscript here: <https://www.dovepress.com/orthopedic-research-and-reviews-journal>

welcome. The manuscript management system is completely online and includes a very quick and fair peer-review system, which is all easy to use. Visit <http://www.dovepress.com/testimonials.php> to read real quotes from published authors.

Dovepress