

# Dellen formation as a complication of subconjunctival silicone oil following microincision vitrectomy

Mohamed M Mahgoub<sup>1,2</sup>

Maged M Roshdy<sup>1,2</sup>

Sherine S Wahba<sup>1,2</sup>

<sup>1</sup>Ophthalmology Department, Ain Shams University, <sup>2</sup>Ophthalmology Department, Al Watany Eye Hospital, Cairo, Egypt

**Purpose:** To study the subconjunctival silicone oil (SCSO) parameters associated with dellen formation following microincision vitrectomy (MIV).

**Patients and methods:** This was a case-control study of 20 eyes with SCSO following MIV. Ten of them suffered postoperative dellen formation. Dellen occurrence, their sizes, number of loci, and distance between SCSO and the limbus were recorded. The outcome after silicone-oil removal was evaluated.

**Results:** The SCSO was at  $3.1 \pm 1.2$  mm from the limbus. All cases with dellen had SCSO within 2 mm of the limbus ( $P < 0.001$ ). No other factors were found to be associated with dellen formation (age,  $P = 0.414$ ; sex,  $P = 0.656$ ; laterality,  $P = 1$ ; indication for pars plana vitrectomy,  $P = 0.655$ ; instrument gauge,  $P = 0.211$ ; circumference involved by SCSO,  $P = 0.252$ ). All the dellen healed after surgical evacuation of SCSO ( $P < 0.001$ ), leaving scars.

**Conclusion:** Dellen can be associated with MIV secondary to SCSO near the limbus. Resolution with scarring occurred following SCSO evacuation. Therefore, SCSO should be evacuated as early as possible to avoid long-term peripheral corneal morbidity.

**Keywords:** silicone oil-removal, subconjunctival silicone oil, dellen, vitrectomy

## Introduction

Dellen were first described by Ernst Fuchs in 1911 as saucer-like excavations at the corneal margin<sup>1</sup> with intact epithelia and no infiltration. They occur next to elevated tissue and are caused by localized dryness. Studies have reported dellen formation in the corneal periphery due to a limbic elevation of various causes, such as filtering bleb<sup>2</sup> and after rectus muscle surgery, especially with the limbic approach.<sup>1,3</sup> However, they have been reported following other relatively distant conditions, including elevation of the conjunctiva after scleral buckle, and resolved when the conjunctival swelling abated.<sup>4</sup>

Dellen have also been reported after silicone oil (SO) escape from the vitreous cavity in an aphakic eye to the subconjunctival space through a Molteno implant.<sup>5</sup> SO leak from the vitreous cavity to the subconjunctival space has been reported in 2.7% of cases after SO injection through pars plana sclerotomies.<sup>6</sup> Leakage of subconjunctival SO (SCSO) has been reported in 9.7% of cases treated with 23-gauge vitrectomy and SO injection, which necessitated second surgery to remove SO from the SC space.<sup>7</sup> Despite its merits, microincision vitrectomy (MIV), carries a greater risk of SCSO,<sup>8</sup> causing conjunctival elevation near the limbus and subsequently leading to corneal dellen formation. The aim of the current study was to report and analyze the factors

Correspondence: Maged M Roshdy  
211 Elhegag Street, Elhegag Square,  
Heliopolis, Cairo 11361, Egypt  
Tel +20 12 2281 1230  
Fax +20 2624 7575  
Email dr\_maged\_roshdy@med.asu.edu.eg

related to SCSO associated with peripheral corneal dellen formation following MIV and to study their fate.

## Patients and methods

This was a case–control study comprising 20 eyes of 20 patients suffering SCSO from 759 sutureless MIV cases done between August 2014 and July 2015. All surgeries were done by the same surgeon at Al Watany Eye Hospital, Cairo, Egypt. The inclusion criterion was any patient suffering SCSO after MIV by the specified surgeon in the 1-year time interval chosen. Exclusion criteria were any preexisting ocular surface disorders or failure to complete the follow-up visits. The 20 eyes were divided into two subgroups: group A (cases) comprised eyes that suffered postoperative dellen ( $n=10$ ), and group B (control) comprised ten eyes that did not experience any dellen formation. The study adhered to the tenets of the Declaration of Helsinki and was approved by the local ethical committee (Watany Research and Development Center; EC/IRB, registration RHDCRC12161216001A), as it involved no interference that deviated from the standard of care in such cases. Patients signed a consent allowing the use of their anonymous medical data and photos for scientific and research purposes. Preoperative evaluation comprised full medical and ophthalmic history, and clinical examination of the anterior and posterior segments. Indicated investigations according to case comprised B-scan ultrasonography, optical coherence tomography, and fundus fluorescein angiography.

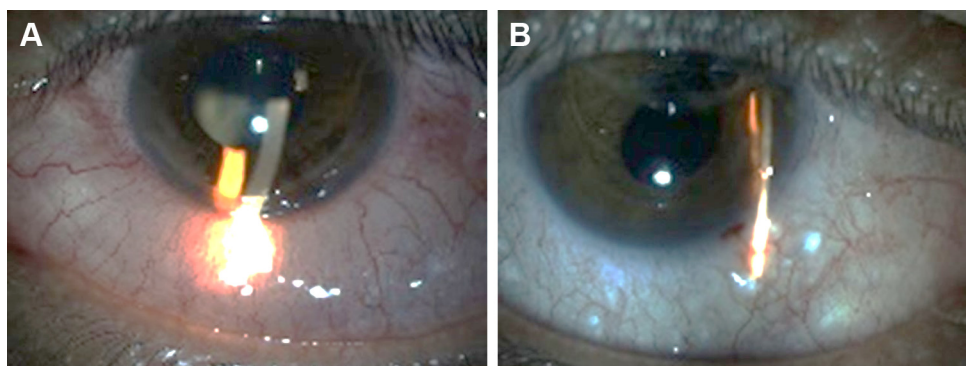
Three-port pars plana vitrectomies using 23 and 25 G systems of the Constellation machine (Alcon, Hünenberg, Switzerland) were performed under local anesthesia. Trocars were inserted at a 30° angle parallel to the scleral fibers using a one-step introduction technique. SO was injected for several indications in the study eyes, including rhegmatogenous retinal detachment with proliferative vitreoretinopathy and proliferative diabetic retinopathy with tractional retinal

detachment. No sclerotomies were sutured, and no SO escape was noted at the end of surgery. Postoperative treatment was moxifloxacin 0.3% eyedrops for 2 weeks and prednisolone acetate 1% eyedrops four times daily, tapered over 4 weeks. Follow-up visits after 2 days, 2 weeks, 1 month, and 3 months comprised full ophthalmic history and clinical examination of the anterior and posterior segments.

Dellen were diagnosed as relative thinning in the corneal periphery, suspected by abnormal reflection and confirmed by detection of different thickness with a thin slit-lamp beam (Figure 1A). Dellen had no corneal staining by fluorescein paper. Patients who developed dellen were prescribed lubricants in the form of drops and gels, and frequency of topical steroids drops was reduced. No patching was done. They were followed up more frequently and scheduled for early SCSO removal when no improvement in corneal dellen was observed.

All patients underwent SO removal from the vitreous cavity with or without phacoemulsification within 2.5–6 months postoperatively. SCSO was also removed intraoperatively at the time of SO removal from the vitreous cavity by puncturing the conjunctiva and squeezing it out or by SC dissection of SO granuloma if found. Ocular surface lubricants were continued, with postoperative treatment following SO removal.

The variables recorded were indication of SO injection, vitrectomy gauge used, clinical occurrence of dellen, SCSO size, number of SCSO loci, their proximity to the limbus, time of SO removal, and the outcome. Data were collected and statistical analysis performed using MedCalc Statistics 12.5.0.0 (MedCalc Software, Ostend, Belgium). The significance level was  $P<0.05$ . Means and standard deviation were calculated and unpaired  $t$ -tests and Pearson's  $\chi^2$  tests performed for the corresponding indications. The  $\chi^2$  test requires that the expected frequency of cases in every cell in



**Figure 1** (A) Extensive lower dellen adjacent to extensive subconjunctival silicone oil; (B) healing of dellen after silicone-oil removal with residual faint opacity.

the 2×2 table is at least five. In cases of infrequent parameters (such as complications), the alternative Fisher's exact test was used.

## Results

Mean age was 54.7±12.7 (23–73) years. There were ten (50%) male patients, and eleven (55%) right eyes. MIV was done due to diabetic tractional retinal detachment in ten eyes (50%) and rhegmatogenous retinal detachment in the others. The vitrectomy-machine gauge used was 23 G in 17 eyes (85%) and 25 G in the remaining.

Dellen occurred in ten eyes with SCSO, all in the 23 G group. No cases of corneal dellen were recorded in cases of SCSO associated with 25 G vitrectomy-system surgery. The occurrence of dellen was distributed among the different categories shown in Table 1. The closest margin of SCSO bubbles was 3.1±1.2 mm from the limbus. All dellen-formation cases occurred when the distance from the limbus was less than 2 mm. SCSO distribution, locations, and relation to dellen formation are shown in Table 2.

All dellen were resistant to medical treatment, but healed with scar formation (Figure 1B) following surgical evacuation of SCSO at the time of SO removal from the vitreous cavity ( $P<0.001$ ). Therefore, removal was done within 2.5–6 months following the original surgery, at the surgeon's discretion (Table 3). There was no correlation between the timing of SO removal and the resolution of dellen ( $P=0.22$  by Pearson's  $\chi^2$  for trend [Cochran–Armitage test]). In all cases, dellen resolved by corneal scar formation following SCSO removal at the time of SO removal from the vitreous cavity.

**Table 1** Distribution of dellen occurrences among different categories

	Distribution	Dellen formation (P-value)
Age	52.3±14 (23–66) years	0.414 <sup>a</sup>
Sex	Six males and four females	0.655 <sup>b</sup>
Laterality	Five right and five left eyes	1 <sup>c</sup>
Indication of microincision vitrectomy	Four diabetics with tractional retinal detachment and six with rhegmatogenous retinal detachment	0.655 <sup>b</sup>
Laser done	Four underwent panretinal photocoagulation and six laser barrage	0.655 <sup>b</sup>
Instrument gauge	All ten cases were 23-gauge	0.211 <sup>c</sup>

**Notes:** <sup>a</sup>Student's *t*-test for independent samples; <sup>b</sup>Pearson's  $\chi^2$  with Yates continuity correction; <sup>c</sup>Fisher's exact test.

**Table 2** Distribution of dellen occurrences according to subconjunctival silicone oil (SCSO) characteristics

	Dellen	No dellen	P-value
Clock hours			0.252
1	1	3	
2	3	3	
≥3	6	4	
Area involved with SCSO			0.174
Upper temporal	3	0	
Direct temporal	1	3	
Both direct temporal and lower temporal	0	1	
Lower temporal	2	0	
Upper nasal	2	4	
Direct nasal	2	2	
Distance from the limbus	<2 mm	>2 mm	<0.001

**Note:** P-value calculated by Pearson's  $\chi^2$  for trend (Cochran–Armitage test).

No factors other than proximity to the corneal limbus were found to be associated with dellen formation in SCSO.

## Discussion

MIV was introduced in 2002 by Fujii et al.<sup>9</sup> Since that time, it has been gaining popularity among retinal surgeons, because it allows for more efficient surgery, faster recovery time, and better visual outcomes than 20 G vitrectomy.<sup>10,11</sup> The wound construction in MIV with the use of a trocar and cannula system causes less disruption of the conjunctiva and sclera. The incisions are smaller (0.51 mm for 25 G and 0.64 mm for 23 G), beveled, self-sealed, and ideally not requiring any suturing.<sup>12,13</sup> In spite of relatively better wound construction, leakage from the sclerotomies is a potential complication.<sup>14</sup>

Zivovnjovic popularized the use of SO as a tamponade agent with vitrectomy surgery in 1987.<sup>15</sup> Since then, it has become an established tamponade in treating complex vitreoretinal diseases.<sup>16</sup> SO as a tamponade is intended to be removed after several weeks to months, due to its potential anterior- and/or posterior-segment complications.<sup>17</sup> One of the complications of intraocular SO tamponade is its extraocular seepage. Studies have reported escape of SO and

**Table 3** Duration between microincision vitrectomy and silicone oil removal

Months	Dellen		Total
	No	Yes	
2.5	0	1	1
3	5	6	11
4	1	1	2
5	1	1	2
6	3	1	4

its migration into the eyelid with mechanical blepharoptosis,<sup>18</sup> cerebral migration,<sup>19</sup> migration in the SC space (through Molteno implant<sup>5</sup> or Ahmed glaucoma valve<sup>20</sup>), and formation of SC cysts.<sup>21</sup> Hyung and Min reported dellen disappearance after removal of SCSO.<sup>5</sup>

In the current study, we studied 20 eyes with SCSO, selected in a series from a large cohort of MIV. Because of the relative rarity of SCSO, the decision was taken to limit the sample size to the 20 cases collected over a 12-month duration. We evaluated the effect of SCSO following MIV on peripheral corneal dellen formation. Ten consecutive cases with dellen formation associated with SCSO were studied. All of them were found to have been done using 23 G MIV with SCSO observed within 2 mm of the limbus. Nevertheless, there were seven 23 G cases that did not develop dellen, but no cases with SCSO within the inner 2 mm escaped this complication. The incidence within the 23 G group may just be a coincidence, as it was more commonly used (17 of 20 eyes) or because it causes larger sclerotomies, facilitating the egress of SO. It could even have been due to bias, as larger-gauge MIV may be more common in difficult cases with longer surgery, more maneuvers, and less healthy eyes.<sup>22</sup>

The relation between the proximity of the conjunctival elevation and corneal dellen formation seems intuitive. Unfortunately, sclerotomies are usually done at only 3–4 mm from the limbus. This allows SCSO to form cysts with its proximal border close to the limbus;  $3.1 \pm 1.2$  mm in our study. The proximal 3 mm of the conjunctiva is characterized by its adherence to Tenon's capsule and sclera.<sup>23</sup> This may limit the centripetal spread of SO. However, older patients with looser conjunctiva and Tenon's capsule<sup>24</sup> are not associated with higher dellen incidence. To confirm this, a larger sample with more spread in age range is needed. Nevertheless, inflammation, which can be associated with the surgery and disturbance of ocular surface wetting, can promote matrix metalloproteinase-induced conjunctival and Tenon's capsule loosening,<sup>24</sup> helping the centripetal spread of SCSO.

Healing with scar formation occurred in all cases following SCSO evacuation at the time of SO removal from the vitreous cavity. This was comparable to what Krachmer and Palay reported,<sup>4</sup> and Hyung and Min found<sup>5</sup> resolution of dellen happened after resolution of the conjunctival swelling.

To the best of our knowledge, this study is the only one to analyze the proximity of the SCSO as a risk factor for developing corneal dellen. However, some factors still need to be studied, such as the effect of diabetes duration, smoking, nutritional factors, postoperative corneal sensation, duration of surgery, and need for intraoperative epithelial removal,

as well as the height of the SCSO bubble, the size of the dellen area, and corneal thickness in the dellen area.

In conclusion, SCSO leakage should be avoided by ensuring a tight sclerotomy at the end of MIV. Since these SCSO-associated dellen formations are resistant to topical treatment, an earlier evacuation of SCSO cysts may be necessary, even before the SO removal from the vitreous cavity, especially if close to the limbus, to avoid long-term peripheral corneal morbidity.

## Acknowledgment

The preliminary results of this work were presented as a poster in the third ARVO Egypt conference, held in Cairo, Egypt in December 2015.

## Disclosure

The authors report no conflicts of interest in this work.

## References

1. Tessler HH, Urist MJ. Corneal dellen in the limbal approach to rectus muscle surgery. *Br J Ophthalmol*. 1975;59:377–379.
2. Naritaa A, Seguchia J, Shiragab F. *Paecilomyces lilacinus*-induced scleritis following bleb associated endophthalmitis after trabeculectomy. *Acta Med Okayama*. 2015;69:313–318.
3. Biedner BZ, Rothkoff L, Friedman L, Geltman C. Colchicine suppression of corneal healing after strabismus surgery. *Br J Ophthalmol*. 1977;61:496–497.
4. Krachmer JH, Palay DA. *Cornea Atlas*. 3rd ed. Philadelphia: Saunders; 2013.
5. Hyung SM, Min JP. Subconjunctival silicone oil drainage through the Molteno implant. *Korean J Ophthalmol*. 1998;12:73–75.
6. Federman JL, Schubert HD. Complications associated with the use of silicone oil in 150 eyes after retina-vitreous surgery. *Ophthalmology*. 1988;95:870–876.
7. Siqueira RC, Gil AD, Jorge R. Retinal detachment surgery with silicone oil injection in transconjunctival sutureless 23-gauge vitrectomy. *Arq Bras Oftalmol*. 2007;70:905–909.
8. El-Batarny AM. Transconjunctival sutureless 23-gauge vitrectomy for vitreoretinal diseases: outcome of 30 consecutive cases. *Middle East Afr J Ophthalmol*. 2008;15:99–105.
9. Fujii GY, De Juan E Jr, Humayun MS, et al. A new 25-gauge instrument system for transconjunctival sutureless vitrectomy surgery. *Ophthalmology*. 2002;109:1807–1812.
10. Sato T, Emi K, Bando H, Ikeda T. Faster recovery after 25-gauge microincision vitrectomy surgery than after 20-gauge vitrectomy in patients with proliferative diabetic retinopathy. *Clin Ophthalmol*. 2012;6:1925–1930.
11. Kadonosono K, Yamakawa T, Uchio E, Yanagi Y, Tamaki Y, Araie M. Comparison of visual function after epiretinal membrane removal by 20-gauge and 25-gauge vitrectomy. *Am J Ophthalmol*. 2006;142:513–515.
12. Allen CH. Constructing a wound for MIVS. *Retina Today Suppl*. 2008; Sep-Oct, 6–8.
13. Warriar SK, Jain R, Gilhotra JS, Newland HS. Sutureless vitrectomy. *Indian J Ophthalmol*. 2008;56:453–458.
14. Byeon SH, Chu YK, Lee SC, Koh HJ, Kim SS, Kwon OW. Problems associated with the 25-gauge transconjunctival sutureless vitrectomy system during and after surgery. *Ophthalmologica*. 2006;220:259–265.

15. Zivojnovic R. *Silicone Oil in Vitreoretinal Surgery*. Alphen aan den Rijn, Netherlands: Kluwer; 1987.
16. Morphis G, Irigoyen C, Eleuteri A, Stappler T, Pearce I, Heimann H. Retrospective review of 50 eyes with long-term silicone oil tamponade for more than 12 months. *Graefes Arch Clin Exp Ophthalmol*. 2012; 250:645–652.
17. Lee JH, Kim YD, Woo KI, Kong M. Subconjunctival and orbital silicone oil granuloma (siliconoma) complicating intravitreal silicone oil tamponade. *Case Rep Ophthalmol Med*. 2014;2014:686973.
18. Mustafa TA, Al-Zuoby KM, Alawneh AM. Mechanical blepharoptosis and eyelid swelling caused by silicone oil. *J Optom*. 2009;2:27–28.
19. Kiilgaard JF, Milea D, Løgager V, la Cour M. Cerebral migration of intraocular silicone oil: an MRI study. *Acta Ophthalmol*. 2011;89: 522–525.
20. Nazemi PP, Chong LP, Varma R, Burnstine MA. Migration of intraocular silicone oil into the subconjunctival space and orbit through an Ahmed glaucoma valve. *Am J Ophthalmol*. 2001;132:929–931.
21. Biswas J, Bhende PS, Gopal L, Parikh S, Badrinath SS. Subconjunctival cysts following silicone oil injection: a clinicopathological study of five cases. *Indian J Ophthalmol*. 1999;47:177–180.
22. Nagpal M, Verma A, Goswami S. Micro-incision vitrectomy surgery: past, present and future vitreoretina. *Eur Ophthalmic Rev*. 2015;9: 64–68.
23. Bron AJ, Tripathy RC, Tripathy BJ. *Wolff's Anatomy of the Eye and Orbit*. 8th ed. London: Chapman and Hall; 1998.
24. Guo P, Zhang SZ, He H, Zhu YT, Tseng SC. PTX3 controls activation of matrix metalloproteinase 1 and apoptosis in conjunctivochalasis fibroblasts. *Invest Ophthalmol Vis Sci*. 2012;53:3414–3423.

## Clinical Ophthalmology

### Publish your work in this journal

Clinical Ophthalmology is an international, peer-reviewed journal covering all subspecialties within ophthalmology. Key topics include: Optometry; Visual science; Pharmacology and drug therapy in eye diseases; Basic Sciences; Primary and Secondary eye care; Patient Safety and Quality of Care Improvements. This journal is indexed on

Submit your manuscript here: <http://www.dovepress.com/clinical-ophthalmology-journal>

Dovepress

PubMed Central and CAS, and is the official journal of The Society of Clinical Ophthalmology (SCO). The manuscript management system is completely online and includes a very quick and fair peer-review system, which is all easy to use. Visit <http://www.dovepress.com/testimonials.php> to read real quotes from published authors.