

# Perforated tuberculous appendicitis: a rare case report

Alemayehu Gonie<sup>1</sup>  
Kebebe Bekele<sup>2</sup>

<sup>1</sup>Department of Nursing, School of Health Sciences, Goba Referral Hospital, Mada Walabu University, Bale-Goba, Ethiopia; <sup>2</sup>Department of Surgery, School of Medicine, Goba Referral Hospital, Mada Walabu University, Bale-Goba, Ethiopia

**Background:** Gastrointestinal tuberculosis (TB) accounts for 3% of extrapulmonary TB. Tuberculous appendicitis is a rare type of abdominal TB and is seen in only 0.1%–0.3% of cases. Diagnosis is usually made after histopathologic examination of the appendectomy specimen. In Ethiopia, there had been no previous report of perforated appendicular TB, and to our knowledge, this is the first case report of a patient with perforated tuberculous appendicitis to be presented.

**Case report:** A 22-year-old male patient presented with complaints of severe abdominal cramp, periumbilical pain, nausea, 2 episodes of nonbilious vomiting, as well as high-grade fever. Upon admission, abdominal examination revealed direct tenderness below the umbilicus bilaterally and rebound tenderness over the right lower quadrant of the abdomen. The peritoneal cavity was opened through a lower midline incision, and a perforated appendix at the base was found.

**Discussion:** From the resected appendix, a sample biopsy was sent for histopathology, and the histological picture revealed granulomatous caseification lesion in the body of the appendix, but no granulomatous lesions elsewhere in the bowel or omentum. Based on these findings, the final diagnosis of perforated tuberculous appendicitis was made. After surgery, the patient started anti-TB treatment on the fourth postoperative day and continued therapy for 6 months, and marked clinical recovery has been observed to date.

**Conclusion:** Perforated tuberculous appendicitis was diagnosed only after histopathologic examination of the resected appendix. Hence, TB, a highly prevalent disease in low-income countries, should always be considered in patients with nonspecific abdominal clinical sign and symptoms. It is also suggested that all specimens from perforated appendicitis be subjected to histopathologic examination.

**Keywords:** tuberculous appendicitis, perforated appendix, histopathology, resection, nonspecific abdominal pain

## Background

Tuberculosis (TB), one of the oldest diseases known to affect humans, is a major cause of death in low- and middle-income countries including Ethiopia.<sup>1,2</sup> This disease commonly affects the lungs, but it can involve any organ including the abdominal structures.<sup>1</sup> Among them, the appendix is a rare site of TB and is seen in only 0.1%–0.3% of gastrointestinal TB cases.<sup>3</sup> The uncommonness of tuberculous appendicitis may be due to the fact that there is a minimal contact of appendicular mucosa with intestinal contents.<sup>3,4</sup> In Ethiopia, there has been no data on the incidence of perforated appendicular TB. Hence, this case report of a patient with perforated tuberculous appendicitis is presented for the first time.

Correspondence: Alemayehu Gonie  
Department of Nursing, School of Health Sciences, Goba Referral Hospital, Mada Walabu University, PO Box 302, Bale-Goba, Ethiopia  
Tel +251 91 237 9531  
Email alemayehugonie19@gmail.com

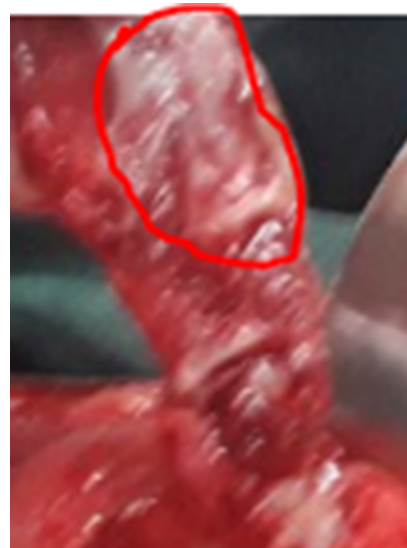
## Case report

A 22-year-old male patient from Agarfa district, south-east Ethiopia, presented to Goba Referral Hospital with complaints of severe abdominal cramp, periumbilical pain which shifted to the right lower quadrant of the abdomen for 30-hours duration, and 2 episodes of nonbilious vomiting as well as high-grade fever. He had no past history or family history of TB. He had no cough, sweating, and weight loss, which suggested the evidence of pulmonary TB. Similarly, the patient had no history of subacute intestinal obstruction in the past, had no diarrhea and constipation, and had no urgency or pain during urination.

During admission, the patient was acutely sick looking and vital signs were as follows: blood pressure 90/60, pulse rate 104 beat/min, respiratory rate 26 breath/min, and body temperature 38.3°C. Examination of respiratory and cardiovascular systems was essentially normal. Local examination of the abdomen revealed that abdomen moved with respiration, there was direct tenderness below the umbilicus bilaterally, and rebound tenderness over the right lower quadrant of the abdomen. Laboratory studies on blood revealed hemoglobin to be 12 g/dL; white blood cell count 15,800/ $\mu$ L, neutrophil 88%, and HIV serology result negative.

With the clinical diagnosis of pelvic peritonitis secondary to perforated acute appendicitis, the patient was taken up for surgery. The peritoneal cavity was opened through the lower midline incision and 30 mL of thick offensive pus in the right lower abdomen and perforated appendix at the base was found. Then, the pus was drained, appendectomy and abdominal lavage were performed, and the abdominal wall was closed inlayer.

From the resected appendix, excisional biopsy was sent for histopathology, and the histological picture revealed granulomatous caseification lesion in the body of the appendix, which is diagnostic for extrapulmonary TB (Figure 1). However, the intra-abdominal fluid, bowel, and omentum did not show any granulomatous lesions and no mesenteric lymphadenopathy. Based on these findings, the final diagnosis of perforated tuberculous appendicitis was made. After surgery, the patient took 1 g of ceftriaxone intravenously (IV) twice per day for 7 days and 500 mg of metronidazole IV 3 times per day for 7 days, and then started anti-TB treatment on the fourth postoperative day and continued it for 6 months. During the follow-up visits, the abdominal signs and symptoms were resolved and the patient had marked clinical recovery to date.



**Figure 1** Multiple tubercles on the body of the appendix (red circle).

## Discussion

Gastrointestinal TB accounts about 3% of extrapulmonary TB.<sup>5</sup> Although any portion of the gastrointestinal tract may be affected by TB, the terminal ileum and the cecum are the most common sites involved in TB.<sup>1</sup> The exact mechanism of tuberculous appendicitis remains unclear. However, the appendix can be involved rarely, but in various ways like via hematogenous route, infected intestinal contents, or through an extension from neighboring ileocecal or genital TB.<sup>6</sup>

Several authors reported the mode of tuberculous appendicitis infection to be ingestion of contaminated foods and unhealthy sanitary habits.<sup>3,6</sup> Rabbani et al<sup>7</sup> reported that tuberculous appendicitis was usually secondary to TB elsewhere in the abdomen.<sup>7</sup> Sinha and Sarin<sup>8</sup> also reported that appendicular TB was associated with secondary tuberculous salpingitis. The present case report represented the rare case of perforated tuberculous appendicitis as there was neither any suspicious lesion of TB in the gastrointestinal tract nor any evidence of TB elsewhere in the body.

Regarding the clinical pictures of perforated tuberculous appendicitis, none of the reported cases had a preoperative diagnosis of tuberculous appendicitis.<sup>7</sup> Some authors, including Maharjan,<sup>10</sup> and Morrison et al<sup>9</sup> reported that patients with tuberculous appendicitis had symptoms consistent with acute appendicitis.<sup>11,12</sup> Majority of the cases presented with recurrent episodes of pain at the right iliac fossa, vomiting,<sup>6</sup> vague abdominal pain, occasional history of diarrhea, and a mass in the right iliac fossa.<sup>3,13</sup> Harris et al<sup>14</sup> also reported periumbilical pain which settled in the right iliac fossa. Some

authors also reported that the symptoms of the disease were indistinguishable from pyogenic appendicitis.<sup>3</sup> The current case also had complained of severe abdominal cramp, periumbilical pain, and 2 episodes of nonbilious vomiting as well as high-grade fever.

Since patients present with unidentifiable clinical features, preoperative diagnosis of appendicular TB is difficult.<sup>11,15</sup> The diagnosis is usually made after the histopathologic examination of the appendectomy specimen.<sup>7,11</sup> In many reports, appendicular TB was found accidentally during the histopathologic examination of the resected appendix.<sup>10,11,16</sup> Similarly, in the current case report of perforated tuberculous appendicitis, the disease was found out accidentally during the histopathologic examination of the resected appendix.

## Conclusion

Upon admission, the patient was not suspected as having perforated tuberculous appendicitis but rather pelvic peritonitis secondary to perforated acute appendicitis. Perforated tuberculous appendicitis was diagnosed only after histopathologic examination of the resected appendix. Hence, TB, a highly prevalent disease in low- and middle-income countries, should always be considered in patients with nonspecific abdominal clinical sign and symptoms. It is also suggested that all specimen from perforated appendicitis be subjected to histopathologic examination.

## Ethical consent

Written informed consent was obtained from the patient for publication of this case report and any accompanying images.

## Acknowledgment

We would like to thank our study subject for his consent of publication of this case report and any accompanying images. We also thank Mr Micheal Carandi (American Peace Corps

volunteer, Ethiopia) and Mr Seifu Zeleke (English language instructor at Debre Berhan University, Ethiopia) for English language editing.

## Disclosure

The authors report no conflicts of interest in this work.

## References

1. Jameson JL, Kasper D, Hauser S, Longo D, Fauci A, Loscalzo J. *Harrison Principles of Internal Medicine*. New York: McGraw-Hill; 2008:Chapter 158.
2. Tessema B, Muche A, Bekele A, Reissig D, Emmrich F, Sack U. Treatment outcome of tuberculosis patients at Gondar University Teaching Hospital, Northwest Ethiopia. A five-year retrospective study. *BMC Public Health*. 2009;9:371.
3. Nuwal P, Dixit R, Jain S, Porwa V. Isolated appendicular tuberculosis – a case report. *Ind J Tub*. 2000;47:241–242.
4. Dogru T, Sonmez A, Tasci I, Yagci G, Mas MR. Perforated tuberculous appendicitis and peritoneal tuberculosis. *East Mediterr Health J*. 2008;14(3):742–744.
5. Wani I, Wani RA, Malik AA, et al. Abdominal tuberculosis. *OA Case Rep*. 2014;3(5):45.
6. Chowdhury FR, Amin R, Khan KH, Alam B, Ahasan H. Isolated appendicular tuberculosis (TB) presented as peritonitis. *Nepal Med Coll J*. 2010;12(1):51–52.
7. Rabbani K, Narjis Y, Difaa A, Louzi A, Benelkhaiat R, Finech B. Tuberculous appendicitis. *Saudi J Gastroenterol*. 2010;17(4):287–289.
8. Sinha S, Sarin YK. Tuberculous appendicitis. *Indian J Pediatr*. 2005;72:712.
9. Morrison H, Mixter CG, Schlesinger MJ, Ober WB. Tuberculosis localized in the vermiform appendix. *N Engl J Med*. 2016;246(9):329–343.
10. Maharjan S. An uncommon case of chronic tubercular appendicitis. *Case Rep Pathol*. 2015;2015:1–4.
11. Gupta S, Kaushik R, Kaur A, Attri AK. Tubercular appendicitis – a case report. *World J Emerg Surg*. 2006;1:22.
12. Chiş BA, Dudric V, Fodor D. Tuberculous appendicitis. A case report. *Med Ultrason*. 2017;19(3):333–335.
13. Dimakopoulos K, Saltas D, Penopoulos V, et al. Gastrointestinal tuberculosis mimicking Crohn's disease. Case report and review of the literature. *Ann Gastroenterol*. 2005;18(1):84–87.
14. Harris SH, Ansari MM, Gupta AR, Afroz N. Isolated appendicular tuberculosis : a rare cause of acute appendicitis. *J Exp Integr Med*. 2015;5(2):114–116.
15. Agarwal PD, Sharma D, Agarwal A, et al. Tuberculous appendicitis in India. *Trop Doct*. 2004;34(1):36–38.
16. Bobrow ML, Friedman S. Tuberculosis appendicitis. *Am J Surg*. 1956;91(3):389–393.

International Medical Case Reports Journal

Publish your work in this journal

The International Medical Case Reports Journal is an international, peer-reviewed open-access journal publishing original case reports from all medical specialties. Previously unpublished medical posters are also accepted relating to any area of clinical or preclinical science. Submissions should not normally exceed 2,000 words or

Submit your manuscript here: <https://www.dovepress.com/international-medical-case-reports-journal-journal>

4 published pages including figures, diagrams and references. The manuscript management system is completely online and includes a very quick and fair peer-review system, which is all easy to use. Visit <http://www.dovepress.com/testimonials.php> to read real quotes from published authors.