

Clinical and epidemiologic profile and predictors of outcome of poisonous snake bites – an analysis of 1,500 cases from a tertiary care center in Malabar, North Kerala, India

KG Sajeeth Kumar
Santhosh Narayanan
V Udayabhaskaran
NK Thulaseedharan

Department of General Medicine,
Government Medical College,
Kozhikode, Kerala, India

Background: Snake bites are a neglected public health problem in all tropical countries, and particularly in Malabar region of Kerala, India. Demographic characteristics and clinical parameters vary in this part of the world, and studies based on them are scarce. Increased incidence of capillary leak syndrome (CLS) in hemotoxic snake bites and emergence of cases of hump-nosed pit viper (HNPV, *Hypnale hypnale*) envenomation are some notable features seen here.

Objectives: The study was conducted to assess the epidemiological profile and clinical features to identify factors contributing to outcome in patients with venomous snakebites.

Materials and methods: An observational cross-sectional study was done among patients with snakebite envenomation, admitted to Government Medical College, Kozhikode, Kerala, from January 2012 to October 2016.

Results: There were 1,500 cases of toxic snake bites, of which 65% of these cases were males. Forty eight percent of them were aged between 21 and 40 years. Hemotoxic snake bites predominated, accounting for 912 cases. Viperine bite was the most commonly observed snakebite, and 70% of this was due to Russell's viper and 25% due to HNPV. Among the neurotoxic bites, common krait bites predominated. Overall mortality was 8.8%. CLS was the major cause of death (80%). The mean dose of antivenom given for neuroparalytic snakebite was 10.25 vials, and 18.5 vials for hemotoxic bites. Albuminuria, neutrophilic leucocytosis, thrombocytopenia, acute kidney injury (AKI), and early onset of symptoms were associated with poor outcome.

Conclusion: This study emphasizes the importance of snakebite as a significant threat to the community in the tropics. CLS in hemotoxic snake bites is the leading cause of mortality and is often refractory to any treatment measures. This study also brings to light the graveness of complications caused by HNPV envenomation. Anti-snake venom with activity against HNPV venom needs to be manufactured. Lack of awareness, delayed presentation to the hospital, and treatment by nonmedical personnel also add to the risk of mortality.

Keywords: hump-nosed pit viper, capillary leak, antivenom, Russell's viper, hemotoxic, neurotoxic, snake bite

Introduction

Snake bites cause considerable mortality and morbidity, with approximately 125,000 deaths worldwide annually.¹ The World Health Organization (WHO) recognizes snakebite as a neglected tropical disease. Mortality due to poisonous snakebites in India is the highest in the world, with around 10,000 deaths per annum.² Social, cultural, and economic reasons contribute immensely to the death toll.³ In India, there are 216

Correspondence: Santhosh Narayanan
Department of General Medicine,
Government Medical College, Kozhikode,
Kerala 673008, India
Email drsanthosh4@gmail.com

species of snakes, with varied distribution in different parts of the country (Table 1).

Kerala is a state in south India with 14 districts. Malabar is the northern part of Kerala and consists of 6 districts, namely, Kozhikode, Malappuram, Kannur, Kasaragod, Palakkad, and Wayanad. Govt. Medical College, Kozhikode, the center where our study was conducted, is the sole government tertiary care center in Malabar and caters to all these districts. Kerala is one of the areas in India with high incidence of snakebites besides West Bengal, Tamil Nadu, Maharashtra, and Andhra Pradesh. In Kerala, there are approximately 37 species of poisonous snakes. Apart from the “Big 4” (common cobra, *Naja naja*; common krait, *Bungarus caeruleus*; Russell’s viper, *Daboia russelli*; and saw-scaled viper), hump-nosed pit viper (HNPV, *Hypnale hypnale*), Malabar pit viper (*Trimeresurus malabaricus*), bamboo pit viper (*Trimeresurus gramineus*), and the banded krait (*Bungarus fasciatus*) are the major species seen here. This study aimed to highlight the differences in epidemiological and clinical profile of toxic snake bites and also outline the possible prognostic factors which can predict the outcome in Malabar region of Kerala, as opposed to rest of the world.

Materials and methods

This was a prospective observational study of all patients with snake bites admitted to the snake bite division of the Government Medical College, Kozhikode, Kerala. The study period was from January 2012 to December 2016. Patients were included if they had a definite history of snake bite and developed features of envenomation. Patients with nonvenomous or so-called “dry” bite, defined by lack of signs or symptoms of envenomation after a period of observation, were excluded. Patients included in the study were evaluated

based on a proforma with detailed history and clinical examination. Data were also collected regarding occupation, educational status, awareness about preventive measures, need for early treatment, and a history of any treatment by nonmedical personnel. Treatment by nonmedical personnel included incision and suction, herbal remedies which included asafetida, neem leaves, and garlic. Other unscientific methods used by nonmedical personnel were application of potassium permanganate and turmeric over the site of the bite. Some of these personnel even used hens to suck out the venom. These irrational measures would delay the patient in seeking hospital attention. The species of snake was labeled only if the snake was brought along with the victim and identified by 2 different experts independently. Clinical features of venomous bites included regional (local) toxicity at the site of bite or systemic toxicity or both. Local toxicity consisted of pain, edema, bruising, blistering, cellulitis, bleeding, and complications like compartment syndrome, abscess formation, and gangrene. Systemic toxicity was defined by the presence of neurological features or hemostatic dysfunction. Drowsiness, paresthesia, ptosis, external ophthalmoplegia, paralysis of facial muscles, regurgitation through the nose, difficulty in swallowing secretions, and respiratory and generalized flaccid paralysis were manifestations of neurotoxicity. Hemotoxicity was deemed as spontaneous systemic bleeding, prolonged bleeding from recent wounds, fang marks, venipuncture sites, coagulopathy, and hemolysis. Capillary leak syndrome (CLS) is a major complication of hemotoxic snake bites encountered in the Malabar region. For our study, this syndrome was defined as a combination of hypotension, hypoalbuminemia, and fluid loss into the third space. Hypoalbuminemia should occur in the absence of albuminuria. To detect third-space fluid loss, imaging methods were used.

Table 1 Common snakes in India and their geographical distribution

Snake species	Common name	Geographical distribution
<i>Naja naja</i>	Common cobra	Throughout India
<i>Naja kouthia</i>	Monocellate cobra	Assam and Northeastern region
<i>Ophiophagus hannah</i>	King cobra	Western Ghats, Andaman and Nicobar Islands
<i>Naja sagittifera</i>	Andaman cobra	Andaman and Nicobar Islands
<i>Bungarus caeruleus</i>	Common krait	Kerala, Tamil Nadu, and Northeastern region
<i>Bungarus fasciatus</i>	Banded krait	Andhra Pradesh, Uttarakhand, and Northeastern regions
<i>Daboia russelii</i>	Russell’s viper	South India and Western India
<i>Echis carinatus</i>	Saw-scaled viper	South India and Western India
<i>Hypnale hypnale</i>	HNPV	Western Ghats
<i>Trimeresurus malabaricus</i>	Malabar pit viper	Southwestern coast and Western Ghats
<i>Trimeresurus gramineus</i>	Indian bamboo viper	South India, Andaman and Nicobar Islands

Abbreviation: HNPV, hump-nosed pit viper.

Grading of severity of envenomation is as follows: Grade 1, local pain and swelling; Grade 2, local ecchymoses, mild systemic findings, and laboratory findings; Grade 3, marked local reaction, severe systemic manifestations and wide laboratory alterations.

As per our hospital protocol (based on WHO guidelines), all patients bitten by a poisonous snake received polyvalent anti-snake venom (ASV) manufactured by VINS Bioproduct Limited, within 15 minutes of reaching the hospital, if they had clinical features of envenomation. The antivenom is a polyvalent one and would neutralize the venoms of the 4 major snakes of India (common cobra, common krait, Russell's viper, and saw-scaled viper). If they did not have features of envenomation at presentation, ASV was administered when the first sign of envenomation appeared. ASV was not administered for pit viper bites. An initial dose of 10 vials of ASV was given for all snake bite patients with features of envenomation. Response to ASV was monitored clinically and by doing 20 minute whole blood clotting time (WBCT20). WBCT20 was done for all patients every 30 minutes for the first 3 hours and hourly for next 3 hours, and hourly after that. If the features of envenomation were persistent or if the WBCT20 was prolonged after 6 hours of first dose, a repeat dose of ASV was given. A maximum of 20 vials were given for hemotoxic snakebites and a maximum of 10 vials were given for neurotoxic snakebites.

The following investigations were carried out in all patients: hemoglobin (Hb), total leukocyte count, platelet count, erythrocyte sedimentation rate, urine albumin, renal and liver function tests, creatine phosphokinase, prothrombin time, activated partial thromboplastin time, and serum fibrinogen. All the data obtained were recorded and analyzed using SPSS software, version 18 (SPSS Inc., Chicago, IL, USA).

Ethics committee approval and informed consent

The Institutional Ethics Committee of Government Medical College, Kozhikode, Kerala, approved the research project. Written informed consent was obtained from all patients who had participated in this study. For patients who were not of legal age to sign on their own behalf, written informed consent was obtained from their guardians.

Results

There were 1,500 cases of venomous snake bites during the study period. Most of the patients were males (65%). A majority of the victims (722) fell in the age group between 21 and 40 (Figure 1).

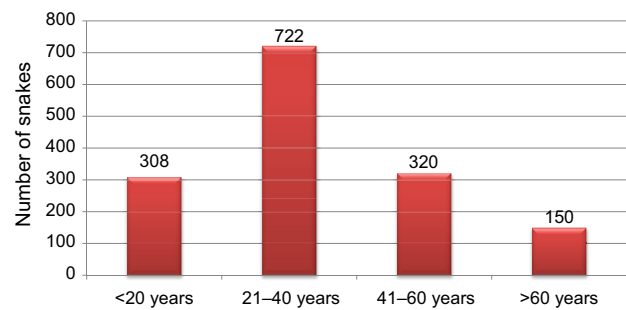


Figure 1 Age distribution of patients.

Most of the bites (42%) occurred between the months of August and October (Figure 2).

The number of patients who came to our hospital with poisonous snake bites over the years is shown in Figure 3.

Bites in the extremities predominated. About 1156 (77%) patients reported lower limb bites. Other sites of snakebite, in decreasing order, were upper limb, trunk, and head and neck, as illustrated in Figure 4.

Only 12% of patients arrived to the hospital within 1 hour of bite, 68% arrived within 6 hours. 10% were brought in after 6 hours, and 6% arrived 24 hours after the bite. The timing of the snakebites varied, with the majority of the bites occurring in the evening hours (5–9 pm) and the least during the early morning hours (4–8 am). Of the snake species identified, the most common snake identified was Russell's viper (538 cases), followed by common krait (382 cases), HNPV (224 cases), and common cobra (204 cases). There were 104 cases where the bite was due to the saw-scaled viper, 26 due to Malabar pit viper, 20 cases due to bamboo pit viper, and 2 cases due to banded krait (Figure 5). The species of snake could not be identified in 206 cases.

Hemotoxic bites (61%) exceeded neurotoxic bites (34%) by a significant margin. Fang marks were seen in 88% (1,320) of the cases.

The clinical profile and complications of patients with hemotoxic snake bite are summarized in Table 2.

Of the systemic bleeding manifestations, hematuria was the most common (seen in 246 patients) followed by bleeding gums in 218 patients. Hemoptysis was seen in 172 patients. Retinal hemorrhages were seen in 106 patients. Features of disseminated intravascular coagulation (DIC) were seen in 89 patients (in 72 patients with Russell's viper bite and the rest were seen in those with a HNPV bite). Three patients had thrombotic thrombocytopenic purpura. Seven patients had intracranial hemorrhage. Six patients (5 with Russell's viper bite and 1 with HNPV bite) sustained cerebrovascular accidents. Thirty-two of the 36 patients who had adult respiratory

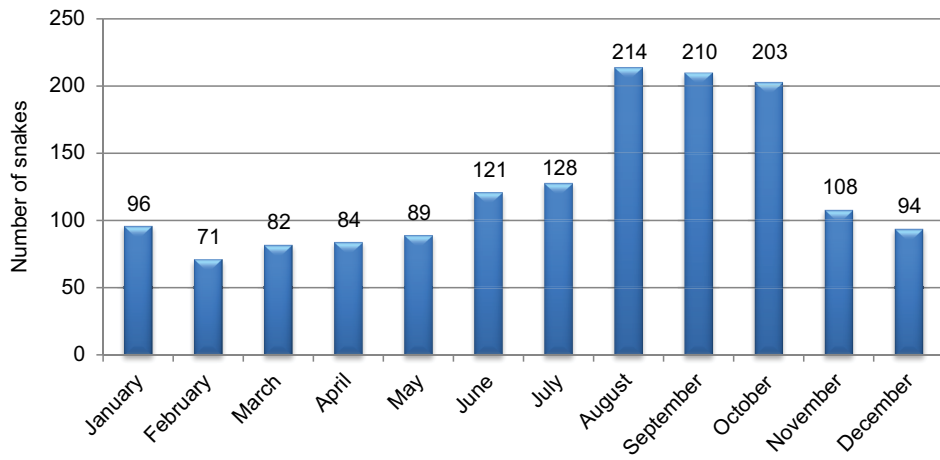


Figure 2 Seasonal variation of snake bites.

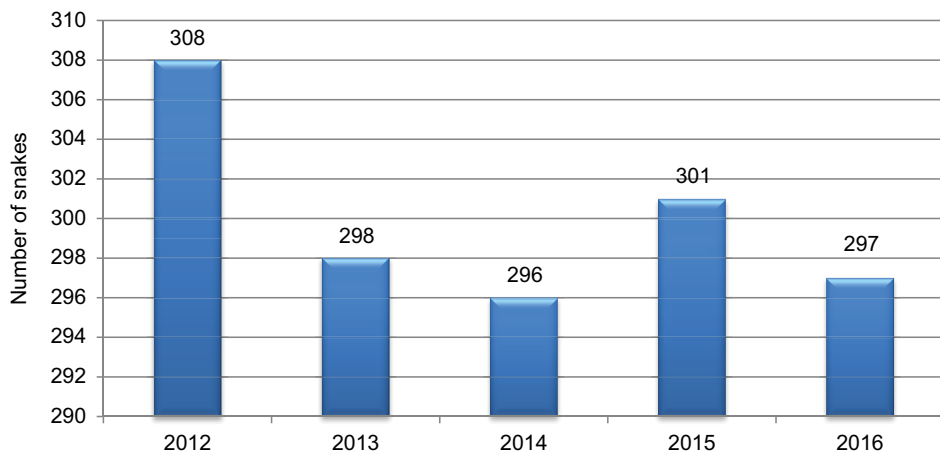


Figure 3 Year-wise distribution of snake bites.

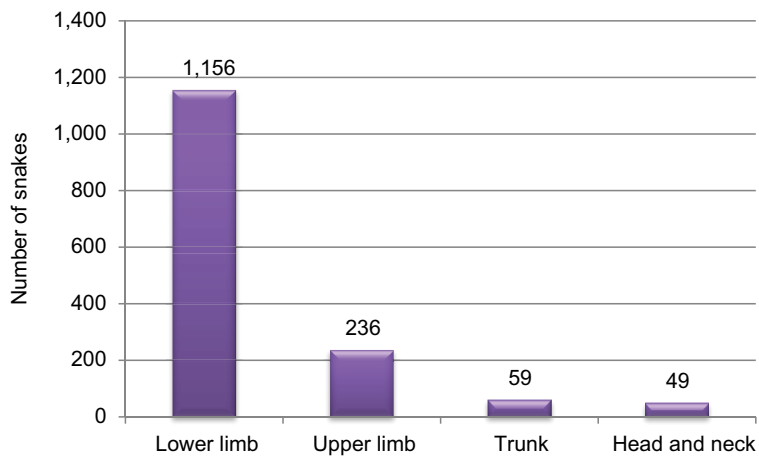


Figure 4 Site of snake bite.

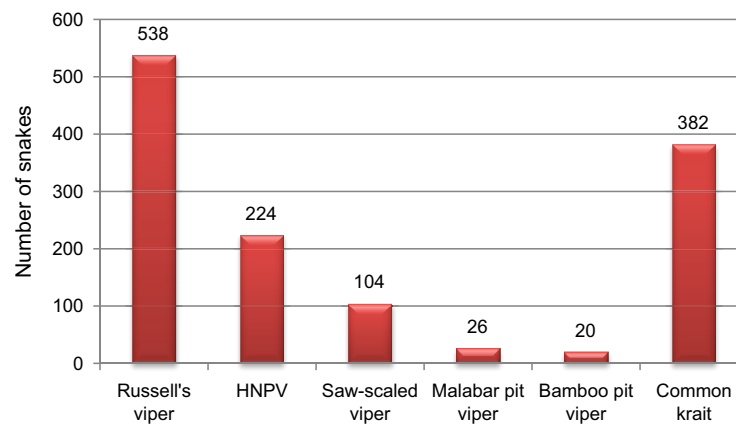


Figure 5 Species distribution of snake bite.
Abbreviation: HNPV, hump-nosed pit viper.

Table 2 Clinical profile and complications of hemotoxic snake bite

Clinical features	Number of patients				
	Russell's viper (n=538)	HNPV (n=224)	Saw-scaled viper (n=104)	Malabar pit viper (n=26)	Bamboo pit viper (n=20)
Bleeding from the bite site	526 (97.7%)	206 (91.9%)	91 (87.5%)	20 (77%)	14 (70%)
Coagulopathy	528 (98.1%)	216 (96.4%)	84 (80.7%)	22 (84.6%)	16 (80%)
Local pain	516 (96%)	209 (93.3%)	102 (98%)	24 (92.3%)	14 (70%)
Local swelling	509 (94.6%)	204 (91%)	100 (96.1%)	21 (80.7%)	17 (85%)
Vomiting	393 (73%)	91 (40.6%)	62 (59.6%)	15 (57.6%)	9 (45%)
Regional lymphadenopathy	121 (41%)	101 (45%)	34 (32.6%)	9 (34.6%)	7 (35%)
Systemic bleeding manifestations	314 (58.3%)	131 (58.4%)	36 (34.6%)	8 (30.7%)	6 (30%)
AKI	189 (35.1%)	44 (19.6%)	39 (37.5%)	6 (23%)	3 (15%)
Dialysis-requiring AKI	54 (10%)	15 (6.6%)	13 (12.5%)	1 (3.8%)	0 (0%)
Features of CLS	91 (17%)	3 (1.3%)	1 (0.09%)	0 (0%)	0 (0%)
Adult respiratory distress syndrome	33 (6.1%)	3 (1.3%)	0 (0%)	0 (0%)	0 (0%)
Local cellulitis, necrosis, and gangrene	105 (19.5%)	81 (36.16%)	14 (13.4%)	1 (0.03%)	0 (0%)
Death	73 (13.5%)	3 (1.3%)	6 (5.7%)	0 (0%)	0 (0%)

Abbreviations: AKI, acute kidney injury; CLS, cellular leak syndrome; HNPV, hump-nosed pit viper.

distress syndrome also required dialysis for their acute kidney injury (AKI), and they succumbed to their illness. Four patients with Russell's viper bite had pulmonary alveolar hemorrhage, of which 2 patients expired. Two patients with Russell's viper bite suffered from in-hospital anterior wall myocardial infarction within 3 days of admission. Cardiac arrhythmias were observed in 27 patients with Russell's viper bite, with atrial fibrillation being the most common (21 patients) followed by paroxysmal supraventricular tachycardia (6 patients). Among the ophthalmic complications, subconjunctival hemorrhage was most commonly seen (156 patients) followed by vitreous hemorrhage in 96 patients. Six patients had acute congestive glaucoma. Among the local complications, 29 patients with Russell's viper bite developed compartment syndrome requir-

ing fasciotomy, and 16 of them developed gangrene of the limb, which ultimately needed amputation. Thirteen patients developed osteomyelitis at the site of the bite.

We had 6 cases of Russell' viper bite and 3 cases of HNPV bite in antenatal women, of which 2 patients with Russell's viper bite succumbed to death due to CLS. Four patients developed pituitary apoplexy, with subsequent hypopituitarism on follow-up.

The clinical features and complications of neurotoxic snake bites are summarized in Table 3.

Ptosis was the commonest manifestation followed by ophthalmoplegia. The most common site of parasthesia was in the perioral region, tongue, followed by the limbs. Two patients with bites by the common krait developed myocar-

Table 3 Clinical profile of neurotoxic snake bites

Clinical features	Number of patients		
	Common krait (n=382)	Common cobra (n=204)	Banded krait (n=2)
Ptosis	194 (50.7%)	96 (47%)	2 (100%)
Ophthalmoplegia	182 (47.6%)	88 (53%)	2 (100%)
Blurred vision	139 (36.3%)	84 (41%)	1 (50%)
Vertigo	82 (21.4%)	76 (37.2%)	0 (0%)
Headache	74 (19.3%)	49 (24%)	0 (0%)
Parasthesia	177 (46.3%)	92 (45%)	1 (50%)
Respiratory distress (SBC <20)	104 (27%)	77 (37.7%)	1 (50%)
Respiratory arrest requiring ventilator	71 (18.58%)	43 (21%)	1 (50%)
Death	36 (9.4%)	14 (6.8%)	0 (0%)

Abbreviation: SBC, single breath count.

ditis. Most of the patients requiring ventilator support had a delayed presentation to the hospital.

Hb concentration could be assessed in 1,456 patients. Twenty-three percent of the patients had Hb concentration less than 10 g/dL, and 16% had Hb concentration more than 16 g/dL. Mean Hb concentration was 12.2 g/dL. Leucocytosis was present in 36% of the patients. Thrombocytopenia was seen in 29% of patients. Clotting time was prolonged in 68% of the patients with hemotoxic snakebites. Prolongation of prothrombin time was observed in 98.1% of patients with Russell's viper bite and in 96.4% with HNPV bite. The mean time taken for resolution of coagulopathy was 1.5 days in patients with Russell's viper bite and 6 days for HNPV bite. The number of days taken for the resolution of coagulopathy had a significant association with the development of AKI, odds ratio 2.88 (95% confidence interval: 1.18–6.20). Different parameters which could predict the outcome and its statistical correlation are illustrated in Table 4.

Discussion

Snake bites are a neglected health problem in tropical countries, as notified by the WHO. In our study which involved 1,500 patients, the majority of the victims were male. Most of the bites occurred in young individuals between 20 and 40 years of age. This might be due to the fact that they are more engaged in outdoor activities and associated with agriculture. This finding is in accordance with the results of other studies done in various Indian regions.^{4,5} Majority of the bites occurred between the months of August and October. This could be explained due to the harvesting of the agricultural crops that occurs during this time. The lush vegetation attracts rodents, which are prey for the snakes.⁶ Hansdak et al⁷ also reported that 51% of cases occurred during monsoon (August–October). A major determinant of the outcome of snakebites is the time taken to reach the hospital following the bite.⁸ In our study, 80% of the victims reached

Table 4 Predictors of outcome of venomous snake bites

Variable	Hazard ratio	P-value
Time between bite and arrival at hospital	1.386	0.031
Vomiting	1.242	0.039
Regional lymphadenopathy	2.173	0.596
Neuroparalysis	1.872	0.041
Bleeding tendency	1.968	0.001
Coagulopathy	3.124	0.021
Mean Hb concentration	1.893	0.796
Mean platelet count	2.125	0.022
Mean serum creatinine	1.347	0.001
Albuminuria	1.818	0.008
Clotting time >20 minutes	1.431	0.005
Capillary leak	1.234	<0.001
Severe local cellulitis	2.864	0.018
Respiratory distress	1.189	0.023

Abbreviation: Hb, hemoglobin.

the hospital within 6 hours of the bite. This may be one of the reasons for the low mortality seen in our study as compared to other studies conducted in India. More than one-fourth of the patients had a history of application of pressure bandages or tourniquet proximal to the site of the bite. In a study by Sitprija and Boonpucknavig,⁹ this was shown to contribute to an increase in local complications.

Majority of the victims were prey to hemotoxic snakes. It is to be emphasized that about one-fourth of hemotoxic bites were due to the HNPV. Bites of the HNPV exhibit symptoms of local envenoming such as pain, swelling, hemorrhagic blistering, bruising, and regional lymphadenopathy. The systemic symptoms included headache, nausea, vomiting, and abdominal pain. In our study, 19.6% of patients with HNPV bites developed AKI, and 15 patients required dialysis. A significant number of patients with HNPV bite had coagulopathy (96.4%). The venom-induced coagulopathy seen in HNPV envenomation is different from DIC as these patients had a normal platelet count. An interesting observation was that these patients had incoagulable blood for a mean of 6 days,

but none of them had any major or minor bleeding. Finding the particular component of the HNPV venom that makes blood incoagulable could be of major therapeutic importance in the field of anticoagulation.¹⁰⁻¹²

The coagulopathy observed in Russell's viper envenomation was significantly associated with low platelet count and clinical bleeding, suggesting venom-induced DIC as the mechanism.¹³ In the present study, Russell's viper envenomation produced more severe complications and death than HNPV bites. CLS was a unique complication that occurred mainly in Russell's viper bite, and it had a very high mortality rate.¹⁴ In our study, all the deaths due to Russell's viper bites were due to CLS. CLS is characterized by hypotension with hemoconcentration, hypoalbuminemia without albuminuria, and generalized edema.¹⁵ Typically, the syndrome manifests in 2 phases: initial capillary leak phase characterized by generalized edema, serous effusion, and hypotension, which is followed by a phase of volume overload or recruitment phase. It is postulated that a vascular apoptosis producing component of Russell's viper venom (a zinc metalloproteinase) that is not neutralized by the available ASV is responsible for this complication.

The most common feature of neuroparalysis was ptosis. When respiratory failure was present in a patient with snakebite, it was associated with increased mortality. This finding was also observed in a study conducted by Bawaskar and Bawaskar.^{16,17} In our study, bites due to common krait outnumbered bites due to other neurotoxic snakes. The krait venom blocks both presynaptic and postsynaptic receptors, and so the patient needs prolonged mechanical ventilation support until these receptors are activated.^{18,19} A single breath count test was a reliable clinical sign and could predict impending respiratory distress.

Among the laboratory parameters, thrombocytopenia, prolongation of whole blood clotting time for more than 20 minutes, AKI with serum creatinine >3 mg/dL, and albuminuria were associated with an adverse outcome.

Conclusion

This study brings to light the fact that snake bite is an important public health problem in tropical countries. In our study, hemotoxic snakebites were the major cause of morbidity. HNPV bite is an underrecognized cause of morbidity and mortality in North Kerala, India. Severe AKI, potential to cause renal cortical necrosis, and even death following HNPV envenomation are the major points highlighted by our study.

ASV with activity against HNPV venom needs to be manufactured and made available in India where these snakes are highly endemic. CLS is a unique manifestation of viperine bites and is a predictor of adverse outcome.

Disclosure

The authors report no conflicts of interest in this work.

References

1. Chippaux JP. Snake-bites: appraisal of the global situation. *Bull World Health Organ.* 1998;76(5):515–524.
2. Kasturiratne A, Wickremasinghe AR, de Silva N, et al. Estimating the global burden of snakebite: a literature analysis and modelling based on regional estimates of envenoming and deaths. *PLoS Med.* 2008;5:e218.
3. Inamdar IF, Aswar NR, Ubaidulla M, Dalvi SD. Snakebite: admissions at a tertiary health care centre in Maharashtra, India. *S Afr Med J.* 2010;100(7):456–458.
4. Kalantri S, Singh A, Joshi R, et al. Clinical predictors of in-hospital mortality in patients with snakebite: a retrospective study from a rural hospital in central India. *Trop Med Int Health.* 2006;11(1):22–30.
5. Suchithra N, Pappachan JM, Sujathan P. Snakebite envenoming in Kerala, South India: clinical profile and factors involved in adverse outcomes. *Emerg Med J.* 2008;25(4):200–204.
6. Warrell DA. Snake bite: a neglected problem in twenty-first century India. *Natl Med J India.* 2011;24(6):321–324.
7. Hansdak SG, Lallar KS, Pokharel P, Shyangwa P, Karki P, Koirala S. A clinico-epidemiological study of snake bite in Nepal. *Trop Doct.* 1998;28(4):223–226.
8. Sharma SK, Khanal B, Pokharel P, Khan A, Koirala S. Snakebite-reappraisal of the situation in Eastern Nepal. *Toxicon.* 2003;41(3):285–289.
9. Sitprija V, Boonpucknavig V. Snake venoms and nephrotoxicity. In: Lee CY, editor. *Snake Venoms.* Berlin: Springer Verlag; 1979.
10. Mehta RL, Kellum JA, Shah SV, et al. Acute kidney injury network. "Acute Kidney Injury network report of an initiative to improve outcome in acute kidney injury." *Crit Care.* 2007;11(2):R31.
11. Joseph JK, Simpson ID, Menon NC, et al. First authenticated cases of life-threatening envenoming by the hump-nosed pit viper (*Hypnale hypnale*) in India. *Trans R Soc Trop Med Hyg.* 2007;101(1):85–90.
12. Shivanthan MC, Yudhishdran J, Navinan R, Rajapakse S. Hump-nosed viper bite: an important but under-recognized cause of systemic envenoming. *J Venom Anim Toxins Incl Trop Dis.* 2014;20:24.
13. Kumar V, Sabitha P. Inadequacy of present polyspecific anti snake venom – a study from central Kerala. *Indian J Pediatr.* 2011;78(10):1225–1228.
14. Vigneau C, Haymann JP, Khoury N, Sraer JD, Rondeau E. An unusual evolution of the systemic capillary leak syndrome. *Nephrol Dial Transplant.* 2002;17(3):492–494.
15. Mohapatra B, Warrell DA, Suraweera W, et al. Snakebite mortality in India: a nationally representative mortality survey. *PLoS Negl Trop Dis.* 2011;5(4):e1018.
16. Kulartane SA. Common krait (*Bungarus caeruleus*) bite in Anuradhapura, Sri Lanka: a prospective clinical study 1996–98. *Postgrad Med J.* 2002;78(919):276–280.
17. Bawaskar HS, Bawaskar PH. Profile of snakebite envenoming in western Maharashtra, India. *Trans R Soc Trop Med Hyg.* 2002;96(1):79–84.
18. Agrawal PN, Agrawal AN, Gupta D, Behera D, Prabhakar S, Jindal SK. Management of respiratory failure in severe neuroparalytic snake envenomation. *Neurol India.* 2001;49(1):25–28.
19. Sharma SK, Koirala S, Dahal G. Krait bite requiring high dose anti-venom: a case report. *Southeast Asian J Trop Med Public Health.* 2002;33(1):170–171.

International Journal of General Medicine**Dovepress****Publish your work in this journal**

The International Journal of General Medicine is an international, peer-reviewed open-access journal that focuses on general and internal medicine, pathogenesis, epidemiology, diagnosis, monitoring and treatment protocols. The journal is characterized by the rapid reporting of reviews, original research and clinical studies across all disease areas.

The manuscript management system is completely online and includes a very quick and fair peer-review system, which is all easy to use. Visit <http://www.dovepress.com/testimonials.php> to read real quotes from published authors.

Submit your manuscript here: <https://www.dovepress.com/international-journal-of-general-medicine-journal>