

Eight-ball hyphema after laser iridotomy in a patient with undiagnosed hypocellular myelodysplastic syndrome

Sira Arunmongkol
Yanin Suwan
Wasu Supakontanasan
Suthaphat Nilphatanakorn
Chaiwat Teekhasaenee

Department of Ophthalmology,
Faculty of Medicine, Ramathibodi
Hospital, Mahidol University, Bangkok,
Thailand

Introduction: We report a rare case of unexpected gross hyphema in the right eye (OD) and eight-ball hyphema in the left eye (OS) from a bilateral laser iridotomy in an acute primary angle-closure patient. We also demonstrated the effectiveness of the inferior full-thickness trabeculectomy with daily intracameral air injection as an alternative treatment in eight-ball hyphema.

Case report: An 81-year-old Thai female presented with gross hyphema grade II OD and eight-ball hyphema with blood-stained cornea OS after laser iridotomy. The patient was scheduled for surgery and the preoperative blood test showed bicytopenia. We performed anterior chamber washout OD and an inferior full-thickness trabeculectomy with daily intracameral air injection OS. The hyphema completely resolved on the following day OD and 3 days after surgery OS. The inferior bleb OS did not raise with digital pressure and became nonfunctional in 7 days. No recurrent hyphema was found in both eyes (OU) during 6 months of follow-up. This patient was ultimately diagnosed with hypocellular myelodysplastic syndrome (MDS).

Conclusion: Gross hyphema after laser iridotomy can be seen in patients with hypocellular MDS. The inferior full-thickness trabeculectomy is an alternative surgical procedure for an eight-ball hyphema.

Keywords: gross hyphema, full-thickness trabeculectomy, primary angle-closure, goniosynechialysis

Introduction

Hyphema after laser iridotomy occurs in up to 40% of patients but gross hyphema is very rare,¹⁻⁶ regardless of antiplatelet or anticoagulant usage.⁷ To our knowledge, this is the first report of an eight-ball hyphema resulting from a laser iridotomy in an acute primary angle-closure patient with undiagnosed hypocellular myelodysplastic syndrome (MDS).

There are various surgical methods for hyphema management such as limbal paracentesis needle drainage, anterior chamber washout using an irrigating Simcoe cannula, anterior chamber washout using an automated anterior vitrectomy, conventional limbal clot delivery method and trabeculectomy with anterior chamber washout and peripheral iridectomy.⁸ For an eight-ball hyphema where surgical management is indicated, procedures other than those described above include injection of urokinase, injection of sodium hyaluronate, cryoextraction, iridectomy and evacuation by vitrectomy instrumentation.⁹⁻¹³ However, surgical management of an eight-ball hyphema is more challenging than a non-eight-ball hyphema, as the anterior segment is totally obscured. Iatrogenic trauma to the lens, iris or corneal endothelium can easily occur with the ab interno approach. To avoid these complications and effectively drain an eight-ball

Correspondence: Yanin Suwan
Department of Ophthalmology,
Ramathibodi Hospital, 270 Rama VI Road,
Ratchatewi, Bangkok 10400, Thailand
Tel +66 2 201 2729
Fax +66 2 201 1516
Email yanin.suwan@gmail.com

hyphema, we demonstrated an alternative ab externo surgical treatment using a limbal-based, inferior full-thickness trabeculectomy with daily intracameral air injection.

Case report

An 81-year-old Thai female was referred to our hospital because of gross hyphema grade II in the right eye (OD) and eight-ball hyphema with blood-stained cornea in the left eye (OS) (Figure 1A–C). She underwent laser iridotomy in both eyes (OU) 7 days prior for prophylaxis and treatment of acute primary angle-closure OD and OS, respectively. The hyphema occurred immediately after the laser iridotomy and the patient was treated conservatively. At our hospital, best corrected visual acuity (BCVA) was hand motion OU and intraocular pressure (IOP) was 52 mmHg OU. Accordingly, surgical intervention for the hyphema OU was

indicated. The preoperative blood test showed bicytopenia (hematocrit 22% and platelet 15,000/mm³). A hematologist was consulted to workup causes and preoperative evaluation. The patient was given leukocyte-depleted platelet concentrate, which raised the platelet count to 140,000/mm³ before surgery.

We performed anterior chamber washout using an irrigating Simcoe cannula OD. The blood clot was left undisturbed at the iridotomy site to prevent iatrogenic injury to the posterior structure of the iris. The hyphema completely resolved on the following day (Figure 1D). At the 2-month follow-up (Figure 1G), BCVA was 20/100 OD with nuclear sclerosis grade 2, IOP was 10 mmHg OD with three anti-glaucoma medications and gonioscopy showed 180° peripheral anterior synechiae (PAS) on the nasal and superior angles. Therefore, phacoemulsification with a 180° goniosynechialysis (GSL) was planned.

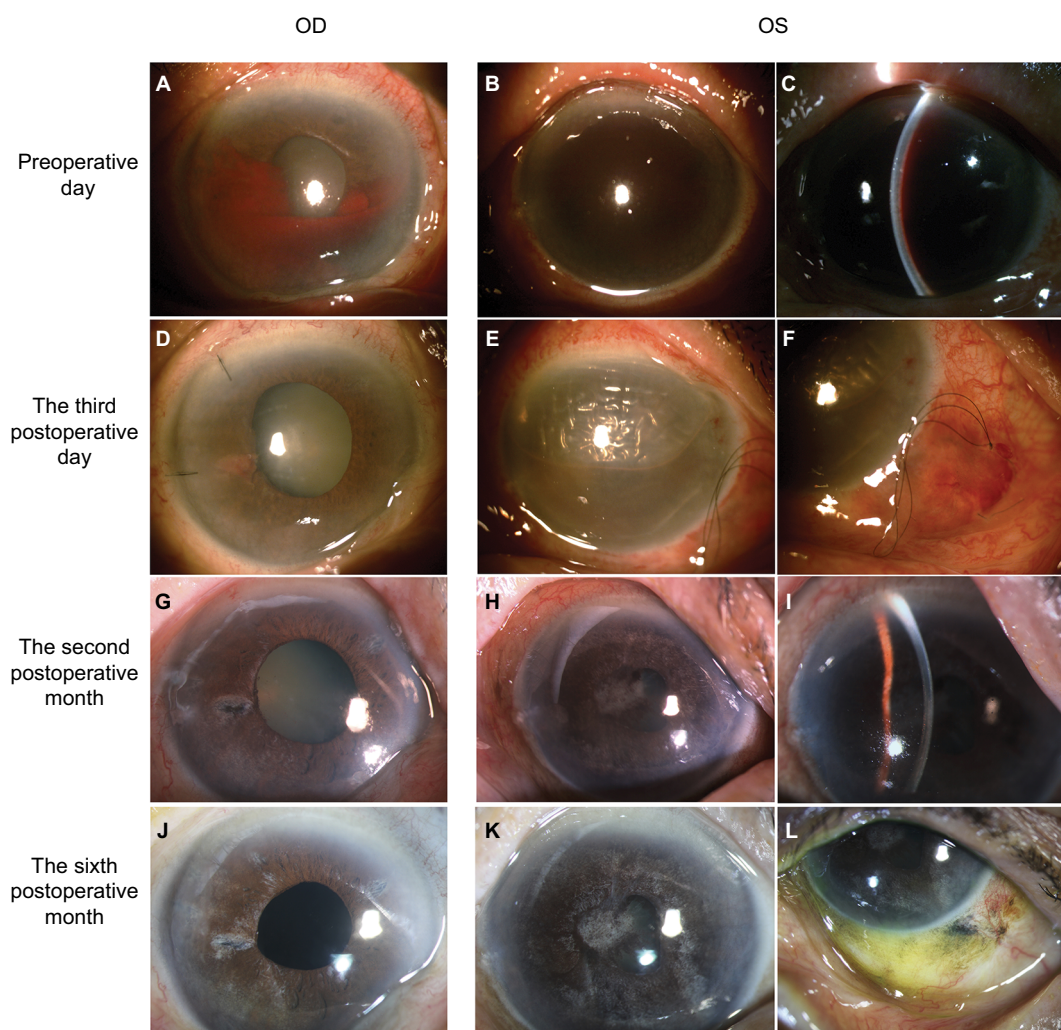


Figure 1 Slit-lamp photographs of the anterior segment OU before and after surgery.

Notes: Preoperation: (A) gross hyphema grade II OD; (B, C) eight-ball hyphema with blood-stained cornea OS. Three-day postoperation: (D–F) completely resolved hyphema OU; (E, F) the inferior blood-containing bleb with air-filled anterior chamber OS. Two-month postoperation: (G) clear anterior chamber with patent iridotomy OD; (H, I) deepened anterior chamber with resolved blood-stained cornea OS. Six-month postoperation: (J) anterior segment OD after combined phacoemulsification and 180-degree goniosynechialysis (GSL); (K) nuclear sclerosis grade 3 and inflammatory membrane obscuring the pupillary axis; (L) the nonfunctioning inferior bleb. No recurrent hyphema was found during the 6 months of follow-up.

We performed a limbal-based, inferior full-thickness trabeculectomy with intracameral air injection OS as an alternative surgical procedure. Postoperatively, the patient was placed in an upright position and given a daily intracameral air injection until the air occupied 60–80% of the anterior chamber space to prevent shallowing of the anterior chamber and to hasten blood drainage inferiorly into the bleb. The hyphema completely resolved within 3 days (Figure 1E–F). The inferior bleb did not raise with digital pressure and eventually became nonfunctional in 7 days and the IOP was 10 mmHg OS without anti-glaucoma medication. Two months later, slit-lamp biomicroscopy demonstrated a deep anterior chamber and resolved corneal blood staining (Figure 1H–I). IOP was 16 mmHg OS without anti-glaucoma medication, BCVA was 10/400 OS due to nuclear sclerosis grade 3 and inflammatory membrane obscuring the pupillary axis. Gonioscopy showed a 90° PAS OS. Therefore, phacoemulsification with intraoperative direct gonioscopy was planned.

Following bone marrow aspiration and biopsy, the patient was ultimately diagnosed with hypocellular MDS. At the 4-month follow-up, the combined phacoemulsification with 180° GSL was performed OD. At the 6-month follow-up (Figure 1J–L), BCVA was 20/50 OD and 10/400 OS. IOP was 13 mmHg OD and 15 mmHg OS without anti-glaucoma medication OU. Gonioscopy showed a 360° open anterior chamber angle after GSL OD (as shown in Figure 2) and a 270° open anterior chamber angle OS. However, the unstable medical condition of the patient caused the phacoemulsification OS to be postponed.

Discussion

Gross hyphema after laser iridotomy is a rare condition.^{1–3} To the best of our knowledge, we are reporting the first case of an eight-ball hyphema resulting from a laser iridotomy



Figure 2 Gonioscopic photographs after goniosynechialysis OD showed a 360 degree open anterior chamber angle.

in an acute primary angle-closure patient with undiagnosed hypocellular MDS. Bleeding in MDS is often related to thrombocytopenia. However, platelet dysfunction may play a role as well, despite a platelet count of greater than 80,000/mm³.^{14–16} From our perspective, surgeons should be cautious before performing a laser iridotomy in patients with a known hematological disorder and preoperative hematological assessment is warranted to reduce the risk of hyphema.

The goal of hyphema management is to accelerate the absorption of the blood and to prevent complications. Most cases can be treated conservatively by medical management. Approximately 5–7.2% of all patients with a hyphema require surgical management.⁸ Surgical management is required only if medical management fails or as a rule, when true eight-ball hyphema occurs.⁸ At presentation, our patient was indicated to surgical intervention OU based on empirical criteria proposed by Read and Goldberg.^{8,17}

We decided to perform the anterior chamber washout using an irrigating Simcoe cannula OD because the clot had already lysed. The hyphema completely resolved on the following day after surgery. BCVA was 20/100 OD with nuclear sclerosis grade 2, IOP was 10 mmHg OD with three anti-glaucoma medications and gonioscopy showed 180° PAS on the nasal and superior angles. IOP is usually elevated when >180° of the angle is closed by a PAS.¹⁸ Progressive irreversible Schlemm's canal endothelial damage and subsequent occlusion of Schlemm's canal and trabecular meshwork will eventually occur if the PAS remains untreated.¹⁹ Furthermore, combined phacoemulsification and GSL has been shown to be safe and highly effective in controlling IOP (<21 mmHg) and decreasing PAS in eyes that developed acute primary angle-closure and had persistent IOP elevation following laser treatment.²⁰ As such, we performed combined phacoemulsification and 180° GSL OD at the 4th month after presentation. At the 6-month follow-up, BCVA was 20/50 OD, IOP was 13 mmHg OD without anti-glaucoma medication and gonioscopy showed a 360° open anterior chamber angle after GSL OD.

For the left eye, we performed the limbal-based, inferior full-thickness trabeculectomy OS as an alternative treatment for an eight-ball hyphema. Since the ab interno surgical approach may put underlying anterior segment structures at risk for rebleeding and iatrogenic injury, we proceeded with the ab externo approach. To effectively drain the hyphema, full thickness sclerotomy in the inferior quadrant is required, as gravity will facilitate the draining process. We preferred a limbal-based conjunctival flap to prevent wound leakage.

After the hyphema drained into the inferior bleb, the blood will eventually clot and obstruct the sclerotomy site. So, the inferior bleb will be flat and become nonfunctioning because the filtering bleb was designed to eventually become nonfunctional as a result of blood clotting and the healing process following resolution of the hyphema. Therefore, antifibrotic agents were not administered during the procedure and no long-term bleb-related complications were a concern. In regard to endophthalmitis, one study has demonstrated that the full-thickness procedures are at an increased risk of late infection.²¹ However, a larger retrospective cohort study from 27,886 cases of partial- and full-thickness filtration surgeries showed that the endophthalmitis rate from the full-thickness procedure is slightly more than partial-thickness procedure (1% vs 0.63%) but this difference was not significant.²² With awareness of this complication, the risk of endophthalmitis was reduced by prevention of wound leakage, no administration of antifibrotic agents and no long-term functioning bleb. Postoperatively, the patient was placed in an upright position and given a daily intracameral air injection to prevent shallowing of the anterior chamber and to hasten blood drainage inferiorly into the bleb. The hyphema completely resolved within 3 days. The inferior bleb became nonfunctional within 7 days as a result of a blood clot in the inferior bleb and ostomy site. At the 2-month follow-up, the anterior chamber was deep and corneal blood staining was resolved. The patient's IOP was 16 mmHg without anti-glaucoma medication. No recurrent hyphema was found during the 6 months of follow-up.

The visual prognosis from an eight-ball hyphema remains poor but this depends on its cause and comorbidities.^{8,12} About 50% of eight-ball hyphema patients have a BCVA of less than 20/40.²³ As a result of a grade III senile cataract and inflammatory membrane obscuring the pupillary axis, the last follow-up BCVA OS was 10/400. We planned to perform phacoemulsification with intraoperative direct gonioscopy OS when the patient's medical condition was stable enough to proceed with the surgery.

Sears reported a case series of 16 patients where the ab externo approach procedure was undertaken by clot delivery from manual expression at the limbus, without instrumentation, within the anterior chamber. This was performed 4 days after the occurrence of an eight-ball hyphema.²³ The overall final BCVA from this series was superior to our case but there are several possible explanations for this discrepancy. First, our patient was older than those from the Sears study, which may account for differences in ocular comorbidities. Second, our patient had the media opacities described above.

Finally, the time interval before surgery in our case is longer than in the Sears study, so the degree of hyphema complications are different.

Conclusion

We have observed gross hyphema after laser iridotomy in a patient with hypocoellular MDS. The inferior full-thickness trabeculectomy can be considered as an alternative surgical procedure for the treatment of an eight-ball hyphema. This procedure provides rapid hyphema resolution and minimizes the risk of injury to the intraocular structures by an ab externo approach.

Ethics approval and informed consent

The study was approved by the ethics committee of Mahidol University, School of Medicine and adhered to the tenets of the Declaration of Helsinki (EC_590059). Written informed consent was obtained from the patient for publication of this case report and any accompanying images.

Acknowledgments

We thank David Dimasi, PhD, from Edanz Group (www.edanzediting.com/ac) for editing a draft of this manuscript. The authors declare that no funding was obtained for this study.

Disclosure

The authors report no conflicts of interest in this work.

References

1. Del Priore LV, Robin AL, Pollack IP. Neodymium: YAG and argon laser iridotomy. Long-term follow-up in a prospective, randomized clinical trial. *Ophthalmology*. 1988;95(9):1207–1211.
2. Moster MR, Schwartz LW, Spaeth GL, Wilson RP, McAllister JA, Poryzees EM. Laser iridectomy. A controlled study comparing argon and neodymium: YAG. *Ophthalmology*. 1986;93(1):20–24.
3. Jiang Y, Chang DS, Foster PJ, et al. Immediate changes in intraocular pressure after laser peripheral iridotomy in primary angle-closure suspects. *Ophthalmology*. 2012;119(2):283–288.
4. Kumar N, Feyi-Waboso A. Intractable secondary glaucoma from hyphema following YAG iridotomy. *Can J Ophthalmol*. 2005;40(1):85–86.
5. Hodes BL, Bentivegna JF, Weyer NJ. Hyphema complicating laser iridotomy. *Arch Ophthalmology*. 1982;100(6):924–925.
6. Drake MV. Neodymium:YAG laser iridotomy. *Survey Ophthalmol*. 1987;32(3):171–177.
7. Golan S, Levkovitch-Verbin H, Shemesh G, Kurtz S. Anterior chamber bleeding after laser peripheral iridotomy. *JAMA Ophthalmol*. 2013;131(5):626–629.
8. Bansal S, Gunasekaran DV, Ang B, et al. Controversies in the pathophysiology and management of hyphema. *Survey Ophthalmol*. 2016;61(3):297–308.
9. Leet DM. Treatment of total hyphemas with urokinase. *Am J Ophthalmol*. 1977;84(1):79–84.

10. Sholiton DB, Solomon OD. Surgical management of black ball hyphema with sodium hyaluronate. *Ophthalmic Surg.* 1981;12(11):820–822.
11. Hill K. Cryoextraction of total hyphema. *Arch Ophthalmol.* 1968;80(3):368–370.
12. Parrish R, Bernardino V, Jr. Iridectomy in the surgical management of eight-ball hyphema. *Arch Ophthalmol.* 1982;100(3):435–437.
13. Diddie KR, Dinsmore S, Murphree AL. Total hyphema evacuation by vitrectomy instrumentation. *Ophthalmology.* 1981;88(9):917–921.
14. Bryan J, Jabbour E, Prescott H, Kantarjian H. Thrombocytopenia in patients with myelodysplastic syndromes. *Semin Hematol.* 2010;47(3):274–280.
15. Manoharan A, Brighton T, Gemmell R, Lopez K, Moran S, Kyle P. Platelet dysfunction in myelodysplastic syndromes: a clinicopathological study. *Int J Hematol.* 2002;76(3):272–278.
16. Mittelman M, Zeidman A. Platelet function in the myelodysplastic syndromes. *Int J Hematol.* 2000;71(2):95–98.
17. Deutsch TA, Weinreb RN, Goldberg MF. Indications for surgical management of hyphema in patients with sickle cell trait. *Arch Ophthalmol.* 1984;102(4):566–569.
18. Campbell DG, Vela A. Modern goniosynechialysis for the treatment of synechial angle-closure glaucoma. *Ophthalmology.* 1984;91(9):1052–1060.
19. Hamanaka T, Kasahara K, Takemura T. Histopathology of the trabecular meshwork and Schlemm's canal in primary angle-closure glaucoma. *Invest Ophthalmol Vis Sci.* 2011;52(12):8849–8861.
20. Teekhasaene C, Ritch R. Combined phacoemulsification and goniosynechialysis for uncontrolled chronic angle-closure glaucoma after acute angle-closure glaucoma. *Ophthalmology.* 1999;106(4):669–674, discussion 674–675.
21. Jampel HD, Quigley HA, Kerrigan-Baumrind LA, Melia BM, Friedman D, Barron Y; Glaucoma Surgical Outcomes Study Group. Risk factors for late-onset infection following glaucoma filtration surgery. *Arch Ophthalmol.* 2001;119(7):1001–1008.
22. Coleman AL, Yu F, Greenland S. Factors associated with elevated complication rates after partial-thickness or full-thickness glaucoma surgical procedures in the United States during 1994. *Ophthalmology.* 1998;105(7):1165–1169.
23. Sears ML. Surgical management of black ball hyphema. *Trans Am Acad Ophthalmol Otolaryngol.* 1970;74(4):820–825.

International Medical Case Reports Journal

Publish your work in this journal

The International Medical Case Reports Journal is an international, peer-reviewed open-access journal publishing original case reports from all medical specialties. Previously unpublished medical posters are also accepted relating to any area of clinical or preclinical science. Submissions should not normally exceed 2,000 words or

4 published pages including figures, diagrams and references. The manuscript management system is completely online and includes a very quick and fair peer-review system, which is all easy to use. Visit <http://www.dovepress.com/testimonials.php> to read real quotes from published authors.

Submit your manuscript here: <https://www.dovepress.com/international-medical-case-reports-journal-journal>

Dovepress