

Atypical presentation of critical left main disease in an HIV-infected patient

Rajeev Seecheran¹
Valmiki Seecheran²
Sangeeta Persad²
Taarik Dookie³
Naveen Anand Seecheran¹

¹Department of Clinical Medical Sciences, University of the West Indies, St. Augustine, Trinidad and Tobago; ²Cardiovascular Services Division, North West Regional Health Authority, Mt. Hope, Trinidad and Tobago; ³Cardiology Unit, Advanced Cardiovascular Institute, Port of Spain, Trinidad and Tobago

Abstract: Coronary artery disease is currently one of the leading causes of mortality in patients with HIV. Severe left main disease (LMD) occurs in ~6% of the HIV-infected patients. We describe a case report of an atypical presentation of silent critical LMD in an HIV-infected patient who underwent a low-risk exercise stress test. The cardiovascular disease team should be vigilant for this latent phenomenon, specifically within this subpopulation despite the high Duke treadmill score.

Keywords: left main disease, left main lesion, left main stenosis, human immunodeficiency virus, HIV

Key clinical message

Clinicians must be cognizant that patients with atypical chest pain infected with HIV may have silent critical left main coronary artery disease (CAD) despite being stratified as low risk after exercise stress test.

Introduction

CAD is currently one of the leading causes of mortality in patients with HIV. This is primarily attributed to their comparably increased life expectancy, antiretroviral induced metabolic derangements, and the lentivirus itself.^{1,2} The pathophysiology involves a complex milieu combining direct endothelial injury and dysfunction and hypercoagulability along with a significant contribution from traditional cardiac risk factors.³⁻⁵

Severe left main disease (LMD) occurs in ~3%–7% of overall patients undergoing index coronary angiography, and if treated with conservative medical management, a 3-year mortality rate of 50% was found.^{6,7} In the HIV-infected subpopulation, the prevalence is ~6% as demonstrated in the studies by Escout et al⁸ and Mehta and Khan⁹.

Accruing epidemiologic data on asymptomatic LMD with silent myocardial ischemia is difficult; however, sudden cardiac death and autopsy studies suggest that this entity is relatively common.¹⁰

We describe a case report of silent critical LMD in an HIV-infected patient who was stratified as low risk according to the Duke treadmill score (DTS) of 12 after exercise stress test.

Correspondence: Naveen Anand Seecheran

Department of Clinical Medical Sciences,
Faculty of Medical Sciences, University of
the West Indies, 2nd Floor, Building #67,
Eric Williams Medical Sciences Complex,
Mt. Hope, Trinidad and Tobago
Tel/fax +868 663 4332
PBX +868 645 3232x2926
Email NSeecheran@gmail.com

Case report

Recently, a 56-year-old Caucasian gentleman with a medical history of HIV infection for 10 years, undergoing antiretroviral therapy (ART) including efavirenz, emtricitabine, and tenofovir, initially presented to the outpatient cardiology clinic for atypical, noncardiac chest pain. His physical examination and vital signs were unremarkable. A 12-lead electrocardiogram (ECG) revealed sinus rhythm with no acute ischemic changes. Recent pertinent laboratory investigations included the following: a normal complete blood count, comprehensive metabolic panel, lipid panel, inflammatory markers such as erythrocyte sedimentation rate and C-reactive protein, glycosylated hemoglobin (HbA_{1c}), cluster of differentiation 4 (CD4) count of 860 cells/mm³ (normal range, 500–1,500 cells/mm³), and undetectable HIV RNA levels (<20 RNA copies/μL). His cardiac troponin T was normal at 0.028 ng×mL⁻¹ (normal range, 0–0.1 ng×mL⁻¹) and did not reflect a myocardial infarction. He was subsequently risk stratified according to Bruce protocol exercise treadmill test, during which he did not report any anginal episodes and achieved 12 minutes and 23 seconds of exercise time with 13.2 metabolic equivalents (METs) and no significant ST-segment deviation. His DTS was calculated at 12, which is considered a low risk for cardiovascular events (Figure 1A–C).¹¹

The patient returned the following fortnight due to persistent atypical chest pain, and as a result, he was hospitalized for further management. Once again, ECGs and cardiac biomarkers of the patient were unremarkable. He was then proceeded to inpatient coronary angiography. Cardiac catheterization revealed an eccentric, critical mid-left main lesion with 90% stenosis (American College of Cardiology/American Heart Association [ACC/AHA] type C) with a diffuse, proximal left anterior descending artery (LAD) stenosis (Figure 2A–C). The left main lesion was unable to be further characterized with intravascular ultrasound or optical coherence tomography due to the unavailability of these imaging modalities. He remained hospitalized and subsequently underwent successful double coronary artery bypass grafting (CABG) the following day without complications. The patient was then safely discharged following his uneventful postoperative recovery on guideline-directed medical therapy which included aspirin 81 mg, clopidogrel 75 mg, lisinopril 2.5 mg, carvedilol 3.125 mg twice daily, spironolactone 12.5 mg, and pravastatin 20 mg in addition to his maintenance ART.

All procedures performed in studies involving human participants were in accordance with the ethical standards of the institutional and/or national research committee and

the 1964 Declaration of Helsinki and its later amendments or comparable ethical standards. The patient has provided written informed consent to have the details of his case published.

Discussion

Although the patient reported atypical chest pain, his symptoms were not considered to be related to the discovery of his severe left main coronary artery (LMCA) lesion, and thus, were initially considered noncardiac in nature. The mechanisms for the atypical presentation with a high DTS (>12) despite having severe LMD remain unclear. Possible reasons include ART-induced neuropathy which may have masked definitive typical angina or its equivalent along with an HIV-associated neuropathy despite the patient being well controlled as evidenced by his CD4 count and undetectable viral load. There was also no significant coronary collateral circulation present which could attenuate any classical symptoms.¹² To the authors' knowledge, this is the reported first-in-human case of illustrating the phenomenon of an oligosymptomatic left main lesion in an HIV-infected patient who underwent a low-risk exercise treadmill test.

Generally, HIV-infected patients have a significantly higher risk of developing acute coronary syndromes (ACSs).¹³ This is in part due to a thrombophilic phenomenon which is attributed to various cellular and plasmatic factors, including decreased levels of natural anticoagulants, increased levels of plasminogen activator inhibitor-1, activated protein C resistance, and platelet reactivity.¹⁴ The patient proceeded to angiography based on the discordance between the atypical symptoms and a low-risk exercise stress test (DTS>12) despite the growing evidence that achieving ≥10 METs with a negative stress ECG resulted in 94% sensitivity and 97% negative predictive value in identifying high-risk CAD.¹⁵

The prevalence of significant LMD appears to be 6%, which is equivalent to a non-HIV-infected cohort.^{8,9} Coronary anatomy seems to be variable, with some studies showing a higher prevalence of single-vessel disease and others multi-vessel disease.¹⁶

CABG has long been considered as the gold standard treatment of unprotected LMCA disease. Currently, there is a dearth of studies with respect to surgical revascularization in HIV-infected patients.^{17,18} These surmised that both short- and long-term outcomes are similar to their noninfected counterparts with respect to cardiovascular mortality and prognosis.

With the advent of drug-eluting stents (DESs), together with advances in adjunctive pharmacotherapies, percutaneous coronary intervention (PCI) is also a feasible revascularization strategy for patients with unprotected LMCA

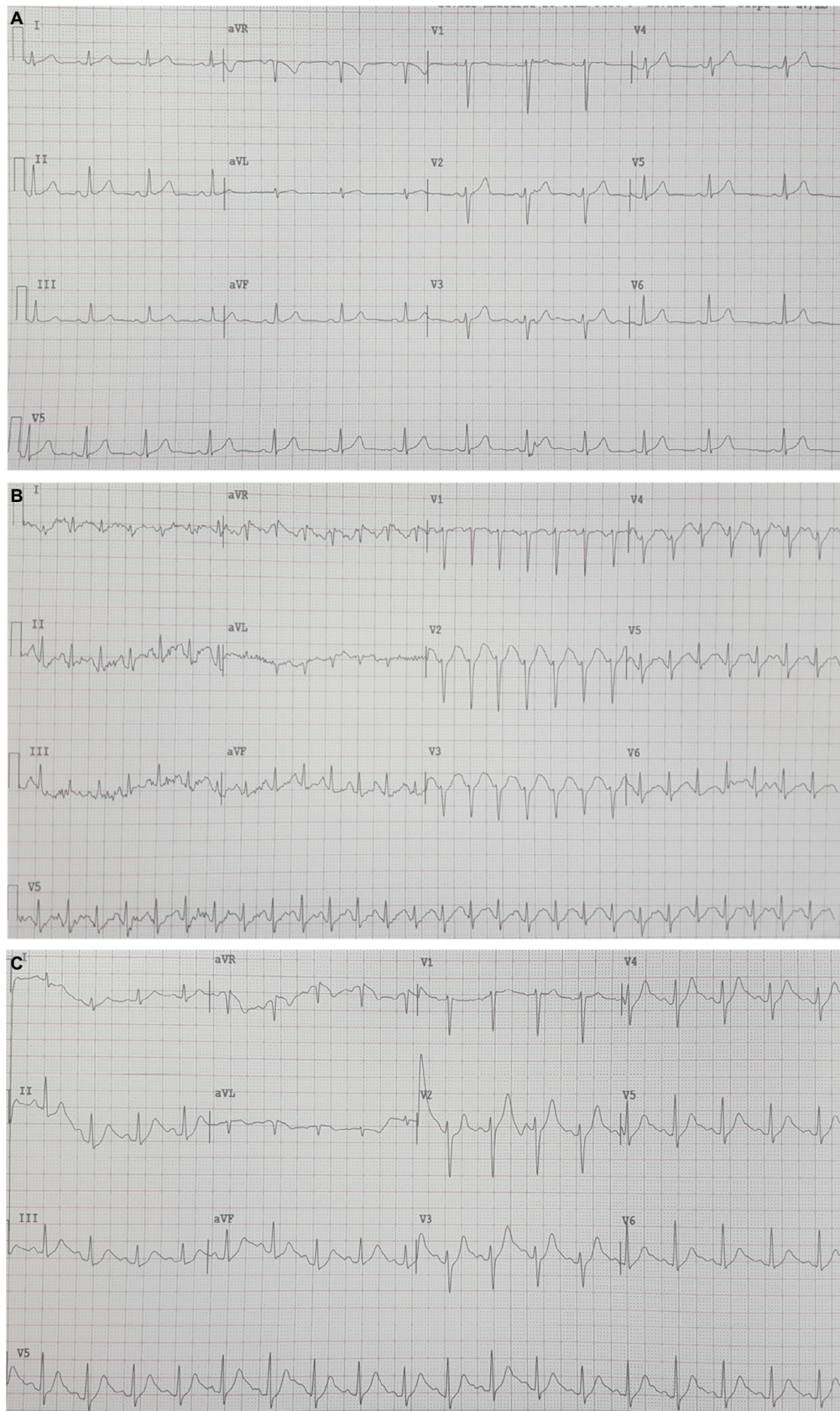


Figure 1 Exercise stress ECGs.

Notes: (A) The patient's baseline ECG. (B) The patient's ECG at peak stress (Bruce protocol) with no acute dynamic changes consistent with ischemia or infarction. (C) The patient's ECG during recovery after exercise treadmill stress test with no ischemic changes.

Abbreviation: ECG, electrocardiogram.

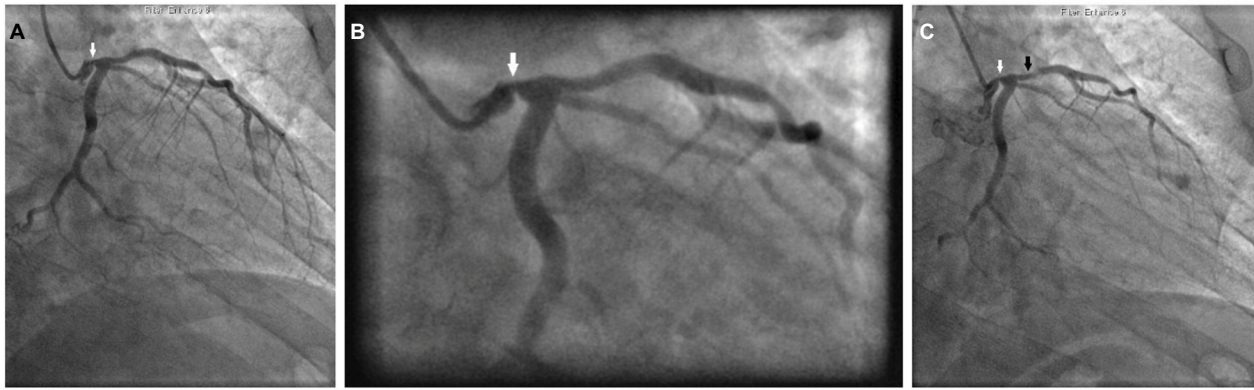


Figure 2 Left coronary artery angiography.

Notes: (A) The white arrow indicates the mid-LMCA 90% stenosis. (B) The white arrow indicates the mid-LMCA 90% stenosis. (C) The white arrow indicates the mid-LMCA 90% stenosis and the black arrow indicates the proximal, diffuse left anterior descending artery 50% stenosis.

Abbreviation: LMCA, left main coronary artery.

stenosis.^{19,20} PCI in HIV-infected patients has been associated with a higher incidence of nonfatal reinfarction, restenosis, and in-stent thrombosis requiring repeat revascularization.^{16,21,22} It has also been demonstrated that DESs display equivalent safety and efficacy in the HIV-infected population as in the general population.^{23–25}

Conclusion

We describe a case report of an atypical presentation of silent critical LMD in an HIV-infected patient who underwent a low-risk exercise stress test. The cardiovascular disease team should be vigilant for this latent phenomenon, specifically within this subpopulation despite the high DTS and markedly above normal functional capacity. Although CABG remains the gold standard of care for the management of LMD, drug-eluting PCI remains a viable option with streamlined procedural techniques, cutting edge devices, and novel adjunctive pharmacology.

Acknowledgment

There was no funding for this case report.

Author contributions

All authors contributed toward data analysis, drafting and revising the paper and agree to be accountable for all aspects of the work.

Disclosure

The authors report no conflicts of interest in this work.

References

1. Worm SW, De Wit S, Weber R, et al. Diabetes mellitus, preexisting coronary heart disease, and the risk of subsequent coronary heart disease events in patients infected with human immunodeficiency virus: the data collection on adverse events of anti-HIV drugs (D:A:D study). *Circulation*. 2009;119(6):805–811.
2. Worm SW, Sabin C, Weber R, et al. Risk of myocardial infarction in patients with HIV infection exposed to specific individual antiretroviral drugs from the 3 major drug classes: the data collection on adverse events of anti-HIV drugs (D:A:D) study. *J Infect Dis*. 2010;201(3):318–330.
3. Matetzky S, Domingo M, Kar S, et al. Acute myocardial infarction in human immunodeficiency virus-infected patients. *Arch Intern Med*. 2003;163(4):457–460.
4. Boccara F, Mary-Krause M, Teiger E, et al. Acute coronary syndrome in human immunodeficiency virus-infected patients: characteristics and 1 year prognosis. *Eur Heart J*. 2011;32(1):41–50.
5. Seecheran VK, Giddings SL, Seecheran NA. Acute coronary syndromes in patients with HIV. *Coron Artery Dis*. 2017;28(2):166–172.
6. Cohen MV, Gorlin R. Main left coronary artery disease. Clinical experience from 1964–1974. *Circulation*. 1975;52(2):275–285.
7. Soleimani A, Abbasi A, Kazzazi EH, et al. Prevalence of left main coronary artery disease among patients with ischemic heart disease: insights from the Tehran Angiography Registry. *Minerva Cardioangiol*. 2009;57(2):175–183.
8. Escaut L, Monsuez JJ, Chironi G, et al. Coronary artery disease in HIV infected patients. *Intensive Care Med*. 2003;29(6):969–973.
9. Mehta NJ, Khan IA. HIV-associated coronary artery disease. *Angiology*. 2003;54(3):269–275.
10. Shawl FA, Chun PK, Mutter ML, et al. Asymptomatic left main coronary artery disease and silent myocardial ischemia. *Am Heart J*. 1989;117(3):537–542.
11. Shaw LJ, Peterson ED, Shaw LK, et al. Use of a prognostic treadmill score in identifying diagnostic coronary disease subgroups. *Circulation*. 1998;98(16):1622–1630.
12. Meier P, Schirmer SH, Lansky AJ, Timmis A, Pitt B, Seiler C. The collateral circulation of the heart. *BMC Med*. 2013;11:143.
13. Freiberg MS, Chang C-CH, Kuller LH, et al. HIV infection and the risk of acute myocardial infarction. *JAMA Intern Med*. 2013;173(8):614–622.
14. Ener RA, Palermo J, O’Murchu B, Burke JA, Wolf NM, Van Decker WA. HIV disease in thrombocardiopathy. *J Invasive Cardiol*. 2007;19(5):235–239.

15. Löffler AI, Perez MV, Nketiah EO, Bourque JM, Keeley EC. Usefulness of achieving ≥ 10 METs with a negative stress electrocardiogram to screen for high-risk obstructive coronary artery disease in patients referred for coronary angiography after exercise stress testing. *Am J Cardiol.* 2017;121(3):289–293.
16. Boccara F, Mary-Krause M, Teiger E, et al. 012 Acute coronary syndrome in HIV-infected patients: characteristics and prognosis. *Arch Cardiovasc Dis Suppl.* 2011;3(1):4.
17. Filsoufi F, Salzberg SP, von Harbou KTJ, Neibart E, Adams DH. Excellent outcomes of cardiac surgery in patients infected with HIV in the current era. *Clin Infect Dis.* 2006;43(4):532–536.
18. Boccara F, Cohen A, Angelantonio E, et al. Coronary artery bypass graft in HIV-infected patients: a multicenter case control study. *Curr HIV Res.* 2008;6(1):59–64.
19. Fajadet J, Chieffo A. Current management of left main coronary artery disease. *Eur Heart J.* 2012;33(1):36b–50b.
20. Dash D. Stenting of left main coronary artery stenosis: A to Z. *Heart Asia.* 2013;5(1):18–27.
21. Mestres CA, Chuquiure JE, Claramonte X, et al. Long-term results after cardiac surgery in patients infected with the human immunodeficiency virus type-1 (HIV-1). *Eur J Cardiothorac Surg.* 2003;23(6):1007–1016; discussion 1016.
22. Boccara F, Ederhy S, Janower S, Benyounes N, Odi G, Cohen A. Clinical characteristics and mid-term prognosis of acute coronary syndrome in HIV-infected patients on antiretroviral therapy. *HIV Med.* 2005;6(4):240–244.
23. Ren X, Trilesskaya M, Kwan DM, Nguyen K, Shaw RE, Hui PY. Comparison of outcomes using bare metal versus drug-eluting stents in coronary artery disease patients with and without human immunodeficiency virus infection. *Am J Cardiol.* 2009;104(2):216–222.
24. Serruys PW, Morice M-C, Kappetein AP, et al. Percutaneous coronary intervention versus coronary-artery bypass grafting for severe coronary artery disease. *N Engl J Med.* 2009;360(10):961–972.
25. Christiansen EH, Mäkikallio T, Holm NR. Everolimus-eluting stents or bypass surgery for left main coronary disease. *N Engl J Med.* 2017;376(11):1087–1089.

International Medical Case Reports Journal

Publish your work in this journal

The International Medical Case Reports Journal is an international, peer-reviewed open-access journal publishing original case reports from all medical specialties. Previously unpublished medical posters are also accepted relating to any area of clinical or preclinical science. Submissions should not normally exceed 2,000 words or

4 published pages including figures, diagrams and references. The manuscript management system is completely online and includes a very quick and fair peer-review system, which is all easy to use. Visit <http://www.dovepress.com/testimonials.php> to read real quotes from published authors.

Submit your manuscript here: <https://www.dovepress.com/international-medical-case-reports-journal-journal>

Dovepress