

Efficacy and safety of ranibizumab monotherapy versus ranibizumab in combination with verteporfin photodynamic therapy in patients with polypoidal choroidal vasculopathy: 12-month outcomes in the Japanese cohort of EVEREST II study

Kanji Takahashi,¹ Masahito Ohji,² Hiroko Terasaki,³ Shigeru Honda,⁴ Philippe Margaron,⁵ Tadhg Guerin,⁶ Mitsuko Yuzawa,⁷

On behalf of the EVEREST II Japanese investigators

¹Department of Ophthalmology, Kansai Medical University, Osaka, Japan; ²Department of Ophthalmology, Shiga University of Medical Science, Otsu, Japan; ³Department of Ophthalmology, Nagoya University Graduate School of Medicine, Nagoya, Japan; ⁴Division of Ophthalmology, Department of Surgery, Kobe University Graduate School of Medicine, Kobe, Japan; ⁵Department of Ophthalmology, Novartis Pharma AG, Basel, Switzerland; ⁶Department of Ophthalmology, Novartis Ireland Limited, Dublin, Ireland; ⁷Division of Ophthalmology, Department of Visual Sciences, Nihon University School of Medicine, Tokyo, Japan

Correspondence: Kanji Takahashi
Department of Ophthalmology,
Kansai Medical University, 3-1
Shinmachi 2 Chome, Hirakata City,
Osaka 573-1191, Japan
Tel +81 72 804 0101
Email takahask@hirakata.kmu.ac.jp

Purpose: To compare the efficacy and safety of ranibizumab 0.5 mg with or without verteporfin photodynamic therapy in Japanese patients with polypoidal choroidal vasculopathy over 12 months.

Study design: EVEREST II was a 24-month, Phase IV, multicenter, randomized, double-masked study in Asian patients with symptomatic macular polypoidal choroidal vasculopathy.

Methods: Of the 322 enrolled patients, 84 patients, including 46 patients who received ranibizumab + verteporfin photodynamic therapy (combination therapy arm) and 38 patients who received ranibizumab/sham PDT (monotherapy arm), were Japanese who were evaluated in this subanalysis. Mean change in best-corrected visual acuity (BCVA) and complete polyp regression at Month 12, ranibizumab treatment exposure, and safety over 12 months were assessed.

Results: Baseline demographics were well balanced between the arms. At Month 12, mean change in BCVA letter score was +8.5 with combination therapy versus +6.4 with monotherapy. Complete polyp regression was higher with combination therapy than with monotherapy at Month 12 (70.5% vs 27.3%). Over 12 months, patients in the combination arm received a median of 4.0 ranibizumab injections vs 7.0 in the monotherapy arm. Serious adverse events were generally low in both arms, and retinal hemorrhage, an adverse event, was reported in one patient (2.2%).

Conclusion: The results from the Japanese cohort were in agreement with the EVEREST II study. Combination therapy was effective in improving BCVA and achieving a higher rate of complete polyp regression with a lower number of ranibizumab injections than monotherapy. No new safety signals were reported, and safety events were comparable between both arms over 12 months.

Keywords: Japanese, polypoidal choroidal vasculopathy, ranibizumab, neovascular age-related macular degeneration, verteporfin photodynamic therapy

Plain language summary

The EVEREST II study was a 24-month multicenter clinical trial of 322 patients diagnosed with polypoidal choroidal vasculopathy (PCV) from 42 sites across Asia. EVEREST II is one of the first studies to enroll a large number of patients across 22 sites in Japan. The present study is

specific to the 12-month outcomes observed in the Japanese cohort of the EVEREST II study.

For management of PCV in patients with 20/32 or more Snellen equivalent, Japanese guidelines recommend anti-vascular endothelial growth factor (VEGF) monotherapy over verteporfin photodynamic therapy (vPDT) due to the complications associated with vPDT. Prof Takahashi, on behalf of the EVEREST II study investigators, report that combination therapy (ranibizumab 0.5 mg + vPDT) was more effective in improving vision without any risk of complications when compared with ranibizumab 0.5 mg alone.

The study also addresses one of the pressing issue of effectively utilizing limited medical resources to reduce the overall treatment burden. This has become a critical issue especially in Japan, where the elderly population is on rise, which creates an additional burden on their national public insurance system. The present 12-month findings confirmed that combination therapy involved fewer anti-VEGF injections while still providing improved treatment outcomes than ranibizumab monotherapy. Therefore, combination therapy could be considered as a first-line therapy for treatment of PCV in Japan, as well as in other countries worldwide.

Prof Takahashi et al strongly believe that the importance of these 12-month findings be communicated as it could guide physicians and health authorities in evolving and improving the current Japanese treatment guidelines of PCV.

Introduction

Polypoidal choroidal vasculopathy (PCV), generally recognized as a subtype of neovascular age-related macular degeneration (nAMD), is an exudative retinal disease characterized by a branching vascular network (BVN) with polypoidal lesions under the retinal pigment epithelium (RPE).^{1,2} Although the pathogenesis of PCV is still unclear, histopathological evidence suggests that PCV is a variant of type I or occult choroidal neovascularization observed in nAMD, located above or within the Bruch's membrane.¹⁻⁴ However, evidence from recent genetic studies indicated a plausible difference in the genetic background between nAMD and PCV.⁵⁻⁸ Besides, PCV often shows several unique clinical manifestations that are seemingly different from typical nAMD.⁸ Indocyanine green angiography (ICGA) is an important tool for accurate diagnosis of PCV. Polyps can be visualized using ICGA, with or without abnormal BVN in the choroid.^{1,8,9} These features are associated with serous exudation and hemorrhage that may lead to detachment of the RPE and sometimes the retina, which causes vision deterioration.^{1,10} The current treatment strategies for PCV offer good short-term visual outcomes but poorer longer-term outcomes; therefore, the optimal treatment option for PCV remains elusive.^{9,11} Moreover, the long-term prognosis of PCV is poor if left untreated.⁹

The proportion of patients with nAMD is increasing in Japan.¹²⁻¹⁴ Studies have shown that the Japanese have the highest prevalence of PCV in nAMD (22.3%–54.7%) when compared with Taiwanese (49%), Chinese (22.3%–24.5%), Koreans (22.2%–24.6%), and Caucasians (8%–13%).^{8,15-18} These reported accounts could also be an underestimation of PCV as there might be a significant number of asymptomatic patients with PCV in a regressed or quiescent stage in these populations.

A retrospective, open-label, multicenter, uncontrolled study in 471 eyes of 469 Japanese patients demonstrated that vPDT was effective in maintaining visual acuity (VA) over 12 months for all types of nAMD lesions. Furthermore, a significant improvement in VA was observed for eyes with PCV compared with those without ($P < 0.001$).¹⁹ The results from other reports have also shown a high regression rate of polyps after vPDT.^{20,21} However, there are concerns regarding visual outcomes after vPDT administration, especially in eyes with good starting vision. Potential complications of vPDT include acute vision loss caused by subretinal hemorrhage, RPE tears, and progressive RPE atrophy.⁹ While the Japanese Guidelines of nAMD recommends vPDT, anti-VEGF agents, or anti-VEGF agents in combination with vPDT for effective PCV management,²² the guidelines do not recommend vPDT for treating PCV patients with VA $>20/40$ (Snellen equivalent) due to the concerns of risks for complication of vPDT.¹⁹⁻²²

Recently, the EVEREST II study results showed that the ranibizumab 0.5 mg plus vPDT combination arm achieved superior best-corrected visual acuity (BCVA) gains (8.3 vs 5.1 letters, respectively; $P = 0.01$), along with superior anatomical outcomes, including higher polyp regression rate (69.3% vs 34.7%, respectively; $P < 0.001$) at Month 12, and higher proportion with absence of disease activity (79.5% vs 50.0%, respectively) at Month 11 compared with ranibizumab monotherapy.²¹ Over 12 months, the combination arm also required fewer injections compared with the monotherapy arm (mean of 5.2 vs 7.3 injections), with 50.6% of patients in the combination arm requiring only three to four injections over 12 months, almost twice as many as in the monotherapy arm (26.2%).²¹

There is a pressing need for an optimum treatment strategy in Japan and other Asian countries to better manage patients with symptomatic macular PCV. Combination therapy has been reported to be effective in improving functional and anatomical outcomes in PCV patients; however, only limited evidence of its safety and effectiveness is available in Japan. Therefore, we present an exploratory

analysis of the EVEREST II study to compare the efficacy and safety of ranibizumab with vPDT combination therapy vs ranibizumab monotherapy in the Japanese cohort over the first 12 months.

Methods

Study design

The EVEREST II study was a Phase IV, multicenter, randomized, double-masked study designed to compare the long-term efficacy and safety of ranibizumab 0.5 mg with or without vPDT in patients with symptomatic macular PCV over 24 months.²¹ Out of the 42 sites in Asia, 22 sites in Japan participated in the study.²¹ The study began in August 2013 and was completed in March 2017.

The study followed the Declaration of Helsinki and Tripartite International Council on Harmonization Good Clinical Practice Guidelines and applicable local regulations. An independent ethics committee or institutional review board at each center reviewed and approved the study protocol. Written informed consent was provided by all participants. The study is registered with ClinicalTrials.gov as NCT01846273. The trial protocol and statistical analysis plan were published as previously described.²¹

Participants

The EVEREST II study included adult treatment-naïve patients (aged ≥ 18 years) with symptomatic macular PCV, as defined by the presence of active macular polypoidal

lesions on ICGA and by the presence of serosanguinous maculopathy on color fundus (CF) photography and fluorescein angiography. The Central Reading Center (Fundus Image Reading Centre, Singapore) confirmed the presence of PCV in one study eye and eligibility for enrolment,²¹ using a standardized reading protocol using well-defined grading criteria as the EVEREST study.²⁰ The BCVA letter score range needed for eligibility was between 78 and 24 letters (approximately 20/32 to 20/320 Snellen equivalent), measured with the help of Early Treatment Diabetic Retinopathy Study VA charts at 4 m following refraction. Inclusion and exclusion criteria are provided in more detail in previous publication.²¹

Randomization and treatment

Randomization has been described in detail previously.²¹ All enrolled patients were randomized 1:1 to receive either ranibizumab 0.5 mg plus vPDT (combination therapy) or ranibizumab 0.5 mg monotherapy with sham PDT. The randomization was balanced by site. In this exploratory analysis of EVEREST II, Japanese patients who self-identified themselves having Japanese ethnicity were included from the total participants' list.

Patients were administered intravitreal ranibizumab 0.5 mg on Day 1 (baseline visit) and at Months 1 and 2, followed by pro re nata (PRN; as needed) regimen according to the protocol-specific retreatment criteria (with an interval of at least 1 month between the two ranibizumab injections, as shown in Figure 1).

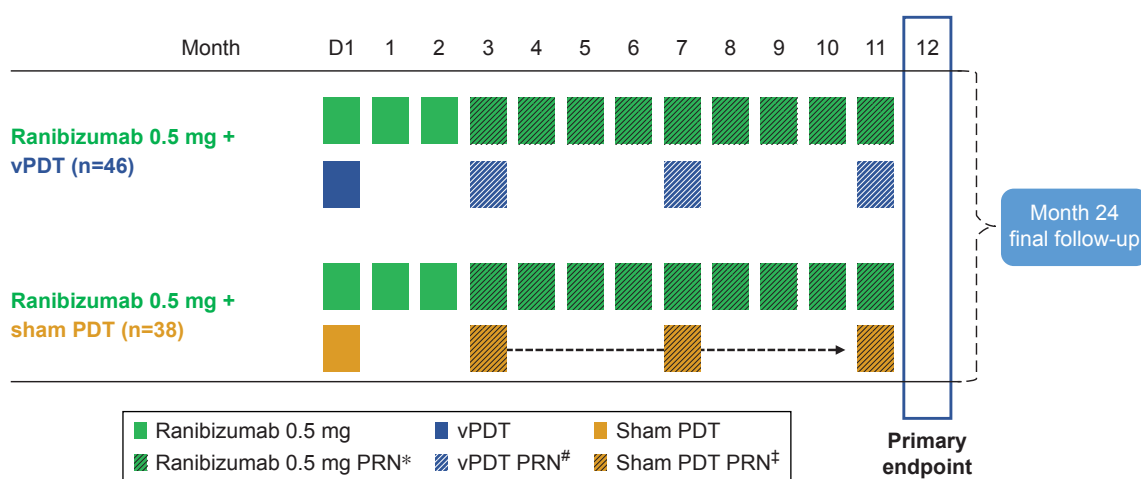


Figure 1 Study design and treatment schedule.

Notes: Included Japanese patients. *Ranibizumab was administered PRN as per protocol-specific retreatment criteria if there was a BCVA loss or presence of disease activity as seen in OCT. #vPDT/sham PDT‡ was administered PRN as per protocol-specific retreatment criteria based on presence of active polyp(s) on ICGA with a minimum interval between two PDT treatments of at least 3 months. The interval between two ranibizumab treatments was at least 28 days.

Abbreviations: BCVA, best-corrected visual acuity; D, Day; ICGA, indocyanine green angiography; OCT, optical coherence tomography; PRN, pro re nata; vPDT, verteporfin photodynamic therapy.

On Day 1, all patients were treated with vPDT or sham PDT (details have been published previously).²¹ The vPDT or sham PDT was thereafter administered on a PRN basis from Month 3 to Month 11, as per the protocol-specific retreatment criteria (with intervals between two vPDT or sham PDT treatment of at least 3 months, provided in Supplementary material S2).

Study objectives

The objectives presented here are specific to the Japanese cohort of the global EVEREST II study. The efficacy and safety of combination therapy and ranibizumab monotherapy were evaluated in this subset of patients with symptomatic macular PCV with respect to: mean change in BCVA (letters) from baseline at Month 12; proportion of patients with BCVA ≥ 69 letters at Month 12; complete polyp regression as assessed by ICGA at Month 12; mean change in BCVA over 12 months; the proportion of patients with complete polyp regression (assessed by ICGA) at Months 3, 6, and 12; the changes in central subfield thickness (CSFT) from baseline at Month 12; the number of ranibizumab injections and vPDT treatment received in the study eye prior to Month 12; and safety of both treatments up to Month 12.

Efficacy assessments

Both functional (BCVA) and anatomical evaluations (ICGA, CF, and spectral-domain optical coherence tomography [SD-OCT]) of the study eye were used for efficacy assessments.²¹ Disease activity was assessed based on BCVA loss, SD-OCT, ICGA, and CF anomalies.²¹

Safety assessments

Safety was assessed at every visit based on frequency and severity of adverse events (AEs) and serious AEs (SAEs), including vital signs and ophthalmic examinations, over 12 months.

Statistical analysis

In this exploratory analysis of a subgroup of patients from EVEREST II, for which the study was not powered, only descriptive analyses were performed. To be consistent and to compare with the global results, the change in BCVA from baseline in the study eye at Month 12 was assessed using the full analysis set (FAS) with the last observation carried forward approach for imputing missing data, as previously described.²¹ The FAS comprised all participants who were assigned to a treatment regimen. The other analyses were conducted using the FAS and were performed with no

imputation of missing data. Safety and treatment exposure were analyzed using the safety set, which comprised all patients who received at least one administration of study drug and had a safety assessment.

Informed consent

Informed consent for publication was obtained from the subjects before examination. All authors have seen the manuscript and approved to publish it in the journal.

Ethics approval

The study was conducted in accordance with the Declaration of Helsinki and Tripartite International Council on Harmonization Good Clinical Practice Guidelines and applicable local regulations. The study protocol was reviewed and approved by an independent ethics committee or institutional review board at each center. All participants provided written informed consent. The study is registered with [ClinicalTrials.gov](https://clinicaltrials.gov) as NCT01846273. Study sites – IRB ethics committee: Kansai Medical University Hirakata Hospital (Study site and IRB); Osaka City University Hospital (Study site and IRB); The University of Tokyo Hospital (Study site and IRB); Nagoya University Hospital (Study site and IRB); Shiga University of Medical Science Hospital (Study site and IRB); Fukushima Medical University Hospital (Study site and IRB); Gunma University Hospital (Study site and IRB); Kyoto University Hospital (Study site and IRB); Kyushu University Hospital (Study site and IRB); Nihon University Hospital (Study site and IRB); Kyorin University Hospital (Study site and IRB); Tokyo Women's Medical University Hospital (Study site and IRB); Chiba University Hospital (Study site and IRB); Okayama University Hospital (Study site and IRB); Hyogo Prefectural Amagasaki General Medical Center (Study site and IRB); Tane Memorial Eye Hospital (Study site) and Kikkokai (IRB); Miyake Eye Hospital (Study site) and Nagoya Medical Association (First IRB); Kobe University Hospital (Study site and IRB); Mie University Hospital (Study site); Tokyo Medical University Ibaraki Medical center (Study site and IRB); Kagawa University Hospital (Study site and IRB); and Kobe City Medical Center General Hospital (Study site and IRB).

Results

Patient disposition and baseline characteristics

Of the 322 patients diagnosed with PCV and randomized in the EVEREST II study,²¹ 84 Japanese patients were enrolled including 46 patients in the combination therapy

arm and 38 patients in the ranibizumab monotherapy arm. Overall, 91.7% of patients (combination arm, n=44; monotherapy arm, n=33) completed the first 12 months of the study (Figure 2). Two patients (4.3%) in the combination arm and five patients (13.2%) in the monotherapy arm discontinued the study prior to Month 12; the most common reasons for treatment discontinuation were AEs (4.8%) and consent withdrawal (1.2%; Figure 2). The baseline demographics and ocular characteristics were well balanced between the two arms (Table 1). At baseline, the mean (SD) ages in the combination and monotherapy arms were 72.9 (7.35) and 72.9 (7.46) years, respectively, and the majority of patients were male (78.6%). The majority of patients in both arms had “occult with no classic component” lesion at baseline (Table 1). No patients in both arms were graded with “100% classic” lesion, while one patient (2.2%) in the combination arm had a “predominantly classic” lesion (Table 1).

The mean baseline BCVA for the Japanese cohort was slightly numerically higher in the combination arm than in the monotherapy arm (combination therapy, 64.3 letters and monotherapy, 61.6 letters). In the combination arm at baseline, 26.1% of patients presented with good vision, ≥ 74 letters (20/32 in Snellen equivalent), vs 18.4% in the monotherapy arm (Table 1). Other baseline characteristics

such as CSFT (combination therapy, 404.1 μm and monotherapy, 411.3 μm) and greatest linear dimension (GLD) of the lesion, including both polyps and interconnecting BVN (combination therapy, 2,193.5 μm and monotherapy, 2,362.6 μm), were comparable between both treatment arms and were also similar to those of the whole EVEREST II study population.²¹

Efficacy outcomes

At Month 12, the mean change in BCVA (SD) from baseline was +8.5 (11.14) letters in the combination therapy arm versus +6.4 (9.82) letters in the monotherapy arm for the Japanese cohort (Figure 3A), which was similar to the results from the overall population.²¹

The proportion of patients with BCVA of ≥ 69 letters (approximately 20/40 Snellen equivalent) increased from 41.3% at baseline to 75.0% at Month 12 in the combination arm and from 32.4% at baseline to 56.3% at Month 12 in the monotherapy arm (Figure 3B).

At Month 12, the complete polyp regression rate, assessed by ICGA, was higher in the combination arm than in the monotherapy arm (70.5% vs 27.3%; Figure 4). Similarly, the mean change in CSFT (SD) from baseline at Month 12 was also numerically higher in the combination arm than in the monotherapy arm (−147.1 [119.88] μm vs −124.9 [115.41] μm).

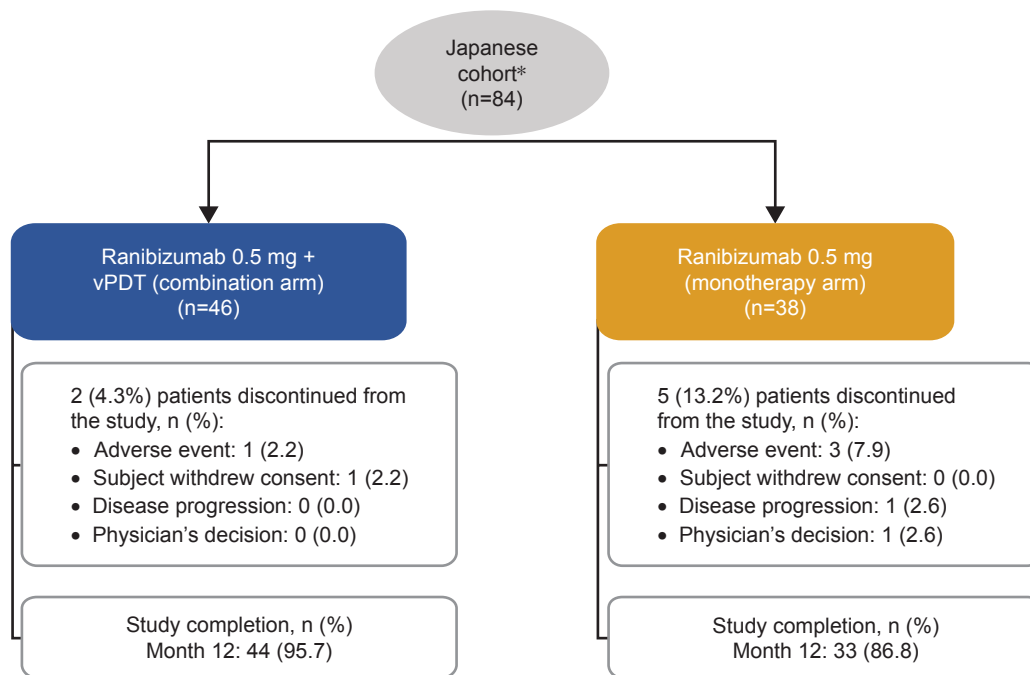


Figure 2 Randomization and patient disposition in the Japanese cohort.

Notes: *Of the 322 patients who were randomized 1:1 in the EVEREST II study, 84 patients identified themselves as belonging to the Japanese ethnicity. Percentages are based on the total number of patients in the randomized set in the respective treatment arm.

Abbreviation: vPDT, verteporfin photodynamic therapy.

Table 1 Patient demographics, baseline disease, and ocular characteristics (randomized set)

Characteristics	Japanese cohort	
	Ranibizumab 0.5 mg + vPDT (n=46)	Ranibizumab 0.5 mg (n=38)
Age, mean (SD), years	72.9 (7.4)	72.9 (7.5)
Gender, male, n (%)	38 (82.6)	28 (73.7)
BCVA, mean (SD), letters	64.3 (11.3)	61.6 (11.6)
BCVA category, n (%)		
<39	1 (2.2)	1 (2.6)
39 to <54	8 (17.4)	8 (21.1)
54 to <74	25 (54.3)	21 (55.3)
≥74	12 (26.1)	7 (18.4)
Type of lesion, n (%)		
100% classic	0 (0.0)	0 (0.0)
Predominantly classic	1 (2.2)	0 (0.0)
Minimally classic	0 (0.0)	7 (18.4)
Occult with no classic component	39 (84.8)	26 (68.4)
Cannot grade	6 (13.0)	5 (13.2)
CSFT, mean (SD), μm	404.1 (128.3)	411.3 (149.7)
CCT, mean (SD), μm	313.3 (95.8)	258.2 (77.0)
Presence of SRF, n (%)	43 (93.5)	37 (97.4)
Presence of IRF, n (%)	27 (58.7)	24 (63.2)
Presence of visible cysts, n (%)	14 (30.4)	15 (39.5)
Presence of polyp, n (%)	46 (100.0)	38 (100.0)
Polyp size, mean (SD), mm ²	0.318 (0.3)	0.346 (0.4)
BVN size, mean (SD), mm ²	2.045 (1.8)	2.224 (1.6)
GLD (polyp + BVN), mean (SD), μm	2,193.5 (945.6)	2,362.6 (827.3)

Notes: Randomized set consisted of all randomized participants. Percentages are based on the total number of participants in the randomized set in the respective treatment arms.

Abbreviations: BCVA, best-corrected visual acuity; BVN, branching vascular network; CCT, central choroidal thickness; CSFT, central subfield thickness; GLD, greatest linear dimension; IRF, intraretinal fluid; SRF, subretinal fluid; vPDT, verteporfin photodynamic therapy.

Reductions in CSFT and central choroidal thickness (CCT) of the study eye are shown in Figure 5A and B.

The proportion of patients with no disease activity from Month 3 to Month 11 was considerably higher in the combination arm when compared with the monotherapy arm (Month 3: 82.6% vs 47.4% and Month 11: 86.4% vs 50.0%; Figure 5C). At Month 12, serosanguinous hemorrhage was present in 15.9% of patients in the combination arm (n=7) and in 12.1% of participants in the monotherapy arm (n=4), whereas submacular hemorrhage ≥4 disc area at Month 12 was absent in the study eye of patients in both arms.

Treatment exposure

The median (interquartile range [IQR]) number of ranibizumab injections administered prior to Month 12 was 4.0 (3.0, 5.0) in the combination arm and 7.0 (4.0, 11.0) in the monotherapy arm (Table 2). About 28.9% of patients in the monotherapy arm required 10–12 injections prior to Month 12 compared with 2.2% of patients in the combination arm; accordingly, 71.7% of patients in the combination arm required 3–4 ranibizumab injections when compared with 26.3% of patients in the monotherapy arm.

The median (IQR) number of vPDT/sham PDT treatments prior to Month 12 was lower in the combination arm (vPDT; 1.0 [1.0, 1.0]) than in the monotherapy arm (sham PDT; 2.0 [2.0, 2.0]; Table 2). This is in agreement with the higher complete polyp regression rate observed in the combination arm as additional vPDT/sham PDT was administered only if active polyps were present.

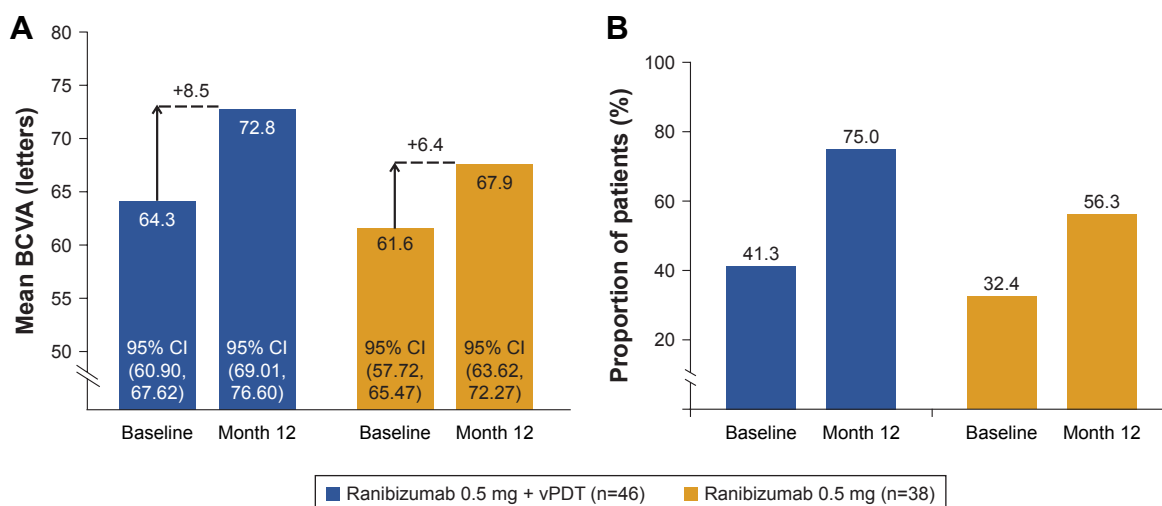


Figure 3 Assessment of BCVA outcomes over the 12-month study period.

Notes: (A) Mean BCVA and mean change at baseline and Month 12 (FAS; LOCF). (B) Proportion of patients with BCVA ≥ 69 letters at baseline and Month 12 (FAS). The FAS comprised all participants who were assigned to a treatment regimen. The total counts presented are the counts of patients in the specific treatment arm who attended the specific visit. These total counts are used as the denominator for the percentages.

Abbreviations: BCVA, best-corrected visual acuity; FAS, full analysis set; vPDT, verteporfin photodynamic therapy; LOCF, last observation carried forward; n, number of patients.

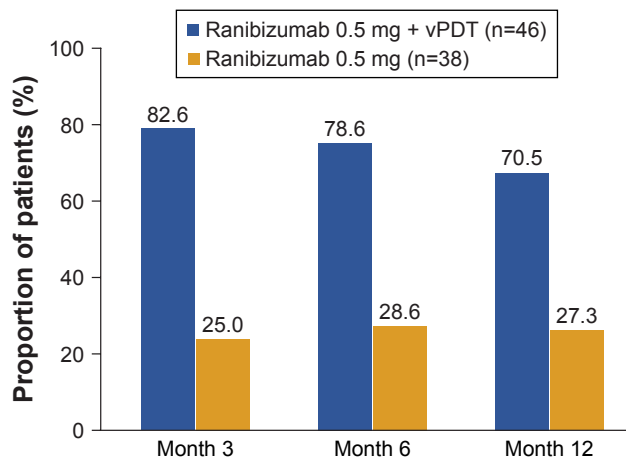


Figure 4 Proportion of participants with complete polyp regression by study visits up to Month 12 (FAS).

Notes: Values assessed by the Central Reading Center using ICGA. The FAS comprised all participants who were assigned to a treatment regimen. Number values indicate the total number of participants in the FAS in the respective treatment arm. Percentages are computed by considering the total number of participants in the respective treatment arm who attended the specific visit as a denominator.

Abbreviations: FAS, full analysis set; ICGA, indocyanine green angiography; vPDT, verteporfin photodynamic therapy.

Safety outcomes

Ocular AEs of the study eye were reported in 11 of 46 patients (23.9%) in the combination arm and 6 of 38 patients (15.8%) in the monotherapy arm. Retinal hemorrhage and increased intraocular pressure were reported each in one patient (2.2%)

in the combination arm (n=46) and none in the monotherapy arm. No cases of vitreous hemorrhage and endophthalmitis were reported in either arm (Table 3).

Nonocular AEs regardless of study drug relationship were reported in 54.3% and 52.6% of patients in the combination therapy and monotherapy arms, respectively. The most frequent nonocular AE reported in the combination and monotherapy arms was nasopharyngitis (15.2% and 15.8%, respectively). Other prominent nonocular AEs reported were eczema (4.3%) and sinusitis (4.3%) in the combination arm, and hypertension (7.9%) and constipation (5.3%) in the monotherapy arm.

No ocular SAEs were reported in the Japanese cohort. Overall, the rates of nonocular SAEs were comparable between the two treatment arms (13.0% in the combination arm vs 5.3% in the monotherapy arm).

No deaths were reported in the Japanese patients during the first 12 months; however, a single patient in the combination arm and three patients in monotherapy arm permanently discontinued the study treatment due to AEs (Figure 2).

Discussion

The results from this 12-month subanalysis of the Japanese cohort from the EVEREST II study showed that combination therapy was numerically more effective compared with

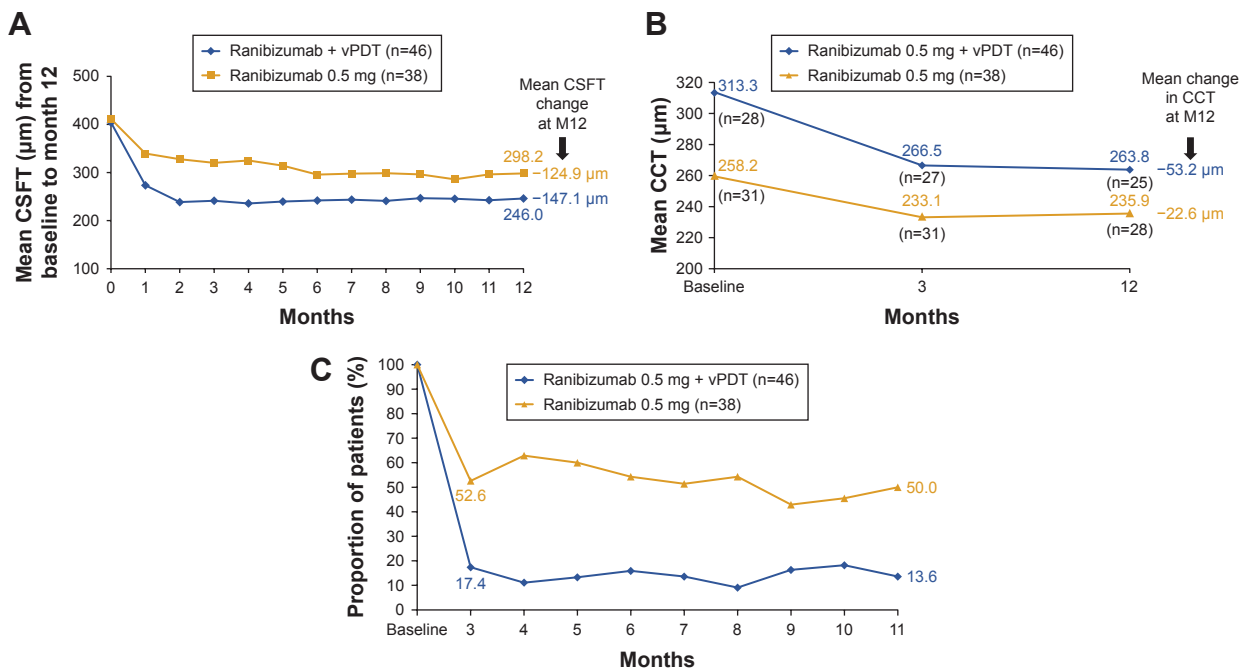


Figure 5 Mean change in CSFT and CCT, and proportion of participants with disease activity.

Notes: (A) Mean CSFT change from baseline to Month 12 (FAS). (B) Mean reduction in CCT from baseline to Month 12 (FAS). (C) Proportion of participants with disease activity by visit (FAS). The FAS comprised all participants who were assigned to the treatment regimen. Number values indicate the total number of participants in the FAS in the respective treatment arm. Percentages are computed by considering the total number of participants in the respective treatment arm who attended the specific visit as a denominator.

Abbreviations: CSFT, central subfield thickness; CCT, central choroidal thickness; FAS, full analysis set; M, month; vPDT, verteporfin photodynamic therapy.

Table 2 Number of ranibizumab injections and vPDT/sham PDT treatments administered prior to month 12 in the Japanese cohort (safety set)

Characteristics	Ranibizumab 0.5 mg + vPDT (n=46) ^a	Ranibizumab 0.5 mg (n=38) ^a
Number of ranibizumab injections		
Mean (SD)	4.2 (1.65)	7.3 (3.26)
Median (IQR)	4.0 (3.0, 5.0)	7.0 (4.0, 11.0)
Number of vPDT/sham PDT		
Mean (SD)	1.2 (0.43)	2.4 (1.13)
Median (IQR)	1.0 (1.0, 1.0)	2.0 (2.0, 4.0)

Notes: ^aSafety set consisted of all patients who received at least one application of study treatment and had at least one post baseline safety assessment. n is the total number of subjects with at least one injection.

Abbreviations: IQR, interquartile range; vPDT, verteporfin photodynamic therapy.

monotherapy in improving BCVA and achieving complete polyp regression in patients with symptomatic macular PCV with a lower mean number of ranibizumab injections. The proportion of patients with disease activity was less in the combination arm compared with the monotherapy arm. These results were consistent with those observed in the whole EVEREST II study population.²¹ The 12-month results of EVEREST II study demonstrated that combination therapy of ranibizumab and vPDT was superior to monotherapy in

Table 3 Ocular AEs regardless of study drug relationship up to month 12 (safety set)

Preferred term, n (%)	Ranibizumab 0.5 mg + vPDT (n=46)	Ranibizumab 0.5 mg (n=38)
Ocular AEs, total	11 (23.9)	6 (15.8)
Asthenopia	2 (4.3)	0 (0.0)
Blepharospasm	1 (2.2)	0 (0.0)
Cataract	0 (0.0)	2 (5.3)
Conjunctivitis allergic	0 (0.0)	1 (2.6)
Conjunctival deposit	1 (2.2)	0 (0.0)
Conjunctival hemorrhage	1 (2.2)	0 (0.0)
Corneal disorder	0 (0.0)	1 (2.6)
Eye hemorrhage	1 (2.2)	0 (0.0)
Eyelid edema	0 (0.0)	1 (2.6)
Eye pain	1 (2.2)	0 (0.0)
Hyphema	1 (2.2)	0 (0.0)
Corneal injury	1 (2.2)	0 (0.0)
Increased IOP	1 (2.2)	0 (0.0)
Retinal hemorrhage	1 (2.2)	0 (0.0)
Subretinal fluid	1 (2.2)	0 (0.0)
Blurred vision	1 (2.2)	0 (0.0)
Visual field defect	1 (2.2)	0 (0.0)
Vitreous floaters	1 (2.2)	1 (2.6)

Note: The safety set consisted of all patients who received at least one application of study treatment and had at least one post baseline safety assessment.

Abbreviations: AEs, adverse events; IOP, intraocular pressure; vPDT, verteporfin photodynamic therapy.

improving BCVA and achieving complete polyp regression. In addition, when analyzed using different modeling methods and approaches for handling missing data and outlier values, the sensitivity analyses showed similar results.²¹ Furthermore, the combination therapy arm reportedly received fewer mean ranibizumab injections (5.2) when compared with the monotherapy arm (7.3).²¹

The mean change in BCVA in the combination arm of the Japanese cohort (+8.5 letters) was similar to the other studies, such as EVEREST II (+8.3 letters) and in the initial vPDT group of the multicenter, 12-month Fujisan study (+8.1 letters).²³ This comparable mean BCVA gain was achieved, despite the fact that the combination arm of the Japanese cohort had a higher absolute baseline BCVA of about three letters than the combination arm of the overall population (in general, the higher the baseline BCVA, the lower is the BCVA gain due to the “ceiling effect”). This may result from the difference in mean disease lesion size (BVN and GLD) between the Japanese cohort, which had smaller lesions, and the overall population. Accordingly, GLD has been shown to impact on the prognosis of VA.^{24,25}

In addition to BCVA gains, other factors, such as complete polyp regression, mean BCVA value maintained over time, anatomical responses, and treatment exposure, should also be accounted for a complete assessment of treatment outcomes. In EVEREST II, with respect to complete polyp regression at Month 12, the combination therapy of ranibizumab and vPDT was superior to monotherapy (69.3% vs 34.7%; $P < 0.001$). The proportion of patients who had resolution of polyps at Month 12 in the initial vPDT group in the Fujisan study was also similar to that observed in the EVEREST II study (62.1%).²³ The present study results also corroborate the findings from EVEREST II and the initial vPDT group of Fujisan with respect to rates of complete polyp regression which were consistently higher in patients who received combination therapy (82.6%, 78.6%, and 70.5% of patients at Months 3, 6, and 12, respectively) compared with those who received monotherapy (25.0%, 28.6%, and 27.3% of patients at Months 3, 6, and 12, respectively). The difference in complete polyp regression rate between combination therapy and monotherapy is considered clinically meaningful. In concordance with the results from the overall population in EVEREST II, the mean BCVA letter score was higher, and the mean CSFT and CCT also showed a more pronounced decline from baseline at Month 12 in the ranibizumab plus vPDT combination therapy arm than the monotherapy arm.

In the current subanalysis, the median number of ranibizumab injections, prior to Month 12, required in the

combination arm in the Japanese cohort was lower compared with that in the monotherapy arm (combination arm: 4.0 and monotherapy arm: 7.0), which was similar to the EVEREST II results.²¹ The median difference of the three injections is regarded as clinically meaningful as this would contribute to reduce the treatment burden in treating patients with PCV. Moreover, >70% of Japanese patients in combination arm required only three to four ranibizumab injections in 12 months. Also, in the Fujisan study, the mean number of ranibizumab injections in the initial vPDT group was 3.5 over 12 months.²³ In LUMINOUS, the largest multicenter, worldwide, prospective, observational study of ranibizumab treatment in routine clinical practices across all approved indications, the mean number of ranibizumab injections administered prior to Month 12 was 3.4 with a mean change in BCVA at Month 12 of +6.3 letters for treatment-naïve patients with PCV in the Asian population (n=421).³⁶ As per the recently published TREND study,²⁶ it was found that Treat and Extend (T&E) regimen was effective in patients with visual impairment due to nAMD; however, the first year of T&E requires at least seven injections and this often creates a huge treatment burden on patients in real-life clinical settings. In the near future, it is expected that disease burden due to nAMD including PCV, will continue to rise in Japan (from 0.26% in 2013 to 0.32% in 2060), and correspondingly, the increase in medical expenses is expected to become ninefold.¹² A Danish database study reported that the annual injection frequencies had increased over the years despite growing options of anti-VEGF agents in nAMD.²⁷ Hence, effectively using limited medical resources in order to obtain better treatment outcomes while reducing treatment burden has become a challenge worldwide. This problem is an urgent issue especially in Japan where the elderly population is augmenting, which creates an additional burden on the national public insurance system.²⁸ In that sense, ranibizumab using a PRN regimen with initial vPDT combination therapy could be considered a first-line therapy for PCV treatment because of the high VA improvement with high complete polyp regression rate and the reduced number of anti-VEGF injections.

There have been some concerns regarding the sudden deterioration of VA due to subretinal hemorrhage after vPDT is performed, especially in patients with good VA. According to the guidelines for the management of PCV, only anti-VEGF monotherapy was recommended for patients with good VA;³ furthermore, only anti-VEGF monotherapy was recommended for PCV with 20/32 or more in Snellen equivalent in Japanese guidelines for the treatment of AMD due to the concerns of complication risks with vPDT.⁹

However, the combination therapy did not show any increase in the risk of hemorrhage in the first year of therapy when compared with monotherapy in this Japanese cohort, which incidentally included 12 patients (26.1%) with VA \geq 74 letters at baseline in the combination arm. One retinal hemorrhage (2.2%) was reported over 12 months in combination arm, and there were low rates of ocular AEs in both treatment arms. In addition, the proportion of patients with serosanguinous hemorrhage and massive submacular hemorrhage also showed a considerable decrease over 12 months in both the treatment arms, similar to the results from the overall population.²¹ Furthermore, some reports have also indicated that the combination of vPDT with an anti-VEGF agent can reduce the rate of vPDT-related hemorrhages.^{29–33} Therefore, combination therapy of an anti-VEGF agent and vPDT can be recommended as a first-line therapy even for patients with good VA.

There are a few limitations in this analysis of the Japanese cohort. This is an exploratory analysis, and the number of patients in each treatment arm is small; hence, the study was not powered to perform comparative statistics between the arms. In addition, the study reported relatively short-term results over 12 months and, therefore, long-term study outcomes would provide further insights into the efficacy and safety in this Japanese cohort.

The strength of this analysis lies in the fact that the EVEREST II study is one of the first studies to enroll such a large number of patients with symptomatic macular PCV across 22 sites in Japan. A total of 84 Japanese patients, who had self-identified themselves as having Japanese ethnicity, were included in the EVEREST II study, and they were exclusively from 22 Japan sites only. Therefore, the outcomes of this study are specific to Japanese population. The EVEREST II study has generated one of the largest prospectively collected multi-modal image sets of PCV lesions based on a standardized imaging, reading, and diagnostic protocol. At baseline, the majority of patients in both treatment arms had “occult with no classic component” as the major lesion type, which is a common characteristic in patients with PCV.^{34,35} This highlights the importance of the central reading center during the screening phase,²¹ as it ensured that only patients with well-defined PCV were recruited.

Conclusion

The results of the 12-month analysis of Japanese cohort of the EVEREST II study were in agreement with the results of EVEREST II, which showed that combination therapy of ranibizumab and vPDT was more effective in improving

BCVA, and achieving complete polyp regression, numerically higher reduction in CSFT and CCT, with a higher proportion of patients with no disease activity than ranibizumab monotherapy. As these functional and anatomical outcomes were achieved with a fewer number of ranibizumab injections received in the combination therapy arm compared with the monotherapy arm, there was a reduction in treatment burden in these patients. There were no new safety signals with ranibizumab and vPDT in this study, and the safety outcomes were consistent between both treatment arms. The 24-month data of the EVEREST II study will provide valuable insights into the baseline characteristics and long-term efficacy and safety outcomes of the combination as well as monotherapy, in patients with symptomatic macular PCV.

Data sharing statement

All data generated or analyzed during this study are included in this published article.

Acknowledgments

The authors thank Apra Manral and Sabyasachi Ghosh (Scientific Services Practice – Product Lifecycle Services, Novartis Healthcare Pvt. Ltd., India) for medical writing and editorial assistance toward the development of this article. The authors of this manuscript would also like to thank the EVEREST II study investigators from Japan: Kunihiro Shiraki, Osaka City University Hospital, Osaka-city, Osaka; Yasuo Yanagi and Satoshi Kato, The University of Tokyo Hospital, Bunkyo-ku, Tokyo; Tetsuju Sekiryu, Fukushima Medical University Hospital, Fukushima city, Fukushima; Shoji Kishi and Masahiro Morimoto, Gunma University Hospital, Maebashi city, Gunma; Tatsuro Ishibashi, Yuji Oshima, and Koh-hei Sonoda, Kyushu University Hospital, Fukuoka city, Fukuoka; Rvsuburo Mori, Nihon University Hospital, Kanda Surugadai, Chiyoda, Tokyo; Ayame Annabelle Okada, Kyorin University Hospital, Shinkawa, Mitaka, Tokyo; Tomohiro Iida, Tokyo Women's Medical University Hospital, Kawada-cho, Shinjuku-ku, Tokyo; Takayuki Baba, Chiba University Hospital, Inohana Chuo-ku Chiba-shi Chiba; Fumio Shiraga, Okayama University Hospital, Shikata-cho, Kita-ku, Okayama, Okayama; Hideyasu Oh, Hyogo Prefectural Amagasaki General Medical Center, Higashinaniwa-cho, Amagasaki city, Hyogo; Toshiya Sakurai, Tane Memorial Eye Hospital, Sakaigawa, Nishi-ku, Osaka; Nagako Kondo, Miyake Eye Hospital, Ozone, Kita-ku, Nagoya City; Mineo Kondo, Mie University Hospital, Edobashi, Tsu, Mie; Masahiro Miura, Tokyo Medical University Ibaraki Medical Center, Inashiki-gun Ibaraki; Chieko Shiragami, Kagawa University Hospital, Kita-gun,

Kagawa; Yasuo Kurimoto, Kobe City Medical Center General Hospital, Kobe city, Hyogo; and Nagahisa Yoshimura, Kyoto University Hospital, Sakyo-ku, Kyoto. The study was funded by Novartis Pharma AG. The sponsor had no direct role in the design or conduct of this research.

Disclosure

Kanji Takahashi received grant, personal fees, and nonfinancial support from Novartis, Santen, Alconpharma, Bayer; grant and personal fees from Senju; personal fees from Ohtsuka and Carl Zeiss; grant from Hoya, Amo, Senju and Sun Contact Lens; grant and financial support from Pfizer. Dr Masahito Ohji reported grants and personal fees from Novartis, Bayer, Santen, Pfizer, Senju, Alcon, Otsuka Pharmaceutical, Kowa Pharmaceutical, HOYA Corporation, Topcon; personal fees from Allergan, Carl Zeiss, RE Medical Inc., Bausch + Lomb, Chuo Sangio; and grants from AMO, TOMEY, outside the submitted work. Hiroko Terasaki received grant and personal fees from Nidek Inc., Otsuka Pharmaceutical Co., Ltd., Pfizer, Inc., Santen Inc., Alcon Japan Ltd., Novartis Pharmaceuticals Corporation, Senju Pharmaceutical Co. Ltd., Kowa Pharmaceutical Co. Ltd., Wakamoto Co., Ltd.; personal fees from Rohto Pharmaceutical co., Ltd., Takeda Pharmaceutical Company Limited., Mitsubishi Tanabe Pharma Corporation, Graybug Vision, Inc, Alcon Research Surgical Retina R&D, Alcon Laboratories, Inc., Alcon Research Ltd, AbbVie GK, Daiichi Sankyo Company, Limited, Chuo Sangio Co., Sanofi K.K., Nihon Tenganyaku Kenkyusyo Co. Ltd., Alcon Pharma Corporation, Bayer Healthcare Pharmaceuticals; financial grant from HOYA Corporation and Allergan Japan; and personal fees and nonfinancial support from Carl Zeiss Meditec co., Ltd. Shigeru Honda has no conflicts of interest to be disclosed. Philippe Margaron is an employee of Novartis Pharma AG, Basel, Switzerland. Tadhg Guerin is an employee of Novartis Global Service Center, Dublin, Ireland. Mitsuko Yuzawa received grants and personal fees from Alcon Japan; personal fees and nonfinancial support from Novartis, Bayer, Bausch & Lomb Japan; personal fees from Senju, Astelles Pharma, Japan focus company, Janssen Japan. The authors report no other conflicts of interest in this work.

References

1. Koh AH; Expert PCV Panel, Chen LJ, et al. Polypoidal choroidal vasculopathy: evidence-based guidelines for clinical diagnosis and treatment. *Retina*. 2013;33(4):686–716.
2. Japanese Study Group of Polypoidal Choroidal Vasculopathy. Criteria for diagnosis of polypoidal choroidal vasculopathy. *Nippon Ganka Gakkai Zasshi*. 2005;109(7):417.
3. Terasaki H, Miyake Y, Suzuki T, Nakamura M, Nagasaka T. Polypoidal choroidal vasculopathy treated with macular translocation: clinical pathological correlation. *Br J Ophthalmol*. 2002;86(3):321–327.

4. Yuzawa M. Polypoidal choroidal vasculopathy. *Nihon Ganka Gakkai Zasshi*. 2012;116:200–231; discussion 232.
5. Fan Q, Cheung CMG, Chen LJ, et al. Shared genetic variants for polypoidal choroidal vasculopathy and typical neovascular age-related macular degeneration in East Asians. *J Hum Genet*. 2017;62(12):1049–1055.
6. Ma L, Li Z, Liu K, et al. Association of genetic variants with polypoidal choroidal vasculopathy: a systematic review and updated meta-analysis. *Ophthalmology*. 2015;122(9):1854–1865.
7. Nishiguchi KM, Yasuma TR, Tomida D, et al. C9-R95X polymorphism in patients with neovascular age-related macular degeneration. *Invest Ophthalmol Vis Sci*. 2012;53(1):508–512.
8. Honda S, Matsumiya W, Negi A. Polypoidal choroidal vasculopathy: clinical features and genetic predisposition. *Ophthalmologica*. 2014; 231(2):59–74.
9. Wong RL, Lai TY. Polypoidal choroidal vasculopathy: an update on therapeutic approaches. *J Ophthalmic Vis Res*. 2013;8(4):359.
10. Kim JH, Chang YS, Lee DW, Kim CG, Kim JW. Quantification of retinal changes after resolution of submacular hemorrhage secondary to polypoidal choroidal vasculopathy. *Jpn J Ophthalmol*. 2018;62(1):54–62.
11. Akagi-Kurashige Y, Tsujikawa A, Yuzawa M, et al. A 5-year multicenter prospective cohort study on the long-term visual prognosis and predictive factors for visual outcome in Japanese patients with age-related macular degeneration: the AMD2000 study. *Jpn J Ophthalmol*. 2018;62(2):137–143.
12. Kume A, Ohshiro T, Sakurada Y, Kikushima W, Yoneyama S, Kashiwagi K. Treatment patterns and health care costs for age-related macular degeneration in Japan: an analysis of national insurance claims data. *Ophthalmology*. 2016;123(6):1263–1268.
13. Kawasaki R, Wang JJ, Ji GJ, et al. Prevalence and risk factors for age-related macular degeneration in an adult Japanese population: the Funagata study. *Ophthalmology*. 2008;115(8):1376–1381.
14. Yasuda M, Kiyohara Y, Hata Y, et al. Nine-year incidence and risk factors for age-related macular degeneration in a defined Japanese population the Hisayama study. *Ophthalmology*. 2009;116(11):2135–2140.
15. Tsujikawa A, Akagi-Kurashige Y, Yuzawa M, et al. Baseline data from a multicenter, 5-year, prospective cohort study of Japanese age-related macular degeneration: an AMD2000 report. *Jpn J Ophthalmol*. 2018;62(2):127–136.
16. Sho K, Takahashi K, Yamada H, et al. Polypoidal choroidal vasculopathy: incidence, demographic features, and clinical characteristics. *Arch Ophthalmol*. 2003;121(10):1392–1396.
17. Maruko I, Iida T, Saito M, Nagayama D, Saito K. Clinical characteristics of exudative age-related macular degeneration in Japanese patients. *Am J Ophthalmol*. 2007;144(1):15–22.
18. Coscas G, Yamashiro K, Coscas F, et al. Comparison of exudative age-related macular degeneration subtypes in Japanese and French patients: multicenter diagnosis with multimodal imaging. *Am J Ophthalmol*. 2014;158(2):309–318.
19. Tano Y. Guidelines for PDT in Japan. *Ophthalmology*. 2008;115(3): 585–585.e6.
20. Koh A, Lee WK, Chen L-J, et al. EVEREST study: efficacy and safety of verteporfin photodynamic therapy in combination with ranibizumab or alone versus ranibizumab monotherapy in patients with symptomatic macular polypoidal choroidal vasculopathy. *Retina*. 2012;32:1453–1464.
21. Koh A, Lai TYY, Takahashi K, et al. Efficacy and safety of ranibizumab with or without verteporfin photodynamic therapy for polypoidal choroidal vasculopathy. *JAMA Ophthalmol*. 2017;135(11):1206–1213.
22. Takahashi K, Ogura Y, Ishibashi T, Shiraga F, Yuzawa M. Treatment guidelines for age-related macular degeneration. *Nippon Ganka Gakkai Zasshi*. 2012;116:1150–1155.
23. Gomi F, Oshima Y, Mori R, et al. Initial versus delayed photodynamic therapy in combination with ranibizumab for treatment of polypoidal choroidal vasculopathy: The Fujisan Study. *Retina*. 2015;35(8):1569–1576.
24. Kuroda Y, Yamashiro K, Miyake M, et al. Factors associated with recurrence of age-related macular degeneration after anti-vascular endothelial growth factor treatment: a retrospective cohort study. *Ophthalmology*. 2015;122(11):2303–2310.
25. Matsumiya W, Honda S, Otsuka K, et al. One-year outcome of combination therapy with intravitreal aflibercept and verteporfin photodynamic therapy for polypoidal choroidal vasculopathy. *Graefes Arch Clin Exp Ophthalmol*. 2017;255(3):541–548.
26. Silva R, Berta A, Larsen M, et al. Treat-and-extend versus monthly regimen in neovascular age-related macular degeneration: results with ranibizumab from the TREND Study. *Ophthalmology*. 2018;125:57–65.
27. Vorum H, Olesen TK, Zinck J, Størling Hedegaard M. Real world evidence of use of anti-VEGF therapy in Denmark. *Curr Med Res Opin*. 2016;32(12):1943–1950.
28. Nomura H, Nakayama T. The Japanese healthcare system. *Br Med J*. 2005;331(7518):648–649.
29. Gomi F, Sawa M, Wakabayashi T, Sasamoto Y, Suzuki M, Tsujikawa M. Efficacy of intravitreal bevacizumab combined with photodynamic therapy for polypoidal choroidal vasculopathy. *Am J Ophthalmol*. 2010;150(1):48–54.
30. Sato T, Kishi S, Matsumoto H, Mukai R. Comparisons of outcomes with different intervals between adjunctive ranibizumab and photodynamic therapy for polypoidal choroidal vasculopathy. *Am J Ophthalmol*. 2013;156(1):95–105.
31. Tomita K, Tsujikawa A, Yamashiro K, et al. Treatment of polypoidal choroidal vasculopathy with photodynamic therapy combined with intravitreal injections of ranibizumab. *Am J Ophthalmol*. 2012;153(1): 68–80.
32. Wong CW, Cheung CMG, Mathur R, et al. Three-year results of polypoidal choroidal vasculopathy treated with photodynamic therapy: retrospective study and systematic review. *Retina*. 2015;35:1577–1593.
33. Yamashita A, Shiraga F, Shiragami C, Shirakata Y, Fujiwara A. Two-year results of reduced-fluence photodynamic therapy for polypoidal choroidal vasculopathy. *Am J Ophthalmol*. 2013;155(1):96–102.
34. Kameda T, Tsujikawa A, Otani A, et al. Polypoidal choroidal vasculopathy examined with en face optical coherence tomography. *Clin Exp Ophthalmol*. 2007;35(7):596–601.
35. Yadav S, Parry DG, Beare NAV, Pearce IA. Polypoidal choroidal vasculopathy: a common type of neovascular age-related macular degeneration in Caucasians. *Br J Ophthalmol*. 2017;101(10):1377–1380; bjoophthalmol-2016-310074.
36. Koh A, Prajapati K, Macfadden W. Baseline characteristics and 1-year outcomes of treatment-naïve nAMD patients with PCV from the LUMINOUS study: ranibizumab in a real-world setting. 17th EURETINA Congress, Barcelona, Spain, 7–10 September 2017. Available from: <http://new.euretina.org/barcelona2017/programme/free-papers-details.asp?id=13359&day=0>. Accessed July 24, 2018.

Clinical Ophthalmology

Publish your work in this journal

Clinical Ophthalmology is an international, peer-reviewed journal covering all specialties within ophthalmology. Key topics include: Optometry; Visual science; Pharmacology and drug therapy in eye diseases; Basic Sciences; Primary and Secondary eye care; Patient Safety and Quality of Care Improvements. This journal is indexed on

Submit your manuscript here: <http://www.dovepress.com/clinical-ophthalmology-journal>

Dovepress

PubMed Central and CAS, and is the official journal of The Society of Clinical Ophthalmology (SCO). The manuscript management system is completely online and includes a very quick and fair peer-review system, which is all easy to use. Visit <http://www.dovepress.com/testimonials.php> to read real quotes from published authors.