

Endoscopic treatment of biliary complications in left lobe living donor liver transplantation

Mehmet Ali Erdogan
Muhsin Murat Harputluoglu

Department of Gastroenterology,
Medical Faculty, Inonu University,
Malatya 44210, Turkey

Purpose: Almost all of the publications regarding the treatment of biliary complications after liver transplantation are related to biliary complications after right lobe living donor liver transplantation (LDLT) and cadaveric liver transplantation (LT). The number of publications regarding endoscopic treatment of biliary complications after left lobe LDLT is negligible. In this study, we aimed to present the results of endoscopic treatments applied in the management of biliary complications developed in left-lobe duct-to-duct LDLT patients.

Patients and methods: Between 2008 and 2018, patients with duct-to-duct anastomosis who underwent ERCP due to biliary complication after left lobe LDLT were included in the study. Clinical data included patient demographics, indications for LDLT, duration till the first ERCP after LDLT, number of ERCP procedures, ERCP indications (stricture or leak), and treatment outcomes, including the need for percutaneous and surgical interventions.

Results: Among 13 patients who underwent ERCP, 2 (15%) had biliary leakage and 11 (8%) had an anastomotic stricture. Our endoscopic success rate was 100% in patients with biliary stricture. Despite the implementation of ERCP on two patients with leakage, they died due to the biliary complication.

Conclusion: Our results suggest that endoscopic treatment methods are successful in the management of biliary stricture complication in patients with left lobe LDLT and duct-to-duct anastomosis. Although our findings show that endoscopic treatments fail when there is a leakage after left lobe LDLT, there is a need for further studies that include more patients to reach a definite conclusion.

Keywords: anastomotic stricture, biliary leakage, biliary stone, ERCP, liver transplantation

Introduction

Biliary complications develop in approximately 30% of the liver transplant patients and are associated with significant morbidity and mortality.¹ Often, one or more of the biliary complications may be in the form of anastomotic stricture, biliary leakage, stone or debris.^{2,3} Biliary complication incidence after cadaveric liver transplantation is 10%–15%, while in living donor liver transplantations, this rate goes up to 37%.⁴ Living donor liver transplants are usually performed using the right lobe.^{5,6} Nearly all the publications related to the treatment of biliary complications after liver transplantation are focused on biliary complications that occur after right lobe living donor liver transplantation (LDLT) and cadaveric liver transplantation (LT). The number of publications regarding endoscopic treatments of biliary complications after left lobe LDLT is almost negligible.

In this study, we present the results of endoscopic treatments that we performed in the management of biliary complications developed in left lobe duct-to-duct LDLT patients.

Correspondence: Mehmet Ali Erdogan
Department of Gastroenterology,
Medical Faculty, Inonu University,
Malatya 44210, Turkey
Tel +90 505 496 5191
Fax +90 85 0297 9003
Email mehmet_ali_erdogan@hotmail.com

Material and methods

We analyzed the patient records of the Liver Transplantation Institute of Inonu University between September 2008 and January 2018, retrospectively. In our center, some parameters are taken into account in the graft type decision-making process in liver transplantation. These parameters are the risk to the donor, the residual liver volume for the donor, the size of the recipient and the liver mass required. Left lobe grafts were preferred in patients who were not expected to pose a risk to the recipient and the donor. Patients, who underwent endoscopic retrograde cholangiopancreatography (ERCP) after left lobe LDLT, were included in our study. The study was approved by the ethics committee of our university (decision number 2018/16–36) and written informed consents for reaching medical histories and interventions were obtained from all patients.

Clinical data included patient demographics, indication for LDLT, number of ERCP procedures, ERCP indications (stricture or leak), time for the first ERCP after LDLT and treatment outcomes including the need for percutaneous and surgical interventions.

Every patient was evaluated at a multidisciplinary committee including transplant surgeons, radiologists and gastroenterologists, along with their clinical data and imaging including magnetic resonance (MRI) or percutaneous cholangiography prior to ERCP.

When there were cholangitis symptoms or elevation of liver function tests, biliary stricture was suspected to be the cause. Magnetic resonance cholangiopancreatography (MRCP)/computerized tomography (CT) or percutaneous cholangiography was used to diagnose the biliary strictures. ERCP was preferred to be the first choice in patients with duct-to-duct anastomosis, in case there were findings of biliary stricture. Percutaneous cholangiograms were routinely performed for clinical indications just prior to catheter removal in approximately 90 days after liver transplantation. We used diluted contrast reagent (Iohexol, Omnipaque 300™, 647 mg iohexol/mL, GE Healthcare, Oslo, Norway) to confirm the presence of biliary complications during percutaneous cholangiography. ERCP was not performed in patients without duct-to-duct anastomosis. Two experienced gastroenterologists (M.M.H., and M.A.E.) performed ERCP using Olympus duodenoscopes (TJF 160, Olympus Optical Co., Ltd., Tokyo, Japan). During ERCP, we routinely performed endoscopic sphincterotomy in every patient. When biliary stricture was detected in cholangiography performed with contrast agent, a 0.025 or 0.035-inch guidewire (Jagwire, Boston Scientific, Natick, MA, USA) was inserted via the

catheter into the intrahepatic bile ducts. Later, we dilated it using a bougie (7 and 10 French, Wilson-Cook Medical GI Endoscopy, Winston Salem, NC, USA), and/or a balloon catheter (4, 6, or 8 mm, Hurricane RX; Boston Scientific, USA). Then, Amsterdam-type biliary stents (7 and 10 French, 9–18 cm long, Boston Scientific) were placed across the stricture or anastomosis. ERCP and stent revision was performed every 3–6 months. We incrementally increased the diameter and number of the stent to treat the stricture in each session. In our center, minimum stenting time was approximately 18 months. After 18 months, all patients with stricture were especially evaluated for stentless follow-up by cholangiography during the ERCP procedure. When the stricture was treated, we removed the biliary stents and monitored the patient without stents and when the stricture persisted, re-dilatation and re-stenting was performed endoscopically.

In the cases where cholangiogram showed a biliary leakage in patients with duct-to-duct anastomosis, ERCP was preferred as a treatment modality. Figure 1 shows our treatment algorithm in the presence of biliary leakage. When biliary leakage was detected during ERCP, we inserted biliary stents to stop the leakage. When biliary stones were found on imaging or during ERCP, we extracted the stones with a balloon or basket catheter.

When ERCP was unsuccessful (failure to avoid stricture or persistent biliary complications despite dilatation and stent placement), our multidisciplinary team determined whether percutaneous transhepatic biliary interventions (PTBI) and/or surgical treatments were indicated. When endoscopic and percutaneous treatments failed, surgical treatment was offered as a final option. In this study, ERCP was considered successful when patients did not have PTBI, surgery or death due to a biliary complication at any time during follow-up after the first ERCP. The data were analyzed using SPSS version 16.0 (SPSS Inc, Chicago, IL, USA) after being entered manually.

Results

Total liver transplantation number during the study period was 1,810 (1,460 LDLT, 350 cadaveric). Thirty-two patients underwent left lobe LDLT, all remaining patients underwent right lobe LDLT. It was found that ERCP was performed on 13 patients having duct-to-duct anastomosis due to biliary complications, out of 32 left lobe LDLT patients. Six of these patients were male (46%) and their median age was 46 (21–70). Recipients had transplantations due to Hepatitis B in 4, cryptogenic in 3, autoimmune hepatitis in 2, Budd–Chiari syndrome in 1, primary sclerosing cholangitis

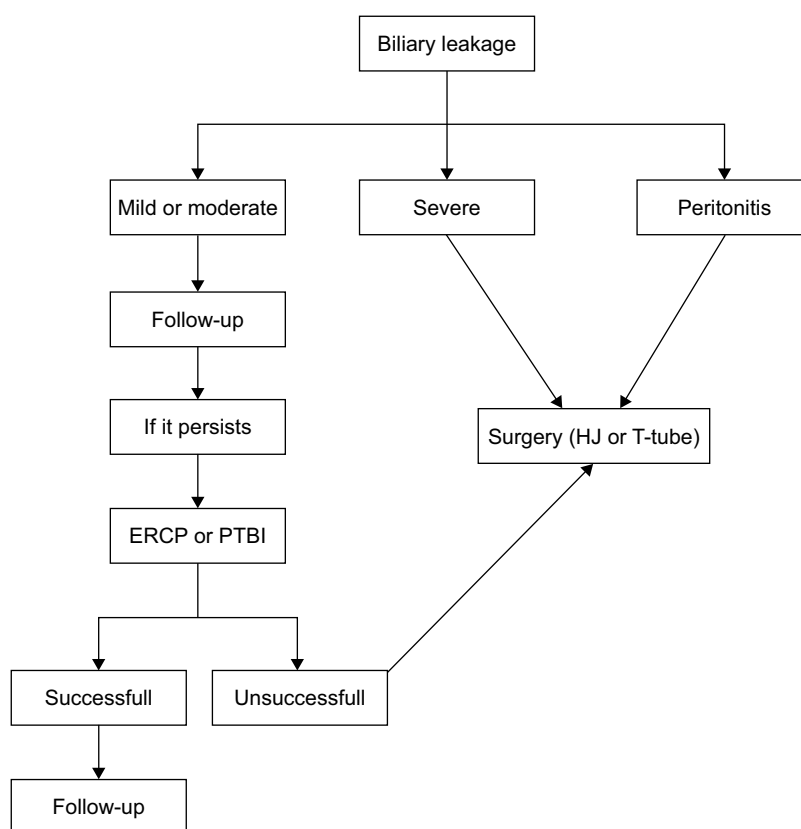


Figure 1 Our treatment algorithm in patients with Biliary Leakage.

Abbreviations: ERCP, endoscopic retrograde cholangiopancreatography; HJ, hepaticojejunostomy; PTBI, percutaneous transhepatic biliary interventions.

in 1, congenital hepatic fibrosis in 1 and fulminant hepatic failure in 1. Of the 13 patients who underwent ERCP, 2 had biliary leakage (15%) and 11 had an anastomotic stricture (85%). In patients with anastomotic stricture, the median time till the first ERCP after transplantation was 17 (7–96) weeks. The median number of ERCP processes in patients with stricture was 4 (1–14). The stricture was accompanied by stones in 6 of the patients. The time passed till the first ERCP after transplantation was 14 weeks (8–20 weeks) in patients with leakage. ERCP was performed only once in two patients with leakage.

Biliary dilatation and stenting were performed on 6 patients with anastomotic stricture. The remaining 5 patients received stenting only. We decided to use these interventional approaches according to the degree of strictures. Serious strictures were first dilated with bougie and balloon and then a stent was applied. The stent was implanted in the first session in patients with less strictures. The biliary stone balloon was used to clean the stones. ERCP was successfully performed on all 11 patients with stricture, no PTBI or surgical treatment was needed. In these patients, the median follow-up period of the process after the first

ERCP was 16 months (3–42). In 6 of the patients, stenting with ERCP is being performed once every 3 months. Five patients with stricture, are being monitored in a stent-free way for 2, 3, 5, 8 and 50 months, respectively. Only endoscopic sphincterotomy (EST) was performed on 1 patient who had developed a biliary leakage, whereas the other patient underwent endoscopic sphincterotomy (EST) and stenting. One of these patients underwent an abdominal washout surgery, and the other did not receive any treatment except for endoscopic treatment. Both patients died after two weeks of ERCP due to biliary sepsis (Table 1).

Discussion

In this study, the ERCP success rate in 11 patients, who underwent ERCP due to biliary stricture after left lobe LDLT, was 100%. None of these patients needed PTBI or surgical treatment due to the biliary problem. Despite the ERCP implementation, 2 patients who had biliary leakage died due to biliary complication.

Unlike in right lobe, a bile duct is usually encountered in left lobe graft. Therefore, duct-to-duct anastomosis in left lobe liver transplantation is easier. However, arterial feeding

Table 1 Results of patients who underwent ERCP after left lobe LDLT

Patients	Age	Sex	Etiology	Biliary complication	Time to the first ERCP (week)	ERCP procedure number	Endoscopic treatment	Surgery	Outcome and follow-up duration (months)
Case 1	63	M	HBV	Leak	8	1	ST	AW	Death
Case 2	69	M	HBV	AST	60	4	BD, ST		WS (16) and SF (50) respectively
Case 3	52	F	HBV	Leak	20	1	EST		Death
Case 4	22	M	CC	AST, BS	64	5	BD, ST		WS (16) and SF (2)
Case 5	57	F	CC	AST, BS	96	13	BD, ST		WS (40) and SF (8) respectively
Case 6	21	F	CHF	AST	28	4	ST		WS (12)
Case 7	49	M	AIH	AST	9	3	ST		WS (10)
Case 8	32	F	FHF	AST	13	2	BD, ST		WS (6)
Case 9	29	F	AIH	AST, BS	13	4	ST		WS (16)
Case 10	42	F	PSC	AST, BS	10	9	BD, ST		WS (28) and SF (3)
Case 11	46	M	CC	AST, BS	7	14	ST		WS (42) and SF (5)
Case 12	35	F	BCS	AST, BS	17	11	ST		WS (30)
Case 13	70	M	HBV	AST	53	1	BD, ST		WS (3)

Abbreviations: AIH, autoimmune hepatitis; AST, anastomotic stricture; AWW, abdominal washout; BCS, Budd–Chiari syndrome; BD, biliary dilatation; BS, biliary stone; CC, cryptogenic cirrhosis; CHF, congenital hepatic fibrosis; ERCP, endoscopic retrograde cholangiopancreatography; EST, endoscopic sphincterotomy; FHF, fulminant hepatic failure; HBV, Hepatitis B virus; LDLT, living donor liver transplantation; PSC, primary sclerosing cholangitis; SF, stent-free; ST, stent; WS, with stent.

of the biliary duct bifurcation is extremely complex. When the segment 4 artery anastomosis is sometimes neglected, ischemic changes may be seen in the bile ducts of the left lobe grafts. In addition, the right and upward growth of the graft after left LDLT makes it difficult to visualize duct-to-duct anastomosis with ERCP.

Cadaveric organ shortage is the most important problem in liver transplantation. However, nowadays different graft types are being used to overcome this major problem. Right-lobe is preferred most commonly during the living donor liver transplantation because it helps to meet the metabolic demands of a recipient. However, the donor morbidity and mortality after right lobe donation have remained a formidable challenge over the last two decades. Donor safety has the highest priority in LDLT. The risk of donor mortality with the left lobe donation is lower compared to right liver donation.⁷ Therefore, left-lobe graft use seems to be an important option because of advantages such as donor safety and positive biliary results.⁸ However, the use of these grafts has increased the frequency of biliary complications significantly.⁴ The rate of biliary complications was reported to be 47% in patients with left lobe transplant.⁹ One of the most common complications after LDLT are biliary strictures. A biliary stricture is frequently observed to be 7.3%–60% in the right lobe grafts, 24% in the left lateral segment grafts¹⁰ and 23.8%–32.1% in the left lobe grafts.^{9,11}

There is no established therapeutic algorithm for treatment of biliary complications after LDLT. However, endoscopic treatments, percutaneous transhepatic intervention, and surgery have been frequently used. Currently,

non-surgical treatments have largely replaced surgery as the initial treatment of biliary complications. ERCP is the first choice treatment in the presence of duct-to-duct anastomosis in post-LDLT biliary complications because it is less invasive, safe, effective, and easily accessible.^{12,13} Percutaneous transhepatic interventions are subsequently considered in cases where the endoscopic treatments fail. Surgical treatments are more complicated. Therefore, these are considered as a rescue therapy when all other treatment methods prove to be unsuccessful.¹³

In literature, the success rate of endoscopic treatment of biliary strictures after LDLT is 20%–100%.^{14,15} However, almost all of the publications related to this topic are about endoscopic treatment results after right lobe LDLT. Chan et al reported an endoscopic success rate of 75% for biliary stricture in 8 patients with LDLT (left graft in 4 patients).¹⁶ Nakaseko et al reported that a stent was applied to a bile duct using ERCP in a patient with left-side grafted having duct-to-duct anastomosis and biliary stricture, and a stricture was successfully treated using a combination of ERCP, PTBI, and magnet compression anastomosis methods in another non-visible bile duct with stricture.¹⁷ In our study; the frequency of biliary stricture after left lobe LDLT was 34% (11/32) and the success rate of ERCP in 11 patients who underwent ERCP due to stricture, was 100%. None of these patients needed PTBI or surgical treatment due to a biliary problem. All of the patients, who underwent ERCP due to stricture, are being followed-up with stent revisions at the moment except five. Our results show that endoscopic treatment methods are very successful in the management

of biliary stricture complications in patients with left lobe LDLT and duct-to-duct anastomosis.

Another biliary complication seen after LDLT is biliary leakage. The prevalence of bile leaks does not differ significantly between DDLT and LDLT and furthermore, the frequency is not affected by anastomosis type (duct-to-duct or hepaticojejunostomy).¹⁸ The incidence of bile leakage after transplantation has been reported to be 2%–25%.^{12,19} ERCP, along with sphincterotomy and biliary stent placement, has become the preferred method of diagnosing and treating biliary leakage with high success rates and low complication rates in the patients with duct-to-duct anastomotic LDLT.²⁰ Wadhawan et al reported an endoscopic success rate of 82% (14/17 patients) in patients with biliary leakage after LDLT.²¹ Chan et al reported that endoscopic treatments were successful in more than 85% of biliary leakage patients.¹⁶ Elwir et al reported that ERCP was the only treatment modality in 19 (90%) out of 21 patients who underwent ERCP due to leakage after LDLT.²² Chok et al reported that half of the patients were successfully treated with endo-radiological method in a very small group of patients (n=12) after LDLT.²³ Although endoscopic treatments have taken priority over surgical treatments in the treatment of biliary stricture, there is still a need for surgical treatments when there is leakage. In a meta-analysis of 2,812 LDLT patients, contrary to previous studies reporting high success rates of endoscopic treatments in biliary leakages, only 40 out of 268 patients with biliary leakage could be treated endoscopically, and most patients (101 patients) were reported to have undergone surgery.²⁴ Similarly, it has been reported that primary surgical approach was implemented in more than 50% of patients with biliary leakage.^{23,25,26} The studies mentioned are related to the treatment of leakage after right lobe LDLT. There are no publications on the treatment of patients with leakage after left lobe LDLT. In our study, the biliary leak rate was 6% (2/32) and was consistent with the literature. Only EST was applied to one of the 2 ERCP patients due to biliary leakage, and EST and stent were applied to the other. One of these patients underwent an abdominal washout surgery, whereas the other did not receive any treatment other than endoscopic treatment. Both patients died due to biliary sepsis after two weeks of ERCP. Mostly biliary leakage is diagnosed in the early postoperative period and is associated with significant mortality and morbidity. In one study, 19% of patients with biliary leakage were lost due to complications related to biliary leakage. The 2-year survival rate in patients with biliary leakage was reported to be 65%, whereas it was reported to be 85% in patients without biliary leakage.^{27,28} Our results suggest that endoscopic treatment is unsuccessful

in left lobe LDLT patients with leakage. In addition, the fact that our case count is very low and that there is no data available in the literature regarding the treatment of leakages after left lobe LDLT makes it difficult to comment on the efficacy of endoscopic methods in managing this complication.

Conclusion

Our results suggest that endoscopic treatment methods are very successful in the management of biliary stricture complication in patients with left lobe LDLT and duct-to-duct anastomosis. Although our findings suggest that endoscopic treatments fail when there is leakage after left lobe LDLT, there is a need for studies that include more patients to reach to a definite conclusion.

Disclosure

The authors report no conflicts of interest in this work.

References

1. Roos FJM, Poley JW, Polak WG, Metselaar HJ. Biliary complications after liver transplantation; recent developments in etiology, diagnosis and endoscopic treatment. *Best Pract Res Clin Gastroenterol*. 2017; 31(2):227–235.
2. Traina M, Tarantino I, Barresi L, et al. Efficacy and safety of fully covered self-expandable metallic stents in biliary complications after liver transplantation: a preliminary study. *Liver Transpl*. 2009; 15(11):1493–1498.
3. Tarantino I, Barresi L, Petridis I, Volpes R, Traina M, Gridelli B. Endoscopic treatment of biliary complications after liver transplantation. *World J Gastroenterol*. 2008;14(26):4185–4189.
4. Chang JH, Lee I, Choi MG, Han SW. Current diagnosis and treatment of benign biliary strictures after living donor liver transplantation. *World J Gastroenterol*. 2016;22(4):1593–1606.
5. Shah SA, Grant DR, Mcgilvray ID, et al. Biliary strictures in 130 consecutive right lobe living donor liver transplant recipients: results of a Western center. *Am J Transplant*. 2007;7(1):161–167.
6. Freise CE, Gillespie BW, Koffron AJ, et al. Recipient morbidity after living and deceased donor liver transplantation: findings from the A2ALL Retrospective Cohort Study. *Am J Transplant*. 2008; 8(12):2569–2579.
7. Raut V, Alikhanov R, Belghiti J, Uemoto S. Review of the surgical approach to prevent small-for-size syndrome in recipients after left lobe adult LDLT. *Surg Today*. 2014;44(7):1189–1196.
8. Taketomi A, Kayashima H, Soejima Y, et al. Donor risk in adult-to-adult living donor liver transplantation: impact of left lobe graft. *Transplantation*. 2009;87(3):445–450.
9. Botha JF, Langnas AN, Campos BD, et al. Left lobe adult-to-adult living donor liver transplantation: small grafts and hemiportalocaval shunts in the prevention of small-for-size syndrome. *Liver Transpl*. 2010; 16(5):649–657.
10. Soejima Y, Taketomi A, Yoshizumi T, et al. Biliary strictures in living donor liver transplantation: incidence, management, and technical evolution. *Liver Transpl*. 2006;12(6):979–986.
11. Halazun KJ, Przybylski EM, Griesemer AD, et al. Leaning to the Left: Increasing the Donor Pool by Using the Left Lobe, Outcomes of the Largest Single-center North American Experience of Left Lobe Adult-to-adult Living Donor Liver Transplantation. *Ann Surg*. 2016; 264(3):448–456.
12. Lee HW, Shah NH, Lee SK. An Update on Endoscopic Management of Post-Liver Transplant Biliary Complications. *Clin Endosc*. 2017; 50(5):451–463.

13. Shin M, Joh JW. Advances in endoscopic management of biliary complications after living donor liver transplantation: Comprehensive review of the literature. *World J Gastroenterol*. 2016;22(27):6173.
14. Hsieh TH, Mekeel KL, Crowell MD, et al. Endoscopic treatment of anastomotic biliary strictures after living donor liver transplantation: outcomes after maximal stent therapy. *Gastrointest Endosc*. 2013; 77(1):47–54.
15. Gómez CM, Dumonceau JM, Marcolongo M, et al. Endoscopic management of biliary complications after adult living-donor versus deceased-donor liver transplantation. *Transplantation*. 2009;88(11):280–285.
16. Chan CH, Donnellan F, Byrne MF, et al. Response to endoscopic therapy for biliary anastomotic strictures in deceased versus living donor liver transplantation. *Hepatobiliary Pancreat Dis Int*. 2013;12(5):488–493.
17. Nakaseko Y, Shiba H, Yamanouchi E, et al. Successful Treatment of Stricture of Duct-to-Duct Biliary Anastomosis After Living-Donor Liver Transplantation of the Left Lobe: A Case Report. *Transplant Proc*. 2017;49(7):1644–1648.
18. Greif F, Bronsther OL, van Thiel DH, et al. The incidence, timing, and management of biliary tract complications after orthotopic liver transplantation. *Ann Surg*. 1994;219(1):40–45.
19. Kochhar G, Parungao JM, Hanounah IA, Parsi MA. Biliary complications following liver transplantation. *World J Gastroenterol*. 2013; 19(19):2841–2846.
20. Dumonceau JM, Tringali A, Blero D, et al. Biliary stenting: indications, choice of stents and results: European Society of Gastrointestinal Endoscopy (ESGE) clinical guideline. *Endoscopy*. 2012;44(3):277–298.
21. Wadhawan M, Kumar A, Gupta S, et al. Post-transplant biliary complications: an analysis from a predominantly living donor liver transplant center. *J Gastroenterol Hepatol*. 2013;28(6):1056–1060.
22. Elwir S, Thompson J, Amateau SK, et al. Endoscopic Management of Biliary Leaks and Strictures After Living Donor Liver Transplantation: Optimizing Techniques for Successful Management. *Dig Dis Sci*. 2017;62(1):244–252.
23. Chok KS, Chan AC, Sharr WW, et al. Outcomes of endo-radiological approach to management of bile leakage after right lobe living donor liver transplantation. *J Gastroenterol Hepatol*. 2016;31(1): 190–193.
24. Akamatsu N, Sugawara Y, Hashimoto D. Biliary reconstruction, its complications and management of biliary complications after adult liver transplantation: a systematic review of the incidence, risk factors and outcome. *Transpl Int*. 2011;24(4):379–392.
25. Seven G, Çınar K, Idilman R, et al. Endoscopic treatment of biliary complications following liver transplantation. *Turk J Gastroenterol*. 2014;25(2):156–161.
26. Kim PT, Marquez M, Jung J, et al. Long-term follow-up of biliary complications after adult right-lobe living donor liver transplantation. *Clin Transplant*. 2015;29(5):465–474.
27. Kim JH, Ko GY, Sung KB, et al. Bile leak following living donor liver transplantation: clinical efficacy of percutaneous transhepatic treatment. *Liver Transpl*. 2008;14(8):1142–1149.
28. Popescu I, Sheiner P, Mor E, et al. Biliary complications in 400 cases of liver transplantation. *Mt Sinai J Med*. 1994;61(1):57–62.

Therapeutics and Clinical Risk Management

Publish your work in this journal

Therapeutics and Clinical Risk Management is an international, peer-reviewed journal of clinical therapeutics and risk management, focusing on concise rapid reporting of clinical studies in all therapeutic areas, outcomes, safety, and programs for the effective, safe, and sustained use of medicines. This journal is indexed on PubMed Central, CAS,

Submit your manuscript here: <http://www.dovepress.com/therapeutics-and-clinical-risk-management-journal>

EMBASE, Scopus and the Elsevier Bibliographic databases. The manuscript management system is completely online and includes a very quick and fair peer-review system, which is all easy to use. Visit <http://www.dovepress.com/testimonials.php> to read real quotes from published authors.

Dovepress