

Accuracy of fetal anatomy survey in the diagnosis of velamentous cord insertion: a case–control study

This article was published in the following Dove Medical Press journal:
International Journal of Women's Health

William M Curtin^{1,2}
Jennifer M Hill^{3,4}
Karmaine A Millington²
Odessa P Hamidi⁵
Stephen S Rasiah⁵
Serdar H Ural^{1,6}

¹Division of Maternal-Fetal Medicine, Department of Obstetrics & Gynecology, Pennsylvania State University College of Medicine, Hershey, PA, USA; ²Department of Pathology & Laboratory Medicine, Pennsylvania State University College of Medicine, Hershey, PA, USA; ³Pennsylvania State University College of Medicine, Hershey, PA, USA; ⁴Department of Obstetrics & Gynecology, St Francis Hospital and Medical Center, Hartford, CT, USA; ⁵Department of Obstetrics & Gynecology, Pennsylvania State University College of Medicine, Hershey, PA, USA; ⁶Department of Radiology, Pennsylvania State University College of Medicine, Hershey, PA, USA

Objective: Our objective was to determine the accuracy of ultrasound at the time of the fetal anatomy survey in the diagnosis of velamentous cord insertion (VCI).

Study design: This retrospective case–control study identified placentas with VCI (cases) and randomly selected placentas with normal placental cord insertion (PCI) (controls) as documented by placental pathology for mothers delivered from 2002 through 2015. Archived ultrasound images for PCI at the time of the fetal anatomy survey were reviewed. Data analysis was by calculation of sensitivity, specificity, and accuracy and their 95% CI for the ultrasound diagnosis of VCI.

Results: The prevalence of VCI was 1.6% of placentas submitted for pathologic examination. There were 122 cases of VCI and 347 controls with normal PCI. The performance criteria calculated for the diagnosis of VCI at the time of fetal anatomy survey were as follows: sensitivity 33.6%; 95% CI: 25.3, 42.7; specificity 99.7%; 95% CI: 98.4, 99.9 and accuracy 82.5; 95% CI: 80.5, 82.9.

Conclusion: The identification of a VCI at the time of fetal anatomy survey is highly specific for the presence of a VCI as documented by placental pathology. The sensitivity in this study was less than expected. Sensitivity could be improved by reducing the number of nonvisualized PCIs, creating an awareness of risk factors for VCI, and obtaining more detailed images in the case of an apparent marginal PCI.

Keywords: velamentous, placental cord insertion, placental pathology, sensitivity, specificity, accuracy

Introduction

A velamentous cord insertion (VCI) is one in which the umbilical cord inserts into the fetal membranes, rather than directly on the placental disk, causing the umbilical arteries and vein to travel unprotected for varying distances before reaching the placenta. It has been identified in ~1.5% of singleton deliveries when the gross examination is performed by an obstetrician or midwife at the time of delivery.¹ The frequency of VCI is much higher in multiple gestations, with a prevalence of 7.6%, 34.7%, and 28.2% in dichorionic twins, monochorionic twins, and triplet pregnancies, respectively.^{2,3}

VCI is associated with both perinatal and maternal morbidity. A VCI coursing over the internal cervical os, vasa previa, estimated to occur in 1 in 50 VCIs, can lead to fetal exsanguination.⁴ There are increased risks for preterm delivery, small for gestational age (SGA) infants, manual removal of the placenta, postpartum hemorrhage, and intrauterine fetal demise.^{1,5,6} There are also associations with birth

Correspondence: William M Curtin
Division of Maternal-Fetal Medicine,
Department of Obstetrics & Gynecology,
Pennsylvania State University College
of Medicine, 500 University Dr.,
PO Box 850, Penn State Milton S.
Hershey Medical Center, Hershey,
PA 17033-0850, USA
Tel +1 717 531 8142
Fax +1 717 531 0947
Email wcurtin@pennstatehealth.psu.edu

defects, placenta previa, and single umbilical artery (SUA).^{6–8} These risks highlight the importance of identifying the VCI in the antepartum period.

Ultrasound detects VCI with variable success. In one prospective study of 832 women referred to ultrasound ≥ 16 weeks, the placental cord insertion (PCI) was able to be identified in 825; 8 VCIs were identified and of these 7 proved to have a VCI at delivery.⁹ In another prospective study, Hasegawa et al¹⁰ identified 25 out of 40 VCIs (sensitivity 62.5%) among 3,446 routine ultrasounds performed at 18–20-week gestation with no false positives. In our maternal-fetal medicine unit PCI identification is a routine part of every fetal anatomy survey; thus, a large number of archived images are available for ultrasound and placental pathology correlation. We chose to study the accuracy of ultrasound for the diagnosis of VCI in a retrospective case–control study of placentas that had been previously submitted for examination to pathology where the site of the PCI was well documented. This design differs from prospective studies but was necessary as clinician-performed gross placental examination is not done with sufficient detail nor reliably and consistently documented at our institution. VCI recorded at the time of pathologic examination of the placenta was considered the gold standard and this would also allow us to obtain a large sample of VCIs to study. We hypothesized, based on the studies referenced above and our own clinical experience, that fetal anatomy survey would have high specificity but lower sensitivity for the diagnosis of VCI.

Methods

This was a retrospective case–control study of placentas submitted for pathologic examination. The study was approved by the Research Subjects Review Board at the Penn State Milton S Hershey Medical Center (IRB protocol no. 43017EP). A waiver of informed consent was granted, in accordance with U.S. Federal regulation 45 CFR Part 46.116(d): the research involved minimal risk to subjects; the waiver would not adversely affect the rights and welfare of the subjects; the research could not practically be carried out without the waiver. A waiver was granted for authorization to access protected health information, in accordance with U.S. Federal regulation 45 CFR Part 164. These waivers were in accordance with the Declaration of Helsinki document on human research ethics. The gold standard for VCI diagnosis was placental pathology. The study began with the identification of the cases, VCI group, recorded on the pathology report from placentas examined from deliveries between 2002 and 2015 at Milton S. Hershey Medical Center. The indication

for pathologic placental examination was at the obstetrician's discretion, which in general followed established guidelines.¹¹ Briefly, these are College of American Pathologists' guidelines that list indications for placental examination in three broad categories: maternal, fetal/neonatal, and placental. Preeclampsia, multiple gestation, and VCI, as examples, would fall into the categories of maternal, fetal, and placental indications, respectively, for examination of the placenta. The obstetrician-recorded indication on the pathology report was categorized into maternal, fetal/neonatal, placenta, or other, if it did not meet the three criteria for examination, for each patient. Pregnancies that have pathologic examination at our institution are predominantly those that are classified as high risk; every placenta is not submitted for evaluation. Historically, at Penn State Milton S Hershey Medical Center 40%–50% of all placentas have a pathologic examination. Placental examination search was performed with the use of Cerner CoPath Plus Anatomic Pathology (Cerner, Kansas City, MO, USA). The controls, the normal PCI group, were selected randomly during the same time period. We extracted all placental report requisition numbers in the pathology database from 2002 to 2015 into a numbered spread sheet followed by the use of a random number generator to select the normal PCI group. We evaluated the placental pathology report's gross description section for a thorough documentation of PCI. A cord insertion directly onto the placental disk and >1 cm from the nearest placental edge was considered a normal PCI and classified into the normal PCI group. A clear description of the umbilical cord insertion site off of the placental disk and into the fetal membranes qualified as a VCI, and the distance the cord inserted off of the placental disk in centimeters was also sought, when available, but an exact measurement was not required for a diagnosis. Cord insertions described as marginal on gross pathology of the placenta were excluded from the study. Also excluded were cases and controls with no archived ultrasound studies available for review. We ultimately chose to exclude multiple gestations from the final analysis.

Ultrasound images and reports were accessed through the Philips IntelliSpace PACS Enterprise (Koninklijke Philips NV, Amsterdam, the Netherlands). Clinical data were extracted through the use of the electronic medical record, Cerner Millennium (Cerner Health Systems, Malvern, PA, USA). Ultrasound identification of the PCI at the fetal anatomic survey was performed with 2–5 MHz curvilinear transducers using the Philips iU22 or EPIQ machines (Koninklijke Philips NV). All ultrasounds were performed by experienced sonographers in maternal-fetal

medicine. Identification and imaging of the PCI were part of all fetal anatomy surveys regardless of whether they were for routine screening or a detailed, also referred to as targeted, examination. Images were acquired in sagittal and transverse planes with the aid of color flow Doppler. All images were reviewed by two of the researchers (WMC, JMH). Images showing the insertion of the umbilical cord beyond the placental edge and into the extraplacental membranes verified the diagnosis of VCI. We measured the distance off the placental disk where possible. Images showing the PCI >1 cm from the placental edge were designated normal PCI and images showing the PCI ≤1 cm from the placental edge but still on the placental disk were designated as marginal PCI.¹² Representative examples are given in Figures 1A, B and 2. If there was a follow-up ultrasound study where the PCI was subsequently visualized that had not been visualized at the prior fetal anatomy survey this was included in the data. It was not the usual practice to reimagine the PCI on subsequent studies if it had already been identified. Studies where the umbilical cord was not imaged were considered indeterminate.

Maternal variables collected included age, parity, race/ethnicity, assisted reproduction, smoking, diabetes, hypertension, and antepartum bleeding after the first trimester. Additional ultrasound variables collected included gestational age at the time of anatomy survey or follow-up study that subsequently successfully imaged the cord, and placental location. Intrapartum variables collected included the occurrence of abnormal fetal heart rate patterns, retained placenta, gestational age, and mode of delivery. Birth information collected included livebirth/stillbirth, birth weight, SGA (<10th

percentile for gestational age), Apgar scores, and the presence of major birth defects. We recorded the presence of a SUA noted on the placental examination.

Data were analyzed between cases and controls by Student's *t*-tests for independent comparisons, chi-square tests, OR with 95% CI as appropriate. Statistical analysis was performed using SPSS (Chicago, IL, USA). Significance was set at $P < 0.05$. Multivariate analyses were performed where applicable. The sensitivity, specificity, and accuracy with their 95% CIs were calculated for ultrasound as a diagnostic test for the detection of VCI using placental pathology as the gold standard. We used the Standards for Reporting of Diagnostic Accuracy (STARD) checklist guidelines for the study.¹³ Using the data from Hasegawa et al¹⁰ we hypothesized sensitivity around 63%. We hypothesized a specificity of 90%. We used the tables reported by Flahault et al¹⁴ for sample size calculation in diagnostic studies. According to these tables a hypothesized sensitivity of 65% with a lower 95% CI of 50% required 119 VCIs; a hypothesized specificity of 91% with a lower 95% CI of 85% required 319 normal PCIs. We planned to have two normal PCIs for each VCI.

Results

The prevalence of VCI among pathologically examined placentas, including multiple gestations, at our institution was ~186/11,618 (1.6%). There were seven cases of vasa previa (3.8%) among the VCIs. The selection of cases and controls is given in Figure 3. Overall there were 469 study subjects consisting of 122 singleton pregnancies with VCI (cases) and 347 singleton pregnancies with normal PCI (controls). Indications recorded for placental examination in

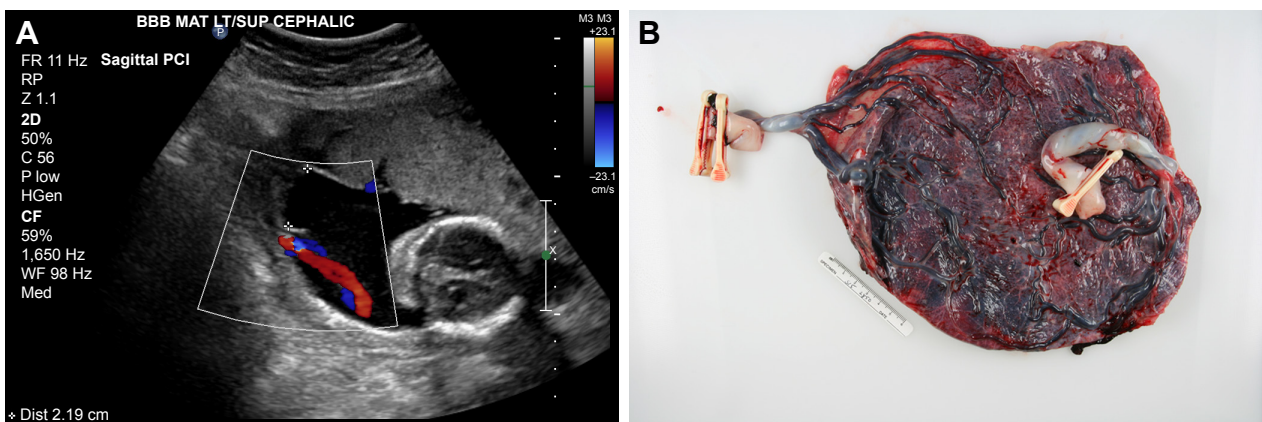


Figure 1 (A) Color flow Doppler ultrasound showing velamentous umbilical cord inserting into fetal membranes, 2.19 cm off of placental disk for twin B in a monozygotic, diamniotic twin pregnancy identified at 20-week gestation. (B) Delivered monozygotic, diamniotic twin placenta at 30 weeks from same pregnancy as (A). There is a velamentous insertion of the umbilical cord for twin B (two clamps). Note the division of cord vessels within the fetal membranes and before they join the placental disk at multiple sites along the margin; insufficient imaging can confuse these vessels with a marginal cord insertion. The umbilical cord insertion site of twin A (one clamp) is inserted at the margin of the disk. This pregnancy was complicated by late-onset twin-to-twin transfusion syndrome with twin B, the donor, and twin A, the recipient.

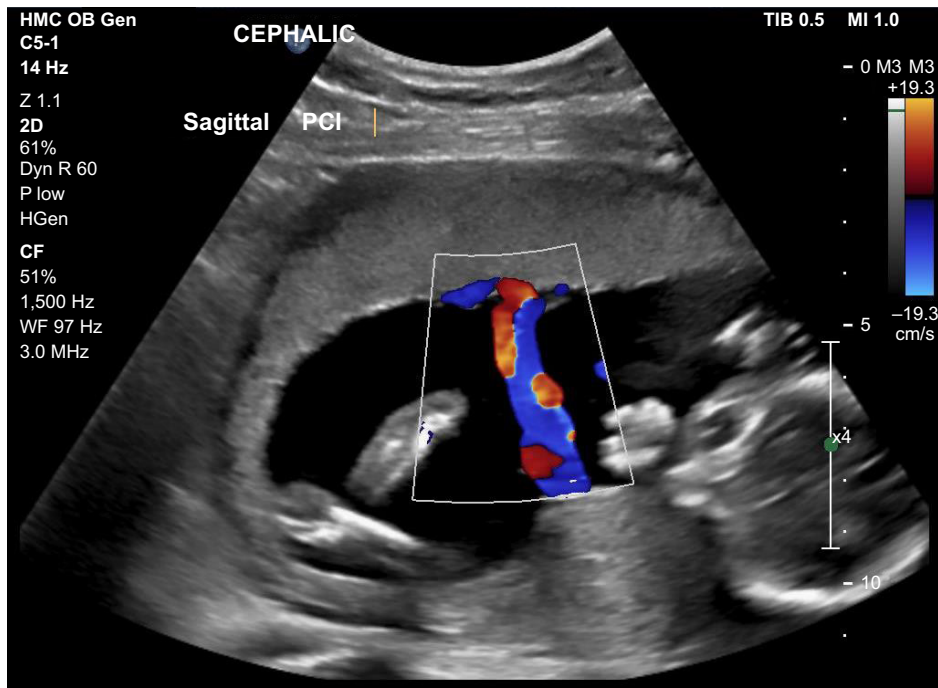


Figure 2 Color flow Doppler ultrasound from singleton pregnancy during a routine fetal anatomy survey showing the PCI to be centrally located on the placental disk. **Abbreviation:** PCI, placental cord insertion.

the 122 case mothers were as follows: 48 (39.3%) maternal, 23 (18.9%) fetal/neonatal, 46 (62.2%) placental, and other 5 (4.1%). Indications recorded for placental examination in the 347 control mothers fell into the following categories: 231 (66.2%) maternal, 68 (19.6%) fetal/neonatal, 28 (8.1%) placenta, and other 20 (5.8%), $P < 0.001$ for all. Maternal

comparisons of the VCI and the control groups are given in Table 1. The VCI group delivered at a lower mean gestational age and was more likely to be preterm. Pregnancies in the VCI group were more likely to have been conceived by assisted reproduction, to have had vaginal bleeding beyond the first trimester and a retained placenta. VCI was not significantly

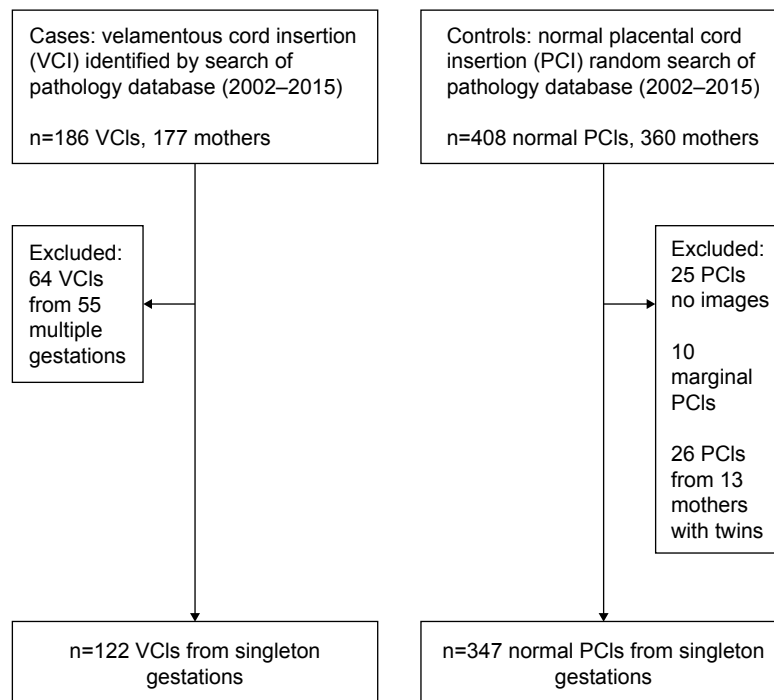


Figure 3 Flow diagram of study inclusion.

Table 1 VCI vs normal PCI, pregnancy comparisons

Variables ^a	VCI N=122	Normal PCI N=347	OR (95% CI)	P-value
Maternal age (years)	29.05±6.23	28.55±6.29		0.450
Gestational age at delivery (weeks)	36.61±3.74	37.52±3.25		<0.001
Preterm delivery (<37 weeks)	47 (38.5)	80 (23.1)	2.09 (1.31, 3.33)	0.001
Parity ≥ 1	65 (53.3)	170 (49.0)	1.89 (0.77, 1.83)	0.415
Smoking	21 (17.2)	52 (15.0)	1.18 (0.65, 2.12)	0.559
Caucasian	104 (85.2)	289 (83.3)	1.16 (0.63, 2.15)	0.613
Assisted reproduction	11 (9.0)	5 (1.4%)	6.72 (2.12, 22.93)	<0.001
Abnormal intrapartum FHR	16 (13.1)	50 (14.4)	0.90 (0.47, 1.70)	0.724
Bleeding after first trimester	21 (17.2)	6 (1.7)	11.82 (4.36, 33.7)	<0.001
Cesarean section	61 (50.0)	159 (45.8)	1.18 (0.77, 1.83)	0.426
Hypertension	29 (23.8)	95 (27.4)	0.83 (0.50, 1.37)	0.437
Diabetes	7 (5.7)	31 (8.9)	0.62 (0.24, 1.53)	0.266
Retained placenta	18 (14.8)	7 (2.0)	8.41 (3.2, 22.9)	<0.001

Note: ^aResults expressed in mean ± SD or number (%).

Abbreviations: FHR, fetal heart rate; PCI, placental cord insertion; VCI, velamentous cord insertion.

associated with preterm delivery after adjustment for bleeding beyond the second trimester, parity, smoking, hypertension, diabetes, and race/ethnicity (adjusted OR 1.34; 95% CI: 0.80, 2.22). The cesarean section rate was high among both groups, which is much higher than our institution's overall rate. This finding reflects that placentas submitted to pathology tend to be from high-risk pregnancies, which have already high cesarean section rates, and that physicians may be more likely to submit placentas for examination from cesarean deliveries than vaginal deliveries.¹⁵

Newborn and placental data for the two groups are given in Table 2. Birth weights were lower in the VCI group but the infants were not more likely to be SGA. There was a higher incidence of birth defects in the VCI group. Information regarding the distance of the cord insertion off the placental disk, as recorded at the time of placental examination, was recorded for 80 VCIs, 5.11±3.69 cm.

Table 3 gives the ultrasound data and PCI designation at the time of the fetal anatomic survey. The average gestational

age at the time of the fetal anatomy survey for the VCI group was marginally more than for the normal PCI group. The proportion of placentas noted to be low-lying or placenta previa at the time of the fetal anatomy survey were greater in the VCI group. The VCI group was less likely than the control group to have had successful imaging of the PCI location. The classification of the archived images for the VCI group was as follows: 41 VCI, 24 marginal, 44 normal, and 13 indeterminate. In the control group the classification was as follows: 1 VCI, 6 marginal, 328 normal, and 12 indeterminate. The number of PCIs able to be visualized on the initial fetal anatomy survey and those on a subsequent follow-up scan were as follows: VCI group 98 and 11 and controls 325 and 10 (OR 0.27; 95% CI: 0.10, 0.72). PCIs were not reimaged if they had been successfully identified on the initial fetal anatomy survey. A misclassification of marginal PCI on the fetal anatomy survey was more likely in the VCI group than the normal PCI group (OR 13.92; 95% CI: 5.23, 39.22; *P*<0.001). Overall, ultrasound detected 41 (33.6%)

Table 2 VCI vs normal PCI, neonatal and placental comparisons

Variables ^a	VCI N=122	Normal PCI N=347	OR (95% CI)	P-value
Stillbirth	2 (1.6)	2 (0.6)	2.88 (0.29, 28.9)	0.272
Birth weight (g)	2,776.2±739.7 ^b	3,094.0±756.5		<0.001
SGA	14 (11.6) ^b	27 (7.8)	1.55 (0.74, 3.21)	0.204
Major birth defect	20 (16.4)	30 (8.6)	2.07 (1.88, 3.96)	0.017
Five-minute Apgar <7	8 (6.7)	14 (4.1)	1.69 (0.63, 4.43)	0.247
VCI, distance off placenta (cm) ^c	5.11±3.69			
SUA	6 (4.9)	7 (2.0)	2.51 (0.73, 8.52)	0.093

Note: ^aResults expressed as mean ± SD, number (%); ^bn=121; ^cn=80, distance as recorded at the time of gross placental examination.

Abbreviations: PCI, placental cord insertion; SGA, small for gestational age; SUA, single umbilical artery; VCI, velamentous cord insertion.

Table 3 Characteristics of umbilical cord identification at the time of fetal anatomy survey

Variables ^a	VCI N=122	Normal PCI N=347	OR (95% CI)	P-value
Gestational age at US	22.50±4.99	21.20±5.4		0.016
Low-lying placenta or placenta previa	16 (13.1)	22 (6.3)	2.23 (1.07, 4.62)	0.018
PCI visualized on archived images	109 (89.3)	335 (96.5)	0.30 (0.12, 0.73)	0.004
VCI by US	41 (33.6)	1 (0.3)	175.1 (25.6, 3,477.0)	<0.001
VCI, distance off placenta (cm) ^b	3.13±1.58			

Note: ^aResults expressed as mean ± SD, number (%); ^bn=43, distance able to be measured from images.

Abbreviations: PCI, placental cord insertion; US, ultrasound; VCI, velamentous cord insertion.

of 122 VCIs. There was one false-positive VCI among the normal PCIs. We measured the distance of the cord insert off the placental disk for the 43 VCIs that were observed on ultrasound, 3.13±1.58 cm. Of the 28 cases that had both an ultrasound measurement and a placental measurement of this distance the correlation was $r_s=0.455$, $P=0.015$.

Table 4 gives the performance characteristics of ultrasound at the time of the fetal anatomy survey for the diagnosis of VCI on placental examination. The sensitivity of the identification of a VCI at the time of fetal anatomy survey is limited but the specificity is high. Overall, the location of the PCI is correctly classified 82.5% of the time. The adjusted positive predictive and negative predictive values were calculated based on a 1.6% population prevalence of VCI.

Discussion

VCI is an abnormal PCI that can be identified at the time of the fetal anatomy survey. In this retrospective case-control study, where PCI was a routine part of the fetal anatomy survey, the detection rate of VCI was 33.6%. This is significantly lower than expected based on previous prospective studies specifically targeting the PCI that report 60%–90% sensitivity.^{9,10} The reason for the discrepancy of the results between ours and that of the others is likely related to the latter's prospective design specifically focusing on the PCI, the limited numbers of VCIs, and the relatively short time periods (8–24 months) of the studies. One study¹⁰ utilized physicians in the technical performance of the ultrasound. We do not feel that our results represent a lack of technical ability on the part of our sonographers. Our reported sensitivity may represent a more realistic value when the PCI is attempted

to be visualized in the context of a fetal anatomy survey, where the PCI is just one item in a number of structures to be visualized, with limited time for the overall examination. Guidelines for identification of the PCI on fetal anatomy survey have changed over time. The American Institute of Ultrasound in Medicine (AIUM) document, *Guidelines for the Performance of Obstetric Ultrasounds*, recommended identification of PCI when technically feasible for the standard fetal examination in the second and third trimesters.¹⁶ Eddleman et al¹⁷ found that routine nontargeted ultrasound detected none of their 82 cases of VCI at delivery in a four-year period. More recent guidelines from the AIUM recommend identification of the PCI, when possible, on the basic fetal anatomy survey, and PCI identification is now considered to be an integral component of the detailed (targeted) fetal anatomy survey.¹⁸ The number of VCI cases identified subsequent to publication of the 2014 AIUM guidelines was small. Although the detection of VCI after the 2014 AIUM guidelines was higher, the results were not significant, 7/16 (44%) vs 36/105 (34%) ($P=0.461$).

VCI is associated with adverse fetal outcomes; therefore, its antenatal identification could be useful for identification of risk, management of the pregnancy, and timing and conduct of delivery. We found an association of VCI with birth defects in our study. One population-based study showed an increased risk for birth defects with VCI.⁶ We noted an increased frequency of retained placentas in the VCI group. This happens most likely because of cord avulsion and may be able to be prevented by limited use of cord traction to deliver the placenta. Others have noted the increased rate of manual removal of the placenta, as well as an increased frequency of postpartum hemorrhage.^{5,19}

Table 4 Performance characteristics of fetal anatomy survey in the diagnosis of VCI

	Sensitivity	Specificity	PPV ^b	NPV ^b	Accuracy
VCI visualized on US ^a	33.6 (25.3, 42.7)	99.7 (98.4, 99.9)	64.6 (54.9, 73.2)	98.9 (98.8, 99.0)	82.5 (80.5, 82.9)

Note: ^aResults expressed in % (95% CI); ^bresults adjusted for a population prevalence of 1.6%.

Abbreviations: NPV, negative predictive value; PPV, positive predictive value; US, ultrasound; VCI, velamentous cord insertion.

Antenatal detection of VCI is a worthy endeavor as it has the potential to reduce adverse fetal outcomes. Guidelines recommending the identification of the PCI at the time of all fetal anatomy surveys, whether basic or detailed, may increase the detection of VCI overall. It does appear that there is zero to coincidental detection of the VCI when the PCI is not part of routine screening.^{17,20} In our study, even with the intent of identifying the PCI, the sensitivity of ultrasound was low; however, the specificity was high. Efforts to improve the detection rate of VCI with routine screening could consist of, first, identifying known risk factors for VCI and second, getting more detailed images when a marginal cord insertion is identified. Multiple gestations and in particular monochorionic placentation have high rates of VCI.^{2,6} Other risk factors for VCI that we identified in the antenatal period that, if known at the time of the ultrasound, could direct more attention to the PCI are assisted reproduction, bleeding after the first trimester, and failure to identify the PCI. Associations between VCI and assisted reproduction and bleeding during pregnancy have been previously reported.⁶ The sensitivity of ultrasound for diagnosis of VCI might be improved if further attention is given to imaging in the case of a marginal PCI. The VCI has a fixed insertion into the fetal membrane, and the arteries and veins ramify within the membranes, eventually entering or leaving the placental disk at the margin, which is also fixed. These velamentous branching vessels at the margin of the disk may be mistaken for a marginal cord insertion. Ideally, when a marginal cord insertion is identified the vessels should be followed off the disk until they clearly join the portion of the umbilical cord that floats freely in the amniotic fluid to exclude the presence of a VCI. Kuwata et al²¹ made an analogy to a mangrove tree, where the trunk of the tree (umbilical cord) is connected to the roots located above ground (velamentous vessels) before they finally enter the soil (placental disk). They called this the “mangrove sign” and provided color Doppler and gross images of the VCI aside an image of a mangrove tree to illustrate their point. Regardless of whether a PCI has a velamentous or marginal insertion, they have a similar risk of adverse perinatal outcomes, albeit to a lesser degree in the case of a marginal insertion, so the ultrasound identification of either prior to delivery would be clinically relevant.⁶

There are two theories on how a VCI develops: 1) primary abnormal implantation or polarity theory – with implantation of the blastocyst, the embryonic pole is oriented away from the endometrium and the cord insertion occurs in what ultimately becomes the chorion laeve; or 2) trophotropism – the implantation site is unfavorable, for example, a placenta

previa, the placenta atrophies at one pole and if the umbilical cord had inserted there it then becomes velamentous.²² The findings we observed of more frequent low-lying placental locations at the time of the fetal anatomy survey and the occurrence of bleeding beyond the first trimester lend support to the theory of trophotropism in the genesis of VCI, whereas the higher frequency of assisted reproduction may support the polarity theory.

Strengths and limitations

The strength of the study was the large numbers of VCIs present that were documented by placental pathology over a number of years. We had a large archive of placental images for correlation with placental pathology. This study may more closely simulate what results would be obtained in a busy ultrasound practice where the PCI is one component, among many, of a fetal anatomy survey. The weaknesses of the study were the usual biases present in retrospective studies, lack of blinding of the ultrasound study reviewers, and only having placentas that underwent pathologic examination, as this group would tend to be a high-risk group. Although ideally it may have been preferable to have had a complete gross description of the placenta and the PCI at the time of deliveries for all deliveries, this data is not routinely collected nor reported upon in a consistent manner at our institution. We also chose to calculate the sensitivity and specificity of ultrasound for VCI without dropping out the cases where the location of the PCI was indeterminate from the images that were archived. This could be perceived as inappropriately lowering the diagnostic ability of ultrasound since in strictest terms this is not a missed diagnosis; however, nonvisualization of the PCI is almost fourfold more likely with a VCI in comparison to a normal PCI and may be an important clue in the diagnosis.

Conclusion

VCI occurred in ~1.6% of all placentas submitted for pathologic examination at our institution. VCI was associated with perinatal and maternal morbidity; thus, its antenatal detection is important. The identification of a VCI at the time of fetal anatomy has high specificity (99.7%) for the presence of VCI at delivery. The sensitivity of fetal anatomy survey for VCI in our study was less than expected (33.6%) and represents an opportunity for improvement. Awareness of risk factors for VCI, such as multiple gestation and assisted reproduction, decreasing the incidence of nonvisualized PCIs, and allowing more technical time in distinguishing a marginal PCI from a VCI, may increase the frequency of antenatal diagnosis and mitigate the associated morbidity.

Disclosure

The authors report no conflicts of interest in this work.

References

- Ebbing C, Johnsen SL, Albrechtsen S, Sunde ID, Vekseth C, Rasmussen S. Velamentous or marginal cord insertion and the risk of spontaneous preterm birth, prelabor rupture of the membranes, and anomalous cord length, a population-based study. *Acta Obstet Gynecol Scand.* 2017;96(1):78–85.
- Costa-Castro T, Zhao DP, Lipa M, et al. Velamentous cord insertion in dichorionic and monochorionic twin pregnancies – does it make a difference? *Placenta.* 2016;42:87–92.
- Feldman DM, Borgida AF, Trymbulak WP, Barsoom MJ, Sanders MM, Rodis JF. Clinical implications of velamentous cord insertion in triplet gestations. *Am J Obstet Gynecol.* 2002;186(4):809–811.
- Quek SP, Tan KL. Vasa praevia. *Aust N Z J Obstet Gynaecol.* 1972; 12(3):206–209.
- Esakoff TF, Cheng YW, Snowden JM, Tran SH, Shaffer BL, Caughey AB. Velamentous cord insertion: is it associated with adverse perinatal outcomes? *J Matern Fetal Neonatal Med.* 2015;28(4):409–412.
- Ebbing C, Kiserud T, Johnsen SL, Albrechtsen S, Rasmussen S. Prevalence, risk factors and outcomes of velamentous and marginal cord insertions: a population-based study of 634,741 pregnancies. *PLoS One.* 2013;8(7):e70380.
- Albalawi A, Brancusi F, Askin F, et al. Placental characteristics of fetuses with congenital heart disease. *J Ultrasound Med.* 2017;36(5):965–972.
- Suzuki S, Kato M. Clinical significance of pregnancies complicated by velamentous umbilical cord insertion associated with other umbilical cord/placental abnormalities. *J Clin Med Res.* 2015;7(11):853–856.
- Sepulveda W, Rojas I, Robert JA, Schnapp C, Alcalde JL. Prenatal detection of velamentous insertion of the umbilical cord: a prospective color Doppler ultrasound study. *Ultrasound Obstet Gynecol.* 2003; 21(6):564–569.
- Hasegawa J, Matsuoka R, Ichizuka K, Sekizawa A, Farina A, Okai T. Velamentous cord insertion into the lower third of the uterus is associated with intrapartum fetal heart rate abnormalities. *Ultrasound Obstet Gynecol.* 2006;27(4):425–429.
- Langston C, Kaplan C, Macpherson T, et al. Practice guideline for examination of the placenta: developed by the Placental Pathology Practice Guideline Development Task Force of the College of American Pathologists. *Arch Pathol Lab Med.* 1997;121(5):449–476.
- di Salvo DN, Benson CB, Laing FC, Brown DL, Frates MC, Doubilet PM. Sonographic evaluation of the placental cord insertion site. *AJR Am J Roentgenol.* 1998;170(5):1295–1298.
- Bossuyt PM, Reitsma JB, Bruns DE, et al. Towards complete and accurate reporting of studies of diagnostic accuracy: the STARD initiative. *BMJ.* 2003;326(7379):41–44.
- Flahault A, Cadilhac M, Thomas G. Sample size calculation should be performed for design accuracy in diagnostic test studies. *J Clin Epidemiol.* 2005;58(8):859–862.
- Curtin WM, Krauss S, Metlay LA, Katzman PJ. Pathologic examination of the placenta and observed practice. *Obstet Gynecol.* 2007;109(1): 35–41.
- American Institute of Ultrasound in Medicine. AIUM practice guideline for the performance of obstetric ultrasound examinations. *J Ultrasound Med.* 2013;32(6):1083–1101.
- Eddleman K, Lockwood C, Berkowitz G, Lapinski R, Berkowitz R. Clinical significance and sonographic diagnosis of velamentous umbilical cord insertion. *Am J Perinatol.* 1992;9(2):123–126.
- Wax J, Minkoff H, Johnson A, et al. Consensus report on the detailed fetal anatomic ultrasound examination: indications, components, and qualifications. *J Ultrasound Med.* 2014;33(2):189–195.
- Ebbing C, Kiserud T, Johnsen SL, Albrechtsen S, Rasmussen S. Third stage of labor risks in velamentous and marginal cord insertion: a population-based study. *Acta Obstet Gynecol Scand.* 2015;94(8): 878–883.
- Yerlikaya G, Pils S, Springer S, Chalubinski K, Ott J. Velamentous cord insertion as a risk factor for obstetric outcome: a retrospective case-control study. *Arch Gynecol Obstet.* 2016;293(5):975–981.
- Kuwata T, Suzuki H, Matsubara S. The “mangrove sign” for velamentous umbilical cord insertion. *Ultrasound Obstet Gynecol.* 2012;40(2): 241–242.
- Benirschke K. Anatomy and pathology of the umbilical cord. In: Benirschke K, Burton GJ, Baergen RN, editors. *Pathology of the Human Placenta.* 6th ed. Berlin: Springer-Verlag; 2012:332–336.

International Journal of Women's Health

Publish your work in this journal

The International Journal of Women's Health is an international, peer-reviewed open-access journal publishing original research, reports, editorials, reviews and commentaries on all aspects of women's healthcare including gynecology, obstetrics, and breast cancer. The manuscript management system is completely online and includes

Submit your manuscript here: <http://www.dovepress.com/international-journal-of-womens-health-journal>

Dovepress

a very quick and fair peer-review system, which is all easy to use. Visit <http://www.dovepress.com/testimonials.php> to read real quotes from published authors.