

# Differential response to a combination of full-dose osimertinib and crizotinib in a patient with *EGFR*-mutant non-small cell lung cancer and emergent *MET* amplification

Viola W Zhu<sup>1</sup>  
Alexa B Schrock<sup>2</sup>  
Siraj M Ali<sup>2</sup>  
Sai-Hong Ignatius Ou<sup>1</sup>

<sup>1</sup>Chao Family Comprehensive Cancer Center, Division of Hematology/Oncology, Department of Medicine, University of California, Irvine School of Medicine, Orange, CA, USA;

<sup>2</sup>Clinical Development, Foundation Medicine, Inc., Cambridge, MA, USA

**Abstract:** Exploring resistance mechanisms in patients with *EGFR*-mutant non-small-cell lung cancer (NSCLC) upon disease progression on *EGFR* tyrosine kinase inhibitors (TKIs) has been an area of great interest as it may lead to effective next-line treatment strategies. Here we report a case of emergent *MET* amplification detected in a tumor sample from a patient with NSCLC harboring *EGFR* L858R mutation after disease progression on erlotinib. The patient subsequently had a sustained partial response to a combination of full-dose osimertinib and crizotinib with excellent tolerance but eventually had central nervous system (CNS) progression. Comprehensive genomic profiling performed on the resected brain sample continued to demonstrate *MET* amplification as an acquired resistance mechanism. A review of literature shows several groups have utilized similar combination regimens (erlotinib or osimertinib + crizotinib or cabozantinib), albeit with various dosing to target *MET* alterations in patients with *EGFR*-mutant NSCLC. As more actionable resistance mechanisms are identified, we envision combination TKI therapy will be readily adopted in clinical practice. Our case report adds to a growing body of evidence that combination osimertinib and crizotinib should be recommended to *EGFR*-mutant NSCLC patients with emergent *MET* amplification as acquired resistance. More importantly, as crizotinib has limited brain penetration, developing next-generation *MET* inhibitors with better CNS activity is urgently needed.

**Keywords:** resistance, TKI, erlotinib, cabozantinib, CGP, gefitinib

## Introduction

Patients with *EGFR*-mutant non-small-cell lung cancer (NSCLC) derive great benefit from treatment with *EGFR* tyrosine kinase inhibitors (TKIs) but the response is often not long-lasting. Exploring resistance mechanisms has been an area of hot pursuit. In addition to the most common *EGFR* T790M mutation, other mechanisms of acquired resistance include *MET* amplification (5%–20%), *HER2* amplification (5%–13%), *EGFR* amplification (8%), *BRAF* mutations (1%), and so on.<sup>1</sup> Crizotinib, a small molecule TKI against ALK, ROS1, and *MET*, has recently been granted a breakthrough therapy designation by the US Food and Drug Administration for patients with metastatic NSCLC harboring *MET* exon 14 skipping alterations after platinum-based chemotherapy. For patients with *MET*-amplified NSCLC, as well as other tumor types, crizotinib has also been reported to be an effective therapy, demonstrating that *MET*

Correspondence: Viola W Zhu  
Chao Family Comprehensive Cancer Center, Division of Hematology/Oncology, Department of Medicine, University of California, Irvine School of Medicine, 101 The City Dr S, Bldg 56, Room 244, Orange, CA 92868, USA  
Tel +1 714 456 8105  
Fax +1 714 456 6179  
Email zhuvw@uci.edu

amplification is indeed an actionable genomic alteration. Here we report a case of emergent *MET* amplification detected in a tumor sample from a patient with NSCLC harboring EGFR L858R mutation after disease progression on erlotinib. The patient subsequently had a sustained partial response (PR) to a combination of full-dose osimertinib and crizotinib with excellent tolerance but eventually had central nervous system (CNS) progression highlighting the need to develop next-generation MET inhibitors with better CNS activity.

## Case presentation

This is a 55-year-old African-American male never-smoker who was diagnosed with stage IV NSCLC in December 2016 after presenting with self-palpable lymph node in the neck. His disease burden involved a dominant right apex lung mass, bilateral lung nodules, extensive lymphadenopathy, multiple liver lesions, one single bony lesion in the T6 vertebral body, and two brain lesions. He first received one cycle of carboplatin/nab-paclitaxel in January 2017. When comprehensive genomic profiling (CGP) on his lymph node biopsy specimen revealed EGFR L858R mutation and equivocal *EGFR* amplification (7 copies) by Foundation Medicine (Cambridge, MA, USA), his treatment was switched to erlotinib in early February 2017 (Table 1). In the interim, he also received stereotactic radiation to two brain lesions. The patient had a PR to erlotinib, but in July 2017 was found to have a new brain lesion for which he received additional stereotactic radiation while being continued on erlotinib. His scan in September 2017 was concerning for mild disease progression so liquid biopsy was obtained via Guardant360 (Guardant Health, Redwood City, CA, USA)

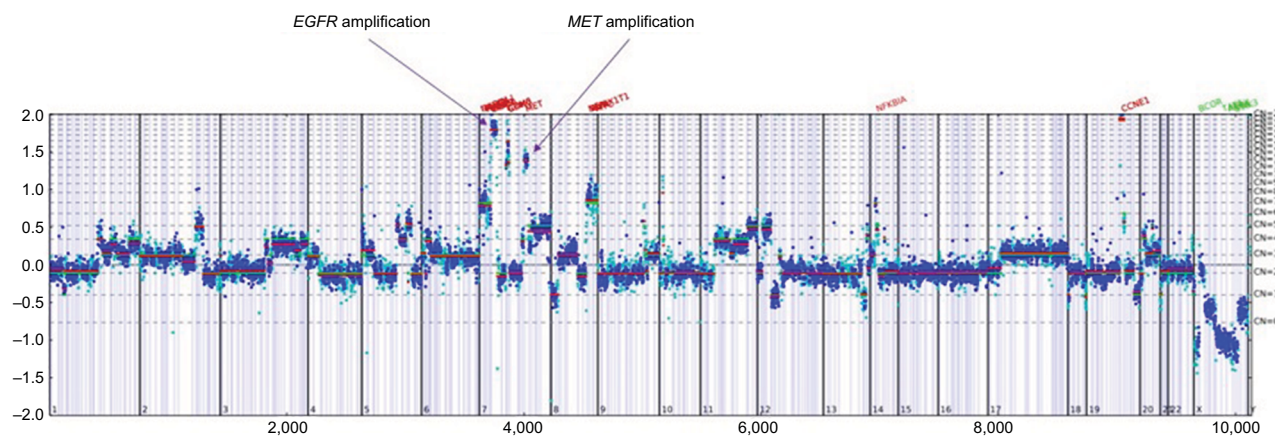
which showed EGFR L858R without T790M mutation. A follow-up scan in November 2017 confirmed disease progression in his lung and liver. He then underwent biopsy of a liver mass and CGP revealed EGFR L858R, *EGFR* amplification (17 copies), *MET* amplification (12 copies), among other non-actionable genomic alterations (Table 1; Figure 1).

The patient subsequently transferred care to us. He had successful microwave ablation of a hepatic lesion at the end of January 2018. For his systemic treatment, erlotinib was switched to a combination of osimertinib and crizotinib in early February 2018 in an attempt to target both *EGFR* and *MET* alterations. We started the patient on 80 mg daily osimertinib and 250 mg daily crizotinib with close monitoring for toxicity. The main reason to choose osimertinib over erlotinib in the absence of T790M mutation is better tolerability of osimertinib particularly when it is combined with another TKI. Ten days later, crizotinib dose was titrated up to 250 mg twice daily given excellent tolerance. Restaging scans around 8 weeks showed interval significant decrease in size of the right apex lung mass and slight decrease in size of a hepatic mass. He had a sustained PR as follow-up scans ~20 weeks later showed further improvement of target lesions (–32% by RECIST 1.1) (Figure 2A–I). However, despite good extracranial response after 28 weeks of combination therapy, the patient experienced CNS progression with increase in size of a pre-existing lesion (Figure 2J and K) and development of three new punctate lesions. He underwent resection of the enlarging brain metastasis (Figure 2L) and CGP performed on this tumor specimen again identified EGFR L858R, *EGFR* amplification (42 copies), and *MET* amplification

**Table 1** List of genomic alterations detected from three different metastatic sites over the clinical course

Timing	Initial diagnosis	Pre-combination therapy	28 Weeks after combination therapy
Specimen site	Lymph node	Liver	Brain
Driver mutations	EGFR L858R <i>EGFR</i> amplification – equivocal (7 copies)	EGFR L858R <i>EGFR</i> amplification (17 copies) <i>MET</i> amplification (12 copies)	EGFR L858R <i>EGFR</i> amplification (42 copies) <i>MET</i> amplification (35 copies)
Associated mutations	<i>CCNE1</i> amplification – equivocal	<i>CDK6</i> amplification <i>MYC</i> amplification – equivocal <i>CCNE1</i> amplification <i>NFKBIA</i> amplification – equivocal	<i>CDK6</i> amplification <i>MYC</i> amplification <i>CCNE1</i> amplification <i>IRS2</i> amplification <i>NFKBIA</i> amplification <i>NKX2-1</i> amplification <i>RAD21</i> amplification
MSI	N/A	Stable	Stable
TMB (Muts/Mb)	3 (low)	4 (low)	10 (intermediate)

**Abbreviations:** MSI, microsatellite instability; Muts/Mb, mutations per megabase; N/A, not available; TMB, tumor mutational burden.



**Figure 1** Copy number plot for the liver biopsy sample tested before combination therapy of osimertinib and crizotinib.

**Notes:** The x-axis shows the target positions (exons); the left y-axis, the log ratio; the right y-axis, gene copy number. Vertical lines indicate divisions between chromosomes (numbered at the lower left corner of each section).

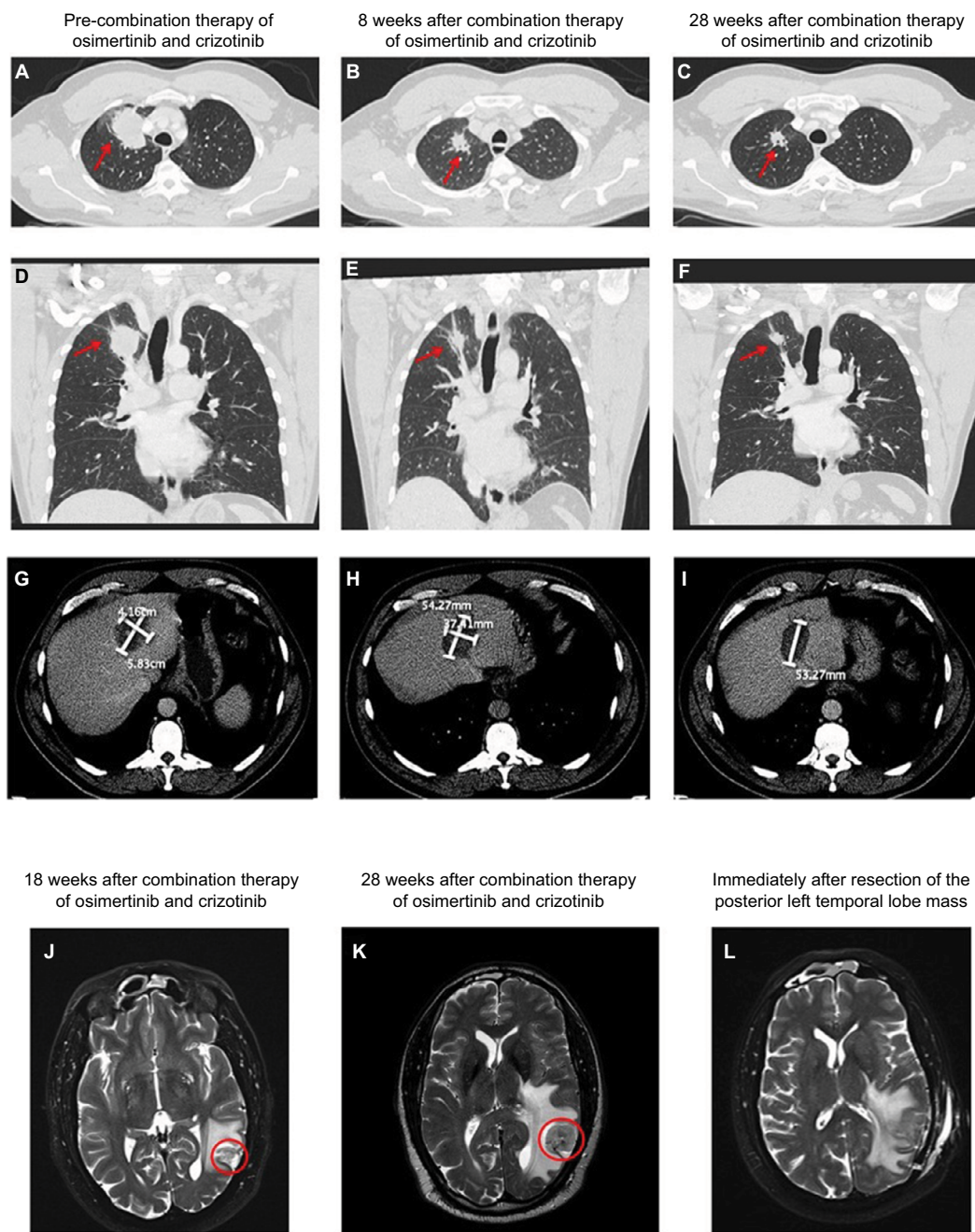
(35 copies) without revealing additional mechanisms of resistance (Table 1). Following resection, the patient received stereotactic radiation to the surgical bed and other untreated brain lesions. He remained on full-dose osimertinib and crizotinib without any toxicity. At the time of this manuscript submission, his combination therapy has been ongoing for 35 weeks. The schematic summary of treatment course is shown in Figure 3. The patient has provided a written informed consent to have the case details published, and institutional approval is not required to publish this case report.

## Discussion

*MET* amplification has been well documented to confer acquired resistance in patients with *EGFR*-mutant NSCLC after progression on various *EGFR* TKIs. Crizotinib has known activity against *MET* amplification. In fact, we have previously reported a case of high *MET* amplification (30 copies) in a patient who progressed on osimertinib and then responded to crizotinib symptomatically.<sup>2</sup> Other agents, such as cabozantinib, capmatinib, emibetuzumab, glesatinib, merestinib, telisotuzumab vedotin, tepotinib, and savolitinib, can also target *MET* amplification. It is worth mentioning that the cutoff for *MET* amplification varies by detection method. Using fluorescent in situ hybridization, a *MET/CEP7* (centromeric enumeration probe for chromosome 7) ratio  $\geq 2$  defines high-level amplification, whereas CGP reports gene copy number per cell  $\geq 6$  as amplification.<sup>3</sup> We have previously investigated focal (<20 megabase pair) vs non-focal *MET* amplification in 545 NSCLC cases and found that focal *MET* amplification was associated with higher *MET* copy number (median 11 vs 7 copies) and lower co-occurrence

of other driver mutations.<sup>4</sup> Whether or not this can serve as a prognostic or predictive biomarker for patients receiving anti-*MET* targeted therapies has yet to be elucidated.

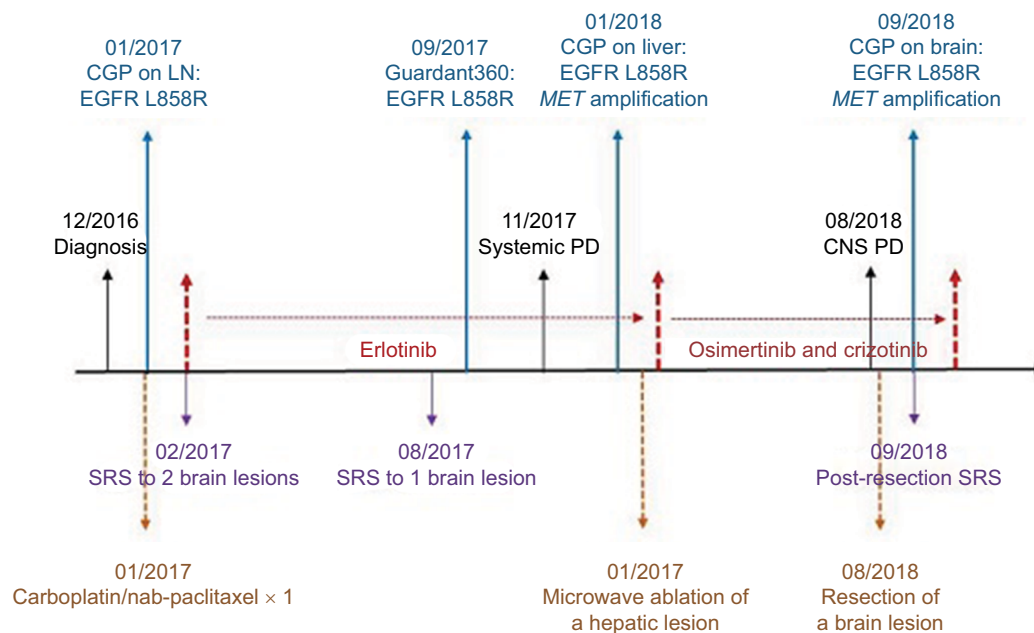
The use of combination TKI therapy to dual-target primary and resistance genomic alterations when patients progress on targeted therapies is emerging in clinical practice. For instance, Scheffler et al successfully treated an NSCLC patient with erlotinib at 100 mg daily in combination with crizotinib at 250 mg twice daily when rebiopsy showed high-level *MET* amplification (*MET/CEP7* ratio: 8.3) emerging in the setting of *EGFR* L858R mutation. The patient had a dramatic response to this combination therapy.<sup>5</sup> Gainor et al reported a NSCLC case with *EGFR* L858R mutation and de novo high-level *MET* amplification (*MET/CEP7* ratio: >15) that was primarily resistant to erlotinib but had an excellent response to the combination of erlotinib at 100 mg daily and crizotinib at 250 mg daily. The lower than standard doses were chosen given concern for increased exposure of erlotinib by crizotinib, and this patient tolerated the treatment well with only grade 1 rash and diarrhea.<sup>6</sup> Li et al also used the same combination therapy to target pre-existing *EGFR* L858R mutation and secondary *MET* amplification in a patient who had progressed on erlotinib. While this patient also had an excellent response, the combination erlotinib at 150 mg daily and crizotinib at 250 mg daily resulted in severe vomiting and rash.<sup>7</sup> Osimertinib is now moving to the front-line setting for metastatic NSCLC patients with activating *EGFR* mutations based on the FLAURA trial showing its superior efficacy and tolerability (lower rates of serious adverse events) to gefitinib or erlotinib. The combination of osimertinib and *MET* inhibitors has proven to be safe and efficacious. This was first



**Figure 2** CT images showing the right apex lung mass before (**A & D**), 8 weeks after (**B & E**), and 28 weeks after (**C & F**) combination therapy of osimertinib and crizotinib. The red arrows indicate the right apex lung mass seen on the axial view (**A–C**) as well as the coronal view (**D–F**). CT images showing a hepatic mass before (**G**), 8 weeks after (**H**), and 28 weeks after (**I**) combination therapy of osimertinib and crizotinib. This patient also received microwave ablation of this hepatic mass prior to initiation of the combination therapy. MRI images showing the posterior left temporal lobe mass 18 weeks after (**J**) and 28 weeks after (**K**) combination therapy of osimertinib and crizotinib. The red circles clearly indicate disease progression at 28 weeks as demonstrated by the interval increase in size of the mass. Of note, this mass had previously received stereotactic radiation. The patient subsequently underwent total resection of the mass (**L**).

demonstrated by York et al in the management of an African American NSCLC patient with emergent *MET* amplification (*MET/CEP7* ratio: 3.67) after EGFR T790M mutation. The patient received 80 mg daily osimertinib and 200 mg twice daily crizotinib at first with repeat scans after four months

of therapy showing significant improvement. Notably, when serum carcinoembryonic antigen (CEA) started to rise, the dose of crizotinib was increased to 250 mg twice daily resulting in reduction of the CEA level. The most notable toxicity was grade 2 fatigue.<sup>8</sup> Kang et al reported a case of acquired



**Figure 3** Schematic summary of treatment course.

**Abbreviations:** CGP, comprehensive genomic profiling; CNS, central nervous system; LN, lymph node; PD, progressive disease; SRS, stereotactic radiosurgery.

*MET* amplification with pre-existing *EGFR* L858R and T790M mutations that achieved a PR to full-dose osimertinib and crizotinib after becoming resistant to gefitinib and then osimertinib. This patient subsequently developed multiple *MET* secondary-site mutations and responded symptomatically when crizotinib was switched to cabozantinib at 80 mg daily.<sup>9</sup> Most recently, Deng et al treated a Hispanic male patient with a combination of osimertinib at 80 mg daily and crizotinib at 250 mg daily in the setting of severe hepatic dysfunction when liquid biopsy revealed *MET* amplification (5.3 copies) in addition to three pre-existing *EGFR* mutations including *EGFR* L858R, R776C, and T790M. The dose of crizotinib had to be reduced to 200 mg daily due to grade 3 neutropenia, nausea, and lower extremity edema. This combination therapy had provided clinical benefit for 6 months until the patient experienced disease progression with rising *MET* copy number to 22.4 copies.<sup>10</sup>

While our patient derived good extracranial response to full-dose osimertinib and crizotinib without experiencing any toxicity, he eventually progressed in the brain 28 weeks into combination therapy. Interestingly, CGP performed on the resected brain specimen did not reveal additional resistance mechanisms suggesting *MET* amplification likely continued to contribute to acquired resistance. This is not entirely surprising as crizotinib, a type Ia *MET* inhibitor, is well known to have poor brain penetration. Switching to a different *MET* inhibitor with potentially better CNS

activity, such as cabozantinib, a type II *MET* inhibitor, can be considered should the patient develop further CNS progression.<sup>11,12</sup>

## Conclusion

As more actionable resistance mechanisms are identified in *EGFR*-mutant NSCLC patients, we envision combination TKI therapy will be readily adopted in clinical practice. Understanding the safety profile of each agent and drug interactions will be essential to provide effective yet tolerable combination therapy. Notably, we have successfully treated a patient with full-dose osimertinib and alectinib when liquid biopsy detected a novel in-frame *PLEKHA7-ALK* fusion after the patient had developed resistance to sequential erlotinib, afatinib, and osimertinib.<sup>13</sup> Taken together, our case report adds to a growing body of evidence that combination of osimertinib and crizotinib should be recommended to *EGFR*-mutant NSCLC patients with emergent *MET* amplification as acquired resistance. More importantly, developing next-generation *MET* inhibitors with better CNS activity is urgently needed.

## Disclosure

VWZ has received honoraria from AstraZeneca, Roche-Foundation Medicine, Roche/Genentech, and Takeda, and consulting fees from TP Therapeutics. ABS and SMA are employees of Foundation Medicine, Inc., a wholly owned

subsidiary of Roche. SIO has received honoraria from Astra-Zeneca, Pfizer, Roche-Foundation Medicine, Roche/Genentech and Takeda, and has stock ownership in TP Therapeutics. The authors report no other conflicts of interest in this work.

## References

1. Fenizia F, De Luca A, Pasquale R, et al. *EGFR* mutations in lung cancer: from tissue testing to liquid biopsy. *Future Oncol.* 2015;11(11):1611–1623.
2. Ou SI, Agarwal N, Ali SM. High *MET* amplification level as a resistance mechanism to osimertinib (AZD9291) in a patient that symptomatically responded to crizotinib treatment post-osimertinib progression. *Lung Cancer.* 2016;98:59–61.
3. Schildhaus HU, Schultheis AM, Rüschoff J, et al. *MET* amplification status in therapy-naïve adeno- and squamous cell carcinomas of the lung. *Clin Cancer Res.* 2015;21(4):907–915.
4. Ou SH, Pavlick D, Stephens PJ, et al. Gemonic analysis of non-small cell lung cancer (NSCLC) cases with focal and non-focal *MET* amplification. Abstract OA 12.08, IASLC 18th World Conference on Lung Cancer; 2017.
5. Scheffler M, Merkelbach-Bruse S, Bos M, et al. Spatial tumor heterogeneity in lung cancer with acquired epidermal growth factor receptor-tyrosine kinase inhibitor resistance: targeting high-level *MET*-amplification and *EGFR* T790M mutation occurring at different sites in the same patient. *J Thorac Oncol.* 2015;10(6):e40–e43.
6. Gainor JF, Niederst MJ, Lennerz JK, et al. Dramatic response to combination erlotinib and crizotinib in a patient with advanced, *EGFR*-mutant lung cancer harboring de novo *MET* amplification. *J Thorac Oncol.* 2016;11(7):e83–e85.
7. Li YQ, Song SS, Jiang SH, Zhang XY. Combination therapy of erlotinib/crizotinib in a lung adenocarcinoma patient with primary *EGFR* mutation plus secondary *MET* amplification and a novel acquired crizotinib-resistant mutation *MET* G1108C. *Ann Oncol.* 2017;28(10):2622–2624.
8. York ER, Varela-Garcia M, Bang TJ, Aisner DL, Camidge DR. Tolerable and effective combination of full-dose crizotinib and osimertinib targeting *MET* amplification sequentially emerging after T790M positivity in *EGFR*-mutant non-small cell lung cancer. *J Thorac Oncol.* 2017;12(7):e85–e88.
9. Kang J, Chen H-J, Wang Z, et al. Osimertinib and cabozantinib combinatorial therapy in an *EGFR*-mutant lung adenocarcinoma patient with multiple *MET* secondary-site mutations after resistance to crizotinib. *J Thorac Oncol.* 2018;13(4):e49–e53.
10. Deng L, Kiedrowski LA, Ravera E, Cheng H, Halmos B. Response to dual crizotinib and osimertinib treatment in a lung cancer patient with *MET* amplification detected by liquid biopsy who acquired secondary resistance to *EGFR* tyrosine kinase inhibition. *J Thorac Oncol.* 2018;13(9):e169–e172.
11. Reungwetwattana T, Liang Y, Zhu V, Ou S-HI. The race to target *Met* exon 14 skipping alterations in non-small cell lung cancer: the why, the how, the WHO, the unknown, and the inevitable. *Lung Cancer.* 2017;103:27–37.
12. Klemptner SJ, Borghei A, Hakimian B, Ali SM, Ou S-HI. Intracranial activity of cabozantinib in *MET* exon 14-positive NSCLC with brain metastases. *J Thorac Oncol.* 2017;12(1):152–156.
13. Schrock AB, Zhu VW, Hsieh WS, et al. Receptor tyrosine kinase fusions and *BRAF* kinase fusions are rare but actionable resistance mechanisms to *EGFR* tyrosine kinase inhibitors. *J Thorac Oncol.* 2018;13(9):1312–1323.

### Lung Cancer: Targets and Therapy

#### Publish your work in this journal

Lung Cancer: Targets and Therapy is an international, peer-reviewed, open access journal focusing on lung cancer research, identification of therapeutic targets and the optimal use of preventative and integrated treatment interventions to achieve improved outcomes, enhanced survival and quality of life for the cancer patient. Specific topics covered in the journal include: Epidemiology, detection and screening; Cellular research and biomarkers; Identification of biotargets and agents with novel

mechanisms of action; Optimal clinical use of existing anticancer agents, including combination therapies; Radiation and surgery; Palliative care; Patient adherence, quality of life, satisfaction; Health economic evaluations. The manuscript management system is completely online and includes a very quick and fair peer-review system. Visit <http://www.dovepress.com/testimonials.php> to read real quotes from published authors.

Submit your manuscript here: <https://www.dovepress.com/lung-cancer-targets--therapy-journal>

Dovepress