

Management of double-head pterygium with conjunctival autograft and primary closure

This article was published in the following Dove Press journal:
International Medical Case Reports Journal

Tobias Röck
Karl Ulrich Bartz-Schmidt
Daniel Röck

Centre for Ophthalmology, University of
Tübingen, Tübingen, Germany

Purpose: Double-headed pterygia are rare and present the surgeon with challenges. This case report illustrates the surgical management and the course of healing in a double-head pterygium patient.

Case report: A 53-year-old man was referred to our eye hospital with a double-head pterygium of the right eye. During the follow-up examinations, 1 and 3 years later stable findings were found. Five years after initial referral we saw a progression of the double-head pterygium and the patient explained a worse visual acuity. The nasal and temporal pterygium was resected and conjunctival autograft transplantation, and a primary closure was performed, respectively, for the bulbar conjunctival reconstruction. After the surgery, a reduction in the inflammation and healing of the conjunctival lesion could be seen. At the 12-month follow-up, there was no sign of recurrence or any postoperative complication.

Conclusion: A surgical excision combined with conjunctival autograft transplantation and primary closure in a one-time intervention seems to be effective and economical for the treatment of double-head pterygium.

Keywords: double-head pterygium, reconstructive surgical procedures, conjunctival autograft transplantation, primary closure, one-time intervention

Introduction

Double-headed pterygia are a rare benign fibrovascular overgrowths of the nasal and temporal bulbar conjunctiva onto the cornea, which have mostly a triangular appearance.^{1–5} The development of pterygia is multifactorial, including environmental irritants, for example long-term ultraviolet-B damage, wind, dust, chemicals, air pollution and hereditary factors. A pterygium can usually be diagnosed by slit-lamp examination.

Most patients have no discomforts from the pterygium except that they may be aware that there is a wing-shaped tissue growing onto the cornea. In most pterygium cases, the patient wants the lesion to be removed for cosmetic reasons, but surgery is indicated when pterygium grows into the visual axis, causing vision loss or induces reduction of visual acuity caused by increasing astigmatism or corneal scarring.

In recent years, different surgical techniques have been described in the literature. The best method to deal with a double-head pterygium remains uncertain. In 2017, Hirst et al described the treatment with P.E.R.F.E.C.T with no recurrences and excellent cosmetic results.⁵ This method is a two-time intervention. First, the larger pterygium is removed and at least 6–12 months later the smaller one. After wide resection of the pterygium, the defect will be covered with a very thin superior

Correspondence: Tobias Röck
Centre for Ophthalmology, University of
Tübingen, Elfriede-Aulhorn-Str. 7,
Tübingen D-72076, Germany
Tel +49 7 071 298 8088
Email Tobias.Roeck@med.uni-tuebingen.de

conjunctival graft. Most of the patients do not want to come two times to the eye hospital for surgery. Also, they do not want to have a surgical intervention twice with pain during the early postsurgical period. However, if you want to do the resection of a double-head pterygium in one surgery often there exists too little conjunctival graft for covering the nasal and temporal defects.

Confronted with the potential risk of pterygium recurrence after surgical treatment and the conflict to have to operate the patient a second time, we decided to combine two well-known and proven surgical methods, including primary closure for the smaller pterygium and conjunctival autograft for the larger one.

Here, we illustrate the case of a large double-head pterygium of the right eye managed with conjunctival autograft transplantation and primary closure.

Case report

A 53-year-old man was referred to our eye hospital in March 2012 with a double-head pterygium of the right eye. Upon examination, a pterygium was present on both the nasal and temporal sides of the right eye, a so-called double-head pterygium (Figure 1A). The initial patient's medical history reported stable findings in recent years. The best-corrected visual acuity (BCVA) of the right eye was 0.8 (0.1 logMAR). After slit-lamp examination, we did photo documentation during the first visit for classification of pterygium.

In 1997, Tan et al proposed a clinical grading which is based on its translucence appearance of pterygium tissue which corresponds to an increase of fleshiness of the fibrovascular components of pterygium.⁶ Other clinical grading available is mainly based on the extent of pterygium progression from limbus to central cornea via slit-lamp biomicroscopy examination.⁷ Either of these grading is applicable; however, the different classification between graders is high especially on latter approach. For this

reason, we make photo documentation after slit-lamp examination during every visit. Photo documentation is recommended and will allow objective comparison with findings during a subsequent follow-up visit. Often pterygia can be safely left alone and just watched and controlled by the ophthalmologist.

We recommended long term and frequent use of artificial tears and the use of cyclosporine eye drops 0.05% (University Pharmacy, University Hospital, Tübingen, Germany) two times a day. In December 2013 and July 2015 during follow-up examinations, we found stable finding of the double-head pterygium. Two years later, during the next follow-up visit in September 2017 (Figure 1B) we saw a progression in the photo documentation and the patient explained a worse visual acuity. The BCVA of the right eye was 0.32 (0.5 logMAR). In October 2017, the nasal and temporal pterygium was resected in peribulbar anesthesia and conjunctival autograft transplantation at the nasal side and a primary closure at the temporal side with absorbable 9-0 Vicryl sutures were performed, respectively, for the bulbar conjunctival reconstruction in one intervention.

Surgical technique

First, the head and the body of the pterygia were excised with Westcott scissors. The remaining subconjunctival degenerative parts of pterygia were abraded with a hockey knife. Polishing of corneal and limbal surfaces were done using a motorized diamond burr. Cautery was gently applied to bleeding vessels. Afterward, the residual conjunctival defect was measured with calipers. For the nasal side, the conjunctival autograft with limbal tissue was taken from the supero-temporal bulbar conjunctiva. Fine liner sterile mediware skin marker (servoprax GmbH, Wesel, Germany) was used to outline the conjunctiva to be removed according to the previous measurements and the general shape of the surgical defect. Additionally, the

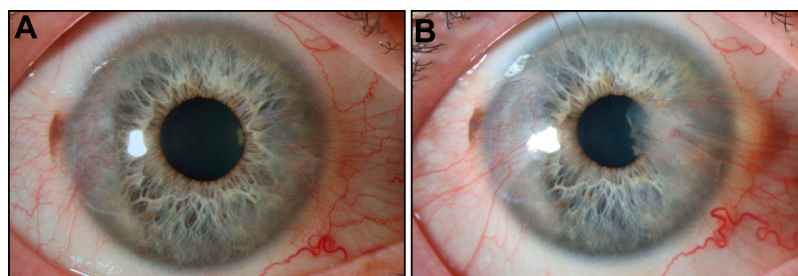


Figure 1 (A) Initial slit-lamp image showing a double-head pterygium of the right eye. (B) Five and a half years later, during a follow-up visit a progression could be seen in the photo comparison and the patient explained a worse visual acuity (slit-lamp images with white light showing a 10× magnification).

limbal edge was denoted with this skin marker so that this edge could be subsequently easily identified. Then, 2% scandicaine was injected supero-temporal to facilitate separation of conjunctiva from Tenon's capsule. The thin conjunctival autograft was then harvested by undermining and careful dissection with blunt Wescott scissors. The free conjunctival autograft was then positioned over the nasal area of bare sclera, being careful to maintain the limbus-to-limbus and epithelial-side-up orientations. The orientation of the thin conjunctival autograft has been made easier by previous marking with the skin marker. The autograft was then sutured to the underlying sclera at the limbus and to the cut conjunctiva edges with interrupted 9-0 Vicryl sutures. The supero-temporal graft harvest site did not require closure and re-epithelialized on its own. Afterward, the procedure of primary closure involved closure of the temporal conjunctival defect following undermining and mobilization of the surrounding conjunctiva to cover the bare sclera. The conjunctiva was sutured with 9-0 Vicryl sutures.

A topical corticosteroid [1.3 mg/mL dexamethasone eye drops (DexaEDO[®], Bausch+Lomb GmbH, Dr. Gerhard Mann Chem.-Pharm. Fabrik GmbH, Berlin, Germany)], antibiotic eye drops [0.5% moxifloxacin hydrochloride ophthalmic solution (Vigamox[®], Novartis Pharma GmbH, Nürnberg, Germany)] and artificial tears (Artelac[®] splash EDO, Bausch+Lomb GmbH, Dr. Gerhard Mann Chem.-Pharm. Fabrik GmbH) were used postoperatively four times a day over a 2-week period. Then, the

corticosteroid eye drops were reduced by one drop each week, while the artificial tears were still applied four times a day.

After the surgery, a reduction in the inflammation and healing of the conjunctival lesion could be seen. The "reduction in the inflammation and healing of the conjunctival lesion" was evaluated by our experience and redness appearance of the conjunctiva. In 2017, Hilmi et al showed a new semi-automated computer program to measure the pterygium fibrovascular redness from digital pterygium images.⁸ This redness grading could be used in addition to the existing pterygium grading.

Figure 2 shows this eye's course of healing over time. At the 12-month follow-up, a slit-lamp examination revealed stable findings. There was no sign of recurrences. The BCVA of the right eye had increased to 0.8 (0.1 logMAR). There was no sign of any postoperative complication (Figure 3). The written, informed consent of the patient was obtained to publish this case report. In addition, this case study was approved by the Institutional Review Board of the University of Tübingen and adhered to the tenets of the Declaration of Helsinki.

Discussion

Here, this report illustrates how double-head pterygium resection can be managed with conjunctival autograft transplantation and primary closure in a one-time intervention. Confronted with the potential risk of pterygium recurrence after surgical treatment and the conflict to have to operate

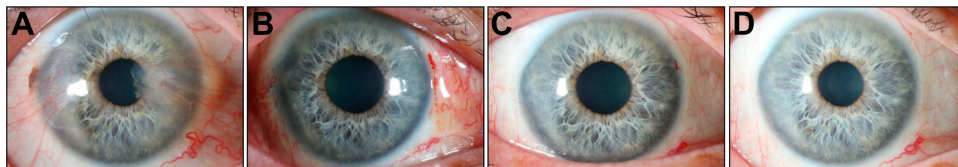


Figure 2 Slit-lamp images showing the course of healing over time. (A) Slit-lamp image showing the large double-head pterygium before surgery. (B) Fourteen days after pterygium resection and nasal conjunctival autograft transplantation, and temporal primary closure. (C) Eight weeks after surgery a reduction in the inflammation and healing could be seen. (D) At the 12-month follow-up, a slit-lamp examination revealed stable findings. There was no sign of recurrence or any postoperative complication.

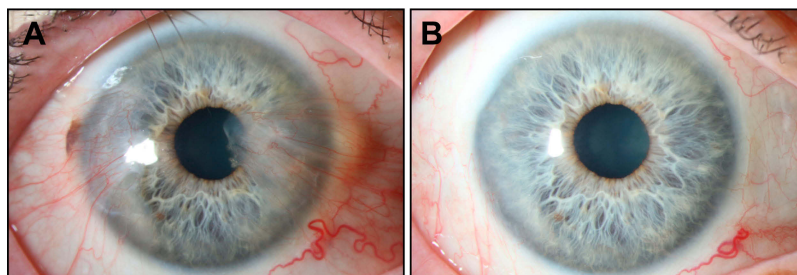


Figure 3 (A) Slit-lamp image showing the large double-head pterygium before surgery. (B) At the 12-month follow-up, there was no sign of recurrence.

the patient a second time, we decided to combine two well-known and proven surgical methods, including primary closure for the smaller pterygium and conjunctival autograft for the larger one.

In 2019, our study group showed in 521 primary pterygium resections effectiveness of conjunctival autograft. Pterygium surgery with conjunctival autograft had a recurrence rate of 6.4%, primary closure 14.4% and amniotic membrane transplantation 14.7%, respectively.⁹

If the double-head pterygium is not so large, the conjunctival autograft could be divided into two pieces and suturing in place of the excised pterygium on both sides of the cornea or perform a two-time intervention like described by Hirst et al before.⁵ But if it is a very large double-head pterygium and no two interventions by the patient are desired the best alternative is unclear. Most of the patients do not want to have two surgeries because of pain during the early postsurgical period. However, if you want to do the resection of a double-head pterygium in one surgery often there exists too little conjunctival graft for covering the nasal and temporal defects.

Confronted with the potential risk of pterygium recurrence after surgical treatment and the conflict to have to operate the patient a second time, we decided to combine two well-known and proven surgical methods, including primary closure for the smaller temporal pterygium and conjunctival autograft for the larger nasal one in a one-time intervention.

In principle, patients should be told that often pterygia can be safely left alone and just watched and controlled by the ophthalmologist. Because the major complication of pterygium surgery is that the pterygium can recur. Sometimes when it recurs it may be larger and more troublesome than the pterygium that was removed. But when it comes to a pterygium progression and a reduction of visual acuity surgery is indicated.

Recurrence rates depend on surgical technique⁹ but also on the races and ethnicities of the patient. Recently, Campagna et al showed that hispanic and black patients are more likely to experience pterygium recurrence after amniotic membrane transplantation and conjunctival autograft.¹⁰ Other predicting factors of recurrence are young age⁹ and ocular surface inflammation caused by environmental factors¹¹ like dusty dry air, smoke-filled rooms or ultraviolet radiation.^{12–16} Therefore, patients should know these triggers and were advised to avoid dusty and sunny conditions and to use sunglasses and hats.

If a pterygium is going to recur, Yang et al reported that 97% of recurrences will start to recur within the first year.¹⁷ Therefore, a follow-up visit of 12 months after pterygium surgery to recognize a possible recurrence makes sense.

Al Fayed, Fernandes et al and Ma et al obtained recurrence rates after conjunctival autograft in line with our study group results of 8.3%, 12.2% and 5.4%, respectively.^{9,18–20}

In accordance with other studies, in our opinion amniotic membrane may still be in mind in cases of great conjunctival defects or insufficient conjunctiva after glaucoma filtering surgeries.^{9,21} However, our study group showed that conjunctival autograft combined with primary closure in a one-time intervention seems to be effective for the treatment of double-head pterygium. Studies in the future will require a larger sample size, which would increase the power of the analysis and the validity of its findings.

Conclusion

A surgical excision combined with conjunctival autograft transplantation and primary closure in a one-time intervention seems to be effective and economical for the treatment of double-head pterygium.

Abbreviations

P.E.R.F.E.C.T, pterygium extended removal followed by extended conjunctival transplantation; logMAR, logarithm of the minimum angle of resolution.

Acknowledgment

This case report was supported by the Deutsche Forschungsgemeinschaft and the Open Access Publishing Fund of the University of Tübingen.

Disclosure

The authors report no conflicts of interest in this work.

References

1. Fonseca EC, Rocha EM, Arruda GV. Comparison among adjuvant treatments for primary pterygium: a network meta-analysis. *Br J Ophthalmol*. 2018;102(6):748–756. doi:10.1136/bjophthalmol-2017-310288
2. Wu WK, Wong VW, Chi SC, et al. Surgical management of double-head pterygium by using a novel technique: conjunctival rotational autograft combined with conjunctival autograft. *Cornea*. 2007;26(9):1056–1059. doi:10.1097/ICO.0b013e31813349ec
3. Maheshwari S. Split-conjunctival grafts for double-head pterygium. *Indian J Ophthalmol*. 2005;53(1):53–55. doi:10.4103/0301-4738.15286
4. Prajna NV, Devi L, Seeniraj SK, et al. Conjunctival autograft versus amniotic membrane transplantation after double pterygium excision: a randomized trial. *Cornea*. 2016;35(6):823–826. doi:10.1097/ICO.0000000000000812

5. Hirst LW, Smallcombe K. Double-headed pterygia treated with P.E.R. F.E.C.T for PTERYGIUM. *Cornea*. 2017;36(1):98–100. doi:10.1097/ICO.0000000000001036
6. Tan DT, Chee SP, Dear KB, et al. Effect of pterygium morphology on pterygium recurrence in a controlled trial comparing conjunctival autografting with bare sclera excision. *Arch Ophthalmol*. 1997;115(10):1235–1240. doi:10.1001/archophth.1997.01100160405001
7. Mahar PS, Manzar N. Pterygium recurrence related to its size and corneal involvement. *J Coll Physicians Surg Pak*. 2013;23(2):120–123. doi:02.2013/JCPSP.120123
8. Hilmi MR, Che Azemin MZ, Mohd Kamal K, et al. Prediction of changes in visual acuity and contrast sensitivity function by tissue redness after pterygium surgery. *Curr Eye Res*. 2017;42(6):852–856. doi:10.1080/02713683.2016.1250277
9. Röck T, Bramkamp M, Bartz-Schmidt KU, Röck D. A retrospective study to compare the recurrence rate after treatment of pterygium by conjunctival autograft, primary closure, and amniotic membrane transplantation. *Med Sci Monit*. 2019;25:7976–7981.
10. Campagna G, Adams M, Wang L, et al. Comparison of pterygium recurrence rates among different races and ethnicities after primary pterygium excision by surgeons in training. *Cornea*. 2018;37(2):199–204. doi:10.1097/ICO.0000000000001453
11. Kim KW, Kim JC. Current approaches and future directions in the management of pterygium. *Int J Ophthalmol*. 2018;11(5):709–711. doi:10.18240/ijo.2018.05.01
12. Coroneo MT. Pterygium as an early indicator of ultraviolet insolation: a hypothesis. *Br J Ophthalmol*. 1993;77(11):734–739. doi:10.1136/bjo.77.11.734
13. Hilgers JH. Pterygium: its incidence, heredity and etiology. *Am J Ophthalmol*. 1960;50(4):635–644. doi:10.1016/0002-9394(60)90245-2
14. Marchetti C, Sidahmed-Adrar N, Collin F, et al. Melatonin protects PLPC liposomes and LDL towards radical-induced oxidation. *J Pineal Res*. 2011;51(3):286–296. doi:10.1111/j.1600-079X.2011.00889.x
15. Kau HC, Tsai CC, Lee CF, et al. Increased oxidative DNA damage, 8-hydroxydeoxy-guanosine, in human pterygium. *Eye*. 2006;20(7):826–831. doi:10.1038/sj.eye.6702064
16. Balci M, Sahin S, Mutlu FM, et al. Investigation of oxidative stress in pterygium tissue. *Mol Vis*. 2011;17:443–447.
17. Yang Y, Pi M, Xu F. Observation of long-term efficacy of corneal limbal conjunctival autografts in microscopy treatments of pterygium. *Eye Sci*. 2013;28(2):73–78.
18. Fernandes M, Sangwan VS, Bansal AK, et al. Outcome of pterygium surgery: analysis over 14 years. *Eye*. 2005;19(11):1182–1190. doi:10.1038/sj.eye.6701728
19. Ma DH, See LC, Liau SB, et al. Amniotic membrane graft for primary pterygium: comparison with conjunctival autograft and topical mitomycin C treatment. *Br J Ophthalmol*. 2000;84(9):973–978. doi:10.1136/bjo.84.9.973
20. Al Fayed MF. Limbal versus conjunctival autograft transplantation for advanced and recurrent pterygium. *Ophthalmology*. 2002;109(9):1752–1755.
21. Clearfield E, Hawkins BS, Kuo IC. Conjunctival autograft versus amniotic membrane transplantation for treatment of pterygium: findings from a cochrane systematic review. *Am J Ophthalmol*. 2017;182:8–17. doi:10.1016/j.ajo.2017.07.004

International Medical Case Reports Journal

Dovepress

Publish your work in this journal

The International Medical Case Reports Journal is an international, peer-reviewed open-access journal publishing original case reports from all medical specialties. Previously unpublished medical posters are also accepted relating to any area of clinical or preclinical science. Submissions should not normally exceed 2,000 words or 4

published pages including figures, diagrams and references. The manuscript management system is completely online and includes a very quick and fair peer-review system, which is all easy to use. Visit <http://www.dovepress.com/testimonials.php> to read real quotes from published authors.

Submit your manuscript here: <https://www.dovepress.com/international-medical-case-reports-journal-journal>