

The Anti-Inflammatory Effect of Different Doses of Aliskiren in Rat Models of Inflammation

This article was published in the following Dove Press journal:
Drug Design, Development and Therapy

Tavga Ahmed Aziz 
Ahmed Azad Kareem
Hemn Hassan Othman 
Zheen Aorahman Ahmed 

Department of Pharmacology and
Toxicology, College of Pharmacy,
University of Sulaimani, Sulaimani,
Kurdistan Region, Iraq

Objective: The present study was designed to evaluate the anti-inflammatory effects of different doses of aliskiren in two animal models of inflammation.

Methodology: Sixty-six Wistar rats were allocated into five groups: the first group (six rats) was treated with the vehicle only, without induction of paw edema and granulomatous inflammation, and served as a negative control; the second group (12 rats) was allocated into two subgroups and treated with the vehicle only, with induction of paw edema and granulomatous inflammation, and served as a positive control; the third group (36 rats) was allocated into six subgroups and treated with different doses of aliskiren (15, 30, and 60 mg/kg) in both models; the fourth group (12 rats) was treated with dexamethasone (1 mg/kg) in both models of inflammation. Serum concentrations of tumor necrosis factor- α (TNF- α), interleukin-10 (IL-10), vascular cell adhesion molecule-1 (VCAM-1), and high sensitivity C-reactive protein (hs-CRP) were measured. Skin samples were also sent for histopathological examination.

Results: Aliskiren, in a dose-dependent pattern, significantly decreased inflammation in rat models of inflammation, by attenuating the percentage of exudate, granuloma, and paw edema. Furthermore, it significantly reduced serum concentrations of TNF- α , VCAM-1, and hs-CRP and restored the serum concentration of IL-10. Additionally, significant improvement was seen in the histopathological findings.

Conclusion: In the current study, aliskiren was successful in decreasing inflammation in both models. These findings suggest that aliskiren is a good candidate for the treatment of inflammatory diseases.

Keywords: aliskiren, inflammation, granuloma, paw edema, inflammatory markers

Introduction

Inflammation is the biological response of the immune system to stimuli. It can be triggered by a variety of deleterious agents, such as infections, irritants, antibodies, or physical injuries. Depending on the nature of the stimulus and the initial response in removing the injurious tissues, inflammation may be acute or chronic.^{1,2} It is the organizer of the signaling pathways that regulate inflammatory mediator levels in injured tissue cells.³

Although there are currently available anti-inflammatory drugs, there is a need for safer alternatives. Despite the effectiveness of the medications presently used in the management of inflammation, such as nonsteroidal anti-inflammatory drugs (NSAIDs), opioids, and corticosteroids, some critical adverse reactions may halt their use. These are as follows: gastrointestinal and renal disturbance with NSAIDs, respiratory depression and addiction with opioids^{4,5}, and immunologic side effects and numerous organ dysfunctions associated with the use of corticosteroids.⁶ Recently,

Correspondence: Tavga Ahmed Aziz
Department of Pharmacology and
Toxicology, College of Pharmacy,
University of Sulaimani, Sulaimani, Iraq
Tel +9647701523544
Email tavga.aziz@univsul.edu.iq

many studies have shed light on the involvement of the renin–angiotensin–aldosterone system (RAAS) in inflammation.⁷ The RAAS plays a pivotal role in stimulating and maintaining inflammation. At cellular and molecular levels, it has proinflammatory and profibrotic effects. Renin is the first component of the RAAS. It is first synthesized as prorenin, then undergoes subsequent changes in the renal system and is released into the bloodstream.⁸ In the circulation, prorenin is activated to renin. Active renin then give rise to angiotensin I, which in turn cleaves to angiotensin II, the main component of the RAAS.⁹ Aliskiren is a direct renin inhibitor; it is the first orally available agent in its class of anti-hypertensive agents. It was approved in March 2008 for the treatment of hypertension as a monotherapy or in combination with other antihypertensive agents.¹⁰ Aliskiren has been shown to be able to significantly reduce gingival inflammation and enhance wound-healing processes.¹¹ Another study proved its analgesic and anti-allodynic activity in animal models of pain.¹² These studies demonstrate that aliskiren is a good candidate to be tested for its anti-inflammatory effects. Accordingly, the present study was designed to evaluate the anti-inflammatory effects of aliskiren in two animal models of inflammation.

Methodology

Experimental Animals

Wistar rats (150–200 g) of both sexes, aged 8–10 weeks, were purchased from the College of Medicine, Hawler Medical University and housed in the animal house, College of Pharmacy, University of Sulaimani, during March to September 2019. They were kept in well-ventilated plastic cages and maintained at normal conditions of temperature (25 ± 2 °C) and humidity ($55 \pm 5\%$), with a 12-hour light–dark cycle. They were fed standard pellet chow and had free access to water. The experimental protocol was approved by the Ethical Committee of the Faculty of Medical Sciences, University of Sulaimani, and performed in accordance with the Canadian Council on Animal Care (CCAC) guidelines, 1998.

Study Design

Sixty-six rats were used in the present study, divided into groups as follows:

- (i) Negative control group: six rats were used in this group. They were treated with the vehicle only, without induction of inflammation.
- (ii) Positive control group: twelve rats were subdivided into two groups and treated with the vehicle only. Six rats were assigned to cotton-pellet-induced granuloma, and the other six rats were assigned to formaldehyde-induced paw edema.
- (iii) Aliskiren-treated group: thirty-six rats were subdivided into six groups and treated with different doses (15, 30, and 60 mg/kg/day) of aliskiren (Rasilez[®] 300 mg tabs; Novartis, Switzerland) orally to study the anti-inflammatory activity of aliskiren in the rat model of cotton-pellet-induced granuloma and formaldehyde-induced paw edema.
- (iv) Dexamethasone-treated group: twelve rats were divided into two groups and treated with dexamethasone (TAD, Germany) (1 mg/kg) orally as a standard anti-inflammatory agent in the rat model of cotton-pellet-induced granuloma and formaldehyde-induced paw edema.

Study of the Effect of Aliskiren in Cotton-Pellet-Induced Granulomatous Inflammation

The Winter and Porter method of cotton-pellet-induced granulomatous inflammation was used to evaluate the anti-inflammatory effects of aliskiren.¹³ In this model of inflammation, cotton pellets weighing 10 ± 1 mg were sterilized in an autoclave for 30 minutes at 120 °C. Four pellets were inserted subcutaneously into the ventral region of the anaesthetized rat, two on each side (right and left). Aliskiren (15, 30, and 60 mg/kg), dexamethasone (1 mg/kg), and the vehicle, distilled water (0.2 mL/100 g), were given 1 hour prior to the procedure and continued for 7 consecutive days. On day 8, the rats were anaesthetized and the pellets and granulation tissue were carefully removed and freed from extraneous tissue.

The wet pellets were weighed to determine the wet weight, dried in an incubator at 60 °C for 18 hours and then the dried pellets were weighed again. The exudate amount was calculated by subtracting the constant weight of the dried pellets from the weight of the wet pellets. The granulation tissue weight was calculated by deducting the weight of the cotton pellets (10 mg) from the weight of the dried pellets. The percentage of inhibition of exudate and granulation tissue formation were calculated using the following equations:¹⁴

$$\text{Exudate inhibition (\%)} = (1 - \text{Exudate in treated group} / \text{Exudate in controls}) \times 100.$$

Granuloma inhibition (%) = $(1 - \text{Granuloma in treated group} / \text{Granuloma in controls}) \times 100$.

Study of the Effects of Aliskiren in the Rat Model of Formaldehyde-Induced Paw Edema

The effects of aliskiren in inflammation were evaluated using the Turner method of formaldehyde-induced paw edema.¹⁵ In this model, inflammation was induced by the injection of 0.1 mL 2% formaldehyde subcutaneously into the sub-plantar region of the right hind-paw of ether-anaesthetized rats. Aliskiren (15, 30, and 60 mg/kg), dexamethasone (1 mg/kg), and the vehicle distilled water (0.2 mL/100 g) were given orally 1 hour before induction of inflammation and continued for 7 consecutive days. The increase in paw thickness was measured by the digital Vernier caliper method: the paw thickness was measured before starting the administration of drugs and on day 8 before scarification and presented as the mean increase in paw thickness. The ability of the drug to suppress paw edema was expressed as the percentage of inhibition, calculated according to the following equation:¹⁶

$$\text{Percentage of inhibition (\%)} = (C - T) / C \times 100$$

Where C is the mean increase in paw thickness of the control group and T is the mean increase in paw thickness of the treated group.

Five milliliters of blood was drawn from each rat and left to clot for 20 minutes at room temperature. The serum was separated by centrifugation at 3000 rpm for approximately 20 minutes and then stored at -20°C unless immediately analyzed. Serum concentrations of tumor necrosis factor- α (TNF- α), interleukin-10 (IL-10), vascular cell adhesion molecule-1 (VCAM-1), and high sensitivity C-reactive protein (hs-CRP) were analyzed using ready-made enzyme-linked immunosorbent assay (ELISA) kits based on the sandwich method, according to the specifications of the manufacturer (Bioassay technology laboratory, Shanghai, China).

Histological Studies and Preparation Histotechnique Procedure

At the end of each experiment, the animals were fasted for at least 12 hours, then euthanized humanely. Following necropsy, paw and granuloma skin samples were taken for histological preparation. Sectioned tissues were stained with hematoxylin and eosin and viewed under a bright-field light microscope. First, samples were added into tissue cassettes and fixed in 10% neutral formaldehyde solution for at least 48 hours. Tissue sections were dehydrated using a series of ascending concentrations of ethanol (50%, 60%, 70%, 90%, and 100%),

then cleaned twice using xylene. The processed tissues were embedded in melted paraffin blocks at $60\text{--}70^{\circ}\text{C}$ using an automated wax embedder. Tissue blocks were trimmed and sectioned to $5\ \mu\text{m}$ using a semi-automated rotary microtome. Then the tissue sections were mounted on glass slides using a hot-plate tissue holder. Afterward, the mounted tissue sections were deparaffinized, cleaned with xylene solution for 15 minutes and oven dried at 50°C for 5 minutes. Finally, tissue sections were stained with Harris's hematoxylin and eosin solutions using an automated tissue-staining machine (Leica-Germany), and then tissue slides were cleaned, as a final step, with xylene and cover-slipped.

Semi-Quantitative Histological Evaluation

As a quantitative measure, histological sections of paw edema and inflammatory exudates from the skin of each animal were estimated and measured in micrometers and statistically evaluated as the mean percentage. Inflammatory cells for both acute (paw edema) and chronic (granuloma) inflammatory models were counted in four randomly chosen fields of view in each tissue section under high-power magnification ($100\times$). Then the mean average was calculated statistically as a percentage. Moreover, the area of tissue granuloma and the thickness of proliferated collagen fibers were measured in micrometers and semi-quantitatively evaluated in the same manner as the inflammatory exudates. Tissue samples were analyzed under the light microscope (NOVEL XSZ-N107, China) with image analyzer software (AmScope Ver. 3.7) using a microscope digital camera (MU300, 2019). The mean percentages of the calculated values were elaborated into the following lesion grading scores: 0–10% as no lesions, 10–25% as mild lesions, 25–75% as moderate lesions, and 75–100% as severe lesions.

Statistical Analysis

All the results were expressed as mean \pm SD. The data were analyzed using GraphPad Prism 7.00 software (GraphPad Software Inc., La Jolla, CA, USA). An unpaired *t*-test, one-way ANOVA, and Tukey's multiple comparison test were utilized for statistical evaluation of the differences between the means; $p < 0.05$ was considered statistically significant.

Results

The Effect of Aliskiren in Cotton-Pellet-Induced Granulomatous Inflammation

The data presented in Table 1 reveal that treatment with aliskiren significantly decreased the formation of

Table 1 Effect of Different Doses of Aliskiren on Exudate and Granuloma Formation in the Cotton-Induced Granuloma Model of Inflammation

Treatment Groups	Exudate (mg)	Inhibition of Exudate %	Granuloma (mg)	Inhibition of Granuloma %
Control	98.6 ± 17.1 ^a	–	26.5 ± 10.8 ^a	–
Dexamethasone 1 mg/kg	62.6 ± 14.2 ^b	37	9.8 ± 4.7 ^b	63
Aliskiren 15 mg/kg	70.4 ± 9 ^b	28.6	16.7 ± 3.5 ^c	36.9
Aliskiren 30 mg/kg	75 ± 14.8 ^b	24	15.5 ± 3.6 ^c	41.5
Aliskiren 60 mg/kg	68.3 ± 11.7 ^b	37	15.5 ± 5.6 ^c	41.5

Notes: Values are presented as mean ± SD; n = 6 rats in each group; values with different superscripts (a, b, c) among different groups are significantly different ($p < 0.05$), using ANOVA and post hoc test, SD, standard deviation.

inflammatory exudate compared to the control, with the maximum percentage of inhibition produced by the dose of 60 mg/kg of aliskiren (30.7%). Meanwhile, administration of 1 mg/kg of dexamethasone significantly decreased the exudate formation compared to the control, reaching the maximum effect of 37%; this result was comparable to that produced by aliskiren 60 mg/kg. Aliskiren 15 mg/kg and 30 mg/kg resulted in 28.6% and 24% decreases in exudate formation respectively. Moreover, aliskiren significantly decreased the formation of granuloma, with the maximum effect produced by aliskiren 30 mg/kg and 60 mg/kg (41.5%), while aliskiren 15 mg/kg produced a 36.9% reduction in granuloma formation compared with the control. Meanwhile, 1 mg/kg dexamethasone significantly attenuated the formation of granuloma compared with the control (63%).

Effects of Aliskiren in the Rat Model of Formaldehyde-Induced Paw Edema

Table 2 shows that treatment with aliskiren significantly decreased the formation of paw edema ($p < 0.05$) in a dose-dependent pattern compared with the control, with maximum effect achieved with 60 mg/kg of aliskiren (61%). Meanwhile, 1 mg/kg dexamethasone significantly attenuated the increase in paw thickness compared to the control (50%).

Effects of Aliskiren on the Inflammatory Markers in Both Models of Inflammation

In the granuloma model of inflammation, Figure 1A shows that treatment with aliskiren 30 mg/kg and 60 mg/kg significantly reduced the serum TNF- α concentration ($p < 0.05$) compared with the positive control, with the greatest suppression produced by 30 mg/kg. No significant changes were observed with the other treatment. In Figure 1A, there is a reduction in the concentration of IL-10 in the positive control group compared to the negative control. However, the reduction was statistically not significant. The use of aliskiren 60 mg/kg increased the concentration of IL-10, which was comparable with the negative control. In Figure 2A, the positive control group shows a non-significant increase in the level of VCAM-1 compared to the negative control. Dexamethasone and aliskiren 60 mg/kg revealed a significant reduction in the concentration of VCAM-1 compared to the positive control ($p < 0.05$); more significant reduction was observed with the use of aliskiren 30 mg/kg compared to the others ($p < 0.01$). Regarding the effect on hs-CRP, Figure 2B shows a significant increase in the positive control compared with the negative control and the use of dexamethasone. Aliskiren 30 mg/kg and 60 mg/kg resulted in a significant decrease compared with the positive control ($p < 0.05$).

Table 2 Effect of Different Doses of Aliskiren on Paw Edema Formation in the Formalin-Induced Paw Edema Model of Inflammation

Treatment Groups	Paw Thickness (mm) at Zero Time	Paw Thickness (mm) After 7 Days	Change in Paw Thickness (mm) After 7 Days	Inhibition of Paw Edema %
Control	3.22 ± 0.4	4.97 ± 0.3*	1.75 ± 0.7 ^a	–
Dexamethasone 1 mg/kg	3.02 ± 0.17	3.94 ± 0.32*	0.92 ± 0.4 ^b	50
Aliskiren 15 mg/kg	3.08 ± 0.33	4.75 ± 0.49*	1.67 ± 0.35 ^a	9.7
Aliskiren 30 mg/kg	2.78 ± 0.26	3.85 ± 0.53*	1.07 ± 0.51 ^c	42
Aliskiren 60 mg/kg	2.85 ± 0.24	3.57 ± 0.2*	0.72 ± 0.17 ^d	61

Notes: Values are presented as mean ± SD; n = 6 rats in each group; *significantly different compared with zero time value ($p < 0.05$), within the same group, using t-test; values with different superscripts (a, b, c, d) among different groups are significantly different ($p < 0.05$), using ANOVA and post hoc test, SD, standard deviation.

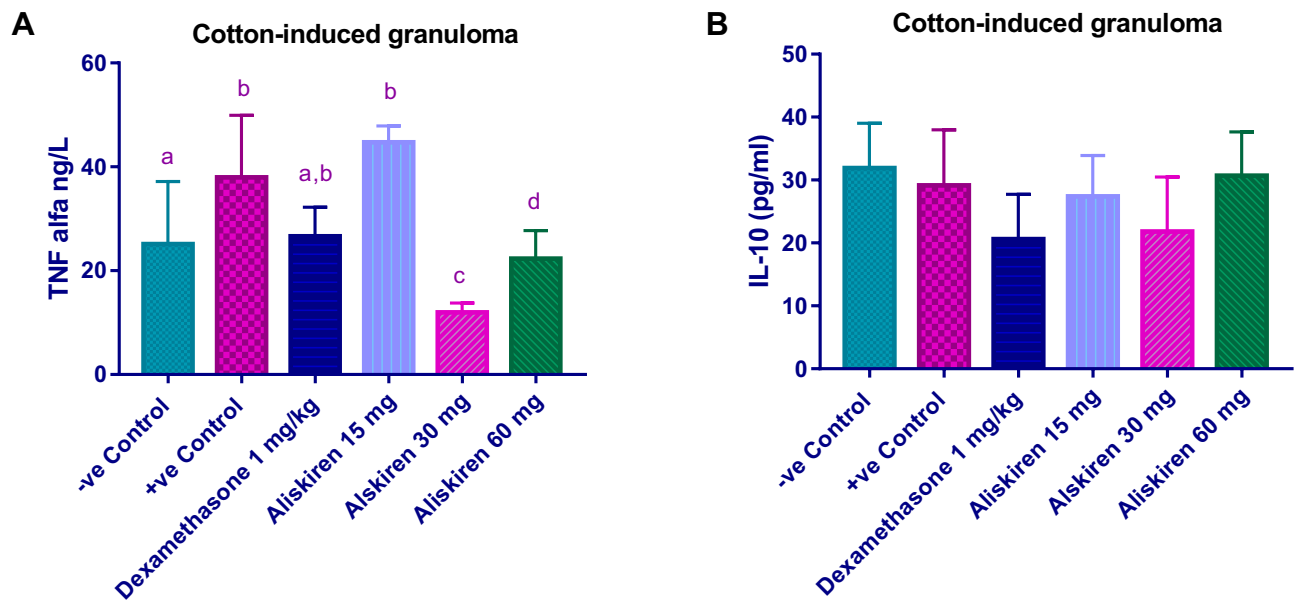


Figure 1 (A) Effect of different doses of aliskiren on the serum concentrations of TNF- α in the granuloma model of inflammation; values with non-identical letters (a, b, c, d) are significantly different using ANOVA and post hoc test ($p < 0.05$). **(B)** Effect of different doses of aliskiren on the serum concentrations of IL-10 in the granuloma model of inflammation.

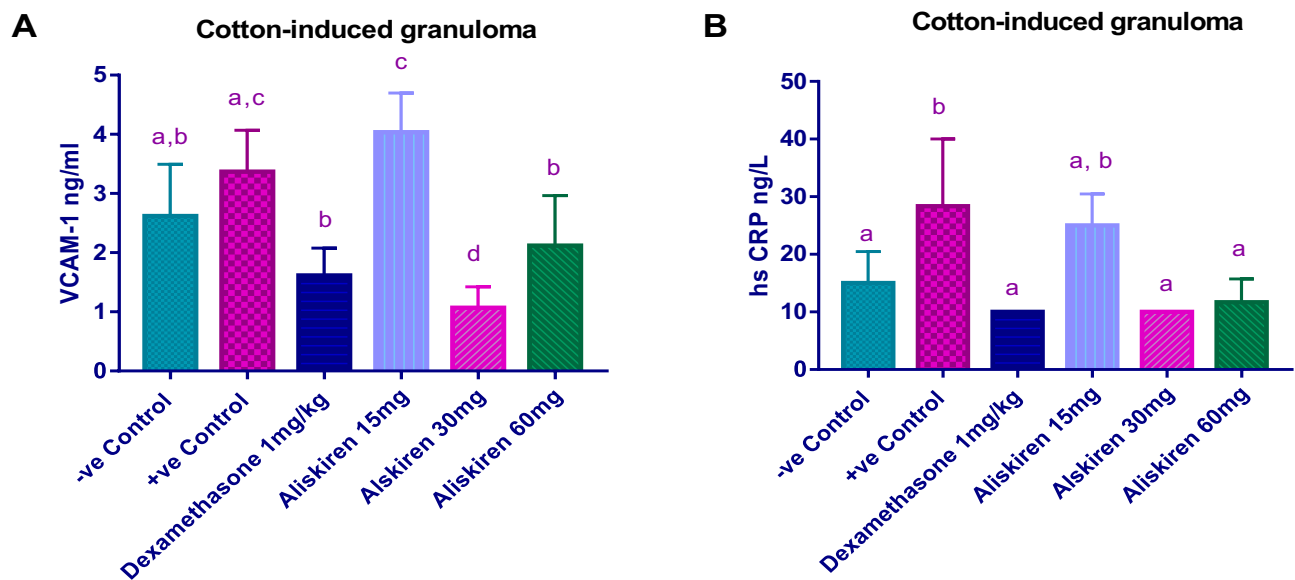


Figure 2 (A) Effect of different doses of aliskiren on the serum levels of VCAM-1 in the granuloma model of inflammation; values with non-identical letters (a, b, c, d) are significantly different using ANOVA and post hoc test ($p < 0.05$). **(B)** Effect of different doses of aliskiren on the serum levels of hs-CRP in the granuloma model of inflammation; values with non-identical letters (a, b, c, d) are significantly different using ANOVA and post hoc test ($p < 0.05$).

Concerning the formalin-induced paw edema, [Figure 3A](#) shows that treatment with aliskiren 30 mg/kg and 60 mg/kg significantly reduced serum TNF- α concentration, compared with the positive control, with greater effects produced by 30 mg/kg ($p < 0.001$). A significant decrease in serum TNF- α concentration was also achieved by dexamethasone compared to the positive control. In [Figure 3B](#), there was

a reduction in the serum concentration of IL-10 in the positive control group compared to the negative control, but the reduction was statistically not significant. The use of aliskiren 15 mg/kg increased the serum concentration of IL-10, which was comparable with the negative control. In [Figure 4A](#), the positive control group showed a non-significant increase in the serum concentration of VCAM-1

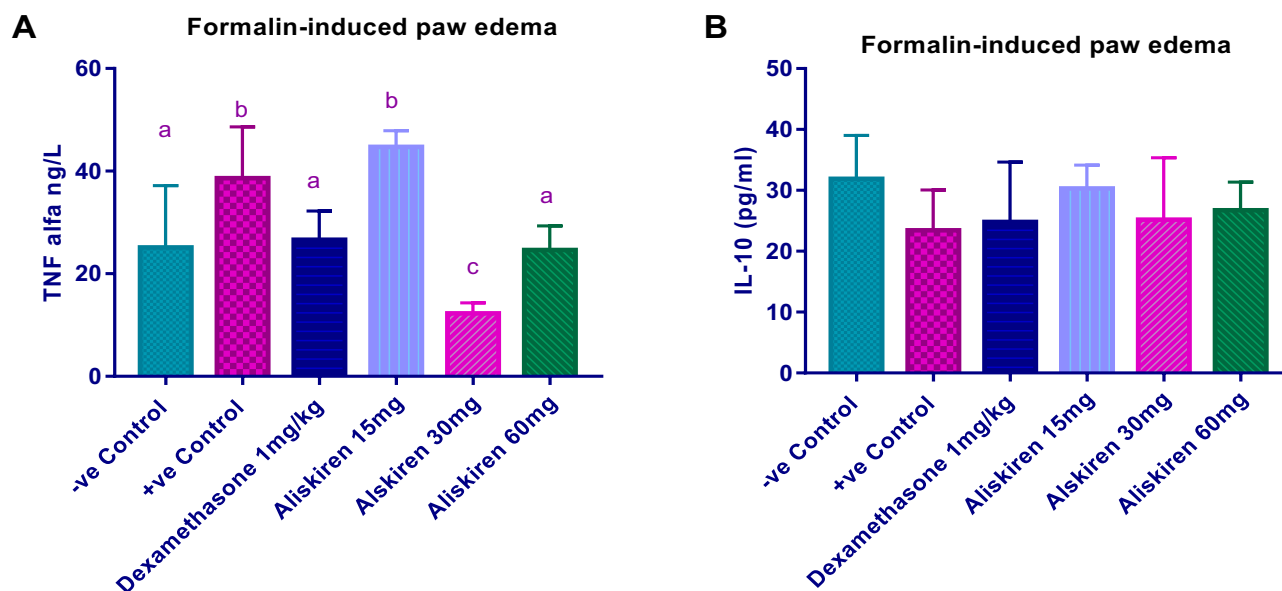


Figure 3 (A) Effect of different doses of aliskiren on the serum levels of TNF- α in the paw edema model of inflammation; values with non-identical letters (a, b, c) are significantly different using ANOVA and post hoc test ($p < 0.05$). (B) Effect of different doses of aliskiren on the serum levels of IL-10 in the paw edema model of inflammation.

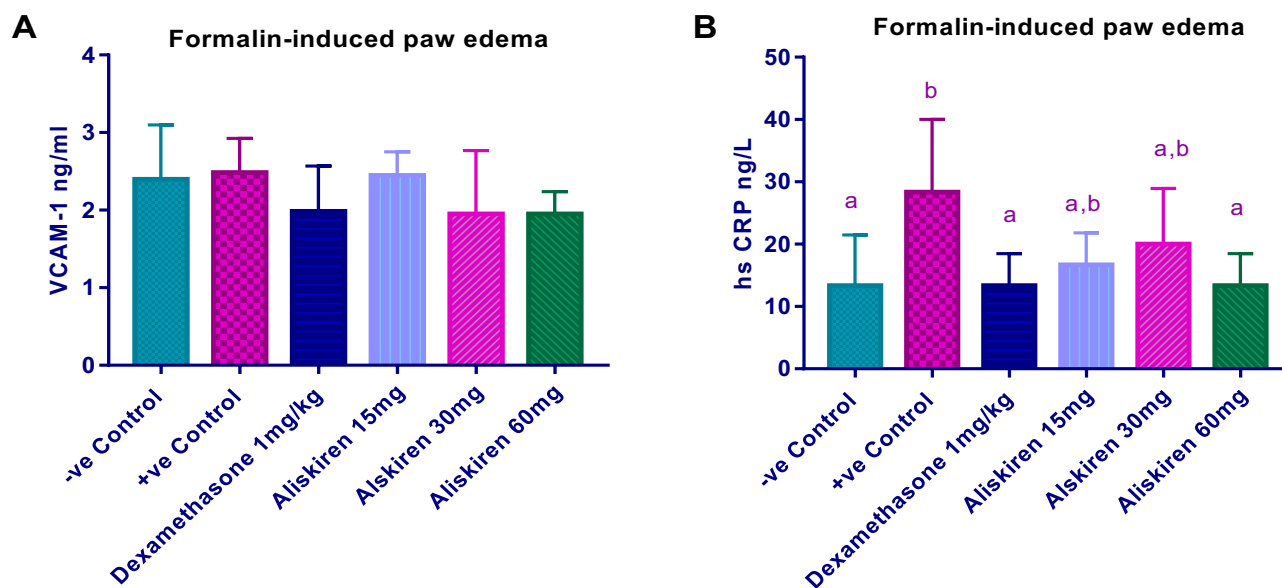


Figure 4 (A) Effect of different doses of aliskiren on the serum levels of VCAM-1 in the paw edema model of inflammation. (B) Effect of different doses of aliskiren on the serum levels of hs-CRP in the paw edema model of inflammation; values with non-identical letters (a, b) are significantly different using ANOVA and post hoc test ($p < 0.05$).

compared to the negative control ($p < 0.05$). The dexamethasone group, aliskiren 30 mg/kg, and aliskiren 60 mg/kg groups all saw a significant reduction in the serum concentration of VCAM-1 compared to the positive control after challenge with formalin ($p < 0.05$). Figure 4B shows that serum hs-CRP was significantly elevated in the formalin-challenged rats compared with the negative control and that the use of dexamethasone and aliskiren 60 mg/kg produced

a significant decrease in the serum concentration of hs-CRP compared with the positive control ($p < 0.05$).

Histopathology Results

Initially, as Figure 5 shows, histological tissue sections of paw edema (PE) were examined for inflammatory markers. Evident infiltration damage due to the accumulation of polymorphonuclear cells (PMNs) and collections of protein-rich

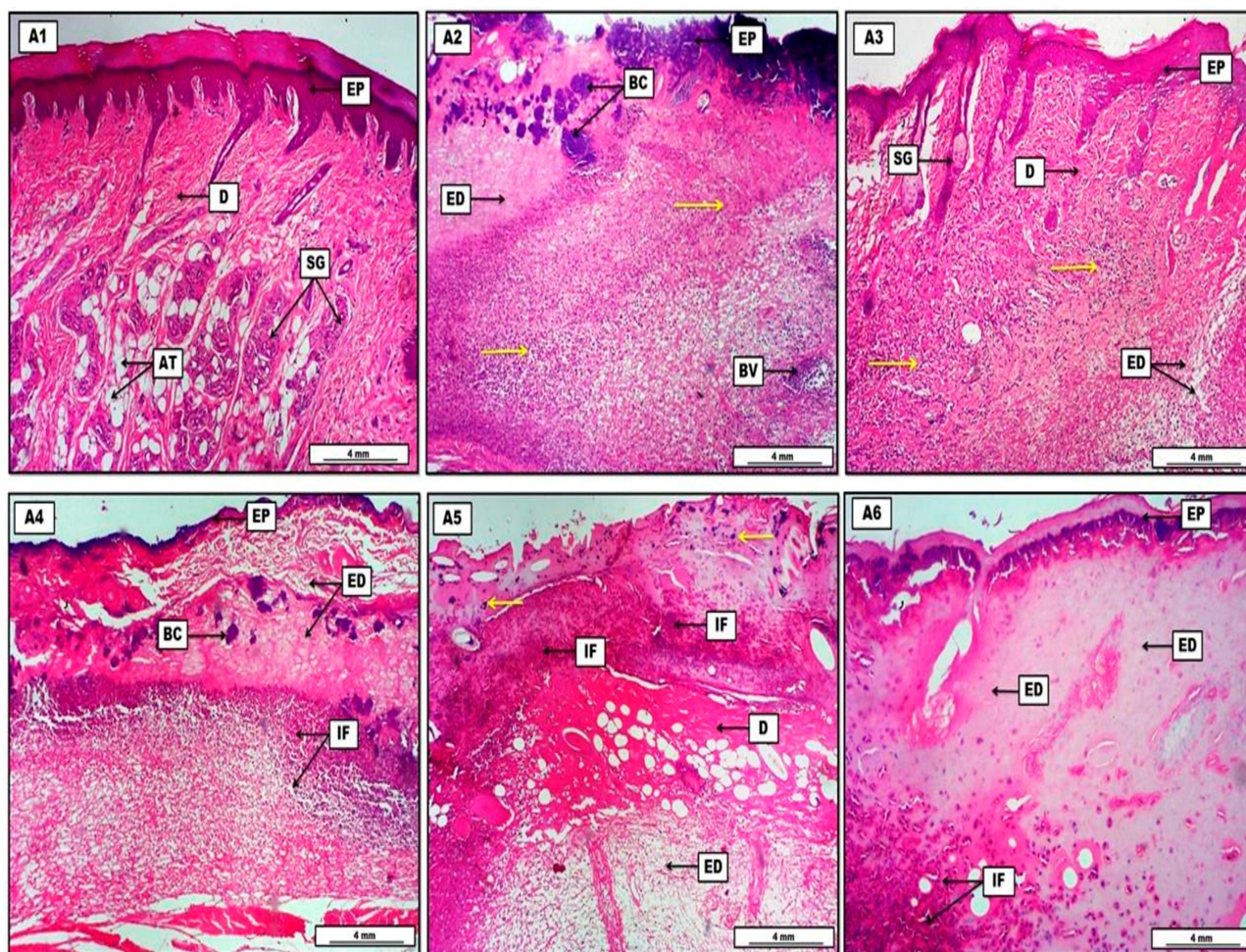


Figure 5 Photomicrograph of skin from groups. **(A1)** Control group, displays normal morphological organization of the epidermis (EP), presence of many sebaceous glands (SG) together with adipose tissues (AT) within the typical dermis (D). **(A2)** Paw-edema positive group, shows significant infiltration of polymorphonuclear inflammatory cells (yellow arrows), associated with severe pinkish edematous fluid (ED), some blood vessels (BV) within the dermis are engorged with inflammatory cells, and the section shows many bacterial colonies (BC) just under inflamed epidermis (EP). **(A3)** Paw edema with dexamethasone 1 mg/kg group, reveals significant reduction in the amount of edema (ED) and the number of inflammatory cells (yellow arrows) within the dermis (D), and the section displays constant regeneration of the epidermal layers (EP) together with some sebaceous glands (SG). **(A4)** Paw edema with aliskiren 15 mg/kg group, shows some regenerative changes within the epidermis (EP), the dermis still contains a significant amount of eosinophilic edema (ED) and significant numbers of inflammatory cells (IF), and the presence of some basophilic bacterial colonies (BC) within the dermis. **(A5)** Paw edema with aliskiren 30 mg/kg group, displays a reduction in the numbers of inflammatory cells (IF) and bacterial colonies (yellow arrows), the dermis (D) still infiltrated with edematous fluid (ED). **(A6)** Paw edema with aliskiren 60 mg/kg group, shows obvious reduction in the inflammatory cells (IF), presence of various amount of light pinkish proteinaceous edema (ED) within the dermis, and the epidermis (EP) reveals noticeable morphological regeneration. H&E. Scale bars: 4 mm.

edematous fluid accompanied by severe inflammatory exudates were found within the dermis of animals from the paw-edema positive group (A2), in comparison to the control negative group (A1), which showed no signs of acute inflammatory infiltration. In contrast, animals treated with an anti-inflammatory drug (dexamethasone 1 mg/kg) in group A3 showed significant reduction in all morphometric inflammatory markers in comparison with the paw-edema positive group. The semi-quantitative morphometric calculations and lesion scoring in the acute inflammatory model are illustrated in Table 3. Here, treatment with aliskiren (Als) revealed a significant ($p < 0.05$) reduction in the amount of inflammatory exudates and PMNs, as shown in Figure 5. Hence, the

anti-inflammatory effect of aliskiren was more significant in groups A5 (PE + Als30mg) and A6 (PE + Als60mg), in a dose-dependent manner, in comparison with A4 (PE + Als 15mg), as presented in Table 3. Hence, treatment with 60 mg/kg of aliskiren created a marked decrease in the inflammatory reaction, evident in the significant reduction in the amount of inflammatory exudates. Table 4 demonstrates the semi-quantitative morphometric assay and lesion grading in the chronic model of inflammation, represented by foreign-body granuloma induction with cotton pellets. Generally, animals in group B2 (the granuloma positive control) showed a significant increment in the area of granuloma in comparison to B1 (the control negative group), evident in a vast

Table 3 Histological Quantitative Evaluation of Paw Edema

Experimental Groups†(N=6)	Area of Edema* (Mean %)**	Inflammatory Cells (Mean %)**	Inflammatory Exudate* (Mean %)**	Lesion Scoring (0–100%)	Lesion Grading
(A1) CNG	2.9 ^{A#}	4.7 ^A	3.7 ^A	0–10	No lesion
(A2) PEC	87.4 ^E	92.3 ^E	90.8 ^E	75–100	Severe
(A3) PE + Dex	46.2 ^B	48.9 ^B	49.2 ^B	25–75	Moderate
(A4) PE + Als15mg	79.6 ^D	81.8 ^D	83.1 ^D	75–100	Severe
(A5) PE + Als30mg	59.8 ^C	63.6 ^C	65.2 ^C	25–75	Moderate
(A6) PE + Als60mg	54.7 ^C	49.6 ^B	61.8 ^C	25–75	Moderate

Notes: *Area of edema and inflammatory exudate were estimated by (µm). **Each value represents mean percentage (n = 6). #Statistical comparison among groups: mean values with different capital letters (A, B, C, D, and E) have significant differences ($p < 0.05$). †A1, control negative group; A2, paw edema positive control; A3, paw edema and dexamethasone 1 mg/kg; A4, paw edema and aliskiren 15 mg/kg; A5, paw edema and aliskiren 30 mg/kg; A6, paw edema and aliskiren 60 mg/kg.

Table 4 Histological Quantitative Evaluation of Skin Granuloma

Experimental Groups†(N=6)	Area of Granuloma* (Mean %)**	Inflammatory Cells (Mean %)**	Collagen Thickness* (Mean %)**	Lesion Scoring (0–100%)	Lesion Grading
(B1) CNG	0.2 ^{A#}	2.8 ^A	5.8 ^A	0–10	No lesion
(B2) GRC	94.3 ^E	96.1 ^E	84.6 ^D	75–100	Severe
(B3) GR + Dex	42.7 ^B	44.6 ^B	59.6 ^C	25–75	Moderate
(B4) GR + Als15mg	83.1 ^D	85.6 ^D	79.8 ^D	75–100	Severe
(B5) GR + Als30mg	62.6 ^C	59.4 ^C	61.7 ^C	25–75	Moderate
(B6) GR + Als60mg	57.2 ^C	60.3 ^C	63.1 ^C	25–75	Moderate

Notes: *Area of granuloma and collagen fiber thickness was estimated by (µm). **Each value represents mean percentage (n = 6). #Statistical comparison among groups: mean values with different capital letters (A, B, C, D, and E) have significant differences ($p < 0.05$). †B1, control negative group; B2, granuloma positive control; B3, granuloma and dexamethasone 1 mg/kg; B4, granuloma and aliskiren 15 mg/kg; B5, granuloma and aliskiren 30 mg/kg; B6, granuloma and aliskiren 60 mg/kg.

accumulation of mononuclear inflammatory cells and diffuse collagen fiber deposition. B1 indicates the normal histology of skin, as shown in Figure 6. Interestingly, animals that received therapeutic doses of aliskiren showed a significant ($p < 0.05$) reduction in the area of granuloma, indicated by a decrease in the number of chronic inflammatory cells and the amount of collagen fibers, in a dose-dependent manner. Thus, treatment with 60 mg/kg and 30 mg/kg of aliskiren in both groups B6 and B5 respectively was shown to be more effective and to create a much more significant anti-inflammatory effect than the 15 mg/kg given to group B4. However, animals treated with 1 mg/kg of dexamethasone from group B3 revealed significant morphological improvement in comparison to the granuloma positive group (B2) and the aliskiren treatment groups, as shown in both Table 4 and Figure 6.

Discussion

Many physiological and pathological processes, including inflammation and oxidative stress, are modulated by the renin–angiotensin system (RAS).^{17,18} Recently, some studies have shown that pro-inflammatory cytokines regulate RAS

components, further enhancing angiotensin II production.¹⁹ Inflammatory factors, such as VCAM-1, TNF- α , and CRP, have key roles in mediating vascular inflammation and blocking the RAAS, negatively modulating the levels of these inflammatory molecules.⁷ Renin can exacerbate the inflammatory response.¹¹ Therefore, inhibition of renin provides an attractive option for inhibiting the RAAS at its origin.²⁰ In the present study, aliskiren was able to attenuate the amount of exudate and granuloma formation significantly, in a dose-dependent manner, in the cotton-induced granuloma model of inflammation in rats and successfully inhibit paw edema formation in formalin-induced paw edema formation in rats. These results were confirmed by the biochemical tests. However, the effect of a 30 mg/kg dose of aliskiren on some of the inflammatory markers was more pronounced than the effect produced by 60 mg/kg, but the patterns noticed in their effect on granuloma and paw edema formation and in the histopathological findings, became more prominent in a dose-dependent manner. Serum concentrations of TNF- α significantly decreased in both models of inflammation. TNF- α is one of the main proinflammatory cytokines that regulate the

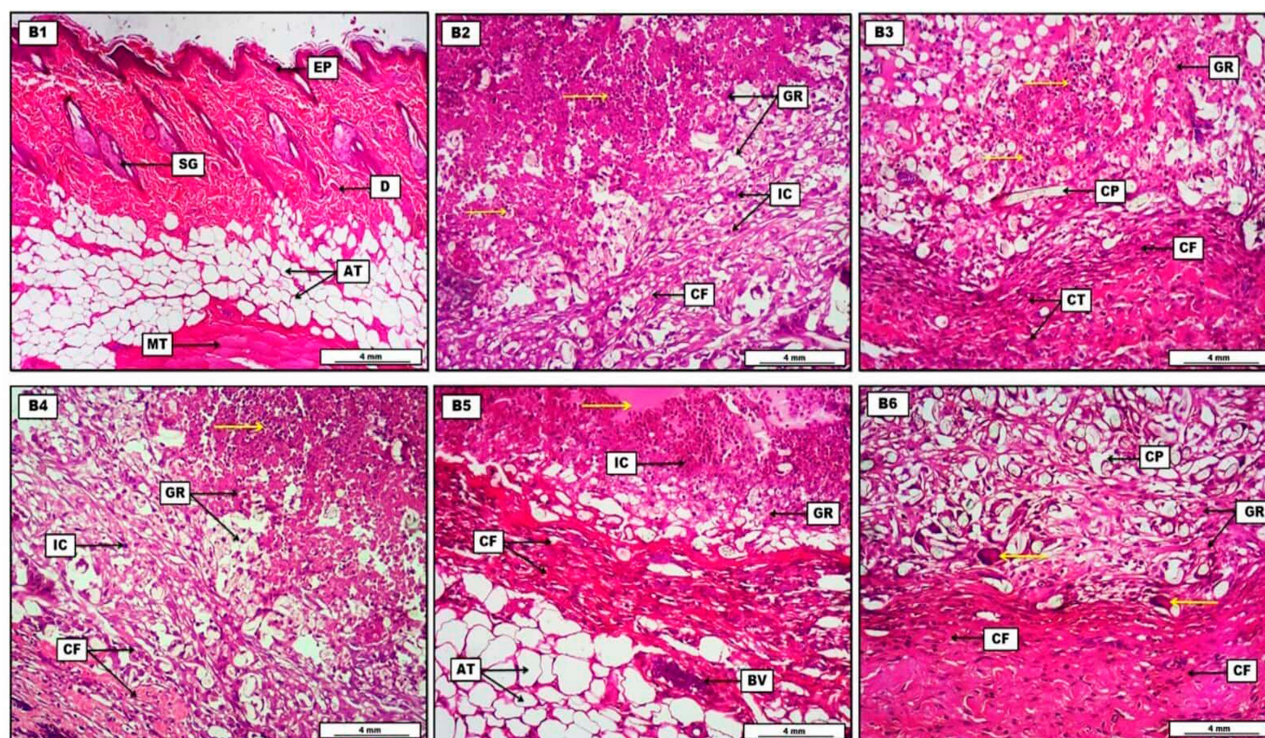


Figure 6 Photomicrograph of skin from groups. **(B1)** Control group, demonstrates typical morphological arrangement of the epidermis (EP) and dermis (D), with the presence of several sebaceous glands (SG) and a considerable amount of adipose tissues (AT), and some muscle tissue (MT) can be seen within the skin section. **(B2)** Granuloma positive group, shows the granuloma area (GR) infiltrated with a substantial amount of inflammatory exudate, cells and fluid (yellow arrows). The granuloma is bounded with proliferated fibrous connective tissue (CT) and infiltrated with chronic inflammatory cells (IC). **(B3)** Granuloma with dexamethasone 1 mg/kg group, reveals apparent reduction in the number of inflammatory cells and exudate (yellow arrows) within the granuloma (GR), which is surrounded with an area of connective tissue (CT) consisting of many proliferated collagen fibers (CF), and the granuloma area shows longitudinal sections of cotton pellet (CP). **(B4)** Granuloma with aliskiren 15 mg/kg group, shows a significant amount of inflammatory exudate infiltration (yellow arrows), the granuloma (GR) is localized by collagen fiber proliferation (CF) and many inflammatory cells (IC), and epithelioid tissue. **(B5)** Granuloma with aliskiren 30 mg/kg group, displays significant reduction of inflammatory exudate (yellow arrows) and inflammatory cells (IC), and the granuloma (GR) is encircled with proliferated collagen fibers (CF). The section reveals engorged blood vessel with inflammatory cells (BV) and many numbers of adipocytes (AT). **(B6)** Granuloma with aliskiren 60 mg/kg group, shows significant reduction in the inflammatory exudate and the size of the granuloma (GR), together with presence of various sections of cotton pellet (CP) within the granuloma area. Multinucleated foreign body giant cells (yellow arrows) can be evident, and increased proliferative amount of collagen fibers (CF) which confined the granuloma. H&E. Scale bars: 4 mm.

inflammatory signaling pathways in nearly all types of cells.²¹ The findings of this study were in line with those of another study,¹² and could be attributed to the anti-cytokine activity.²² Many studies prove the involvement of the RAAS in the inflammatory process, since any increase in the activity of the RAAS may trigger a proinflammatory effect and lead to cellular dysfunction.^{23,24}

Another important anti-inflammatory cytokine tested in this study was IL-10. Interleukin-10 plays a pivotal role in preventing inflammatory response,²⁵ and some studies have shown that a lack of IL-10 causes increased expression of inflammatory mediators.^{26,27} Although the reduction in the serum concentration of IL-10 in the current study was not statistically significant in either models of inflammation, aliskiren was able to restore its concentration. The study also revealed a non-significant increase in the serum concentration of VCAM-1, with a significant increase in the serum

concentration of hs-CRP in both models of inflammation; the use of Aliskiren was effective in significantly reducing serum concentrations of VCAM-1 and hs-CRP. The increase in serum concentration of VCAM-1 may be an indicator of vascular inflammation, vascular permeability, and endothelial dysfunction.²⁸ The significant increase in hs-CRP indicates systemic inflammation, since hs-CRP is produced in response to IL-6.²⁹ It is clear that renin is the rate-limiting enzyme of the RAS, which may contribute to the induction of inflammation via the release of cytokines that mediate the tissue inflammatory process.³⁰ Medications suppressing the RAAS from its origin may show anti-inflammatory activity.³¹ Furthermore, a remarkable improvement, in a dose-dependent manner, was noticed in the histopathology with the use of different doses of aliskiren, which could be attributed to the ability of aliskiren to decrease the concentration of inflammatory factors.³² This finding was confirmed by our study.

Conclusion

In the current study, aliskiren was successful in decreasing the amount of exudate and granuloma in the cotton-induced granuloma model of inflammation and also attenuated the amount of edema formation in the formalin-induced paw edema model of inflammation. Moreover, aliskiren was able to decrease inflammatory markers, such as TNF- α , VCAM-1, and hs-CRP, and increase the level of the anti-inflammatory cytokine IL-10 in both models of inflammation.

Acknowledgments

The authors appreciate the College of Pharmacy, University of Sulaimani for its support and for providing facilities for this project.

Disclosure

The authors report no conflicts of interest in this work.

References

- Saha A, Ahmed M. The analgesic and anti-inflammatory activities of the extract of *Albizia lebbek* in animal model. *Pak J Pharm Sci.* 2009;22(1):74–77.
- Chen L, Deng H, Cui H, Fang J, Zuo Z. Inflammatory responses and inflammation-associated diseases in organs. *2018*;9(6):7204–7218.
- Lawrence T. The nuclear factor NF-kappaB pathway in inflammation. *Cold Spring Harb Perspect Biol.* 2009;1(6):1–11. doi:10.1101/cshperspect.a001651
- Schneider JP. Chronic musculoskeletal pain: rational use of opioid analgesics, Part 2. *Consultant.* 2010;50(10):142–148.
- Harirforoosh S, Asghar W, Jamali F. Adverse effects of nonsteroidal antiinflammatory drugs: an update of gastrointestinal, cardiovascular and renal complications. *J Pharm Pharm Sci.* 2013;16(5):821–847. doi:10.18433/j3vw2f
- Oray M, Abu Samra K, Ebrahimiadib N, Meese H, Foster CS. Long-term side effects of glucocorticoids. *Expert Opin Drug Saf.* 2016;15(4):457–465. doi:10.1517/14740338.2016.1140743
- Pacurari M, Kafoury R, Tchounwou PB, Ndebele K. The renin-angiotensin-aldosterone system in vascular inflammation and remodeling. *Int J Inflamm.* 2014;2014:689360. doi:10.1155/2014/689360
- Pimenta OS. Role of aliskiren in cardio-renal protection and use in hypertensives with multiple risk factors. *Ther Clin Risk Manag.* 2009;459. doi:10.2147/TCRM.S5702
- Nguyen G, Delarue F, Burcklé C, Bouzahir L, Giller T, Sraer J-D. Pivotal role of the renin/prorenin receptor in angiotensin II production and cellular responses to renin. *J Clin Invest.* 2002;109(11):1417–1427. doi:10.1172/jci14276
- Šunjic V, Parnham MJ. Aliskiren Fumarate. In: *Signposts to Chiral Drugs*. Basel: Springer Basel;2011:13–27. doi:10.1007/978-3-0348-0125-6_2
- Oliveira SHP, Brito VGB, Frasnelli SCT, et al. Aliskiren attenuates the inflammatory response and wound healing process in diabetic mice with periodontal disease. *Front Pharmacol.* 2019;10:(July):1–16. doi:10.3389/fphar.2019.00708
- Patel RB, Pawar VD, Prajapati KD, et al. Anti-nociceptive and anti-allodynic activity of aliskiren in various pain models. *Eur J Pharmacol.* 2013;708(1–3):80–87. doi:10.1016/j.ejphar.2013.03.036
- Kaushik D, Kumar A, Kaushik P, Rana AC. Analgesic and anti-inflammatory activity of *pinus roxburghii* sarg. *Adv Pharmacol Sci.* 2012;245431. doi:10.1155/2012/245431
- Lagishetty C, Naik S. Polyamines: potential anti-inflammatory agents and their possible mechanism of action. *Indian J Pharmacol.* 2008;40(3):121–125. doi:10.4103/0253-7613.42305
- Chang JY, Lewis A. *Pharmacological Methods in the Control of Inflammation*. A.R. Liss; 1989.
- Liju VB, Jeena K, Kuttan R. An evaluation of antioxidant, anti-inflammatory, and antinociceptive activities of essential oil from *Curcuma longa*. L. *Indian J Pharmacol.* 2011;43(5):526–531. doi:10.4103/0253-7613.84961
- Xue B, Yu Y, Zhang Z, et al. Leptin mediates high-fat diet sensitization of angiotensin II-elicited hypertension by upregulating the brain renin-angiotensin system and inflammation. *Hypertension.* 2016;67(5):970–976. doi:10.1161/HYPERTENSIONAHA.115.06736
- Zablocki D, SJ. Angiotensin II and oxidative stress in the failing heart. *Antioxidants Redox Signal.* 2013;19(10):1095–1109. doi:10.1089/ars.2012.4588
- Cortes-Penfield NW, Barbara W, Trautner RJ. Inflammation as a regulator of the renin-angiotensin system and blood pressure. *Physiol Behav.* 2017;176(5):139–148. doi:10.1016/j.physbeh.2017.03.040
- Drawz P, Ghazi L. Advances in understanding the renin-angiotensin-aldosterone system (RAAS) in blood pressure control and recent pivotal trials of RAAS blockade in heart failure and diabetic nephropathy. *F1000Research.* 2017;6. doi:10.12688/f1000research.9692.1
- Parameswaran N, Patial S. Tumor necrosis factor- α signaling in macrophages. *Crit Rev Eukaryot Gene Expr.* 2010;20(2):87–103. doi:10.1615/CritRevEukaryotGeneExpr.v20.i2.10
- Patel RB. Anti-cytokine and anti-hyperalgesic effects of aliskiren in experimental models of inflammation. *2014*;4(1):125–133.
- Sever PS, Gradman AH, Azizi M. Managing cardiovascular and renal risk: the potential of direct renin inhibition. *J Renin-Angiotensin-Aldosterone Syst.* 2009;10(2):65–76. doi:10.1177/1470320309104662
- Müller DN, Luft FC. Direct renin inhibition with aliskiren in hypertension and target organ damage. *Clin J Am Soc Nephrol.* 2006;1(2):221–228. doi:10.2215/CJN.01201005
- Sabat R, Grütz G, Warszawska K, et al. Biology of interleukin-10. *Cytokine Growth Factor Rev.* 2010;21(5):331–344. doi:10.1016/j.cytogfr.2010.09.002
- Ko F, Yu Q, Xue QL, et al. Inflammation and mortality in a frail mouse model. *Age (Omaha).* 2012;34(3):705–715. doi:10.1007/s11357-011-9269-6
- Hanada T, Yoshimura A. Regulation of cytokine signaling and inflammation. *Cytokine Growth Factor Rev.* 2002;13(4–5):413–421. doi:10.1016/S1359-6101(02)00026-6
- Risler N, Castro C, Cruzado M, González S, Miatello R. Early changes in proteoglycans production by resistance arteries smooth muscle cells of hypertensive rats. *Am J Hypertens.* 2002;15(5):416–421. doi:10.1016/S0895-7061(02)02263-X
- Cruzado MC, Risler NR, Miatello RM, Yao G, Schiffrin EL, Touyz RM. Vascular smooth muscle cell NAD(P)H oxidase activity during the development of hypertension: effect of angiotensin II and role of insulinlike growth factor-1 receptor transactivation. *Am J Hypertens.* 2005;18(1):81–87. doi:10.1016/j.amjhyper.2004.09.001
- Paul M, Mehr AP, Kreutz R. Physiology of local renin-angiotensin systems. *Physiol Rev.* 2006;86(3):747–803. doi:10.1152/physrev.00036.2005
- Ames MK, Atkins CE, Pitt B. The renin-angiotensin-aldosterone system and its suppression. *J Vet Intern Med.* 2019;33(2):363–382. doi:10.1111/jvim.15454
- Karakousis K, Pinakas V, Kontovos L, Gavra M, Pinaka O. Pleiotropic effect of aliskiren in reducing levels of hscrp and fibrinogen when added as treatment in patients previously in treatment with valsartan and amlodipine plus valsartan: PP.24.484. *J Hypertens.* 2010;28:e391. doi:10.1097/01.hjh.0000379410.77854.c9

Drug Design, Development and Therapy

Dovepress

Publish your work in this journal

Drug Design, Development and Therapy is an international, peer-reviewed open-access journal that spans the spectrum of drug design and development through to clinical applications. Clinical outcomes, patient safety, and programs for the development and effective, safe, and sustained use of medicines are a feature of the journal, which has also

been accepted for indexing on PubMed Central. The manuscript management system is completely online and includes a very quick and fair peer-review system, which is all easy to use. Visit <http://www.dovepress.com/testimonials.php> to read real quotes from published authors.

Submit your manuscript here: <https://www.dovepress.com/drug-design-development-and-therapy-journal>