

Evaluation of the effect of formic acid and sodium formate on hair reduction in rat

Mahnaz Banihashemi^{1,2}
Abolfazl Khajavi Rad²
Seyed Abbas Tabatabaee
Yazdi²
Hasan Rakhshande²
Vahid Mashayekhi
Ghoyonlo^{1,2}
Zahra Zabihi³
Hadis Yousefzadeh⁴

¹Research Center for Skin Diseases and Cutaneous Leishmaniasis, Ghaem Hospital, ²School of Medicine, Mashhad University of Medical Sciences (MUMS), Mashhad, Iran; ³Neishabour Medical University, Neishabour, Iran; ⁴Young Researchers Club, Islamic Azad University, Mashhad Branch, Mashhad, Iran

Abstract: Hirsutism is a common problem in dermatology that imposes high socioeconomical costs on medical care. Consequently, researchers are actively searching for cheaper and safer methods for therapeutic treatment. The objective of the present study is to evaluate formic oil, enriched from formic acid, for the removal of unwanted hair. In this study, 32 female rats (150–200 g) were randomly divided into four groups and maintained with normal water and food availability. A patch of skin was shaved on each rat for application of test solutions. The control group was treated with local once-daily applications of normal saline. The formic acid, acetic acid, and sodium formate groups were treated with once-daily applications of formic acid (pH 5.5), acetic acid (pH 5.5), or sodium formate, respectively. After 2 weeks, horizontally cut sample biopsies were removed, and the numbers of hair follicles were counted under high field microscopy by a specialist blinded to the treatments. Kolmogorov–Smirnov test results indicated a nonparametric distribution for the rat groups. ANOVA analysis indicated no statistically significant differences between groups ($P < 0.05$). There weren't any side effects or evidence for toxicity during the study period. However, hair follicle counts showed a descending order of control, acetic acid, formic acid, and sodium formate. Although the sodium formate group had the lowest hair follicle numbers, the difference was not statistically significant ($P > 0.05$). Formic acid was not effective in reducing hair follicle numbers in rats.

Keywords: hair removal, hirsutism, hair follicles

Introduction

Hirsutism, defined as thick male patterned hair in females, affects 5%–10% of females.¹ Treatment of hirsutism imposes high costs to patients. Most systematic treatments of hirsutism include anti-androgens, and although a lack of high levels of androgen can be helpful, this treatment has side effects, and its beneficial effects wear off some months after discontinuation of the treatment.^{2,3} Hair epilation, defined as temporary hair removal by waxing, shaving, and threading, has also been used for a long time. Epilation or follicle destruction has also been performed by physical methods such as electrolysis and photoepilation. However, researchers are still seeking safer and more economical methods of treatment. Therefore, permanent hair reduction by topical substances has frequently been at the center of attention. One topical treatment approved for use is eflornithine hydrochloride, which is used for face hirsutism. An ornithine inhibitor, eflornithine hydrochloride was originally used as an oral therapy to cure hyperactivity in children. A few studies have revealed that topical application of eflornithine hydrochloride can also decrease the rate of facial hair growth,^{4,5} although it does not eliminate it.⁶ In addition, it has been used therapeutically for the use of

Correspondence: Hadis Yousefzadeh
Young Researchers Club, Islamic Azad
University, Mashhad Branch,
Mashhad, Iran
Tel +98 511 841 0135
Fax +98 511 841 4499
Email hadis_yousefzadeh@yahoo.com

laser epilation.⁷ In some regions of Iran, ant oil is traditionally used to prevent unwanted hair growth.⁸ Large desert-dwelling ants are ground up and mixed with lily or olive oil, and this oil is applied to the skin surface, where it causes hair follicle destruction and inhibition of hair growth.

In some parts of southeastern Iran, ant clay is applied to an infant's pubic area and underarms; after puberty, the hair density in these areas is greatly reduced. In addition, cases of alopecia have been reported in the areas following ant stings.⁹ Infrared techniques have confirmed the presence of formic acid in ant clays so its active ingredient is believed to be formic acid. Indirect support for this is provided by the fact that formic acid (also known as metanoic acid), a decalcifying agent, is used in leather factories and tanneries to remove hair from animal hides.^{10,11} Effects of formic acid were consistent with those of irritant chemicals administered by inhalation exposure in rats, and there wasn't any substantial evidence for its systemic toxicity in female and male rats.¹⁰ Based on this possibility, we decided to study the effects of formic acid and its salt on the reduction of unwanted hair. Since prolonged contact with formic acid may result in renal or hepatic damage, as well as genetic mutation, this study was carried out on rats.

Methods and materials

Formic acid and sodium formate were obtained from Sigma Aldrich (Munich, Germany). A total of 32 female rats (Fischer 344/N rats), weighing 150–200 g, were obtained from the Department of Physiology of Mashhad University of Medical Sciences, Iran. Rats were randomly divided into four equal groups. Water and suitable nourishment were available for all rats in their cages throughout the study. An area of the skin (2 cm × 2 cm above the tail area; selected due to good accessibility) was shaved, and then the test substance was topically applied to the shaved area, on a daily basis for 2 weeks. The test groups included a control group treated with normal saline, an acidity control group treated with acetic acid (pH 5.5) (controlled for effects of acidity and caustic properties), a formic acid (pH 5.5) treatment group; and a sodium formate treatment group. We considered all probable side effects including rash, redness, and swelling during the study period. They were weighed, and horizontal biopsies were taken from the center of treatment areas. Numbers of included biopsies in the evaluation process from each group are presented in Table 1. The tissues were coded, and the numbers of hair follicles were counted in three areas using a high power microscope field (HPF) by a pathologist who was blinded to the codes.

Table 1 Mean number of counted hair follicles in three HPFs of each group

Group	N ^a	Mean	SD
Control-I (normal saline)	12	23.16000	4.949747
Control-I (acetic acid)	19	18.84111	6.058371
Acid formic	17	17.70286	7.778767
Sodium format	14	15.58000	5.678908

Note: ^aNumber of biopsies included in our study.

Abbreviations: HPF, high power microscope field; SD, standard deviation.

Statistical analysis

All data were analyzed by the Statistical Package for Social Sciences (SPSS) for Windows™ software package (v 11.5; SPSS Inc, Chicago, IL). Data were expressed as mean ± standard deviation. A Kolmogorov–Smirnov test showed that our groups had a nonparametric distribution. Analysis of variance (ANOVA) or Kruskal–Wallis tests were used to compare variables (probable side effects and counted hair follicles) between the groups. A two-tailed *P*-value < 0.05 was considered statistically significant.

Results

After 2 weeks, the rats all appeared healthy without any local side effects, such as redness or swelling, or evidence of any systemic toxicity in all four studied groups. The mean number of counted hair follicles in three HPFs of each group is presented in Table 1. The sodium formate group (15.58 ± 5.6) had the lowest count for hair follicles. The total hair follicle counts, in decreasing order, were: the control group, the acetic acid group, the formic acid group, and the sodium formate group. The hair follicle counts for the acetic acid treatment were lower than for normal saline, although these differences were not statistically significant (*P* = 0.067). A macroscopic view of the results for each group is presented in Figure 1. These figures showed that rats treated with formic acid and sodium formate had lower numbers of hairs in comparison to both control groups.

The microscopic follicle counts (Figure 2) also showed that the sodium formate group had the lowest hair follicle numbers, although this decrease was not significantly different from the other groups (*P* < 0.05). The formic acid and sodium formate groups had fewer hair follicles than the control group.

Discussion

Many therapeutic options are available for the treatment of hirsutism; nevertheless, no rapid treatment has yet been developed because the exact mechanism of the effects of androgens on hair follicles on different parts of the body is not yet known.

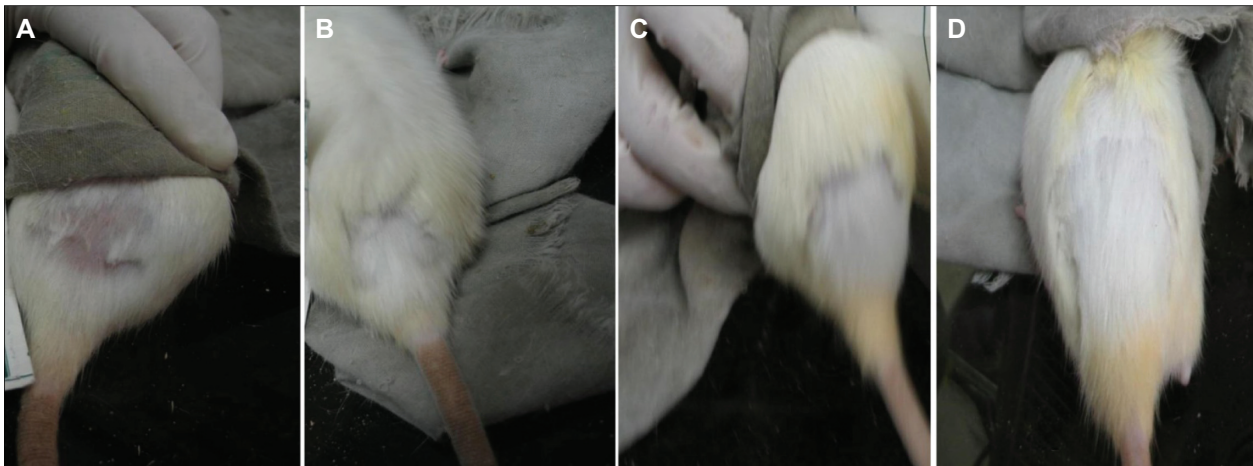


Figure 1 Macroscopic view of our studied groups: sodium format (A), formic acid (B), control with acetic acid (C), control with normal saline (D).

The aim of hair removal therapy is permanent or prolonged hair removal until the patient is satisfied with the effect. Patients usually use temporary physical methods like shaving, depilation with tweezers, threading, waxing, or chemical substances such as depilatory creams before visiting a medical doctor.¹² Electrolysis, as well as laser and light-source epilation, at least hypothetically, are methods of “permanent depilation”.^{2,13} Photoepilation therapy, including the use of lasers and light sources, acts by damaging hair follicles. However, these treatments are expensive and require several sessions.¹⁴

For these reasons, researchers continue to seek local, safer, more economical, and rapid therapeutic methods. Formic acid, as a simple member of the carboxylic acid family, is a colorless, volatile substance that is soluble in water, alcohol, and acetone. It is a common constituent in the stings of insects like ants and bees, as well as in nettle leaf. It is used for medical purposes and has chemical and industrial uses. Formic acid is absorbed by the skin and is oxidized to

carbon dioxide and water and excreted in the urine. Formic acid application is rare in dermatological treatment; it is only used for the treatment of common warts,¹⁵ where its effects may be due to dehydration and damage. In addition, it is used for nit removal after treatment by pediculocides.¹⁶

In our study, toxic effects from the formic acid were not observed, nor were any side effects including redness and swelling. Also, no statistically significant differences were noted in rats treated with formic acid that could be attributed to damage to the hair follicles. However, there were apparent reductions in the numbers of hair follicles and in the hair density in the treated groups when compared with the control group. Decreased hair may be caused by caustic or dehydration properties of formic acid that has entered the follicular pore after hair removal, resulting in histological and hair follicle destruction. Therefore, we recommend further studies be directed at understanding the effects of formic acid on rat hair growth, with longer study durations.

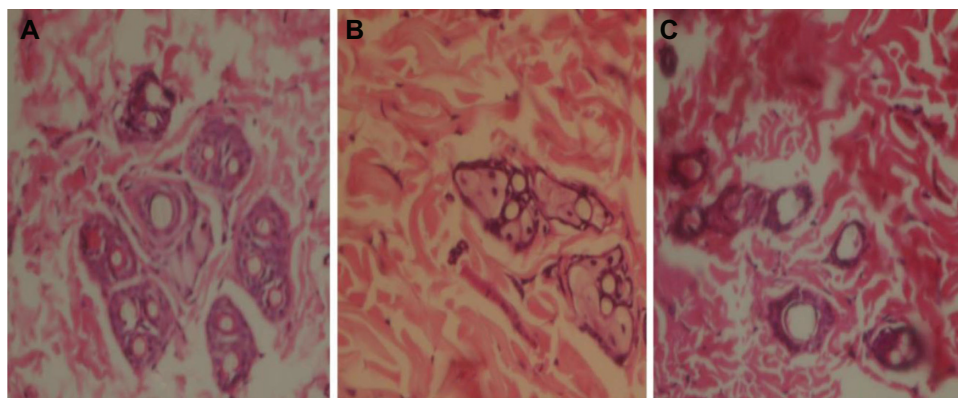


Figure 2 Microscopic view of three high power fields: control (A), formic acid (B), and sodium formate (C).

Note: The authors could not take a good photo from acetic acid high power field.

Acknowledgment

The authors greatly acknowledge the Research Council of Mashhad University of Medical Sciences (MUMS) for financial support of the study.

Disclosure

The authors report no conflicts of interest in this work.

References

- McKnight E. The prevalence of hirsutism in young women. *Lancet*. 1964;1(7330):410–413.
- Messenger AG, Berker DAK, Sinclair KD. Disorders of hair. In: Burns T, Breathnach S, Cox N, et al. *Rook's Textbook of Dermatology*. 8th ed. New York: Wiley-Blackwell; 2010:66:80–89.
- Yücelten D, Erenus M, Gürbüz O, Durmuşoğlu F. Recurrence rate of hirsutism after 3 different antiandrogen therapies. *J Am Acad Dermatol*. 1999;41(1):64–68.
- Wolf JE Jr, Shander D, Huber F, et al; for the Eflornithine HCl Study Group. Randomized, double-blind clinical evaluation of the efficacy and safety of topical eflornithine HCl 13.9% cream in the treatment of women with facial hair. *Int J Dermatol*. 2007;46(1):94–98.
- Hoffmann R. A 4-month, open-label study evaluating the efficacy eflornithine 11.5% cream in the treatment of unwanted facial hair in women using Trich Scan. *Eur Dermatol*. 2008;18(1):65–70.
- Blume-Peytavi U, Hahn S. Medical treatment of hirsutism. *Dermatol Ther*. 2008;21(5):329–339.
- Hamzavi I, Tan E, Shapiro J, Lui H. A randomized bilateral vehicle-controlled study of eflornithine cream combined with laser treatment versus laser treatment alone for facial hirsutism in women. *J Am Acad Dermatol*. 2007;57(1):54–59.
- Khosravi A. *Sina Traditional Medicine*. 2nd ed. Tehran Publication. 1995. [In Persian].
- Radmanesh M, Mousavipour M. Alopecia induced by ants. *Trop Med Hyg*. 1999;93:427.
- Thompson M. NTP technical report on the toxicity studies of formic acid (CAS No. 64-18-6) administered by inhalation to F344/N rats and B6C3F1 mice. *Toxic Rep Ser*. 1992;19:1D–D3.
- Schubert D. IC-07 leather processing industry – assessment of the environmental release of chemicals from the leather processing industry. *Umweltbundesamt Berlin*. 1998 Jul 28:1–13.
- Oslen EA. Methods of hair removal. *J Am Acad Dermatol*. 1999;40(2 Pt 1):143–155; quiz 156–157.
- Wanger RF. Physical methods for the management of hirsutism. *Cutis*. 1990;45:19–26.
- Alexiades-Armenakas MR, Dover JS, Arndt K. Laser therapy. In: Bologna J, Jorizzo J, Rapini R. *Dermatology*. 2nd ed. St Louis, MO: Mosby; 2008:137:2109–2111.
- Bhat RM, Vidya K, Kamath G. Topical formic acid puncture technique for the treatment of common warts. *Int J Dermatol*. 2001;40(6):415–419.
- DeFelice J, Rumsfield J, Bernstein JE, Roshal JY. Clinical evaluation of an after pediculocide nit removal system. *Int J Dermatol*. 1989;28(7):468–470.

Clinical, Cosmetic and Investigational Dermatology

Dovepress

Publish your work in this journal

Clinical, Cosmetic and Investigational Dermatology is an international, peer-reviewed, open access, online journal that focuses on the latest clinical and experimental research in all aspects of skin disease and cosmetic interventions. All areas of dermatology will be covered; contributions will be welcomed from all clinicians and

basic science researchers globally. This journal is indexed on CAS. The manuscript management system is completely online and includes a very quick and fair peer-review system, which is all easy to use. Visit <http://www.dovepress.com/testimonials.php> to read real quotes from published authors.

Submit your manuscript here: <http://www.dovepress.com/clinical-cosmetic-and-investigational-dermatology-journal>