

# Large Vesicovaginal Fistula After Vaginal Insertion of a Plastic Cap Healed with Two Weeks of Catheterization: A Case Report

Zelalem Mengistu , Zelalem Ayichew 

Department of Obstetrics and Gynecology, University of Gondar, Gondar, Ethiopia

Correspondence: Zelalem Mengistu, Department of Obstetrics and Gynecology, University of Gondar, Gondar, Ethiopia, Tel +251936380001, Email emushe10@yahoo.com

**Abstract:** Vesicovaginal fistula (VVF) in developing countries is mainly associated with obstructed labor, iatrogenic injury during cesarean delivery, and hysterectomy. However, formation of VVF after foreign body insertion into the vagina is an extremely rare phenomenon. We report on an 18-year-old girl from rural northwest Ethiopia who presented with continuous leakage of urine for 2 months. She had inserted a plastic cap into her vagina 2 years prior for an unrevealed reason. A foreign body was found in her vagina, resulting in a large VVF. Removal of the foreign body was made under spinal anesthesia. She was catheterized for 14 days and the fistula closed spontaneously. Longstanding impaction of a foreign body in the vagina is associated with VVF formation. VVF resulting from a foreign body in young women could be closed with prolonged catheterization, even for large fistulas.

**Keywords:** vaginal foreign body, vesicovaginal fistula, prolonged catheterization, plastic cap, Gondar

## Introduction

Vesicovaginal fistula (VVF) is an abnormal epithelialized or fibrous communication between the bladder and vagina. The major causes of VVF in developing countries are associated with obstructed labor, whereas in developed countries VVF results from pelvic surgery.<sup>1</sup> The mechanisms of VVF formation are often either related to necrosis of the posterior wall of the bladder and the anterior vaginal wall or direct injury creating communication between the vagina and bladder.<sup>2</sup> VVF impacts the well-being of a patient with continuous leakage of urine and resulting physical, emotional, social, and economic consequences.<sup>3</sup>

Foreign bodies rarely result in VVF formation after being inserted, regardless of reason or situation, such as for sexual gratification during sexual intercourse, for contraceptive purposes, as neglected pessaries or, rarely, during rape or as punishment.<sup>4-6</sup> We present a rare case of a large VVF after a plastic cap was inserted into the vagina. The VVF was treated with two weeks of catheterization, and the patient was discharged continent.

## Case Presentation

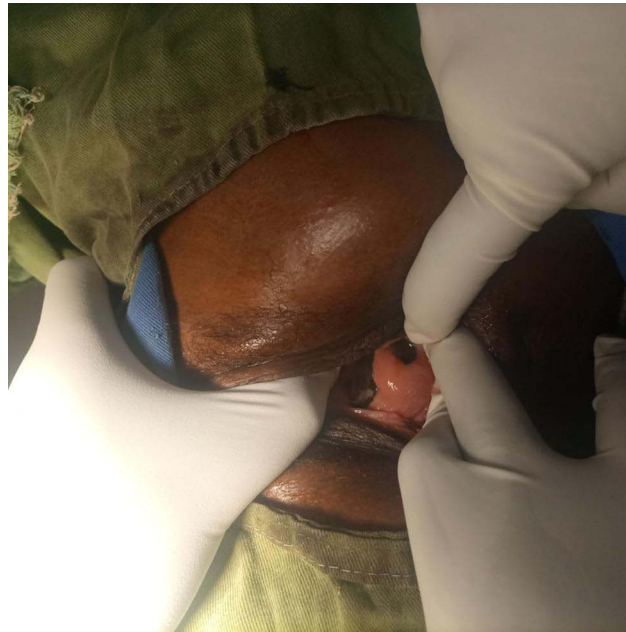
Our patient was an 18-year-old girl from rural northwest Ethiopia who was referred to the University of Gondar Urogynecology and Reconstructive Pelvic Surgery Unit after she presented to a nearby hospital with a complaint of failure to control urine of 2 months duration. She had inserted a detergent plastic cap into her vagina 2 years prior for a reason not revealed by the patient. She did not seek medical attention until she developed continuous leakage of urine. She did not have abdominal pain, abdominal distension, foul smelling vaginal discharge, or failure to pass feces and flatus. She was sexually active before the insertion of the plastic cap. She had regular menses. She had no known history of psychiatry or other medical problems. She gave a history of a significant but unquantified weight loss.

On examination, she was anxious; vital signs were within normal range. Her BMI was 17.7kg/m<sup>2</sup>. Her abdomen was flat, with no tenderness and no palpable mass. On genitourinary evaluation, she had normal looking female external

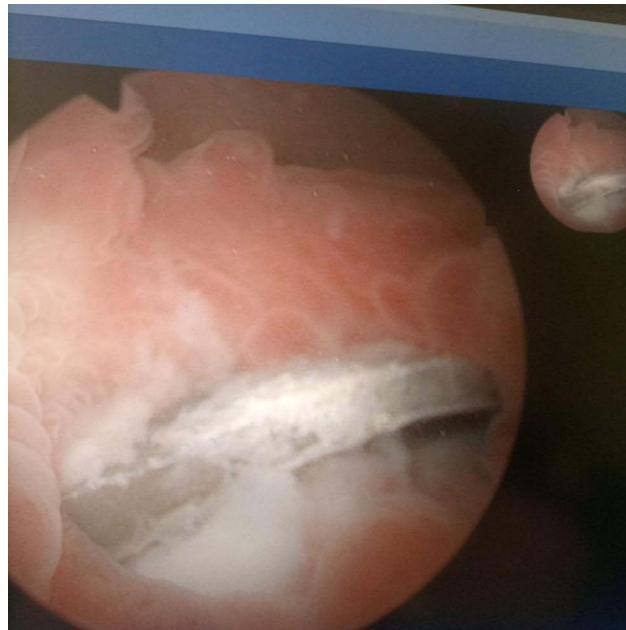genitalia with urine soaked vulva. There was a hard and tender vaginal mass obliterating the vagina with a partly visible foreign body embedded in the anterior vaginal wall (Figure 1). The urethra and the distal one-third of the vagina were intact and not involved with the foreign body.

Her hemoglobin was 13.2 g/dl. On cystoscopy, part of the plastic cap was seen eroding the posterior bladder wall, creating a large fistula covered with debris and tiny multiple bladder stones (Figure 2).

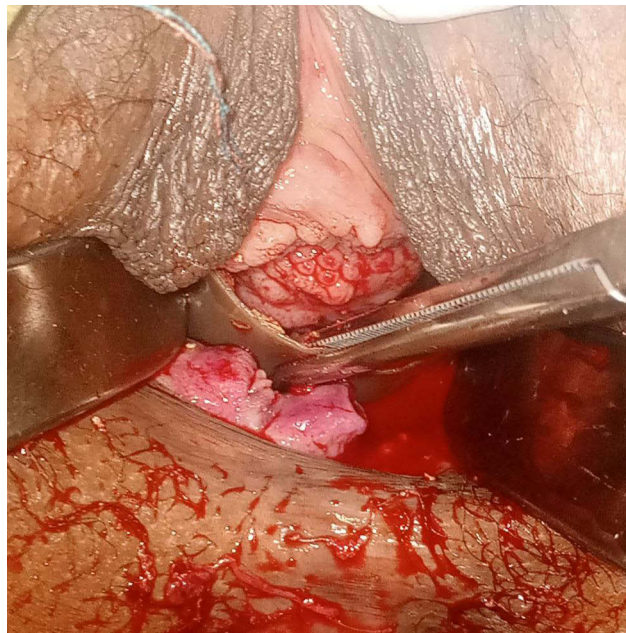It was difficult to identify ureters during the cystoscopy as the bladder base was indurated. The plastic cap was removed after dissecting the overlying granulated tissue and trimming parts of the cap embedded in the anterior vagina (Figures 3 and 4).



**Figure 1** Partly visible foreign body embedded in the anterior vaginal wall.



**Figure 2** Cystoscopy picture showing, part of the plastic cap into the posterior bladder wall, covered with debris and tiny multiple bladder stones.



**Figure 3** The plastic cap on the process of removal.



**Figure 4** The removed plastic cap.

After the removal of the cap, there was a 5cm by 4cm VVF seen from the vaginal side with indurated and fragile edges, and there was a scar band on the proximal one-third of the vagina which was divided. The fragile and scared edge of the fistula was removed and refreshed. The vaginal pack was left in situ to prevent adhesion and stenosis and removed after 48hrs. An Eighteen FR size urinary catheter connected to urine bag was left in situ for two weeks with the intention of allowing tissue healing for later repair. She was not restricted to assume any position. She had minimal urinary leakage in the first 48 hours after catheterization. Then after she was dry. Upon removal of the catheter after 14 days, the fistula was closed spontaneously, and the patient was discharged continent.

## Discussion

Though rare, insertion of a foreign body into the vagina resulting in VVF has been reported in the literature, particularly aerosol bottle caps. In most cases, the patients were young women like our patient, with a median age of 22 years (range: 8–86).<sup>7</sup> Among reasons to insert a foreign body into the vagina, both contraception and masturbation have been mentioned; however, sexual abuse should also be taken into consideration.<sup>8</sup> Many women do not present early due to fear of association with sexual gratification, and these patients rarely provide an accurate history of insertion of the foreign body. Many times, the history is obtained after the discovery of the fistula,<sup>9</sup> as observed in our patient, who presented two years after insertion with VVF. Late appearance to a health facility will have significant debilitation—physically, psychologically and socially—as seen on our patient.<sup>3</sup>

Since our patient presented late, the foreign body embedded deep within the vaginal tissue, anteriorly crossing into the bladder, causing significant fibrosis. This increased the difficulty of removal as well as immediate repair. In our case, an immediate attempt to repair the fistula was avoided due to the poor quality tissue. Hence, we inserted a urinary catheter to facilitate tissue quality for later repair after two weeks. Nonetheless, the large fistula has healed spontaneously with the catheterization and the patient was discharged continent without need of repair, which is an independent factor for success of continence.<sup>10</sup>

## Conclusion

Long-standing impaction of a foreign body in the vagina could result in VVF. Two weeks of bladder catheterization could result in healing of VVF resulting from a foreign body in young women.

## Consent

Written informed consent was obtained from the patient for publication of this case report and accompanying images. A copy of the written consent is available for review by the Editor-in-Chief of this journal.

We would like to declare that the need for approval is waived for the case report by our institutional review board (IRB).

## Acknowledgments

We would like to acknowledge the kind comments and guidance of Professor Sam Dragga on this case report.

## Disclosure

The authors declare that they have no competing interests.

## References

1. Rajaian S, Pragatheeswarane M, Panda A. Vesicovaginal fistula: review and recent trends. *Indian J Urol.* 2019;35(4):250–258. doi:10.4103/iju.IJU\_147\_19
2. Tunçalp Ö, Were WM, MacLennan C, et al. Quality of care for pregnant women and newborns—the WHO vision. *BJOG an Int J Obstet Gynaecol.* 2015;122(8):1045–1049. doi:10.1111/1471-0528.13451
3. Bashah DT, Worku AG, Mengistu MY. Consequences of obstetric fistula in sub Sahara African countries, from patients' perspective: a systematic review of qualitative studies. *BMC Womens Health.* 2018;18(1):1–12. doi:10.1186/s12905-018-0605-1
4. Massinde AN, Kihunrwa A. Large vesicovaginal fistula caused by a foreign body. *Ann Med Health Sci Res.* 2013;3(3):456–457. doi:10.4103/2141-9248.117934
5. Erian M, McLaren G. Unexpected causes of gynecological pelvic pain. *J Soc Laparoscopic Surg.* 2004;8:380–383.
6. Walker KF, Dasgupta J, Cust MP. Case report: a neglected shelf pessary resulting in a urethrovaginal fistula. *Int Urogynecol J.* 2011;22(10):1333–1334. doi:10.1007/s00192-011-1423-2
7. Elia CD, Curti P, Angela M, Carmelo C. Large urethro-vesico-vaginal fistula due to a vaginal foreign body in a 22-year-old woman: case report and literature review. *Urol Int.* 2015;95:120–124. doi:10.1159/000365421
8. Fourie T, Ramphal SU. Aerosol caps and vesicovaginal fistulas. *Int J Gynecol Obstet.* 2001;73:275–276. doi:10.1016/S0020-7292(01)00350-2
9. Siddiqui NY, Paraiso MFR. Case reports vesicovaginal fistula due to an unreported foreign body in an adolescent. *J Pediatr Adolesc Gynecol.* 2007;20:253–255. doi:10.1016/j.jpag.2006.10.003
10. Browning A. Risk factors for developing residual urinary incontinence after obstetric fistula repair. *BJOG.* 2006;113(August2005):482–485. doi:10.1111/j.1471-0528.2006.00875.x

### International Medical Case Reports Journal

Dovepress

### Publish your work in this journal

The International Medical Case Reports Journal is an international, peer-reviewed open-access journal publishing original case reports from all medical specialties. Previously unpublished medical posters are also accepted relating to any area of clinical or preclinical science. Submissions should not normally exceed 2,000 words or 4 published pages including figures, diagrams and references. The manuscript management system is completely online and includes a very quick and fair peer-review system, which is all easy to use. Visit <http://www.dovepress.com/testimonials.php> to read real quotes from published authors.

Submit your manuscript here: <https://www.dovepress.com/international-medical-case-reports-journal-journal>