

# Rapid-Deployment Aortic Valve Replacement: Patient Selection and Special Considerations

Tomoki Sakata<sup>1</sup>, Corazon De La Pena<sup>2</sup>, Suguru Ohira<sup>2</sup>

<sup>1</sup>Cardiovascular Research Institute, Icahn School of Medicine at Mount Sinai, New York, NY, USA; <sup>2</sup>Department of Surgery, Division of Cardiothoracic Surgery, Westchester Medical Center, New York Medical College, Valhalla, NY, USA

Correspondence: Suguru Ohira, Department of Surgery, Division of Cardiothoracic Surgery, Westchester Medical Center, New York Medical College, 100 Woods Road, Macy Pavilion, Valhalla, NY, 10595, USA, Tel +1 404 234 5433, Email [Suguru.Ohira@wmhealth.org](mailto:Suguru.Ohira@wmhealth.org)

**Abstract:** Sutureless or rapid deployment valves in the setting of aortic valve replacement (AVR) is an emerging surgical technique using the transcatheter valve technology, which may lead to reduction in cross-clamp time and potentially better hemodynamics compared to a stented bioprosthetic valve. The absence of subannular pledgets results to excellent hemodynamic performance with reduced turbulent flow and larger effective orifice area. However, complications from both surgical and transcatheter AVR may still occur and impact survival. The incidence of paravalvular leakage and permanent pacemaker implantation are not low. Although technical modifications can improve these outcomes, there is a learning curve effect. Therefore, technical and anatomical considerations as well as better patient selection are paramount for better outcomes. In this review, we discuss the use of sutureless or rapid deployment valves in setting of (1) complex procedures, (2) minimally invasive AVR, and (3) small aortic annulus. The advantage of sutureless or rapid deployment valves in terms of mortality remains to be clarified; therefore, it is necessary to accumulate long-term outcomes in an appropriate patient cohort.

**Keywords:** sutureless valve, rapid deployment valve, aortic valve replacement, minimally invasive cardiac surgery, paravalvular leakage, permanent pacemaker implantation

## Introduction

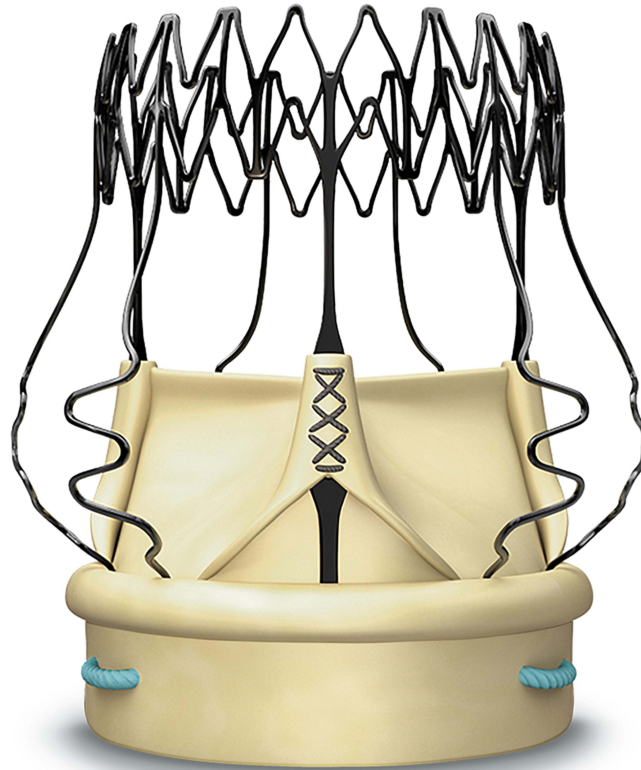
With the introduction of transcatheter technology, transcatheter aortic valve replacement (TAVR) has emerged as a valuable treatment option for high-risk patients with aortic stenosis. It has demonstrated non-inferiority to conventional surgical aortic valve replacement (SAVR) across all risk profiles, and minimally invasiveness has become an important consideration even in patients being considered for SAVR. In this context, sutureless or rapid deployment valve (SRDV) has been introduced to simplify the implantation process and reduce cross-clamp time, enabling their use in minimally invasive cardiac surgery (MICS).<sup>1-4</sup> SRDV is not only a safe and effective alternative to conventional SAVR via median sternotomy but can also facilitate minimally invasive SAVR such as upper hemisternotomy or right thoracotomy.<sup>5</sup> SRDV has been demonstrated to offer hemodynamic advantages over stented bioprosthesis<sup>2,3</sup> and may yield similar short-term outcomes including freedom from major adverse cerebrovascular and cardiovascular events.<sup>6</sup> However, high rates of permanent pacemaker implantation (PPI) and paravalvular leakage (PVL) are two potential drawbacks of SRDV compared to SAVR using a stented bioprosthesis.<sup>7,8</sup> Despite recent cumulative experiences with SRDV have been reported recently, there is no specific recommendation for SRDV in the current guidelines,<sup>9,10</sup> and the appropriate indication for SRDV is still to be defined. This review discusses the technique of SAVR using SRDV, and specific considerations including appropriate patient selection.

## Currently Available Prosthetic Valves of SRDV

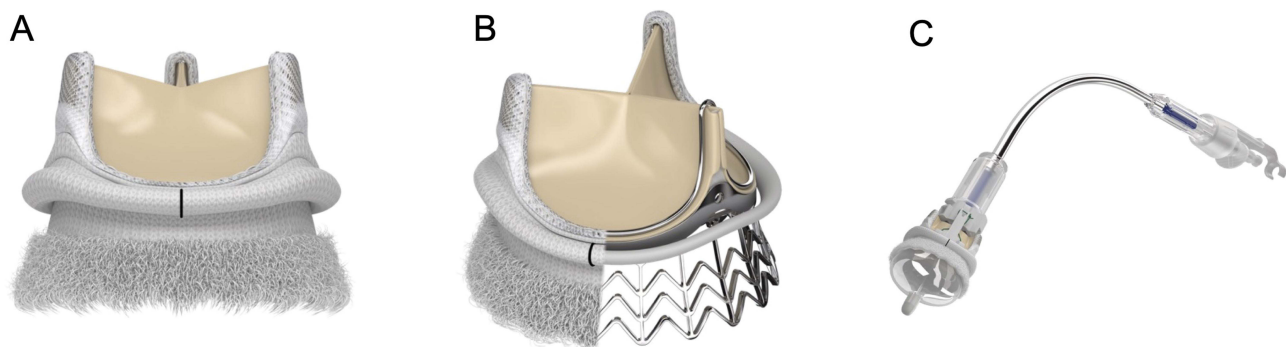
As of December 2022, two SRDVs are commercially available: a Perceval (Corcym, London, UK) and Intuity (Edwards Lifesciences, Irvine, CA, USA). Perceval is composed of bovine pericardial leaflets and a self-expandable nitinol frame

with carbofilm coating (Figure 1).<sup>11</sup> This valve is available in four sizes (S, M, L, and XL) to cover annular diameters from 19 to 27 mm. This valve is designed to land on the annulus and sino-tubular junction (STJ); thus, both diameters need to be considered for sizing of a prosthesis. Perceval valve is crimped into the delivery system and parachuted into the annular level along guiding sutures. The valve is released after positioning is visually confirmed. The guiding sutures are removed, and the valve is expanded to a dedicated size by post-dilation with a balloon catheter.

Intuity is called the rapid deployment valve which uses three guiding sutures for positioning. Its valve system is designed based on Carpentier-Edwards Perimount (Edwards Lifesciences) platform. It is composed of three bovine pericardial leaflets and a subannular balloon-expandable skirt, which works as an anchor and seal of the TAVR stent (Figure 2). The valve system is delivered along guiding sutures placed on each nadir. Finally, the balloon catheter is inflated and the subannular skirt acquires complete attachment. The three guiding sutures are tied down.



**Figure 1** Representative product image of sutureless valve (Perceval™ Plus) with permission from Corcym, London, UK. Perceval is composed of bovine pericardial leaflets and a self-expandable nitinol frame with carbofilm coating. This valve is designed to land on the annulus and sino-tubular junction. Courtesy of CORCYM Srl.



**Figure 2** Representative product images of rapid deployment valve (Edwards INTUITY Elite Valve System) with permission from Edwards Lifesciences, Irvine, CA, USA. It is composed of three bovine pericardial leaflets and a subannular balloon-expandable skirt, which works as an anchor and seal of the stent. (A) External view, (B) Subannular skirt, (C) Delivery system. Courtesy of Edwards Lifesciences.

## Advantages of Sutureless and Rapid Deployment Valves

### Reduction in Procedural Time

The salient feature of SRDV is its sutureless implantation technique, which eliminates the need for sutures in sutureless valve (Perceval) and only necessitates three guiding sutures in rapid deployment valves (Intuity), leading to a reduction of 48% in aortic cross clamp (AXC) time and 39% in cardiopulmonary pump (CPB) time.<sup>12–14</sup> SRDV provides a reduction in operative time for both full sternotomy and MICS,<sup>15–18</sup> and similar reductions are observed in complex surgeries and isolated SAVR.<sup>5,19</sup>

Prolonged CPB and AXC times trigger a systemic inflammatory response, increasing the risk of kidney injury and coagulopathy.<sup>20</sup> These factors have been independently linked to mortality and morbidity in SAVR.<sup>21–26</sup> It remains to be determined whether a decrease in operative time enhances the outcomes of SRDV. Even in the randomized controlled trial (PERSIST-AVR trial), neither in-hospital nor 1-year outcomes were impacted by SRDV implantation.<sup>6</sup> The CPB and AXC time reductions in the study were approximately 17 minutes each and ranged from 10 to 20 minutes in other studies.<sup>1,27</sup> The beneficial effect of using SRDV might be more significant in complex surgeries that necessitate longer AXC or CPB time, given that AXC time for SAVR is comparatively short.<sup>28</sup> Additionally, most reports concerning procedural time reduction have been investigated in low- to intermediate-risk SAVR patients. Further evidence is required to determine if a decrease in CPB and AXC times results in improved clinical outcomes in high-risk patients.

### Hemodynamic Status

The structure and mechanistic features of SRDV resemble those of TAVR more closely than those of conventional SAVR. Kocher et al reported a larger effective orifice area with SRDV due to the absence of a suture cuff, which remained stable even after 1 year.<sup>12</sup> Both clinical and in vitro studies have demonstrated a low-pressure gradient in SRDV.<sup>2,3,29,30</sup> Furthermore, a recent meta-analysis revealed a lower pressure gradient in SRDV than in conventional SAVR using a stented bioprosthesis.<sup>3</sup> In a study evaluating 5-year outcomes of SAVR with SRDV, excellent hemodynamic performance was consistently observed across all sizes.<sup>31</sup> Even in elderly patients with small aortic annulus, SRDV maintained a good effective orifice area.<sup>32</sup>

Various studies have demonstrated that rapid deployment valve (Intuity) exhibits a lower pressure gradient than the sutureless valve (Perceval).<sup>1,27,33</sup> This low-pressure gradient has been maintained for up to 4 years after the operation.<sup>34</sup> Subannular skirts in the rapid deployment valve (Intuity) may contribute to excellent long-term outcomes by expanding the left ventricular outflow tract<sup>33,35–37</sup> and producing laminar flow.<sup>1,2,38,39</sup> This hemodynamic advantage is important in terms of preventing patient-prosthesis mismatch (PPM), with severe PPM reported as few as 3.4% of the 700 rapid deployment valve (Intuity) cases studied.<sup>40</sup> Although some studies have suggested that PPM with SRDV is associated with adverse mortality and cardiovascular outcomes,<sup>41–43</sup> others have reported no such differences.<sup>44,45</sup> Proper size selection is crucial in mitigating PPM risk, as patients with small aortic annulus are more likely to experience PPM. SRDV has the potential to reduce PPM risk, given its superior effective orifice area compared to a stented bioprosthesis.<sup>46</sup>

### Clinical Outcomes

There is up to 10 years of clinical outcomes reported for SRDV, yet its comparative performance with SAVR using stented bioprosthesis and TAVR remains unclear. In a study of 700 rapid deployment valve (Intuity) cases with a mean age of 74, survival rates were 98%, 91%, 76%, and 58% at 1, 3, 5, and 7 years, respectively.<sup>40</sup> A meta-analysis regarding SRDV also demonstrated a 5-year survival rate of 84%, which was similar to the outcomes of SAVR using stented bioprosthesis (Mean age: male, 63 years, and female, 67 years).<sup>47</sup> In the PERSIST-AVR trial, SRDV was non-inferior to conventional SAVR with respect to MACCE at 1 year. This result must be interpreted with caution because PPI, which was higher in the SRDV group, was not included in this composite endpoint. Lloyd et al reported that early mortality was comparable among TAVR, SAVR using stented bioprosthesis and SRDV, while postoperative bleeding was less frequent in TAVR and SRDV.<sup>48</sup> Comparisons between sutureless (Perceval) and rapid deployment (Intuity) valves have been conducted using meta-analysis and propensity score matching, revealing no difference in clinical outcomes including mortality, stroke, and PVL.<sup>27,49</sup> However, procedural time was shorter in sutureless valve (Perceval), while the pressure

gradient across the prosthesis was lower in rapid deployment valve (Intuity). It is crucial to be familiar with the characteristics of each device so that their advantages can be utilized in individual situations.

Fischlein et al demonstrated that the 5-year freedom rate from reintervention in sutureless valve (Perceval) was 94.7%, with 24 out of 658 patients experiencing surgical explants of SRDV during the follow-up period of 5 years.<sup>16</sup> The 7-year freedom rate from reintervention in rapid deployment valve (Intuity) was 91%, which was comparable to that of the sutureless valve (Perceval).<sup>40</sup> Causes of explants include severe PVL, endocarditis, structural valve dysfunction, and injury to other structures such as the mitral valve or ventricular wall. SRDV has a frame landing to the left ventricular outflow tract, as in TAVR, and sutureless valve (Perceval) involves the STJ as well. Therefore, care must be taken when explanting SRDV to avoid further injury to surrounding structures.<sup>50</sup>

## Potential Complications of Sutureless and Rapid Deployment Valves

### Paravalvular Leakage and Central Aortic Insufficiency

A recent meta-analysis revealed that the prevalence of mild and moderate PVL following SAVR using SRDV were 6.7% and 1.0%, respectively.<sup>49</sup> Another meta-analysis demonstrated that PVL is significantly more prevalent in SRDV than SAVR using a stented bioprosthesis, and a sub-analysis by prosthetic valve type also corroborated this finding.<sup>8</sup> Even mild PVL can have a significant impact on survival in both conventional SAVR and TAVR,<sup>51,52</sup> highlighting the importance of careful attention to PVL in SRDV. If left untreated, PVL can lead to increased diastolic left ventricular pressure and volume overload.<sup>53</sup> The incidence of PVL in SRDV is related to the learning curve.<sup>54</sup> It is more common among surgeons who recently started using SRDV, and a reduction in PVL incidence can be observed over time with greater operator experience.<sup>54</sup> Uneven valve orifice due to inadequate decalcification and incomplete sealing due to incorrect size can cause PVL.<sup>55–57</sup> Nevertheless, improvements in implantation techniques have led to a decrease in PVL incidence to approximately the same level as that of conventional SAVR.<sup>58,59</sup> A recent multicenter study comparing sutureless SAVR (Perceval) versus TAVR in elderly patients at intermediate risk found that incidence of PVL was 1.3% and 9.8%, respectively.<sup>60</sup>

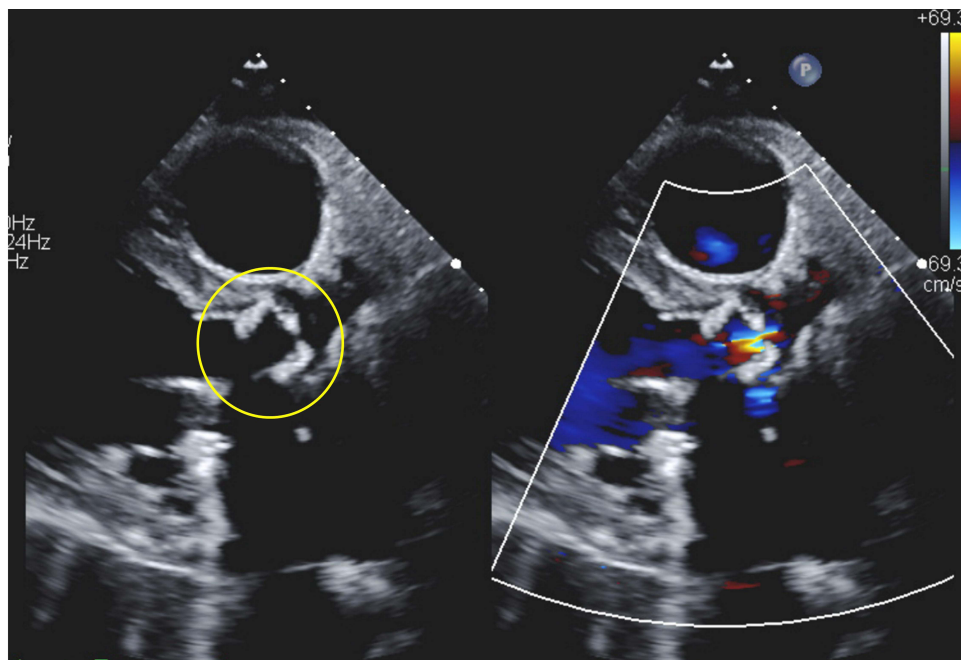
In addition to PVL, central aortic insufficiency has also been reported after SRDV implantation. A 5-year multicenter study (CAVALIER trial) revealed that 7.5% of the patients had mild or greater central aortic insufficiency.<sup>31</sup> Although inappropriate sizing and positioning can exacerbate coaptation and result in central aortic insufficiency, the exact mechanism is unknown. Here is an example of moderate central AI and moderate stenosis 2 years after CABG and AVR using a 19-mm SRDV (Figure 3). Use of SRDV has a potential benefit in patients with a small aortic annulus and root; however, it may also pose a risk of inadequate expansion of the valve at the same time. The impact of central AI or PVL after SRDV deployment is unknown, while PVL after TAVR is associated with mortality and morbidity.

## Conduction Disorder

New left bundle branch block after AVR using SRDV is not rare. It was observed in 23% of the patients who received a sutureless valve at discharge, which is similar to that reported in a recent study of TAVR.<sup>61,62</sup> New left bundle branch block is not associated with long-term mortality and heart failure readmission, but it increases the need for PPI by approximately threefold and has a negative impact on left ventricular function.

PPI incidence rates following TAVR and conventional SAVR have been reported to range between 15–25% and 3%, respectively.<sup>11</sup> PPI incidence rates for SRDV have been reported to be between 6% and 9% in most cases and up to 23%, which surpasses the incidence rate observed in conventional SAVR.<sup>63,64</sup> Since the occurrence of PPI following TAVR or SAVR has been associated with increased long-term mortality,<sup>65–67</sup> reducing the PPI incidence rate in SRDV is critical. Studies have reported that both subvalvular stents of sutureless valve (Perceval) and skirts of rapid deployment valve (Intuity) compress atrioventricular conduction and have a similar risk of PPI.<sup>27,33</sup> Technical modification can reduce the PPI incidence rate by preventing excessive force that pushes conduction, which is likely the primary mechanism for PPI.<sup>17,58,68,69</sup> Yanagawa et al<sup>70</sup> showed that elevating the implantation height by 2–3 mm can prevent compression of conduction and, thus, reduce the PPI incidence rate. Avoiding complete decalcification and oversizing may also reduce the PPI incidence rate.<sup>71</sup> Fabre et al<sup>72</sup> discontinued ballooning at the time of deployment based on the assumption that





**Figure 3** Moderate central AI and moderate stenosis 2 years after CABG and AVR using a 19-mm SRDV (yellow).

ballooning could cause compression of conduction by the prosthesis due to postoperative edema, resulting in a significant reduction in the PPI incidence from 16% to 5%. The recent meta-analysis also demonstrated a decline in the PPI incidence rate since 2016.<sup>73</sup> Nevertheless, patients with non-modifiable risks such as advanced age and preoperative conduction abnormalities, particularly right branch bundle block, should avoid SRDV implantation.<sup>15,40,74</sup>

### Transient Thrombocytopenia

SRDV can cause postoperative transient thrombocytopenia.<sup>75,76</sup> The mechanisms of thrombocytopenia are reported to be (1) inflammation-related platelet activation triggered by host interaction with the bioprosthesis, (2) mechanical platelet destruction due to shear stress, (3) the detoxification process with homocysteic acid and the storage aldehyde-free solution, and (4) the naked alloy stent.<sup>76,77</sup> Despite these mechanisms, thrombocytopenia did not have an impact on clinical outcomes,<sup>75</sup> regardless of the anticoagulation therapy used, including aspirin alone or double platelet therapy.

## Technical Consideration in Specific Situations

### Sizing and Selection of Prosthesis

The utilization of sutureless valve (Perceval) offers enhanced reproducibility of the procedure and may be applied in situations where annular sutures are difficult, particularly in MICS.<sup>78–80</sup> Although both SRDVs have high technical success rates,<sup>12,81,82</sup> it is imperative to recognize that malpositioning may lead to PVL and/or PPI, which can increase in-hospital mortality.<sup>1</sup> Valve sealing and performance are dependent on proper sizing and final stent geometry, as there are no circumferential annular sutures in SRDV. However, oversizing to achieve adequate sealing may cause stent frame infolding, thereby interfering with complete valve motion, resulting in elevated pressure gradient across the valve prosthesis.<sup>83</sup> In 2017, the manufacturer of the sutureless valve (Perceval) introduced new recommendations to avoid oversizing and ensure that the white obturator can pass through the valve annulus with light friction. Szeceł et al exhibited that the updated sizing strategy led to better prosthetic size, hemodynamics and PPI rate without increasing the incidence of PVL.<sup>84</sup> When the annular diameter is 27 mm or greater, SRDV should be avoided given the risk of PVL and device migration. Similarly, use of SRDV should be avoided when annular or aortic root enlargement may be required in patients with annular diameter smaller than 19 mm, because the deployed prosthetic valve would not be stabilized with significant risk of aortic root rupture. As the nitinol stent is designed to be stabilized at the STJ and aortotomy be 3.5 cm

above it, the procedure will be more complicated in patients necessitating ascending aortic replacement.<sup>19</sup> Therefore, the use of sutureless valve (Perceval) should be avoided when the STJ is more dilated compared to the aortic annulus (STJ/annular diameter ratio is more than 1.3).<sup>85,86</sup>

## Decalcification

In contrast to TAVR, decalcification is essential component of SAVR using SRDV. Sufficient decalcification can mitigate the incidence of PPI and PVL compared to TAVR as displacement of a calcified valve and annulus in TAVR would not happen in SRDV after removal of the leaflets and decalcification.<sup>87,88</sup> Thus, decalcification is generally preferred whenever feasible. Since it is not mandatory to decalcify the entire annulus to enable suturing, it can be time-saving in a hostile aortic root or redo cases.<sup>89</sup> Although there is some risk of embolization by small debris after decalcification of the aortic valves, the incidence of stroke is comparable to that of SAVR using stented bioprosthesis.<sup>90–92</sup>

## Usage in Small Aortic Annulus

With its favorable hemodynamic profile, SRDV potentially reduces the risk of significant PPM in patients with small aortic annulus.<sup>46</sup> Both SRDVs have been employed for those patient cohorts with good hemodynamic outcomes.<sup>32,93,94</sup> A sub-analysis of SRDV international registry, comparing large and small annulus groups, yielded no significant difference in 5-year survival, mean pressure gradient, effective orifice area at discharge, or PPM, indicating that SRDV may be an efficacious option even for small aortic annulus.<sup>95</sup> Arribas-Leal et al<sup>96</sup> reported that the pressure gradient remained low for up to 8 years after the placement of rapid deployment valve (Intuity) for small aortic annulus. In this regard, SRDV may hold promise for improving outcomes in patients with a small aortic annulus and obviating the need for annular enlargement procedure.<sup>7</sup>

## Application to Minimally Invasive Cardiac Surgery (MICS)

Several studies showed that AVR via thoracotomy or mini-sternotomy is associated with a lower rate of postoperative atrial fibrillation, shorter hospitalization/intensive care unit stays, and reduced transfusion requirements without increasing mortality and stroke rates.<sup>97–100</sup> Use of Stented valves in MICS, however, is technically challenging which requires complete annular sutures within a limited surgical field, leading to prolonged CPB and AXC times, possibility of paravalvular leakage, and difficulty of hemostasis at aortotomy.<sup>101</sup> SRDV technology can potentially play an important role in this situation and will better facilitate the application of MICS AVR.<sup>102</sup> Detailed assessment of anatomical feasibility of MICS approach on CT such as a cannulation site, anatomy of the ascending aorta and aortic valve, or proximity of great vessels in redo cases may be beneficial, as is the case with TAVR.

In ART, the use of a sutureless valve (Perceval) may allow more precise positioning, which can reduce procedural time when compared to rapid deployment valve (Intuity).<sup>95</sup> ART also allows concomitant surgery for other valves. On the other hand, upper mini-sternotomy allows easy access to central cannulation and exposure of the aortic valve almost similar to full sternotomy while preserving the caudal part of the sternum. Therefore, it is easy to adapt from full sternotomy.<sup>103</sup> Further studies are warranted to compare the outcomes of these two approaches in the setting of MICS-AVR using SRDV. In addition to ART and mini-sternotomy under direct vision, endoscopic and robotic AVR with SRDV have also been reported,<sup>104,105</sup> and their outcomes merit further investigation.

## Application to Bicuspid Aortic Valve

In general, 38–50% of the patients undergoing AVR have a bicuspid aortic valve (BAV).<sup>106,107</sup> Both SAVR and TAVR in patients with BAV are associated with higher PPI rates when compared to patients with tricuspid aortic valve due to the presence of asymmetric aortic cusps, bulky calcification, and abnormal conduction pathway.<sup>108,109</sup> While studies have examined the applicability of SRDV in patients with BAV, its use is not recommended for Sievers type 0 BAV (true bicuspid valve) as restoring circularity of the aortic annulus is challenging due to variation in height and width of each sinus.<sup>110,111</sup> BAV is heavily calcified in general and higher incidence of PPI and stroke were reported after SRDV for patients with BAV.<sup>112–114</sup> Complete decalcification may be necessary to restore the elasticity and flexibility of the calcified annulus and to reduce stroke rate after SRDV for patients with BAV.<sup>112</sup> Although a successful implant rate of

SRDV was similar, CPB and AXC times were longer than those in non-BAV patients.<sup>89,115,116</sup> Given that patients with BAV who undergo AVR are younger with or without aortic root aneurysm and the annulus is larger than those with tricuspid aortic valve,<sup>107</sup> it remains unclear how many BAV patients meet the indication for SRDV.<sup>117</sup>

## Reoperation: Valve-in-Valve Transcatheter Aortic Valve Replacement

While some studies have reported a favorable freedom rate from structural valve deterioration in SRDV,<sup>116,118</sup> the follow-up periods were limited to 3–4 years. In previous reports, structural valve deterioration was observed postoperatively ranging from very early (5 days) to late postoperative period (5 years), primarily due to leaflet calcification and/or stent creep.<sup>119–122</sup>

Regarding re-intervention to failed SRDV prosthesis, conventional open surgery should be considered as an option for reoperation unless there are high-risk factors including re-sternotomy after coronary artery bypass grafting. Valve-in-valve TAVR may be an alternative option for these cases with similar operative outcomes to open reoperation.<sup>123</sup> However, reoperation after SRDV might require more extensive surgery such as root repair/enlargement, replacement of the ascending aorta, aortic root replacement, or mitral valve repair/replacement as a result of explant of SRDR valves, similar to TAVR explant. Recent case series have demonstrated that both balloon- and self-expandable TAVR valves can be successfully used as valve-in-valve TAVR after SRDV.<sup>124,125</sup> In a sub-analysis of the valve-in-valve international data (VIVID registry), valve-in-valve TAVR for failed SRDV showed similar hemodynamic status and complication rates as that for conventional SAVR.<sup>126</sup> When performing valve-in-valve TAVR for structural deterioration of rapid deployment valves (Intuity), it is recommended to determine the size of the TAVR valve based on that of rapid deployment valve (Intuity) which correlates to the inner diameter of Magna Ease valve (Edwards Lifesciences).<sup>127</sup> Sutureless (Perceval) valve's radio-opaque frame and sinusoidal struts may provide easier positioning and may also be protective against coronary obstructions. However, guidewires should be placed in the coronary ostia in case of coronary obstruction after deployment since the risk of coronary obstruction in valve-in-valve TAVR for failed SRDV remains unknown.

## Patient Selection: Who Would Benefit from Sutureless and Rapid Deployment Valves?

Considering the characteristics of SRDV outlined in this review, the ideal candidates for this prosthesis include (1) patients who require multiple procedures in addition to SAVR and are anticipated to have extended AXC time, (2) those undergoing MICS-AVR, and (3) those with a small aortic annulus. In addition to these indications, SRDV may offer potential benefits in cases of complex reoperation, such as redo AVR in the setting of a hostile aortic root or failure of previous homograft as it facilitates valve implantation with less manipulation of friable tissues.<sup>128–130</sup> While SRDV may be a viable option for patients with BAV, careful consideration must be given to the indication. SRDV should be avoided if there is a complex calcification from the annulus to STJ, as this may increase the incidence of stroke from embolization, PVL, and PPI.<sup>88</sup> Type 0 BAV should also be avoided because complex additional procedures are not reproducible and offset the time-saving advantages of SRDV. SRDV can also be utilized in patients with infective endocarditis,<sup>89</sup> however, it should be noted that annular abscess or destruction may compromise valve fitting.<sup>131</sup> In this review, we examine the attributes of sutureless and rapid deployment valves collectively. Although these valves share good hemodynamics and suitability for MICS, it is imperative to comprehend that there exist mechanistic differences among SRDVs, including the retention of a guiding suture, the presence of a supraannular stent or subannular skirt, and whether they are balloon-expandable or self-expandable. The suitability of each prosthesis among the candidates for SRDV should be determined based on individual anatomy. For example, it is safer to use rapid deployment valve (Intuity) in patients at risk of developing aneurysm or dissection in the ascending aorta compared to sutureless valve (Perceval), which requires the landing on the STJ. A detailed and direct comparison between SRDVs is necessary in the future studies.

## Conclusion

This review summarizes the mechanics, hemodynamics, utility, and pitfalls of SRDV from technical and theoretical perspectives. While SRDV has advantages in terms of hemodynamic performance and procedure time, it also inherits

complications from both SAVR and TAVR as disadvantages. Appropriate patient selection and technical proficiency to avoid complications are essential so that SRDV will not result in incomplete AVR. A clinical trial to examine the long-term results in selected patients suitable for SRDV may lead to its widespread use in the future.

## Abbreviations

ART, Anterior right thoracotomy; AVR, Aortic valve replacement; AXC, Aortic cross clamp; BAV, Bicuspid aortic valve; CPB, Cardiopulmonary bypass; MICS, Minimally invasive cardiac surgery; PPI, Permanent pacemaker implantation; PPM, Patient-prosthesis mismatch; PVL, Paravalvular leakage; SAVR, Surgical aortic valve replacement; SRDV, Sutureless and/or rapid deployment valve; STJ, Sinotubular junction; TAVR, Transcatheter aortic valve replacement.

## Disclosure

The authors report no conflicts of interest in this work.

## References

- Berretta P, Andreas M, Carrel TP, et al. Minimally invasive aortic valve replacement with sutureless and rapid deployment valves: a report from an international registry (Sutureless and Rapid Deployment International Registry). *Eur J Cardio Thorac Surg.* 2019;56(4):793–799. doi:10.1093/ejcts/ezz055
- Borger MA, Dohmen PM, Knosalla C, et al. Haemodynamic benefits of rapid deployment aortic valve replacement via a minimally invasive approach: 1-year results of a prospective multicentre randomized controlled trial. *Eur J Cardiothorac Surg.* 2016;50(4):713–720. doi:10.1093/ejcts/ezw042
- Meco M, Montisci A, Miceli A, et al. Sutureless Perceval aortic valve versus conventional stented bioprostheses: meta-analysis of postoperative and midterm results in isolated aortic valve replacement. *J Am Heart Assoc.* 2018;7(4):e006091. doi:10.1161/jaha.117.006091
- Villa E, Messina A, Cirillo M, et al. Perceval sutureless valve in freestyle root: new surgical valve-in-valve therapy. *Ann Thorac Surg.* 2013;96(6):e155–7. doi:10.1016/j.athoracsur.2013.06.125
- Di Eusanio M, Phan K, Berretta P, et al. Sutureless and rapid-deployment aortic valve replacement international registry (SURD-IR): early results from 3343 patients. *Eur J Cardiothorac Surg.* 2018;54(4):768–773. doi:10.1093/ejcts/ezy132
- Fischlein T, Folliguet T, Meuris B, et al. Sutureless versus conventional bioprostheses for aortic valve replacement in severe symptomatic aortic valve stenosis. *J Thorac Cardiovasc Surg.* 2021;161(3):920–932. doi:10.1016/j.jtcvs.2020.11.162
- Lu Y, Wang J, Chen Z, Wei J, Li F, Cai Z. Does quicker mean better? Comparison of rapid deployment versus conventional aortic valve replacement. *Int Heart J.* 2020;61(5):951–960. doi:10.1536/ihj.19-717
- Salmasi MY, Ramaraju S, Haq I, et al. Rapid deployment technology versus conventional sutured bioprostheses in aortic valve replacement. *J Card Surg.* 2022;37(3):640–655. doi:10.1111/jocs.16223
- Vahanian A, Beyersdorf F, Praz F, et al. 2021 ESC/EACTS guidelines for the management of valvular heart disease. *Eur Heart J.* 2022;43(7):561–632. doi:10.1093/eurheartj/ehab395
- Otto CM, Nishimura RA, Bonow RO, et al. 2020 ACC/AHA guideline for the management of patients with valvular heart disease: a report of the American College of Cardiology/American Heart Association Joint Committee on clinical practice guidelines. *Circulation.* 2021;143(5):e72–e227. doi:10.1161/CIR.0000000000000923
- Carrel T, Heinisch PP. History, development and clinical perspectives of sutureless and rapid deployment surgical aortic valve replacement. *Ann Cardiothorac Surg.* 2020;9(5):375–385. doi:10.21037/acs-2020-surd-18
- Kocher AA, Laufer G, Haverich A, et al. One-year outcomes of the Surgical Treatment of Aortic Stenosis With a Next Generation Surgical Aortic Valve (TRITON) trial: a prospective multicenter study of rapid-deployment aortic valve replacement with the EDWARDS INTUITY valve system. *J Thorac Cardiovasc Surg.* 2013;145(1):110–5;discussion 115–6. doi:10.1016/j.jtcvs.2012.07.108
- Brennan JM, Holmes DR, Sherwood MW, et al. The association of transcatheter aortic valve replacement availability and hospital aortic valve replacement volume and mortality in the United States. *Ann Thorac Surg.* 2014;98(6):2016–22; discussion 2022. doi:10.1016/j.athoracsur.2014.07.051
- Goel S, Pasam RT, Wats K, et al. Transcatheter aortic valve replacement versus surgical aortic valve replacement in low-surgical-risk patients: an updated meta-analysis. *Catheter Cardiovasc Interv.* 2020;96(1):169–178. doi:10.1002/ccd.28520
- Woldendorp K, Doyle MP, Bannon PG, et al. Aortic valve replacement using stented or sutureless/rapid deployment prosthesis via either full-sternotomy or a minimally invasive approach: a network meta-analysis. *Ann Cardiothorac Surg.* 2020;9(5):347–363. doi:10.21037/acs-2020-surd-17
- Fischlein T, Meuris B, Folliguet T, et al. Midterm outcomes with a sutureless aortic bioprosthesis in a prospective multicenter cohort study. *J Thorac Cardiovasc Surg.* 2022;164(6):1772–1780 e11. doi:10.1016/j.jtcvs.2020.12.109
- Glauber M, Di Bacco L, Cuenca J, et al. Minimally invasive aortic valve replacement with sutureless valves: results from an international prospective registry. *Innovations.* 2020;15(2):120–130. doi:10.1177/1556984519892585
- Solinas M, Bianchi G, Chiamonti F, et al. Right anterior mini-thoracotomy and sutureless valves: the perfect marriage. *Ann Cardiothorac Surg.* 2020;9(4):305–313. doi:10.21037/acs-2019-surd-172
- Flameng W, Herregods MC, Hermans H, et al. Effect of sutureless implantation of the Perceval S aortic valve bioprosthesis on intraoperative and early postoperative outcomes. *J Thorac Cardiovasc Surg.* 2011;142(6):1453–1457. doi:10.1016/j.jtcvs.2011.02.021
- Smart NA, Dieberg G, King N. Long-term outcomes of on- versus off-pump coronary artery bypass grafting. *J Am Coll Cardiol.* 2018;71(9):983–991. doi:10.1016/j.jacc.2017.12.049



21. Wesselink RM, de Boer A, Morshuis WJ, Leusink JA. Cardio-pulmonary-bypass time has important independent influence on mortality and morbidity. *Eur J Cardiothorac Surg.* 1997;11(6):1141–1145. doi:10.1016/s1010-7940(97)01217-7
22. Chalmers J, Pullan M, Mediratta N, Poullis M. A need for speed? Bypass time and outcomes after isolated aortic valve replacement surgery. *Interact Cardiovasc Thorac Surg.* 2014;19(1):21–26. doi:10.1093/icvts/ivu102
23. Salis S, Mazzanti VV, Merli G, et al. Cardiopulmonary bypass duration is an independent predictor of morbidity and mortality after cardiac surgery. *J Cardiothorac Vasc Anesth.* 2008;22(6):814–822. doi:10.1053/j.jvca.2008.08.004
24. Hanedan MO, Yuruk MA, Parlar AI, et al. Sutureless versus conventional aortic valve replacement: outcomes in 70 high-risk patients undergoing concomitant cardiac procedures. *Tex Heart Inst J.* 2018;45(1):11–16. doi:10.14503/THIJ-16-6092
25. Stacchino C, Bona G, Rinaldi S, Vallana F. Design and performance characteristics of the Pericarbon Stentless valve. *J Heart Valve Dis.* 1995;4(Suppl 1):S102–5.
26. Ranucci M, Frigiola A, Menicanti L, Castelvechio S, de Vincentiis C, Pistuddi V. Aortic cross-clamp time, new prostheses, and outcome in aortic valve replacement. *J Heart Valve Dis.* 2012;21(6):732–739.
27. D'Onofrio A, Salizzoni S, Filippini C, et al. Surgical aortic valve replacement with new-generation bioprostheses: sutureless versus rapid-deployment. *J Thorac Cardiovasc Surg.* 2020;159(2):432–442 e1. doi:10.1016/j.jtcvs.2019.02.135
28. Iino K, Miyata H, Motomura N, et al. Prolonged cross-clamping during aortic valve replacement is an independent predictor of postoperative morbidity and mortality: analysis of the Japan Cardiovascular Surgery Database. *Ann Thorac Surg.* 2017;103(2):602–609. doi:10.1016/j.athoracsur.2016.06.060
29. Abicht JM, Mayr TAJ, Jauch J, et al. Large-animal biventricular working heart perfusion system with low priming volume-comparison between in vivo and ex vivo cardiac function. *Thorac Cardiovasc Surg.* 2018;66(1):71–82. doi:10.1055/s-0036-1580604
30. Tasca G, Vismara R, Mangini A, et al. Comparison of the performance of a sutureless bioprosthesis with two pericardial stented valves on small annuli: an in vitro study. *Ann Thorac Surg.* 2017;103(1):139–144. doi:10.1016/j.athoracsur.2016.05.089
31. Fischlein T, Meuris B, Folliguet T, et al. Midterm outcomes with a sutureless aortic bioprosthesis in a prospective multicenter cohort study. *J Thorac Cardiovasc Surg.* 2021. doi:10.1016/j.jtcvs.2020.12.109
32. Dedelias P, Baikoussis NG, Prappa E, Asvestas D, Argiriou M, Charitos C. Aortic valve replacement in elderly with small aortic root and low body surface area; the Perceval S valve and its impact in effective orifice area. *J Cardiothorac Surg.* 2016;11(1):54. doi:10.1186/s13019-016-0438-7
33. Berretta P, Meuris B, Kappert U, et al. Sutureless versus rapid deployment aortic valve replacement: results from a multicenter registry. *Ann Thorac Surg.* 2022;114(3):758–765. doi:10.1016/j.athoracsur.2021.08.037
34. D'Onofrio A, Tarja E, Besola L, et al. Early and midterm clinical and hemodynamic outcomes of transcatheter valve-in-valve implantation: results from a multicenter experience. *Ann Thorac Surg.* 2016;102(6):1966–1973. doi:10.1016/j.athoracsur.2016.05.055
35. Sadri V, Bloodworth CH, Madukauwa-David ID, Midha PA, Raghav V, Yoganathan AP. A mechanistic investigation of the EDWARDS INTUITY Elite valve's hemodynamic performance. *Gen Thorac Cardiovasc Surg.* 2020;68(1):9–17. doi:10.1007/s11748-019-01154-y
36. Haverich A, Wahlers TC, Borger MA, et al. Three-year hemodynamic performance, left ventricular mass regression, and prosthetic-patient mismatch after rapid deployment aortic valve replacement in 287 patients. *J Thorac Cardiovasc Surg.* 2014;148(6):2854–2860. doi:10.1016/j.jtcvs.2014.07.049
37. Capelli C, Corsini C, Biscarini D, et al. Pledget-armed sutures affect the haemodynamic performance of biologic aortic valve substitutes: a preliminary experimental and computational study. *Cardiovasc Eng Technol.* 2017;8(1):17–29. doi:10.1007/s13239-016-0284-8
38. Andreas M, Coti I, Rosenhek R, et al. Intermediate-term outcome of 500 consecutive rapid-deployment surgical aortic valve procedures dagger. *Eur J Cardiothorac Surg.* 2019;55(3):527–533. doi:10.1093/ejcts/ezy273
39. Laufer G, Haverich A, Andreas M, et al. Long-term outcomes of a rapid deployment aortic valve: data up to 5 years. *Eur J Cardiothorac Surg.* 2017;52(2):281–287. doi:10.1093/ejcts/ezx103
40. Coti I, Haberl T, Scherzer S, et al. Outcome of rapid deployment aortic valves: long-term experience after 700 implants. *Ann Cardiothor Surg.* 2020;9(4):314–321. doi:10.21037/acs.2020.04.01
41. Hong S, Yi G, Youn YN, Lee S, Yoo KJ, Chang BC. Effect of the prosthesis-patient mismatch on long-term clinical outcomes after isolated aortic valve replacement for aortic stenosis: a prospective observational study. *J Thorac Cardiovasc Surg.* 2013;146(5):1098–1104. doi:10.1016/j.jtcvs.2012.07.101
42. Mannacio V, Mannacio L, Mango E, et al. Severe prosthesis-patient mismatch after aortic valve replacement for aortic stenosis: analysis of risk factors for early and long-term mortality. *J Cardiol.* 2017;69(1):333–339. doi:10.1016/j.jcc.2016.07.003
43. Head SJ, Mokhles MM, Osnabrugge RL, et al. The impact of prosthesis-patient mismatch on long-term survival after aortic valve replacement: a systematic review and meta-analysis of 34 observational studies comprising 27 186 patients with 133 141 patient-years. *Eur Heart J.* 2012;33(12):1518–1529. doi:10.1093/eurheartj/ehs003
44. De Das S, Nanjappa A, Morcos K, et al. The effect of patient-prosthesis mismatch on survival after aortic and mitral valve replacement: a 10 year, single institution experience. *J Cardiothorac Surg.* 2019;14(1):214. doi:10.1186/s13019-019-1034-4
45. Koene BM, Soliman Hamad MA, Bouma W, et al. Impact of prosthesis-patient mismatch on early and late mortality after aortic valve replacement. *J Cardiothorac Surg.* 2013;8:96. doi:10.1186/1749-8090-8-96
46. Theron A, Gariboldi V, Grisoli D, et al. Rapid deployment of aortic bioprosthesis in elderly patients with small aortic annulus. *Ann Thorac Surg.* 2016;101(4):1434–1441. doi:10.1016/j.athoracsur.2015.09.024
47. Kvidal P, Bergstrom R, Horte LG, Stahle E. Observed and relative survival after aortic valve replacement. *J Am Coll Cardiol.* 2000;35(3):747–756. doi:10.1016/s0735-1097(99)00584-7
48. Lloyd D, Luc JGY, Indja BE, Leung V, Wang N, Phan K. Transcatheter, sutureless and conventional aortic-valve replacement: a network meta-analysis of 16,432 patients. *J Thorac Dis.* 2019;11(1):188–199. doi:10.21037/jtd.2018.12.27
49. Flynn CD, Williams ML, Chakos A, Hirst L, Muston B, Tian DH. Sutureless valve and rapid deployment valves: a systematic review and meta-analysis of comparative studies. *Ann Cardiothor Surg.* 2020;9(5):364–374. doi:10.21037/acs-2020-surd-27
50. Di Bacco L, Pfeiffer S, Fischlein TJM, Santarpino G. Rapid explantation of rapid-deployment sutureless valve in case of acute endocarditis: how to remove safely sutureless Perceval S prostheses. *Innovations.* 2017;12(6):483–485. doi:10.1097/IML.0000000000000427
51. Shah S, Alashi A, Pettersson GB, et al. Characteristics and longer-term outcomes of paravalvular leak after aortic and mitral valve surgery. *J Thorac Cardiovasc Surg.* 2019;157(5):1785–1792 e1. doi:10.1016/j.jtcvs.2018.08.096
52. Ando T, Briasoulis A, Telila T, Afonso L, Grines CL, Takagi H. Does mild paravalvular regurgitation post transcatheter aortic valve implantation affect survival? A meta-analysis. *Catheter Cardiovasc Interv.* 2018;91(1):135–147. doi:10.1002/ccd.27336

53. Eleid MF, Cabalka AK, Malouf JF, Sanon S, Hagler DJ, Rihal CS. Techniques and outcomes for the treatment of paravalvular leak. *Circ Cardiovasc Interv.* 2015;8(8):e001945. doi:10.1161/CIRCINTERVENTIONS.115.001945
54. Phan K, Tsai YC, Niranjan N, et al. Sutureless aortic valve replacement: a systematic review and meta-analysis. *Ann Cardiothorac Surg.* 2015;4(2):100–111. doi:10.3978/j.issn.2225-319X.2014.06.01
55. Ferrari E, Siniscalchi G, Tozzi P, von Segesser L. Aortic annulus stabilization technique for rapid deployment aortic valve replacement. *Innovations.* 2015;10(5):360–362. doi:10.1097/IMI.0000000000000192
56. Hori D, Yamamoto T, Kusadokoro S, et al. Evaluation of oversizing in association with conduction disorder after implantation of a rapid deployment valve. *J Artif Organs.* 2022;25(3):238–244. doi:10.1007/s10047-021-01301-4
57. Ensminger S, Fujita B, Bauer T, et al. Rapid deployment versus conventional bioprosthetic valve replacement for aortic stenosis. *J Am Coll Cardiol.* 2018;71(13):1417–1428. doi:10.1016/j.jacc.2018.01.065
58. Berretta P, Arzt S, Fiore A, et al. Current trends of sutureless and rapid deployment valves: an 11-year experience from the sutureless and rapid deployment international registry. *Eur J Cardiothorac Surg.* 2020;58(5):1054–1062. doi:10.1093/ejcts/ezaa144
59. Murzi M, Cerillo AG, Gilmanov D, et al. Exploring the learning curve for minimally invasive sutureless aortic valve replacement. *J Thorac Cardiovasc Surg.* 2016;152(6):1537–1546 e1. doi:10.1016/j.jtcvs.2016.04.094
60. Muneretto C, Solinas M, Folliguet T, et al. Sutureless versus transcatheter aortic valves in elderly patients with aortic stenosis at intermediate risk: a multi-institutional study. *J Thorac Cardiovasc Surg.* 2022;163(3):925–935 e5. doi:10.1016/j.jtcvs.2020.04.179
61. Vilalta V, Cediel G, Mohammadi S, et al. New-onset persistent left bundle branch block following sutureless aortic valve replacement. *Heart.* 2022;109(2):143–150. doi:10.1136/heartjnl-2022-321191
62. Chamandi C, Barbanti M, Munoz-Garcia A, et al. Long-term outcomes in patients with new-onset persistent left bundle branch block following TAVR. *JACC Cardiovasc Interv.* 2019;12(12):1175–1184. doi:10.1016/j.jcin.2019.03.025
63. Folliguet TA, Laborde F, Zannis K, Ghorayeb G, Haverich A, Shrestha M. Sutureless Perceval aortic valve replacement: results of two European centers. *Ann Thorac Surg.* 2012;93(5):1483–1488. doi:10.1016/j.athoracsur.2012.01.071
64. Dalen M, Biancari F, Rubino AS, et al. Ministernotomy versus full sternotomy aortic valve replacement with a sutureless bioprosthesis: a multicenter study. *Ann Thorac Surg.* 2015;99(2):524–530. doi:10.1016/j.athoracsur.2014.08.028
65. Nazif TM, Dizon JM, Hahn RT, et al. Predictors and clinical outcomes of permanent pacemaker implantation after transcatheter aortic valve replacement: the PARTNER (Placement of AoRtic TraNscatheter Valves) trial and registry. *JACC Cardiovasc Interv.* 2015;8(1Pt A):60–69. doi:10.1016/j.jcin.2014.07.022
66. Mehaffey JH, Haywood NS, Hawkins RB, et al. Need for permanent pacemaker after surgical aortic valve replacement reduces long-term survival. *Ann Thorac Surg.* 2018;106(2):460–465. doi:10.1016/j.athoracsur.2018.02.041
67. Greason KL, Lahr BD, Stulak JM, et al. Long-term mortality effect of early pacemaker implantation after surgical aortic valve replacement. *Ann Thorac Surg.* 2017;104(4):1259–1264. doi:10.1016/j.athoracsur.2017.01.083
68. Vogt F, Moscarelli M, Nicoletti A, et al. Sutureless aortic valve and pacemaker rate: from surgical tricks to clinical outcomes. *Ann Thorac Surg.* 2019;108(1):99–105. doi:10.1016/j.athoracsur.2018.12.037
69. Vogt F, Dell'Aquila AM, Santarpino G. How to prevent pacemaker implantation after sutureless aortic valve replacement: tips and tricks. *Ann Thorac Surg.* 2017;104(2):720–721. doi:10.1016/j.athoracsur.2016.11.013
70. Yanagawa B, Cruz J, Boisvert L, Bonneau D. A simple modification to lower incidence of heart block with sutureless valve implantation. *J Thorac Cardiovasc Surg.* 2016;152(2):630–632. doi:10.1016/j.jtcvs.2016.02.034
71. Meuris B, Lamberigts M, Szeceł D. The importance of sizing in sutureless valves. *Interact Cardiovasc Thorac Surg.* 2022;35(3). doi:10.1093/icvts/ivac206
72. Fabre O, Radutoiu M, Carjaliu I, Rebet O, Gautier L, Hysi I. Recent improvement in operative techniques lead to lower pacemaker rate after Perceval implant. *Interact Cardiovasc Thorac Surg.* 2022;35(2). doi:10.1093/icvts/ivac182
73. Moscarelli M, Santarpino G, Athanasiou T, et al. A pooled analysis of pacemaker implantation after Perceval sutureless aortic valve replacement. *Interact Cardiovasc Thorac Surg.* 2021;33(4):501–509. doi:10.1093/icvts/ivab137
74. Brookes JDL, Mathew M, Brookes EM, Jaya JS, Almeida AA, Smith JA. Predictors of pacemaker insertion post-sutureless (Perceval) aortic valve implantation. *Heart Lung Circ.* 2021;30(6):917–921. doi:10.1016/j.hlc.2020.11.004
75. Stegmeier P, Schlomicher M, Stiegler H, Strauch JT, Bechtel JFM. Thrombocytopenia after implantation of the Perceval S aortic bioprosthesis. *J Thorac Cardiovasc Surg.* 2020;160(1):61–68 e8. doi:10.1016/j.jtcvs.2019.07.046
76. Jiritano F, Cristodoro L, Malta E, Mastroroberto P. Thrombocytopenia after sutureless aortic valve implantation: comparison between Intuity and Perceval bioprostheses. *J Thorac Cardiovasc Surg.* 2016;152(6):1631–1633. doi:10.1016/j.jtcvs.2016.07.054
77. Lorusso R, Jiritano F, Roselli E, et al. Perioperative platelet reduction after sutureless or stented valve implantation: results from the PERSIST-AVR controlled randomized trial. *Eur J Cardiothorac Surg.* 2021;60(6):1359–1365. doi:10.1093/ejcts/ezab175
78. Wendt D, Thielmann M, Buck T, et al. First clinical experience and 1-year follow-up with the sutureless 3F-enable aortic valve prosthesis. *Eur J Cardiothorac Surg.* 2008;33(4):542–547. doi:10.1016/j.ejcts.2007.12.045
79. Pillai R, Ratnatunga C, Soon JL, Kattach H, Khalil A, Jin XY. 3f prosthesis aortic cusp replacement: implantation technique and early results. *Asian Cardiovasc Thorac Ann.* 2010;18(1):13–16. doi:10.1177/0218492309355489
80. Aymard T, Kadner A, Walpoth N, et al. Clinical experience with the second-generation 3f enable sutureless aortic valve prosthesis. *J Thorac Cardiovasc Surg.* 2010;140(2):313–316. doi:10.1016/j.jtcvs.2009.10.041
81. Barnhart GR, Accola KD, Grossi EA, et al. TRANSFORM (Multicenter Experience With Rapid Deployment Edwards INTUITY Valve System for Aortic Valve Replacement) US clinical trial: performance of a rapid deployment aortic valve. *J Thorac Cardiovasc Surg.* 2017;153(2):241–251 e2. doi:10.1016/j.jtcvs.2016.09.062
82. Laborde F, Fischlein T, Hakim-Meibodi K, et al. Clinical and haemodynamic outcomes in 658 patients receiving the Perceval sutureless aortic valve: early results from a prospective European multicentre study (the Cavalier Trial) dagger. *Eur J Cardiothorac Surg.* 2016;49(3):978–986. doi:10.1093/ejcts/ezv257
83. Cerillo AG, Amoretti F, Mariani M, et al. Increased gradients after aortic valve replacement with the Perceval valve: the role of oversizing. *Ann Thorac Surg.* 2018;106(1):121–128. doi:10.1016/j.athoracsur.2017.12.044

84. Szeceł D, Lamberigts M, Rega F, Verbrugghe P, Dubois C, Meuris B. Avoiding oversizing in sutureless valves leads to lower transvalvular gradients and less permanent pacemaker implants postoperatively. *Interact Cardiovasc Thorac Surg.* 2022;35(2). doi:10.1093/icvts/ivac157
85. Heimansohn D, Moainie S. Aortic valve replacement using a Perceval sutureless aortic bioprosthesis. *Operat Techniq Thorac Cardiovasc Surg.* 2016;21(4):282–305. doi:10.1053/j.optechstcvs.2017.09.004
86. Chandola R, Teoh K, Elhenawy A, Christakis G. Perceval sutureless valve – are sutureless valves here? *Curr Cardiol Rev.* 2015;11(3):220–228. doi:10.2174/1573403x11666141113155744
87. Gonzalez Barbeito M, Estevez-Cid F, Pardo Martinez P, et al. Surgical technique modifies the postoperative atrioventricular block rate in sutureless prostheses. *J Thorac Dis.* 2019;11(7):2945–2954. doi:10.21037/jtd.2019.07.27
88. Nguyen SN, Cohn BM, Nguyen TC. Combined valve surgery with sutureless and rapid-deployment aortic valve replacement: when and why. *Ann Cardiothor Surg.* 2020;9(5):408–410. doi:10.21037/acs-2019-surd-11
89. Dokollari A, Ramlawi B, Torregrossa G, et al. Benefits and pitfalls of the Perceval sutureless bioprosthesis. *Front Cardiovasc Med.* 2021;8:789392. doi:10.3389/fcvm.2021.789392
90. Brown JM, O'Brien SM, Wu C, Sikora JA, Griffith BP, Gammie JS. Isolated aortic valve replacement in North America comprising 108,687 patients in 10 years: changes in risks, valve types, and outcomes in the Society of Thoracic Surgeons National Database. *J Thorac Cardiovasc Surg.* 2009;137(1):82–90. doi:10.1016/j.jtcvs.2008.08.015
91. Barbanti M, Tamburino C, D'Errigo P, et al. Five-year outcomes of transfemoral transcatheter aortic valve replacement or surgical aortic valve replacement in a real world population. *Circ Cardiovasc Interv.* 2019;12(7):e007825. doi:10.1161/CIRCINTERVENTIONS.119.007825
92. Makkar RR, Thourani VH, Mack MJ, et al. Five-year outcomes of transcatheter or surgical aortic-valve replacement. *N Engl J Med.* 2020;382(9):799–809. doi:10.1056/NEJMoa1910555
93. Andreas M, Wallner S, Habrheuer A, et al. Conventional versus rapid-deployment aortic valve replacement: a single-centre comparison between the Edwards Magna valve and its rapid-deployment successor. *Interact Cardiovasc Thorac Surg.* 2016;22(6):799–805. doi:10.1093/icvts/ivw052
94. Rahmanian PB, Kaya S, Eghbalzadeh K, Menghesha H, Madershahian N, Wahlers T. Rapid deployment aortic valve replacement: excellent results and increased effective orifice areas. *Ann Thorac Surg.* 2018;105(1):24–30. doi:10.1016/j.athoracsur.2017.07.047
95. Di Eusanio M, Berretta P. The sutureless and rapid-deployment aortic valve replacement international registry: lessons learned from more than 4500 patients. *Ann Cardiothor Surg.* 2020;9(4):289–297. doi:10.21037/acs-2020-surd-21
96. Arribas-Leal JM, Rivera-Caravaca JM, Aranda-Domene R, et al. Mid-term outcomes of rapid deployment aortic prostheses in patients with small aortic annulus. *Interact Cardiovasc Thorac Surg.* 2021;33(5):695–701. doi:10.1093/icvts/ivab175
97. Chang C, Raza S, Altarabsheh SE, et al. Minimally invasive approaches to surgical aortic valve replacement: a meta-analysis. *Ann Thorac Surg.* 2018;106(6):1881–1889. doi:10.1016/j.athoracsur.2018.07.018
98. Paparella D, Malvindi PG, Santarpino G, et al. Full sternotomy and minimal access approaches for surgical aortic valve replacement: a multicentre propensity-matched study. *Eur J Cardiothorac Surg.* 2020;57(4):709–716. doi:10.1093/ejcts/ez2286
99. Welp HA, Herlemann I, Martens S, Deschka H. Outcomes of aortic valve replacement via partial upper sternotomy versus conventional aortic valve replacement in obese patients. *Interact Cardiovasc Thorac Surg.* 2018;27(4):481–486. doi:10.1093/icvts/ivy083
100. Phan K, Xie A, Di Eusanio M, Yan TD. A meta-analysis of minimally invasive versus conventional sternotomy for aortic valve replacement. *Ann Thorac Surg.* 2014;98(4):1499–1511. doi:10.1016/j.athoracsur.2014.05.060
101. Shehada SE, Elhmidi Y, Mourad F, et al. Minimal access versus conventional aortic valve replacement: a meta-analysis of propensity-matched studies. *Interact Cardiovasc Thorac Surg.* 2017;25(4):624–632. doi:10.1093/icvts/ivx212
102. Fujita B, Ensminger S, Bauer T, et al. Trends in practice and outcomes from 2011 to 2015 for surgical aortic valve replacement: an update from the German Aortic Valve Registry on 42 776 patients. *Eur J Cardiothorac Surg.* 2018;53(3):552–559. doi:10.1093/ejcts/ezx408
103. Kocher A, Coti I, Laufer G, Andreas M. Minimally invasive aortic valve replacement through an upper hemisternotomy: the Vienna technique. *Eur J Cardiothorac Surg.* 2018;53(suppl\_2):ii29–ii31. doi:10.1093/ejcts/ezx514
104. Vola M, Fuzellier JF, Campisi S, et al. Total endoscopic sutureless aortic valve replacement: rationale, development, perspectives. *Ann Cardiothorac Surg.* 2015;4(2):170–174. doi:10.3978/j.issn.2225-319X.2014.11.04
105. Balkhy HH, Kitahara H. First human totally endoscopic robotic-assisted sutureless aortic valve replacement. *Ann Thorac Surg.* 2020;109(1):e9–e11. doi:10.1016/j.athoracsur.2019.04.093
106. Michelena HI, Prakash SK, Della Corte A, et al. Bicuspid aortic valve: identifying knowledge gaps and rising to the challenge from the International Bicuspid Aortic Valve Consortium (BAVCon). *Circulation.* 2014;129(25):2691–2704. doi:10.1161/CIRCULATIONAHA.113.007851
107. Roberts WC, Ko JM. Frequency by decades of unicuspid, bicuspid, and tricuspid aortic valves in adults having isolated aortic valve replacement for aortic stenosis, with or without associated aortic regurgitation. *Circulation.* 2005;111(7):920–925. doi:10.1161/01.CIR.0000155623.48408.C5
108. Mentias A, Sarrazin MV, Desai MY, et al. Transcatheter versus surgical aortic valve replacement in patients with bicuspid aortic valve stenosis. *J Am Coll Cardiol.* 2020;75(19):2518–2519. doi:10.1016/j.jacc.2020.02.069
109. Xiong TY, Ali WB, Feng Y, et al. Transcatheter aortic valve implantation in patients with bicuspid valve morphology: a roadmap towards standardization. *Nat Rev Cardiol.* 2023;20(1):52–67. doi:10.1038/s41569-022-00734-5
110. Gersak B, Fischlein T, Folliguet TA, et al. Sutureless, rapid deployment valves and stented bioprosthesis in aortic valve replacement: recommendations of an International Expert Consensus Panel. *Eur J Cardiothorac Surg.* 2016;49(3):709–718. doi:10.1093/ejcts/ezv369
111. Miceli A, Berretta P, Fiore A, et al. Sutureless and rapid deployment implantation in bicuspid aortic valve: results from the sutureless and rapid-deployment aortic valve replacement international registry. *Ann Cardiothor Surg.* 2020;9(4):298–304. doi:10.21037/acs-2020-surd-33
112. Durdu MS, Gumus F, Ozcinar E, et al. Sutureless valve replacement through a right anterior mini-thoracotomy in elderly patients with stenotic bicuspid aortic valve. *Semin Thorac Cardiovasc Surg.* 2019;31(3):458–464. doi:10.1053/j.semtcvs.2018.09.025
113. Nguyen A, Fortin W, Mazine A, et al. Sutureless aortic valve replacement in patients who have bicuspid aortic valve. *J Thorac Cardiovasc Surg.* 2015;150(4):851–857. doi:10.1016/j.jtcvs.2015.05.071
114. King M, Stambulic T, Payne D, Fernandez AL, El-Diasty M. The use of sutureless and rapid-deployment aortic valve prosthesis in patients with bicuspid aortic valve: a focused review. *J Card Surg.* 2022;37(10):3355–3362. doi:10.1111/jocs.16795
115. Suri RM, Javadikagari H, Heimansohn DA, et al. Prospective US investigational device exemption trial of a sutureless aortic bioprosthesis: one-year outcomes. *J Thorac Cardiovasc Surg.* 2019;157(5):1773–1782 e3. doi:10.1016/j.jtcvs.2018.08.121

116. Szeceł D, Eurlings R, Rega F, Verbrugge P, Meuris B. Perceval sutureless aortic valve implantation: midterm outcomes. *Ann Thorac Surg.* 2021;111(4):1331–1337. doi:10.1016/j.athoracsur.2020.06.064
117. Ohira S, Pena CDL. The role of sutureless or rapid-deployment aortic valve prosthesis in bicuspid aortic valve: standard AVR, TAVR, or somewhere in between? *J Card Surg.* 2022;37(10):3363–3364. doi:10.1111/jocs.16802
118. Martínez-Comendador JM, Estevez-Cid F, González Barbeito M, et al. Mid-term assessment of structural valve deterioration of Perceval S sutureless prosthesis using the last European consensus definition. *Interact Cardiovasc Thorac Surg.* 2021;32(4):499–505. doi:10.1093/icvts/ivaa299
119. Cinelli M, Schwartz L, Spagnola J, et al. Early structural deterioration of a sutureless bioprosthetic aortic valve. *Cardiol Res.* 2020;11(2):113–117. doi:10.14740/cr1013
120. Di Eusanio M, Saia F, Pellicciari G, et al. In the era of the valve-in-valve: is transcatheter aortic valve implantation (TAVI) in sutureless valves feasible? *Ann Cardiothorac Surg.* 2015;4(2):214–217. doi:10.3978/j.issn.2225-319X.2014.11.12
121. Sun X, Song Z, Soffer D, Pirris JP. Transcatheter aortic valve-in-valve implantation for early failure of sutureless aortic bioprosthesis. *J Card Surg.* 2018;33(4):172–175. doi:10.1111/jocs.13567
122. Mangner N, Holzhey D, Misfeld M, Linke A. Treatment of a degenerated sutureless Sorin Perceval(R) valve using an Edwards SAPIEN 3. *Interact Cardiovasc Thorac Surg.* 2018;26(2):364–366. doi:10.1093/icvts/ivx338
123. Patel PM, Chiou E, Cao Y, et al. Isolated redo aortic valve replacement versus valve-in-valve transcatheter valve replacement. *Ann Thorac Surg.* 2021;112(2):539–545. doi:10.1016/j.athoracsur.2020.08.048
124. Amabile N, Zannis K, Veugeois A, Caussin C. Early outcome of degenerated self-expandable sutureless aortic prostheses treated with transcatheter valve implantation: a pilot series. *J Thorac Cardiovasc Surg.* 2016;152(6):1635–1637. doi:10.1016/j.jtcvs.2016.07.079
125. Misfeld M, Abdel-Wahab M, Thiele H, Borger MA, Holzhey D. A series of four transcatheter aortic valve replacement in failed Perceval valves. *Ann Cardiothorac Surg.* 2020;9(4):280–288. doi:10.21037/acs-2020-surd-20
126. Landes U, Dvir D, Schoels W, et al. Transcatheter aortic valve-in-valve implantation in degenerative rapid deployment bioprostheses. *EuroIntervention.* 2019;15(1):37–43. doi:10.4244/EIJ-D-18-00752
127. Bapat VN, Attia R, Thomas M. Effect of valve design on the stent internal diameter of a bioprosthetic valve: a concept of true internal diameter and its implications for the valve-in-valve procedure. *JACC Cardiovasc Interv.* 2014;7(2):115–127. doi:10.1016/j.jcin.2013.10.012
128. Singh N, Chaudhuri K, Nand P. Long-term durability of a Perceval aortic valve implanted inside a calcified homograft root in a patient with Klippel-Trenaunay-Weber syndrome. *J Card Surg.* 2022;37(1):242–244. doi:10.1111/jocs.16091
129. Dhanekula AS, Nishath T, Aldea GS, Burke CR. Use of a sutureless aortic valve in reoperative aortic valve replacement. *JTCVS Techniq.* 2022;13:31–39. doi:10.1016/j.xjtc.2022.02.025
130. Folliguet TA, Laborde F. Sutureless Perceval aortic valve replacement in aortic homograft. *Ann Thorac Surg.* 2013;96(5):1866–1868. doi:10.1016/j.athoracsur.2013.02.056
131. Glauber M, Moten SC, Quaini E, et al. International expert consensus on sutureless and rapid deployment valves in aortic valve replacement using minimally invasive approaches. *Innovations.* 2016;11(3):165–173. doi:10.1097/imi.0000000000000287

## Vascular Health and Risk Management

Dovepress

### Publish your work in this journal

Vascular Health and Risk Management is an international, peer-reviewed journal of therapeutics and risk management, focusing on concise rapid reporting of clinical studies on the processes involved in the maintenance of vascular health; the monitoring, prevention and treatment of vascular disease and its sequelae; and the involvement of metabolic disorders, particularly diabetes. This journal is indexed on PubMed Central and MedLine. The manuscript management system is completely online and includes a very quick and fair peer-review system, which is all easy to use. Visit <http://www.dovepress.com/testimonials.php> to read real quotes from published authors.

Submit your manuscript here: <https://www.dovepress.com/vascular-health-and-risk-management-journal>