

# Late-Onset Meningitis in a Preterm Infant Caused by *Streptococcus gallolyticus* Subsp. *Pasteurianus* in Saudi Arabia: A Case Report and Literature Review

Hassan Al-shehri 

Department of Pediatrics, College of Medicine, Imam Mohammed Ibn Saud Islamic University, Riyadh, Saudi Arabia

Correspondence: Hassan Al-shehri, Department of Pediatrics, College of Medicine, Imam Mohammed Ibn Saud Islamic University, Uthman Ibn Affan Road, an Nada, Riyadh, Saudi Arabia, Email haalshehri@imamu.edu.sa

**Abstract:** This report describes the progression of meningitis in a 24-day-old preterm male infant infected with *Streptococcus gallolyticus* subsp. *pasteurianus* (SGSP) and its medical care, pathogen detection, antibiotic treatment, and monitoring, ultimately leading to a positive outcome of successful recovery. Neonatal meningitis (NM) is a serious and potentially life-threatening condition, particularly in immunocompromised preterm infants. This report from Saudi Arabia presents a rare case of late-onset neonatal meningitis caused by SGSP in a preterm male infant. The 24-day-old preterm neonate presented with fever, lethargy, poor feeding, and respiratory distress. SGSP was confirmed by cerebral spinal fluid analysis showing the presence of pleocytosis and a low glucose ratio. Prompt antibiotic therapy with intravenous Ampicillin and Cefotaxime led to decreased pleocytosis, and the infant was discharged after 21 days. This report highlights the importance of vigilance, diagnosis, and management of neonatal infections caused by uncommon pathogens such as SGSP. The rarity of SGSP-caused meningitis emphasizes the need to monitor pregnant women for potential transmission and to implement early diagnostic and management strategies. This case report also encompasses a review of recent globally reported cases of neonatal *S. gallolyticus* infection, highlighting the distinctiveness of this report as the first of its type in Saudi Arabia.

**Keywords:** *Streptococcus gallolyticus* subsp. *pasteurianus*, neonate, meningitis, late-onset

## Introduction

Neonatal meningitis (NM) is categorized as early onset (EOM) if symptoms appear within the first week and late-onset (LOM) if they appear between days 8 and 28 postnatally.<sup>1,2</sup> The incidence of neonatal bacterial meningitis ranges from 0.25 to 1 per 1000 live births and occurs in 25% of neonates with bacteremia.<sup>3</sup> In developed countries, Group B Streptococci (GBS) account for 50% of cases, whereas *Escherichia coli* (*E. coli*) accounts for 20%.<sup>4</sup> Gram-negative bacteria such as *Klebsiella* and *E. coli* have been reported as highly prevalent in Saudi Arabia.<sup>5</sup> While *Haemophilus influenzae type b* (Hib) (57%), *Streptococcus pneumoniae* (31%), and group B streptococcus (7.5%) have been identified as significant contributors to NM in Saudi Arabia.<sup>6</sup> A sporadic case of *Elizabethkingia meningoseptica* meningitis in an extremely premature infant with low birth weight was reported in Saudi Arabia.<sup>7</sup>

Maternal genitourinary infections play a crucial role in preventing bacterial meningitis in neonates. Multiparty delivery via Cesarean section (C-section) is a top maternal risk factor for both EOS and LOS.<sup>8</sup> The diagnosis of neonatal meningitis relies on clinical symptoms and cerebrospinal fluid (CSF), leukocyte count, glucose, and protein levels in the CSF aid in diagnosis.<sup>9</sup> *Streptococcus gallolyticus* subsp. *pasteurianus* is a subspecies within the broader category of Lancefield group D streptococci.<sup>10</sup> *Streptococcus gallolyticus* is a non-enterococcal group D streptococci, formerly known as *S. bevis*/*S. equine*'s complex (SBSEC).<sup>11</sup> Historically, it has been associated with adult infective endocarditis.<sup>12,13</sup> Although *Streptococcus gallolyticus* was

once considered an uncommon cause of neonatal infections, there has been a noticeable shift over the past decade. An increasing number of reports of neonatal sepsis, meningitis, and intrauterine infections caused by *S. gallolyticus* have been observed.<sup>14,15</sup> However, complications can vary, as observed in cases of liver abscesses and ventriculitis.<sup>16</sup> Insights gained from such cases are essential for early evaluation, detection, and prevention of complications. It also highlights the importance of continuous research and case reporting to enhance understanding and management of such rare infections.

Studies on children are limited, and cases identified at the subspecies level are even rarer. This case report is clinically significant as it reports evidence of a case involving neonatal or infantile meningitis caused by this specific subspecies in Saudi Arabia. The information provided underscores the importance of accurately identifying and classifying bacterial subspecies, particularly in the context of clinical infection. It also highlights the need for continued research and surveillance to better understand the clinical significance and potential transmission routes of pathogens such as SGSP, particularly in neonatal and infant populations.

## Case Presentation

A 24-day-old preterm male infant was admitted to a specialized medical center in Riyadh, Saudi Arabia, with a history of lethargy, poor feeding, and fever of 39.5 °C. The infant was born at 33 weeks of gestation via c-section with a birth weight of 2100 g to a GBS-negative 37-year-old multipara mother with insignificant medical history. On presentation to the emergency department, the infant displayed unusual leg pedaling movements and upward eye rolling. In response to this presentation, the medical team administered emergency phenobarbital for seizure control.

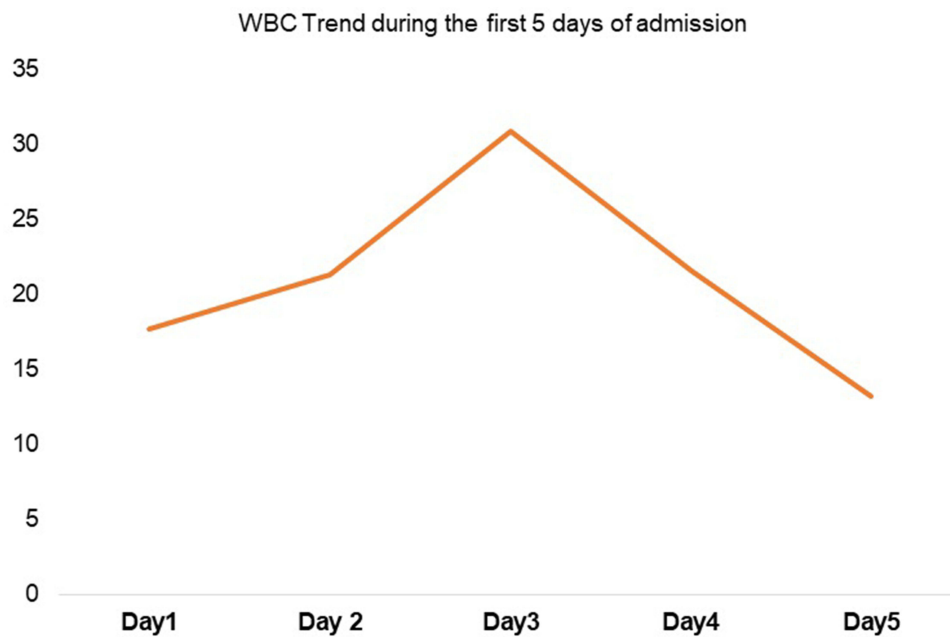
Physical examination findings of the neonate included an open and flat anterior fontanelle (soft spot on the infant's head), normal primitive reflexes, age-appropriate muscle tone, and no signs of rash or stiffness of the neck. Chest X-ray results of the neonate were unremarkable, and the initial peripheral white blood cell (WBC) counts were within the normal range, 18.52 K/ $\mu$ L (Table 1 and Figure 1) along with differential counts of 59.9% neutrophils and 31.4% lymphocytes. Unfortunately, upon admission, c-reactive protein (CRP) level was significantly elevated at 15.8 mg/dL (Table 2 and Figure 2), indicating a marked inflammatory response, suggesting the presence of an ongoing infection or inflammatory process.

CSF study is a crucial technique in the final diagnosis mostly related to biochemical analysis like glucose, protein concentration, and white blood cell differential. CSF microbiology tests like CSF cultures play an important role in contributing to the etiology of the infectious disease.<sup>17</sup> Subsequent lumbar puncture revealed cerebrospinal fluid pleocytosis with an elevated WBC count of 340/uL (93% neutrophils and 7% lymphocytes), an elevated red blood cell (RBC) count of 10/uL, an unusually high protein concentration (243.7 mg/dL), and reduced glucose concentration (31.9 mg/dL). CSF/serum glucose ratio was particularly low (0.39), and SGSP was detected in the CSF culture, while no bacterial growth was observed in blood and urine cultures of the neonate. The maternal blood count and urine analyses were unremarkable. Antibiotic susceptibility testing indicated susceptibility to cefotaxime, penicillin, gentamicin, and cefazolin, which indicated that SGSP was sensitive to these antibiotics. Instantaneously upon admission, the patient received intravenous (IV) antibiotic therapy comprising ampicillin at 400 mg/kg/day and cefotaxime at 200 mg/kg/day.

During this period, the WBC count in the CSF decreased to 188 cells/ $\mu$ L on the fifth day after admission. Seizures were managed by administering phenobarbital at a dose of 5 mg/kg/day, divided into twice-daily doses for optimal

**Table 1** WBC Trend During the First 5 Days of Admission

Day of Admission	WBC (K/ $\mu$ L)
Day 1	18.52
Day 2	21.56
Day 3	30.83
Day 5	12.44



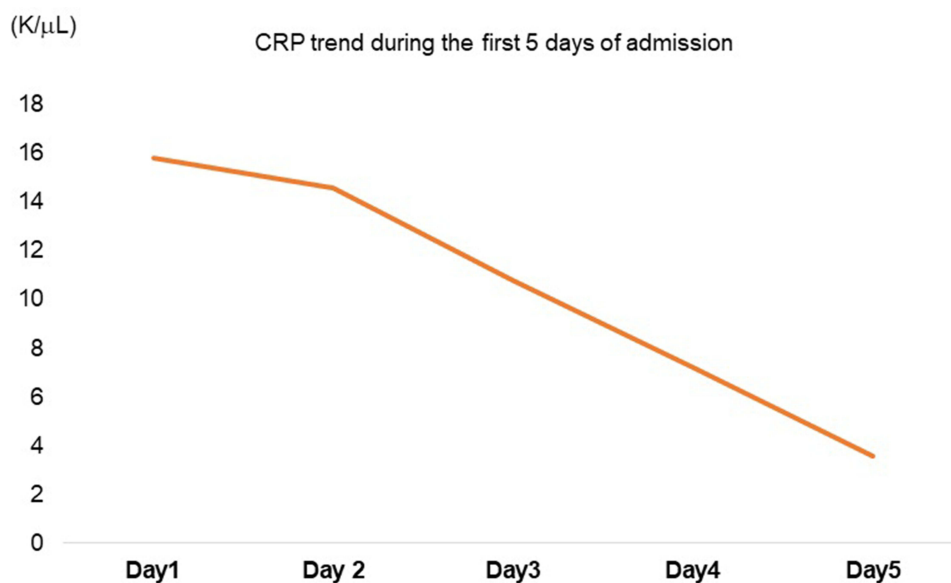
**Figure 1** Plot of WBC trend during the first 5 days of admission.

effects. The WBC count in the CSF decreased to 188 cells/ $\mu$ L on the fifth day after admission, indicating a positive response to antibiotic treatment. The reduction in WBC count suggested that the inflammatory response was under control, and a subsequent bacterial culture of the CSF showed no pathogens, suggesting effective elimination of the pathogen causing the infection by antibiotic treatment. The infant became afebrile within three days, following which he was administered 21 days of IV cefotaxime and ampicillin therapy. Within three days of antibiotic treatment, the infant's fever subsided, indicating a positive response to antibiotics. This initial success prompted the continuation of antibiotic therapy for 21 days.

As late seizures and abnormal findings on neurological examination are indicators that warrant a closer look at the central nervous system, a brain MRI was deemed ideal to determine the extent of neurological involvement and guide appropriate management. The potential for MRI to provide detailed images of the brain, allowing healthcare professionals to identify issues that may impact neurodevelopment, can be particularly relevant in cases of bacterial meningitis, which is an infection that can lead to inflammation of the membranes surrounding the brain and spinal cord.<sup>18</sup> On day 10 of treatment, brain magnetic resonance imaging (MRI) was performed to rule out central nervous system (CNS) complications. The MRI results of the neonate were unremarkable, indicating that no significant structural abnormalities or complications were detected. A continuous 24-hour electroencephalogram (EEG) monitoring was performed to assess the electrical activity of the brain, which revealed no evidence of epileptic discharges, indicating a stable neurological

**Table 2** CRP Trend During the First 5 Days of Admission

Day of Admission	CRP (mg/dL)
Day 1	15.8
Day 2	16
Day 3	9.9
Day 5	3.9



**Figure 2** Plot of CRP trend during the first 5 days of admission.

status. A bilateral auditory-evoked potential test yielded normal results, suggesting the absence of auditory complications. The infant was discharged from the hospital after 21 days of antibiotic therapy and successful management.

## Discussion

This case report highlights the rarity of SGSP-caused meningitis, particularly in the context of the geographic location (Saudi Arabia). This emphasizes the importance of early diagnosis and management of such infections as well as the need for vigilance in monitoring pregnant women for potential transmission. This case report suggests that further investigation is needed into the pathogenesis of and treatment strategies for this emerging infection.

Overall, this case report provides valuable information to the medical community, highlighting the importance of considering rare pathogens, and the need for continuous research to address emerging infections and their management. It also underscores the significance of early diagnosis and effective antibiotic treatment in improving patient outcomes. From a thorough review of previous publications, it is evident that this is the first reported instance of meningitis specifically attributed to *Streptococcus gallolyticus* subsp. *pasteurianus* in a neonate from Saudi Arabia. Thus, careful attention should be paid to identify and study the pathogenic potential of this bacterium, particularly in neonatal populations.

This study is limited by the absence of rectal and vaginal cultures of the neonate's mother to confirm the pathogenesis through intrapartum transmission or the route of infection and the absence of molecular diagnostic tests such as restriction fragment length polymorphism (RFLP), polymerase chain reaction (PCR), and 16S ribosomal ribonucleic acid (16S-rRNA) sequencing for further differential confirmation of the pathogenic strain.

## Literature Review

This case report includes a review of other globally reported cases of NM caused by SGSP, to provide a better understanding of the rarity and emerging nature of these infections. This review contributes significantly to the understanding of *Streptococcus gallolyticus* as a potential pathogen for neonatal infections.

A MEDLINE search identified 13 cases of neonatal meningitis attributed to *Streptococcus gallolyticus* between the time period of 2019 and 2023. Cases that lacked a clear identification or were attributed only to "*Streptococcus bovis*" (*S. bovis*) without further differentiation were excluded from the analysis, leaving nine cases<sup>14,19–26</sup> for evaluation.

**Table 3** Summary of the Recent Neonatal Cases of Streptococcus Gallolyticus Reported in This Report

Study & Country of Reporting	# Cases	Patient Characteristics And Birthweight (g)	Gestational Age (Weeks)	Maternal Perinatal Characteristics	Delivery Type	Age of Presentation	Micro Organism Detected	Clinical Symptoms	Sites Organism Isolated From	Diagnosis	Antibiotic Treatment Course (IV)	Final Outcome
Nguyen et al 2019, <sup>18</sup> USA	2	Male, 4195	39+1 day	GBS-negative	Vaginal	< 24 h	SGSP	Respiratory distress with tachypnea and tachycardia	Blood, CSF, urine	Neonatal sepsis and meningitis, infective endocarditis,	Ampicillin (to Cefepime on day 4) and Gentamicin	Recovered without sequelae
		Male, 3250	40 +1 day	GBS-unknown	Vaginal	< 24 h	SGSP	Drowsy at birth and showed irritability and poor respiratory effort	Blood, CSF, urine, and endotracheal tube	Neonatal sepsis and meningitis	Ampicillin and Gentamicin On day 3 Cefepime (for broader coverage) and clindamycin	Recovered without sequelae
Geetha et al 2021, <sup>19</sup> Singapore	1	Female, 3776	36+6 days	39 y old, GBS-negative, hepatitis B carrier	Vaginal	< 24 h	SGSP and <i>Escherichia coli</i>	Grunting with nasal flaring and subcostal retractions, hypoxia	Blood, CSF, ear swab cultures	Neonatal sepsis and meningitis	Penicillin and Gentamicin, Cefotaxime	Recovered without sequelae
Sim et al 2021, <sup>20</sup> Taiwan	4	Female, 3374	39	GBS-negative	Vaginal	< 24 h	SGSG	Respiratory distress	Blood, CSF	Neonatal sepsis and meningitis	Penicillin and Vancomycin	Recovered without sequelae
		Male, 3268	39	GBS-negative,	Vaginal	4	SGSG	Fever, respiratory distress	Blood, CSF	Neonatal sepsis and meningitis	Penicillin and Ampicillin	Recovered without sequelae
		Female Male, 3194	39	GBS-negative,	Vaginal	23	SGSG	Fever, lethargy	Blood, CSF	Neonatal sepsis and meningitis	Penicillin and Ampicillin	Recovered without sequelae
		Male, 1812	34 twin A	GBS-negative	Cesarean section	< 24 h	SGSG	Fever, poor feeding	Blood, CSF	Neonatal sepsis and meningitis	Vancomycin and Clindamycin	Recovered without sequelae

(Continued)

Table 3 (Continued).

Study & Country of Reporting	# Cases	Patient Characteristics And Birthweight (g)	Gestational Age (Weeks)	Maternal Perinatal Characteristics	Delivery Type	Age of Presentation	Micro Organism Detected	Clinical Symptoms	Sites Organism Isolated From	Diagnosis	Antibiotic Treatment Course (IV)	Final Outcome
Chen et al 2021, <sup>21</sup> Taiwan	3	Female, 2580	35 +1	GBS-negative	Cesarean section		SGSP	Apnea, Desaturation	Blood, CSF	SGSP bacteremia meningitis	Ampicillin and cefotaxime	Recovered without sequelae
		Twins Female, 1861 Male, 2112	37 +1	GBS-positive	Cesarean section	2 5	SGSP	Fever, Tachypnea, Desaturation		Sepsis, meningitis	Ampicillin and cefotaxime	Recovered without sequelae
Srouf et al 2022, <sup>22</sup> Taiwan	1	3190	36+6 days	GBS-negative	Vaginal	< 24 h	SGSG	Intermittent cyanosis and tachypnea	CSF	Bacteremia, meningitis	Penicillin and vancomycin	Recovered without sequelae
Williams et al 2022, <sup>23</sup> USA	1	Male, 950	26	Chronic hypertension. Chorioamnionitis, trichomonas infection, GBS negative	Vaginal	< 24 h	SGSG	Respiratory distress, sepsis	Blood and CSF	Bacteremia, meningitis	Ampicillin and gentamicin	Diseased at 5 <sup>th</sup> h
Iliodromiti et al 2022, <sup>14</sup> Greece	1	Female, 3250	38+1 day	Intrahepatic cholestasis of pregnancy, gestational diabetes mellitus, GBS negative	Cesarean section	< 24 h	SGSG	Grunting, poor feeding, respiratory distress, tachypnoea, fever	Blood and CSF	Bacteremia	Ampicillin and cefotaxime for 10 days	Recovered without sequelae
Orbea et al 2022, <sup>24</sup> USA	15 (5 cases from 2019 to 22)	8 Male and 7 female	<37	NA	NA	Median 24 days (1–74 days)	SGSG	Fever, irritability, difficulty feeding, lethargy, respiratory distress, apnea, seizure-like activity, emesis, diarrhea	Blood and/or CSF	Meningitis, bacteraemia, ventriculitis	Empiric antibiotic therapy	Diseased (1), neurologic complications (1), discharged without any sequelae (13)

Sasi et al 2022, <sup>25</sup> Qatar	2 neonatal cases		36	Pylori gastritis with intestinal metaplasia chorioamnionitis	Vaginal	< 24 h	SGSG	Tachycardia, Tachypnea, poor feeding	Blood	Sepsis	Amikacin and ampicillin	Recovered without sequelae
				Chorioamnionitis	Vaginal	< 24 h	SGSG	Respiratory distress	CSF	Neonatal sepsis.	Ampicillin and amikacin.	Recovered without sequelae
This case, Saudi Arabia	I	Male, 2100	33	GBS negative	Cesarean section	24	SGSP	Fever, lethargy, abnormal movements, poor feeding and respiratory distress			Ampicillin and cefotaxime	Recovered without sequelae

**Abbreviations:** CSF, cerebral spinal fluid; GBS, Group B Streptococcus; IV, intravenous; NA, not available; SG, Streptococcus gallolyticus; SGSG, Streptococcus gallolyticus subsp. gallolyticus; SGSP Streptococcus gallolyticus subsp. pasteurianus.

Of the analyzed cases, 86.66% of the infections occurred during the first week of life. Among the cases, there was a slightly higher incidence of early onset infections ( $\leq 6$  days) than of late-onset infections ( $> 6$  days). The gestational age is known in most cases, and approximately 60% of infants are born prematurely (26–36 weeks).

The clinical symptoms of neonatal *Streptococcus gallolyticus* infections vary and include respiratory distress, apnea, mixed metabolic and respiratory acidosis, fever, lethargy, poor feeding, and seizures.<sup>14,19–26</sup> Interestingly, early onset *S. gallolyticus* infections were more likely to be associated with meningitis than were late-onset infections. Among the cases in which further identification was performed, *Streptococcus gallolyticus* subsp. *Gallolyticus* (86.66%) was identified more commonly than SGSP. This finding suggests that the prevalence of *S. pasteurianus* infection is high in neonates. Most patients were treated with penicillin and/or third-generation cephalosporins. The duration of antimicrobial therapy varied, with a median of 14 days. Despite the severe clinical course of the disease, most patients had a favorable outcome, and the majority survived acute infection. However, few cases of death and neurological deficits have been reported.

However, the exact route of infection by *S. gallolyticus* in neonates remains unclear and is believed that transmission can occur vertically during birth or postnatally through horizontal transmission, possibly from breastfeeding and healthcare workers.<sup>27,28</sup> Similar to Group B *Streptococcus* (GBS), *S. gallolyticus* is often sensitive to penicillin, but cases of reduced susceptibility have been reported.<sup>29,30</sup> The organism also shows susceptibility to Aminoglycosides, Cephalosporins, and Vancomycin, whereas resistance to Quinolones, Macrolides, and Tetracyclines has been reported.<sup>31</sup> Table 3 presents the observations of the studies included in this review.

## Conclusions

Infections caused by *Streptococcus gallolyticus* subsp. *pasteurianus* (SGSP) in neonates are uncommon and can manifest as sepsis, urinary tract infection, or meningitis.<sup>32</sup> This case report uniquely identified a case of late-onset neonatal SGSP infection causing isolated meningitis, which is the first of its kind reported in a preterm infant in Saudi Arabia. The rarity of this presentation underlines the need for healthcare professionals to be aware of unusual pathogens and consider them in the differential diagnosis of neonatal infections. Given the potential transmission of SGSP from colonized pregnant women to neonates, vigilant monitoring of pregnant women during the peripartum period is crucial. This may involve regular diagnostic tests and screening to detect potential infections that can be transmitted to newborns. This case report contributes to the medical literature by expanding our understanding of the potential clinical presentation of SGSP infections in neonates. This case underscores the importance of early diagnosis and prompt treatment to prevent complications and improve outcomes of neonatal infections, providing valuable insights for further research into the epidemiology, transmission routes, and optimal management strategies of SGSP infections in neonates.

In conclusion, this case report emphasizes the importance of clinical awareness, maternal monitoring, and integration of diagnostic tests in the routine care of pregnant women. This proactive approach contributes to improved neonatal care and highlights the significance of reporting and studying rare cases such as those mentioned in this case report.

## Data Sharing Statement

All data underlying the results are available as part of the article and no additional source data are required.

## Institutional Review Board Statement

The study was conducted in accordance with the Declaration of Helsinki and approved by the Institutional Review Board of the College of Medicine, Imam Mohammed Ibn Saud Islamic University (FRP/2023/503/944/880, 5/6/2022) in human studies.

## Informed Consent Statement

Informed consent was obtained from the parent of the patient in the study. Written informed consent has been obtained from the parent of the patient to publish this paper.



## Funding

This study did not receive any external funding.

## Disclosure

The author declares no conflict of interest.

## References

1. Liu Y, Zhu M, Fu X, et al. Escherichia coli causing neonatal meningitis during 2001–2020: a study in eastern China. *Int J General Med.* 2021;14:3007–3016. doi:10.2147/IJGM.S317299
2. Oumer M, Dessie A, Ashenafi T. Time to recovery of neonatal sepsis and determinant factors among neonates admitted in Public Hospitals of Central Gondar Zone, Northwest Ethiopia, 2021. *PLoS One.* 2022;17(7):e0271997. doi:10.1371/journal.pone.0271997
3. Ipek MŞ. Neonatal Bacterial Meningitis. *Neonatal Med IntechOpen.* 2019.
4. Bamshmous YS, Alwagdani SM, Albarakati MM, et al. Infection with Gram-negative Bacteria among Children at a Tertiary Hospital in Jeddah, Saudi Arabia. *Saudi J Kidney Dis Transpl.* 2021;32(6):1593–1599. doi:10.4103/1319-2442.352420
5. Alruqaie N, Falatah Y, Alzahrani F, et al. Case Report: prolonged CSF PCR Positivity in a Neonate With GBS Meningitis. *Front Pediatrics.* 2021;9:752235. doi:10.3389/fped.2021.752235
6. Alwayel ZA, Alghamdi AS, AlmohammedSaleh JA, et al. Hemophilus Septicemia Meningitis in an 11-Month-Old Vaccinated Infant. *Cureus.* 2023;15(2):56.
7. Barnawi AI, Kordy FN, Almuwallad OK, et al. Early neonatal sepsis and meningitis caused by Elizabethkingia meningoseptica in Saudi Arabia. *Saudi Med J.* 2020;41(7):753. doi:10.15537/smj.2020.7.25720
8. Akkaneesermesaeng W, Petpichetchian C, Yingkachorn M, et al. Prevalence and risk factors of group B Streptococcus colonisation in intrapartum women: a cross-sectional study. *J Obstetrics Gynaecol.* 2019;39(8):1093–1097. doi:10.1080/01443615.2019.1587597
9. Pelkonen T, Urtili S, Cardoso O, et al. Accuracy of Clinical and Cerebrospinal Fluid Indicators in the Diagnosis of Bacterial Meningitis in Infants <90 Days of Age in Luanda, Angola. *Pediatric Infectious Dis J.* 2021;40(12):e462–e465. doi:10.1097/INF.0000000000003305
10. Trotta A, Sposato A, Marinaro M, et al. Neurological symptoms and mortality associated with Streptococcus gallolyticus subsp. pasteurianus in calves. *Vet Microbiol.* 2019;236:108369. doi:10.1016/j.vetmic.2019.07.021
11. Park SY, Lee M, Lim SR, et al. Diversity and antimicrobial resistance in the streptococcus bovis/streptococcus equinus complex (sbsec) isolated from Korean domestic ruminants. *Microorganisms.* 2021;9(1):98. doi:10.3390/microorganisms9010098
12. Martínez-Sellés M, Tattevin P, Valerio-Minero M, et al. Infective endocarditis in patients with heart transplantation. *Int J Cardiol.* 2021;328:158–162. doi:10.1016/j.ijcard.2020.12.018
13. Oh YZ, Huang W, Jing Tan J. Streptococcus gallolyticus infective endocarditis, a different presentation-A case report. *Cardiology Plus.* 2022;7(3):144–147. doi:10.1097/CP9.0000000000000020
14. Chandler W, Sakaria RP, Pourcyrous M. Early-Onset Fulminant Sepsis in a Preterm Neonate due to Streptococcus gallolyticus: a Case Report and Literature Review. *Am J Perinatology Rep.* 2022;12(01):e117–e122. doi:10.1055/a-1762-0096
15. Ko MH-J, Chang H-Y, Li S-T, et al. An 18-year retrospective study on the epidemiology of early-onset neonatal sepsis-emergence of uncommon pathogens. *Pediatrics Neonatol.* 2021;62(5):491–498. doi:10.1016/j.pedneo.2021.02.005
16. Ruili WANG, Shiyang HU, Shengnan ZH, Yan LI. Streptococcus gallolyticus meningitis: a systematic review. *Chin J Evidence Based Pediatrics.* 2022;17(5):350.
17. Miyoshi IC, de Toledo AH, Pereira FV, et al. *INFECTIOUS MYELITIS. Seminars in Ultrasound, CT and MRI.* WB Saunders; 2023.
18. Oliveira CR, Morriss MC, Mistrot JG, et al. Brain magnetic resonance imaging of infants with bacterial meningitis. *J Pediatrics.* 2014;165(1):134–139. doi:10.1016/j.jpeds.2014.02.061
19. Nguyen MT, Idriss S, Guzman E, et al. Neonatal meningitis, endocarditis, and pneumonitis due to Streptococcus gallolyticus subsp. pasteurianus: a case report. *BMC Pediatrics.* 2019;19(1):1–5. doi:10.1186/s12887-019-1645-x
20. Geetha O, Cherie C, Natalie TWH, et al. Streptococcus gallolyticus subspecies pasteurianus causing early onset neonatal sepsis complicated by solitary liver abscess in a preterm infant. *Access Microbiol.* 2021;3(3). doi:10.1099/acmi.0.000200
21. Sim JY, Wang L-W, Chow JC, et al. Streptococcus gallolyticus—A potentially neglected pathogen causing neonatal sepsis not covered by routine group B streptococcus screening. *J Microbiol Immunol Infection.* 2021;54(6):1190–1192. doi:10.1016/j.jmii.2021.05.003
22. Chen W-C, Lee P-I, Lin H-C, et al. Clustering of Streptococcus gallolyticus subspecies pasteurianus bacteremia and meningitis in neonates. *J Microbiol Immunol Infection.* 2021;54(6):1078–1085. doi:10.1016/j.jmii.2020.07.004
23. Srour N, Dasnadi S, Korulla A, et al. Early-onset neonatal ventriculomeningitis due to Streptococcus gallolyticus: a case report. *Pediatrics Neonatol.* 2022;63(4):430–431. doi:10.1016/j.pedneo.2021.11.012
24. Iliodromiti Z, Tsaousi M, Kitsou K, et al. Neonatal Sepsis Caused by Streptococcus gallolyticus Complicated with Pulmonary Hypertension: a Case-Report and a Systematic Literature Review. *Diagnostics.* 2022;12(12):3116. doi:10.3390/diagnostics12123116
25. Orbea M, Desai N, Foster C. Invasive Streptococcus gallolyticus Infections in Infants at Texas Children’s Hospital: a 9-Year Retrospective Review. *Pediatric Infectious Dis J.* 2022;41(11):e494–e497. doi:10.1097/INF.0000000000003682
26. Sasi S, Abid FB, Wilson GJ, et al. Intrauterine infection and postpartum bacteremia due to Streptococcus gallolyticus subsp. gallolyticus: an emerging concern. *IDCases.* 2022;29:e01562. doi:10.1016/j.idcr.2022.e01562
27. Miaohang M, Wang S, Zhu X, et al. The Identification of Streptococcus pasteurianus Obtained from Six Regions in China by Multiplex PCR Assay and the Characteristics of Pathogenicity and Antimicrobial Resistance of This Zoonotic Pathogen. *Pathogens.* 2023;12(4):615. doi:10.3390/pathogens12040615
28. Tavares T, Pinho L, Bonifácio Andrade E. Group B streptococcal neonatal meningitis. *Clin Microbiol Rev.* 2022;35(2):e00079–21. doi:10.1128/cmr.00079-21

29. Wang X, Chan PH, Lau HY, et al. Epidemiologic Changes of Neonatal Early-onset Sepsis After the Implementation of Universal Maternal Screening for Group B Streptococcus in Hong Kong. *Pediatric Infectious Dis J.* 2023;10–1097.
30. Stoneham S, Peters J, Price J. Staphylococcal and streptococcal infections. *Medicine.* 2021;49(12):731–738. doi:10.1016/j.mpmed.2021.09.001
31. Hayes K, O'Halloran F, Cotter L. A review of antibiotic resistance in Group B Streptococcus: the story so far. *Crit. Rev. Microbiol.* 2020;46(3):253–269. doi:10.1080/1040841X.2020.1758626
32. Takegami N, Ito T, Yamamoto J, et al. A Rare Case of Meningitis Caused by Streptococcus gallolyticus subsp. pasteurianus in an Immunocompetent Young Adult. *Internal Med.* 2023;62(12):1785. doi:10.2169/internalmedicine.0720-22

### International Medical Case Reports Journal

Dovepress

### Publish your work in this journal

The International Medical Case Reports Journal is an international, peer-reviewed open-access journal publishing original case reports from all medical specialties. Previously unpublished medical posters are also accepted relating to any area of clinical or preclinical science. Submissions should not normally exceed 2,000 words or 4 published pages including figures, diagrams and references. The manuscript management system is completely online and includes a very quick and fair peer-review system, which is all easy to use. Visit <http://www.dovepress.com/testimonials.php> to read real quotes from published authors.

Submit your manuscript here: <https://www.dovepress.com/international-medical-case-reports-journal-journal>