

Clinical Outcomes of Percutaneous Transforaminal Endoscopic Discectomy Assisted with Selective Nerve Root Block for Treating Radicular Pain with Diagnostic Uncertainty in the Elderly

Yanjie Zhu^{1,2}, Xinkun Zhang^{1,2}, Guangfei Gu^{1,2}, Yunshan Fan^{1,2}, Zhi Zhou^{1,2}, Chaobo Feng^{1,2}, Xin Gu³, Shisheng He^{1,2}

¹Department of Orthopedic, Shanghai Tenth People's Hospital, Tongji University School of Medicine, Shanghai, People's Republic of China; ²Spinal Pain Research Institute, Tongji University School of Medicine, Shanghai, People's Republic of China; ³Department of Orthopedic Surgery, Tongren Hospital, Shanghai Jiao Tong University School of Medicine, Shanghai, People's Republic of China

Correspondence: Shisheng He, Department of Orthopedic, Shanghai Tenth People's Hospital, Tongji University School of Medicine, 301 Yanchang Road, Shanghai, 200072, People's Republic of China, Email tjhss7418@tongji.edu.cn; Xin Gu, Department of Orthopedic Surgery, Tongren Hospital, Shanghai Jiao Tong University School of Medicine, No. 1111 Xianxia Road, Shanghai, 200050, People's Republic of China, Email guxin2004ty@163.com

Purpose: To investigate the clinical outcomes of percutaneous transforaminal endoscopic discectomy assisted with selective nerve root block for treating radicular pain with diagnostic uncertainty in the elderly.

Methods: A total number of 36 elderly patients were included in the study. Clinical outcomes collected for analysis include operative time, hospital stay time, Visual Analog Scale, and Oswestry Disability Index before and after the surgery, the global outcome based on the Macnab outcome criteria.

Results: Seventeen males and nineteen females with a mean age of 73.72 ± 7.15 were included in this study. Radicular pain was the main complaint of all the patients with the least symptom duration of two months. Radiological findings showed that 80.6% of the patients with multilevel disc herniation, 16.7% received lumbar fusion surgery before, and 8.3% with degenerative scoliosis. Besides, 69.4% of the patients have at least one comorbidity. 85.4% of the patients showed a positive response to selective nerve root block, and 91.6% of the patients reported a favorable outcome at the last follow-up. The mean value of pre-operative leg pain was 7.56 ± 0.74 and dramatically decreased after surgery (2.47 ± 0.81 , $P < 0.001$). Besides, the mean value of Oswestry Disability Index decreased from 43.03 ± 4.43 to 5.92 ± 5.24 ($P < 0.001$) one year after the surgery.

Conclusion: Multilevel degeneration of the lumbar spine is common in elderly patients. Identifying the responsible segment and decompressing the nerve root through minimally invasive surgery can provide a satisfactory clinical outcome for those with radicular pain as their primary complaint. And selective nerve root block is a reliable diagnostic tool for those with an ambiguous diagnosis.

Keywords: percutaneous transforaminal endoscopic discectomy, selective nerve root block, radicular pain, elderly, clinical outcome

Introduction

Around two-thirds of adults experience low back pain at least once in their lifetime, and approximately 10% report radicular pain.¹ Compression or inflammation irritation of the nerve root caused by the herniated lumbar disc is the primary cause of radicular pain.^{2,3} In most cases, radicular pain resolves spontaneously or after conservative treatment, but a small number of patients suffer from chronic or recurrent pain, some even aggravated by numbness or muscle weakness, and require surgical treatment.^{3,4}

With an aging population, surgical procedures that require less anesthesia, shorter hospital stays, and result in less blood loss and fewer injuries are crucial to the success of surgery in older patients. Clinical outcomes of minimally invasive surgeries like percutaneous transforaminal endoscopic discectomy (PTED) for lumbar disc herniation are

promising.⁵ The prerequisite for minimally invasive surgery is an accurate diagnosis of the responsible segment that relies on the patient's symptoms, physical examinations, and imaging findings.⁴⁻⁶ However, it is not easy for the elderly population with multilevel lumbar spine degeneration or atypical pain, increasing diagnostic uncertainty.^{6,7}

Selective nerve root block (SNRB) was first described by Macnab et al in 1971 to treat lower leg radicular pain and remains a popular therapeutic and diagnostic option for radicular pain.^{3,4,6-9} Despite the fact that many studies have demonstrated that SNRB is a viable diagnostic tool for determining the responsible segment, only a few studies have focused on elderly patients with multilevel lumbar spine degeneration.⁷ Hence, this retrospective study included a group of elderly patients with radicular pain as the primary complaint but a doubtful diagnosis, to investigate the clinical outcomes of selective nerve root block combined with percutaneous transforaminal endoscopic discectomy.

Materials and Methods

Patient Selection

This retrospective study adhered to the Declaration of Helsinki, written informed consent was obtained from each patient, and in the case of patients who were unable to write, informed consent was obtained from the guardians. And it was approved by the Institutional Review Boards of Shanghai Tenth People's Hospital. From January 2017 to December 2021, this study enrolled consecutive patients older than 65 years who underwent SNRB followed by PTED treatment. All patients received SNRB before PTED were because of the diagnostic uncertainty based on their symptoms, physical examinations, and imaging findings.

Surgical Procedures

All patients were instructed to refrain from taking any pain relievers or analgesics for 24 hours prior to surgery. One hour before SNRB, all the patients rated their back pain and leg pain using the Visual Analog Scale (VAS). We performed SNRB through a transforaminal approach starting from the largest possible segment and the procedure was performed as described previously.¹⁰ Briefly, patients were laid in a prone position on a radiolucent table in an X-ray suite. The 18G-long needle was advanced slowly under repeated fluoroscopy and stopped when it was under the lateral edge of the pedicle just above the target foramen (Figure 1a and b). The needle tip should not extend beyond the midportion of the pedicle in an AP view. Once the needle was in the correct position, 0.5 mL of iohexol (contrast medium) (300 mg/mL; Omnipaque GE Healthcare Ireland, Cork, Ireland) was slowly injected under the fluoroscopic guidance to determine the distribution (Figure 1c). Then, 0.5 mL of 1% lidocaine was injected if the correct needle position was confirmed. After around 30 seconds, the patient was

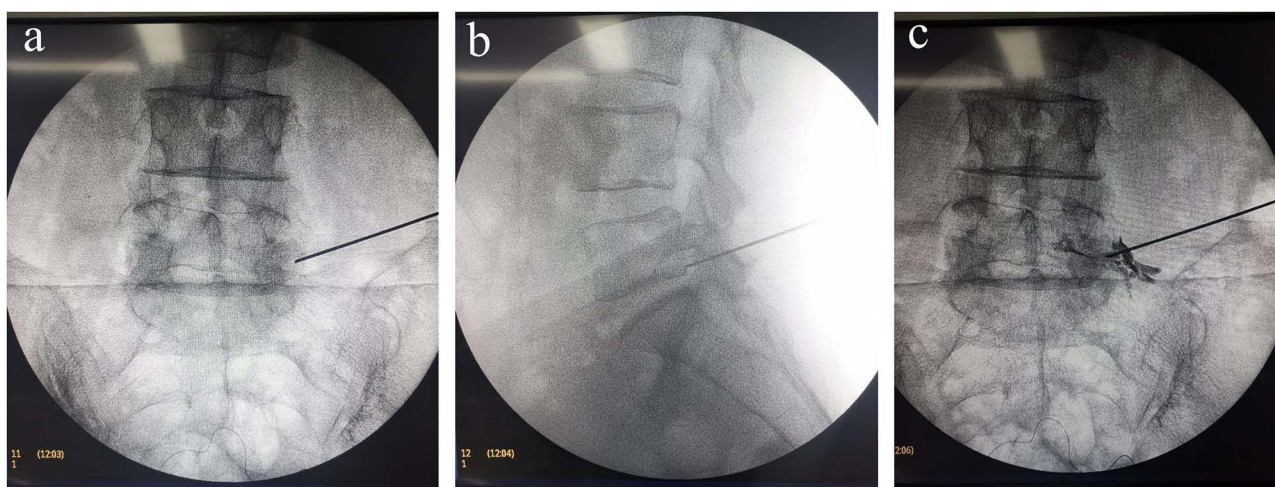


Figure 1 A 67-year-old man presented with radicular pain on the left side. Selective nerve root block (SNRB) was performed on the left side of the L5-S1 level to determine the responsible segment. (a and b) The location of SNRB injection site. The 8G needle was stopped under the lateral edge of the pedicle just above the target foramen. The needle tip should not go beyond the midportion of the pedicle in an anteroposterior view. (c) 0.5 mL of contrast medium was injected to determine the contrast medium's distribution and ensure it is limited around the target foramen.

asked to re-rate the leg pain using the VAS. If a reduction in leg pain of more than 50% was reported by the patient, the nerve root was assumed to be responsible for the radicular pain. If not, the next possible segment was considered for SNRB. The standard PTED procedure was performed by an experienced senior surgeon only on the confirmed responsible segment.

Clinical Evaluation

Primary surgical outcomes included the Visual Analog Scale (VAS) and Oswestry Disability Index (ODI) after surgery, and the secondary surgical outcomes included the times of SNRB, the operative time, hospital stay time, the global outcome based on the Macnab outcome criteria and complications. Back and leg pain was quantified by VAS collected from the patients preoperatively, and 1 week, 3 months, 6 months, and 12 months postoperatively. The ODI was used to assess the impact of the patient's leg or back condition on their daily activities before surgery and at 3, 6, and 12 months after surgery. Operating time including the procedures of SNRB and PTED. Global outcome was assessed as excellent, good, fair, or poor based on the Macnab outcome criteria 12 months postoperatively. A favorable outcome was defined as excellent or good.

Statistical Analysis

The software of SPSS 21.0 (SPSS, USA) was used for statistical analysis. Continuous variables (age, body mass index, operation time, hospital stay time, etc) are presented as mean (standard deviation, SD) or mean \pm SD. Categorical variables were presented as frequency (%). Paired *t*-test was used to compare the clinical outcome at different time points after surgery. The statistical significance level was set at $P < 0.05$.

Results

A total number of 48 cases were performed SNRB, 7 cases got negative responses, 3 cases got positive responses but decided to stop the following surgery, and 2 cases were lost to follow-up, 36 cases (17 males, mean age 73.72 ± 7.15) were included at last. In those included cases, 25 cases (67.6%) got a positive response to the SNRB for the first injection, 10 cases (27.0%) for the second injection, one case for the third injection, and another case got a positive response at two segments and we did two level PTED at last. The baseline characteristics were shown in Table 1. The mean BMI of the patients is 25.89 ± 2.27 . The mean duration of the radicular pain pre-operation is 14.75 ± 14.89 months, ranging from 2 months to 50 months. Twenty-nine patients (80.6%) showed more than one level of lumbar disc herniation, six cases received fusion surgery of the lumbar spine before and three cases showed degenerative scoliosis.

Table 1 Characteristics of the Patients at Baseline and Surgery Information

Characteristics	Mean(SD)/n(%)
Age (yrs)	73.72(7.15)
Gender (male)	17(47.2%)
BMI (kg/m ²)	25.89(2.27)
Duration of radicular pain (Mo)	14.75(14.89)
Diagnosis	
Multilevel disc herniation	29(80.6%)
Lumbar stenosis	17(47.2%)
Post fusion surgery	6(16.7%)
Degenerative scoliosis	3(8.3%)
Comorbidities	
Hypertension	17(47.3%)
Diabetes	9(25.0%)
Cardiovascular disease	4(11.2%)
Post-stroke	3(8.3%)
No any comorbidity	11(30.6%)
More than 2 comorbidities	9(25.0%)

Abbreviation: BMI, Body-mass index.

Clinical Outcomes

The surgery information and clinical outcomes were showed in Tables 2 and 3. Among all the patients, 3 cases received PTED surgery at L3-4, 17 cases at L4-5, 15 cases at L5-S1, and 1 case received two-level PTED at L3-5. The mean surgery time was 71.33 ± 8.52 minutes and the mean length of hospital stay time was 4.67 ± 1.17 days. According to the follow-up, 91.6% of patients had favorable surgery outcomes 12 months after surgery. Radicular pain was the primary complaint of all the patients, the mean value of pre-operative leg pain was 7.56 ± 0.74 and dramatically decreased one year after surgery (1.22 ± 1.53 , $P < 0.001$). Besides, the mean value of ODI decreased from 43.03 ± 4.43 to 5.92 ± 5.24 one year after the surgery. The mean value of pre-operative back pain was 2.47 ± 0.81 , showing significant change 3 months or longer time after surgery but not 1 week after surgery.

Table 2 Surgery Information and Clinical Outcomes

	Mean(SD)/n(%)
Surgery level	
L3-4	3(8.3%)
L4-5	17(47.2%)
L5-S1	15(41.7%)
L3-5	1(2.8%)
Times of SNRB	
First	25(67.6%)
Second	10(27.0%)
Third	1(2.7%)
Twice positive	1(2.7%)
Surgery Time(mins)	71.33(8.52)
Hospital Stay Time(days)	4.67(1.17)
Pathology	
Disc herniation	25(69.4%)
Foraminal stenosis	11(30.6%)
Complications	
Elevated blood pressure	4(11.1%)
Headache	1(2.8)
Macnab Nab Satisfaction	
Excellent	21(58.3%)
Good	12(33.3%)
Fair	2(5.6%)
Poor	1(2.8%)

Abbreviations: SD, Standard deviation; SNRB, Selective Nerve Root Block; Times of SNRB, "First" means got a positive response to SNRB for the first time, "Twice positive" means two segments got a positive response to SNRB.

Table 3 Patients-Reported Clinical Outcomes

	Pre-Operative	Post-Operative			
		1 Week	3 Months	6 Months	12 months
ODI	43.03±4.43	–	10.19±2.82*	8.03±3.81*	5.92±5.24*
Mean dif (95% CI)		–	32.83(30.98,34.68)	35.00(33.02,36.98)	37.11(34.81,39.41)
VAS of back pain	3.58±1.44	3.72±0.70	2.44±0.88*	2.03±0.94*	2.00±0.93*
Mean dif (95% CI)		–0.14(–0.55,0.27)	1.14(0.75,1.53)	1.56(1.14,1.97)	1.58(1.17,1.99)
VAS of leg pain	7.56±0.74	2.47±0.81*	1.78±0.83*	1.44±1.59*	1.22±1.53*
Mean dif (95% CI)		5.08(4.65,5.51)	5.78(5.38,6.18)	6.11(5.50,6.72)	6.33(5.73,6.94)

Notes: * $P < 0.001$, Mean dif: mean difference.

Abbreviation: CI, confidence interval.

Complications

Four patients had evaluated blood pressure during the operation and were controlled with antihypertensive medications. One patient experienced postoperative headache, which improved after bed rest. No other severe intra- or post-operative complications such as nerve root injury, dural sac tear, hematoma formation, or infection were observed. No patient required additional surgery at 12 months postoperatively, and the three patients who reported fair or poor satisfaction achieved relief of back pain after conservative treatments.

Discussion

In this study, we enrolled 36 elderly patients with radicular pain and performed SNRB followed by PTED. A significant decrease in VAS and ODI scores was observed at the last follow-up, and no serious complication was reported.

With the advent of an aging society, the incidence of the degenerative spine disease is increasing, and there has been a dramatic increase in spine surgery in the elderly in recent years.^{11,12} However, determining the best surgical option for elderly patients with severe spinal degeneration, such as multilevel lumbar disc herniation, stenosis, spondylolisthesis, or even degenerative scoliosis, can be difficult. In such conditions, multi-level fusion surgery or even orthopedic surgery may solve all the problems at once. However, it means more tissue damage, more blood loss, longer hospital stay time, and higher costs. Also, osteoporosis and adjacent segmental degeneration may increase the risk of readmission.¹³ In addition, elderly patients have a higher prevalence of multiple medical comorbidities, increasing the pre- and postoperative complications.^{12,13} Hai Nie et al reported that the length of hospital stay in patients over age 80 who received spinal surgery was more than two folds compared to the middle-aged patients.¹⁴ In this study, 80.6% of patients presented with multiple levels of lumbar disc herniation, with 16.7% having received previous fusion surgery and 8.3% exhibiting degenerative scoliosis. Only less than one-third of participants had no comorbidities. And, almost all the patients had a concern about the surgical injury, complications, or costs. The preoperative VAS of leg and back showed that unbearable radicular pain was their main complaint, so we decided to identify the responsible segment first and then decompress the nerve root by PTED. We found the VAS of leg pain decreased dramatically after surgery, also the ODI, and only three patients complained of more severe back pain after surgery. We considered vertebral instability as the main cause of back pain, and foraminoplasty during PTED may increase the instability. After the use of oral analgesics and physical therapy, all three patients experienced pain relief. Overall, more than ninety percent of the patients reported a favorable outcome, and no severe complications were observed, indicating that PTED assisted with SNRB can provide reliable surgical outcomes for elderly patients.

It is widely accepted that an accurate diagnosis is derived from a combination of history taking, physical examinations, and radiologic assessments. However, it can be elusive. Bove and colleagues¹⁵ conducted a study of 25 patients with radicular leg pain and found that classic dermatome maps may not be useful in this context, as all patients reported deep rather than superficial pain. Murphy et al¹⁶ also concluded that two-thirds of nerve root pain in the lumbar spine does not follow a specific dermatome pattern. SNRB has become a popular minimally invasive diagnostic and therapeutic option for radicular pain.^{3,4} Tareq Kanaan et al³ reported that 90.7% of patients got pain relief immediately after SNRB. However, 61.8% of patients experienced pain recurrence during the three months of follow-up. This may be explained by the fact that SNRB does not eliminate the pathological factors contributing to radicular pain.⁴ Sangbong Ko et al⁴ reported that a positive response after SNRB can predict the degree of improvement in lower leg radicular pain at 12 months after surgery. In this study, around one-third of the enrolled patients received a negative response to SNRB for the first injection, which is consistent with the literature, supporting the necessity of SNRB to identify the responsible segment before surgery. Further, we found 14.5% (seven of forty-eight) of the patients showed no response to SNRB, indicating PTED may not be a suitable surgical option for these patients. As the negative SNRB response undermined our confidence in a good surgical outcome after decompression of the nerve root, we ultimately recommended these patients to be treated conservatively. Williams, A.P. et al⁶ showed that the positive predictive value of lumbar dorsal root ganglion block in predicting a good outcome of surgical decompression is 80.4%, but the negative predictive value of the test was weak at 22.2%. Thus, for patients with a negative SNRB response, “surgery or not”, and “what surgery to be performed” must be considered carefully.

The choice of block site and drug dose for selective nerve root blocks are critical to diagnostic accuracy. Datta and Pai⁹ suggested rephrasing SNRB as “paraforaminal injection”. Similarly, the over-volume of injected medication may

result in an extensive blockade and thereby undermining the specificity. Furman et al¹⁷ concluded that for selective diagnostical lumbar SNRB, the volume should not exceed 0.5 mL. In this study, we chose a transforaminal approach for SNRB but the actual block site is out of the foramen to ensure that the injected medication only affects one nerve root.

This study has several limitations. First, the sample size was relatively small, because we only included patients older than 65 years, and not all the patients required diagnostic SNRB. But still, a larger sample size will provide a more convincing conclusion. Second, the length of follow-up was limited, longer follow-up may help to clarify the long-term clinical outcomes. Third, we did not test whether different types or volumes of drugs make a difference to the clinical outcomes. But for diagnostic reliability, we suggested to do paraforaminal injection and do not use drug volume over 0.5 mL.

Conclusion

Multilevel lumbar spine degeneration is common in elderly patients. Identifying the responsible segment and decompressing the nerve root through minimally invasive surgery can result in a satisfactory clinical outcome for those with radicular pain as their primary complaint. And, selective nerve root block is a reliable diagnostic tool for those with an ambiguous diagnosis.

Funding

Science and Technology Commission of Shanghai Municipality(No.22S31900100), Yunnan Academician Expert Workstation(No.202205AF150058).

Disclosure

The authors declare no competing interest exists in this work.

References

1. Deyo RA, Mirza SK. CLINICAL PRACTICE. Herniated Lumbar Intervertebral Disk. *N Engl J Med.* 2016;374(18):1763–1772. doi:10.1056/NEJMcp1512658
2. Rainville J, Lopez E. Comparison of radicular symptoms caused by lumbar disc herniation and lumbar spinal stenosis in the elderly. *Spine (Phila Pa 1976).* 2013;38(15):1282–1287. doi:10.1097/BRS.0b013e31828f463e
3. Kanaan T, Abusaleh R, Abuasbeh J, et al. The Efficacy of Therapeutic Selective Nerve Block in Treating Lumbar Radiculopathy and Avoiding Surgery. *J Pain Res.* 2020;13:2971–2978. doi:10.2147/JPR.S276331
4. Ko S, Jun C, Min WK, et al. Pain Relief After Selective Nerve Root Block as a Predictor of Postoperative Functional Outcome in Patients with Degenerative Lumbar Spinal Stenosis Patients Undergoing Decompressive Surgery. *Spine (Phila Pa 1976).* 2022;47(9):666–671. doi:10.1097/BRS.00000000000004216
5. Kim HS, Wu PH, Jang IT. Current and Future of Endoscopic Spine Surgery: what are the Common Procedures we Have Now and What Lies Ahead? *World Neurosurg.* 2020;140:642–653. doi:10.1016/j.wneu.2020.03.111
6. Williams AP, Germon T. The value of lumbar dorsal root ganglion blocks in predicting the response to decompressive surgery in patients with diagnostic doubt. *Spine J.* 2015;15(3 Suppl):S44–S9. doi:10.1016/j.spinee.2015.01.004
7. Datta S, Manchikanti L, Falco FJ, et al. Diagnostic utility of selective nerve root blocks in the diagnosis of lumbosacral radicular pain: systematic review and update of current evidence. *Pain Physician.* 2013;16(2Suppl):SE97–SE124.
8. Kanayama M, Oha F, Hashimoto T. What types of degenerative lumbar pathologies respond to nerve root injection? A retrospective review of six hundred and forty one cases. *Int Orthop.* 2015;39(7):1379–1382. doi:10.1007/s00264-015-2761-3
9. Datta S, Pai U. Selective nerve root block--is the position of the needle transforaminal or paraforaminal? Call for a need to reevaluate the terminology. *Reg Anesth Pain Med.* 2004;29(6):616–617. doi:10.1016/j.rapm.2004.07.219
10. Shi C, Xu N, Sun B, et al. Clinical Outcomes of Posterior Percutaneous Endoscopic Cervical Foraminotomy and Discectomy Assisted with SNRB in Treating Cervical Radiculopathy with Diagnostic Uncertainty. *Pain Physician.* 2021;24(4):E483–E492.
11. Kobayashi K, Ando K, Nishida Y, Ishiguro N, Imagama S. Epidemiological trends in spine surgery over 10 years in a multicenter database. *Eur Spine J.* 2018;27(8):1698–1703. doi:10.1007/s00586-018-5513-4
12. Cloyd JM, Acosta FL, Ames CP. Complications and outcomes of lumbar spine surgery in elderly people: a review of the literature. *J Am Geriatr Soc.* 2008;56(7):1318–1327. doi:10.1111/j.1532-5415.2008.01771.x
13. Agarwal N, Faramand A, Alan N, et al. Lateral lumbar interbody fusion in the elderly: a 10-year experience. *J Neurosurg Spine.* 2018;29(5):525–529. doi:10.3171/2018.3.SPINE171147
14. Hai NI. Efficacy and Safety of Surgery for Lumbar Disc herniation in Patients Aged 80 and Older. *Turk Neurosurg.* 2011;21:548.
15. Bove GM, Zaheen A, Bajwa ZH. Subjective nature of lower limb radicular pain. *J Manipulative Physiol Ther.* 2005;28(1):12–14. doi:10.1016/j.jmpt.2004.12.011
16. Murphy DR, Hurwitz EL, Gerrard JK, Clary R. Pain patterns and descriptions in patients with radicular pain: does the pain necessarily follow a specific dermatome? *Chiropr Osteopat.* 2009;17(1):9. doi:10.1186/1746-1340-17-9
17. Furman MB, Lee TS, Mehta A, Simon JI, Cano WG. Contrast flow selectivity during transforaminal lumbosacral epidural steroid injections. *Pain Physician.* 2008;11(6):855–861. doi:10.36076/ppj.2008/11/855

Journal of Pain Research

Dovepress

Publish your work in this journal

The Journal of Pain Research is an international, peer reviewed, open access, online journal that welcomes laboratory and clinical findings in the fields of pain research and the prevention and management of pain. Original research, reviews, symposium reports, hypothesis formation and commentaries are all considered for publication. The manuscript management system is completely online and includes a very quick and fair peer-review system, which is all easy to use. Visit <http://www.dovepress.com/testimonials.php> to read real quotes from published authors.

Submit your manuscript here: <https://www.dovepress.com/journal-of-pain-research-journal>