

Successful Treatment of an AML Patient Infected with Hypervirulent ST463 *Pseudomonas Aeruginosa* Harboring Rare Carbapenem-Resistant Genes *bla*_{AFM-1} and *bla*_{KPC-2} Following Allogeneic Hematopoietic Stem Cell Transplantation

Yingying Shen^{1,2,*}, Junmin Cao^{3,*}, Tonglin Hu^{1,2}, Xiawan Yang^{1,2}, Yuechao Zhao^{1,2}, Yiping Shen^{1,2}, Baodong Ye^{1,2}, Yunsong Yu⁴, Dijiong Wu^{1,2}

¹Department of Hematology, The First Affiliated Hospital of Zhejiang Chinese Medical University (Zhejiang Provincial Hospital of Chinese Medicine), Hangzhou, Zhejiang, People's Republic of China; ²National Traditional Chinese Medicine Clinical Research Base (Hematology), Hangzhou, Zhejiang, People's Republic of China; ³Department of Clinical Laboratory, The First Affiliated Hospital of Zhejiang Chinese Medical University (Zhejiang Provincial Hospital of Chinese Medicine), Hangzhou, Zhejiang, People's Republic of China; ⁴Department of Infectious Diseases, Zhejiang Provincial People's Hospital, Hangzhou, Zhejiang, People's Republic of China

*These authors contributed equally to this work

Correspondence: Dijiong Wu, Department of Hematology, The First Affiliated Hospital of Zhejiang Chinese Medical University (Zhejiang Provincial Hospital of Chinese Medicine), Hangzhou, Zhejiang, 310006, People's Republic of China, Tel +86-0571-86620325, Email wudijiong@zcmu.edu.cn; Yunsong Yu, Department of Infectious Diseases, Zhejiang Provincial People's Hospital, Hangzhou, Zhejiang, 310024, People's Republic of China, Tel +8613805790432, Email yvys119@zju.edu.cn

Background: Carbapenem-resistant *P. aeruginosa* (CRPA) is a common hospital-acquired bacterium. It exhibits high resistance to many antibiotics, including *ceftazidime/avibactam* and *ceftolozane/tazobactam*. The presence of carbapenem-resistant genes and co-existence *Klebsiella pneumoniae* carbapenemase (KPC) and metallo- β -lactamases (MBLs) further inactivated all β -lactams. Understanding the resistance genes of CRPA can help in uncovering the resistance mechanism and guiding anti-infective treatment. Herein, we reported a case of perianal infection with hypervirulent ST463 *Pseudomonas aeruginosa*.

Case Presentation: The case is a 32-year-old acute myeloid leukemia (AML) patient with fever and septic shock during hematopoietic stem cell transplantation (HSCT), and the pathogen was finally identified as a highly virulent sequence type 463 (ST463) *P. aeruginosa* harboring carbapenem-resistant genes *bla*_{AFM-1} and *bla*_{KPC-2}, which was detected in the bloodstream and originated from a perianal infection. The strain was resistant to *ceftazidime/avibactam* but successfully treated with *polymyxin B*, surgical debridement, and granulocyte engraftment after HSCT. The AML was cured during the 19-month follow-up.

Conclusion: This case emphasizes the importance of metagenomic next-generation sequencing (mNGS) and whole-genome sequencing (WGS) in identifying microbes with rare resistant genes, and managing CRPA, especially in immunocompromised patients. *Polymyxin B* may be the least resistant option.

Keywords: carbapenem-resistant pseudomonas aeruginosa, *bla*_{AFM}, *bla*_{KPC}, ST463

Background

As one of the most common nosocomial bacteria, *Pseudomonas aeruginosa* often causes infections associated with blood, urinary tract, skin and soft tissue.¹ In the treatment of multidrug-resistant *P. aeruginosa* (MDR-PA), carbapenems have proven to be the most effective antibiotics. However, the extensive use of carbapenems has resulted in a significant increase in carbapenem-resistant *P. aeruginosa* (CRPA) strains.² The increasing prevalence of CRPA has further elevated

the mortality rate, with a 30% 30-day mortality rate even after appropriate treatment,² which was higher in hematological disorder patients with granulocytopenia.

Hematopoietic stem cell transplantation (HSCT) is a crucial treatment for curing hematologic malignancies. Infections often occur during the neutropenic phase of HSCT, which may lead to graft failure or life-threatening complications. In particular, early-onset severe CRPA infection during HSCT will negatively impact the long-term prognosis because it poses a significant constraint on therapeutic strategies. Therefore, it is important to further understand the drug-resistance mechanisms of *P. aeruginosa* and make rational choices for anti-infection strategies. Herein, we isolated a strain of *bla*_{KPC-2} ST463 CRPA, resistant to *ceftazidime/avibactam*, from the bloodstream of a HSCT patient. The final result of whole-genome sequencing (WGS) analysis indicated that this strain simultaneously produces *Klebsiella pneumoniae* carbapenemase (KPC) and *Alcaligenes faecalis* metallo- β -lactamase-1 (AFM1) enzymes, exhibiting a high level of drug resistance. A literature review retrieved only a few papers describing a novel type of plasmid with multidrug-resistant (MDR) regions, and no case had been reported in HSCT with severe immune deficiency. To further understand these strains, we described the process of CRPA strain isolated from blood and the patient's treatment course against CRPA to provide resources for clinicians. We also reviewed the available studies on CRPA carrying the *bla*_{AFM} gene to further study the resistance mechanism of this bacterium.

Case Presentation

A 32-year-old Asian man with hyperleukocytosis was diagnosed with acute myeloid leukemia (AML) in March 2022 (FAB M1), accompanied with CREBBP and ALK mutations, positive fusion gene *ETO* and t (8;21) (q22; q22.1) cytogenetic abnormality. He achieved partial remission after the first round of induction chemotherapy (cytarabine 100 mg/m² days 1–7 and idarubicin 10 mg/m² days 1, 2 and 3), and achieved complete remission after an additional round of chemotherapy with HAD (homoharringtonine 2 mg days 1–7, idarubicin 10 mg/m² days 1, 2 and 3, and cytarabine 100 mg/m² days 1–7). Subsequently, consolidation therapy was administered with HAD and intermediate-dose cytarabine, however, the patient did not reach genetic minimal residual disease (MRD) negativity throughout the treatment course (Figure 1). Owing to hyperleukocytic AML and insufficient depth of remission, the patient was classified as “high-risk AML”, and allogeneic stem cell transplantation was indicated. A fully-matched unrelated

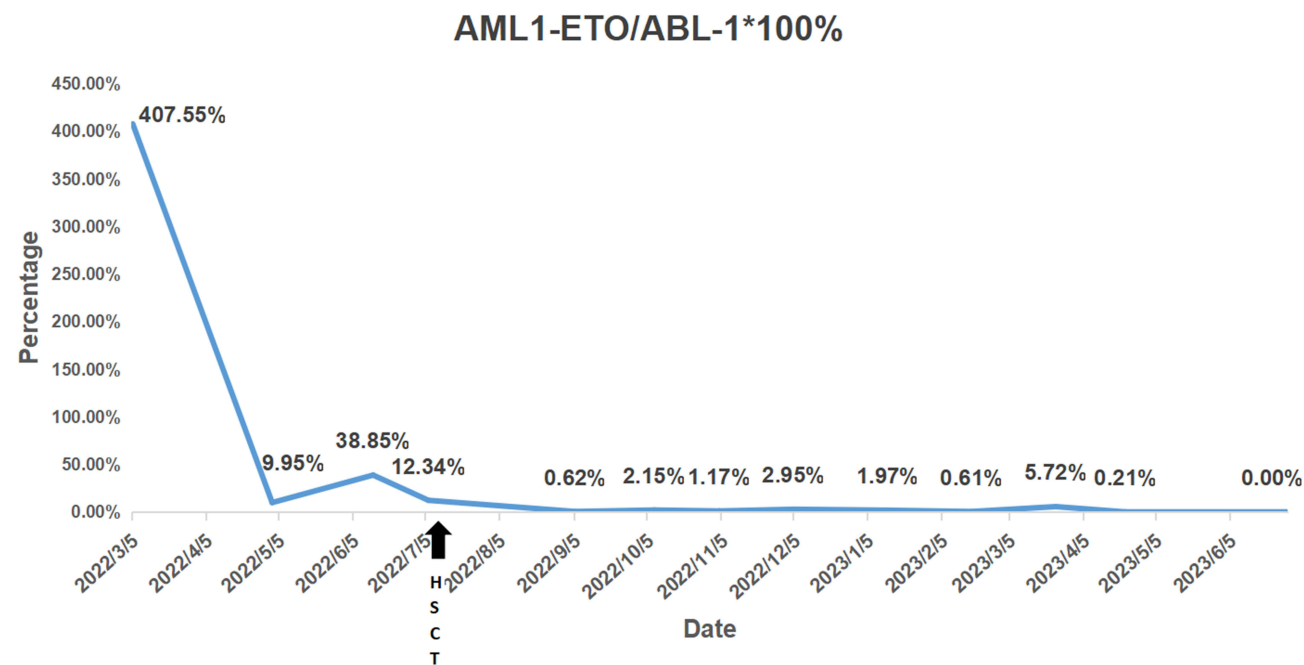


Figure 1 Minimal residual disease of AML1/ETO expression by quantitative RT-PCR assays. The expression level of fusion gene decreased from 407.55% at diagnosis to 0.00% (MRD negative) 19 months after allo-HSCT (cured).

donor was found in the China Bone Marrow Donor Registry for allogeneic-HSCT (allo-HSCT), and the patient underwent conditioning regimen with BUCY (Busulfan-Cyclophosphamide). On Day -5, the patient developed febrile neutropenia during the anti-thymocyte globulin (ATG) application. Laboratory tests revealed an elevated C-reactive protein (CRP) level of 81.45 mg/L (0–8 mg/L) and an increased procalcitonin (PCT) level of 11 µg/L (0–0.046 µg/L), which might also be observed after ATG administration.³ Considering the patient's neutropenic state, we could not rule out that the fever was caused by an infection, and he was treated with *meropenem* for 2 days but showed inadequate response. Subsequently, *tigecycline* was added to cover a wider range of bacterial sources. Finally, the patient's temperature, CRP and PCT returned to normal.

On the evening of stem cell infusion, the patient developed fever again, with a peak temperature of 40.4°C, accompanied by mild perianal pain. Blood culture and metagenomic next-generation sequencing (mNGS) of peripheral blood specimen were performed immediately. The blood culture results were negative, but mNGS indicated the presence of *P. aeruginosa* carrying *bla_{KPC-2}* gene. The antibiotics were adjusted to *polymyxin B* and *ceftazidime/avibactam*, considering the presence of KPC-producing *P. aeruginosa*. Additionally, hematopoietic growth factors and transfusion support were provided. The patient's experienced persistent agranulocytosis and the condition deteriorated with persistent fever ranging from 39–40°C, despite aforementioned antibiotic treatment (Figure 2A and B). The CRP levels progressively increased to over 200 mg/L, and PCT reached a peak of 26 µg/L on Day +3. The perianal pain became increasingly severe, accompanied by local redness and swelling. Moreover, the perianal skin started rupturing and showed signs of suppuration (pus formation) (Figure 3). Due to uncontrolled infection, the patient developed signs of septic shock.

Since there were no antibiotic susceptibility results to guide antibiotic regimen adjustments, we invited a colorectal surgeon to perform surgical debridement and provided aggressive life support treatment to stabilize the patient's condition. On Day +9 after transplantation, a CRPA strain was isolated from a blood culture specimen, with enzyme testing indicating the production of carbapenemase (KPC). CRPA was also identified in the subsequent cultures of perianal secretions. The susceptibility testing (Table 1) showed that the CRPA was resistant to multi-drug including *ceftazidime/avibactam* and *piperacillin-tazobactam*, but was sensitive to *polymyxin B*. Antimicrobial disk combined susceptibility tests (Figure 4A) indicated that when combined with *polymyxin B*, there was a slight zone of inhibition observed, suggesting some degree of effectiveness against the strain. Therefore, the antimicrobial treatment was adjusted to a combination of *polymyxin B*, based on the susceptibility results. Ultimately, with aggressive surgical debridement, effective antimicrobial therapy and successful neutrophil engraftment, the infection was brought under control.

To further elucidate the resistance mechanism of this KPC-producing *P. aeruginosa* which exhibited resistance to *ceftazidime/avibactam*, we performed whole-genome sequencing (WGS) (designated as E45). Results showed that the particular strain belonged to ST463 *P. aeruginosa*, and carried both the *bla_{AFM-1}* and *bla_{KPC-2}* genes (Figure 4B and C). Antimicrobial resistance genes *bla_{AFM-1}* was detected on the chromosome of E45 located within a conserved region of ISCR29 unit, and *bla_{KPC-2}* was detected on the plasmid located within a conserved region of IS26 unit. This result explained the reason for the extensive drug-resistance exhibited by this strain.

Discussion

P. aeruginosa is one of the most common nosocomial bacteria and often causes infections associated with blood, urinary tract, skin and soft tissue. Carbapenems have been the most efficient antibiotics for treating multidrug-resistant *P. aeruginosa*. However, with the extensive use of carbapenems, the incidence of CRPA has increased significantly. In recent years, CRPA have been identified as refractory pathogens because of their increased transmissibility and limited treatment options.^{2,4}

The main mechanisms of resistance to carbapenems in *P. aeruginosa* involve various factors, including the loss of OprD porin, overexpression of the effector pump and chromosomal β-lactamase AmpC, and acquisition of carbapenemases (such as KPC-2, VIM, NDM, and IMP) through mobile genetic elements like plasmids.^{5,6} KPC is a serine protease of the molecular class A and is frequently found in *K. pneumoniae*.⁷ KPC-producing *P. aeruginosa* (KPC-PA) was initially reported in 2007, and identified for the first time in Zhejiang in 2011.⁸ Reports showed that KPC-PA has a prevalence of around 40% in the clinical CRPA population in East China, and ST463 is the predominant KPC-producing clone.⁹ ST463 is the predominant strain in cases of bloodstream infection caused by CRPA, accounting for

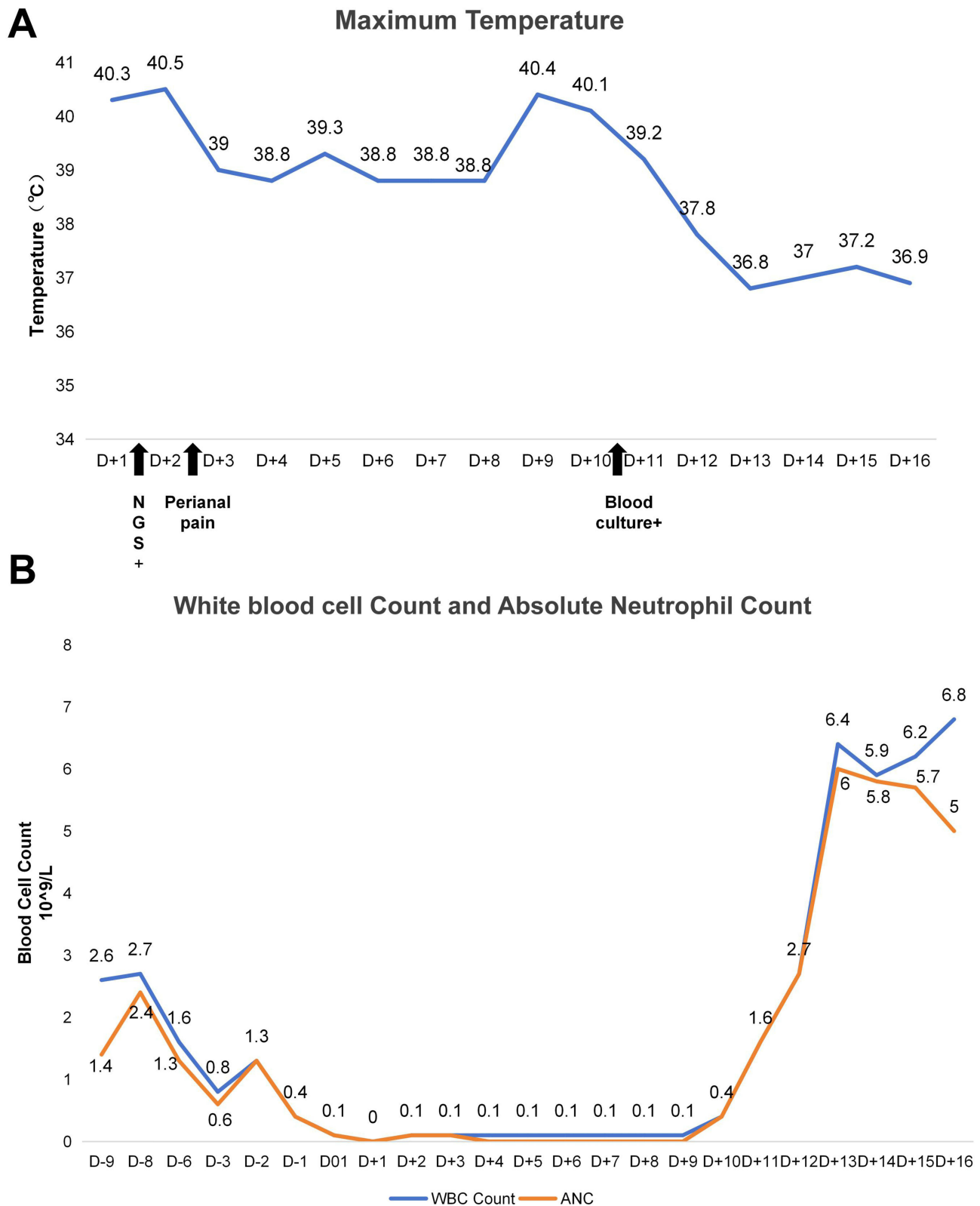


Figure 2 The condition of fever and agranulocytosis during stem cell engraftment. The patient experienced persistent fever (A) during the whole stage of agranulocytic, and the infection got gradually controlled since day +10 when neutrophil engrafted (B).

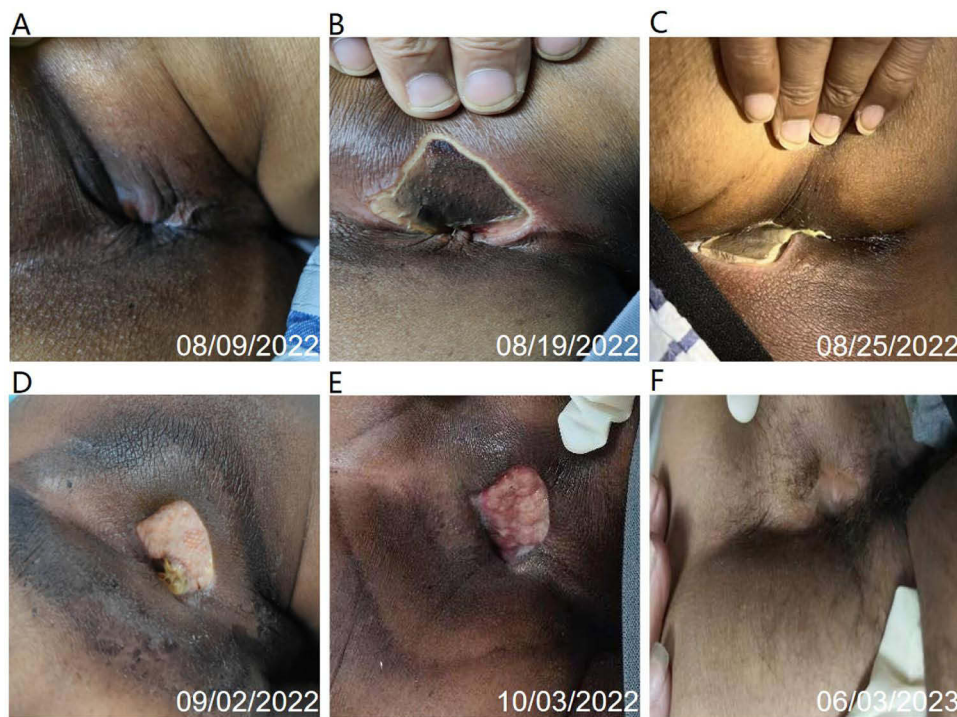

Figure 3 Changes of the infected perianal skin. (A) showed perianal purulent spot formed on day +6. (B) showed perianal abscess with local rupture on day +8. (C) showed giant perianal ulcer after infection control on day +21. (D), (E) and (F) showed the recovery of perianal ulcer.

48.0% of the cases. A study utilizing¹⁰ multivariate analysis identified three independent risk factors for a fatal outcome: KPC carriage (odds ratio [OR] 4.8; 95% CI 1.0–23.7; $P = 0.05$), Pitt bacteraemia score (OR 1.3; 95% CI 1.0–1.6; $P = 0.02$), and underlying hematological disease (OR 8.5; 95% CI 1.6–46.4; $P = 0.01$). Mortality associated with ST463 CRPA is significantly higher compared to non-ST463 CRPA.¹¹

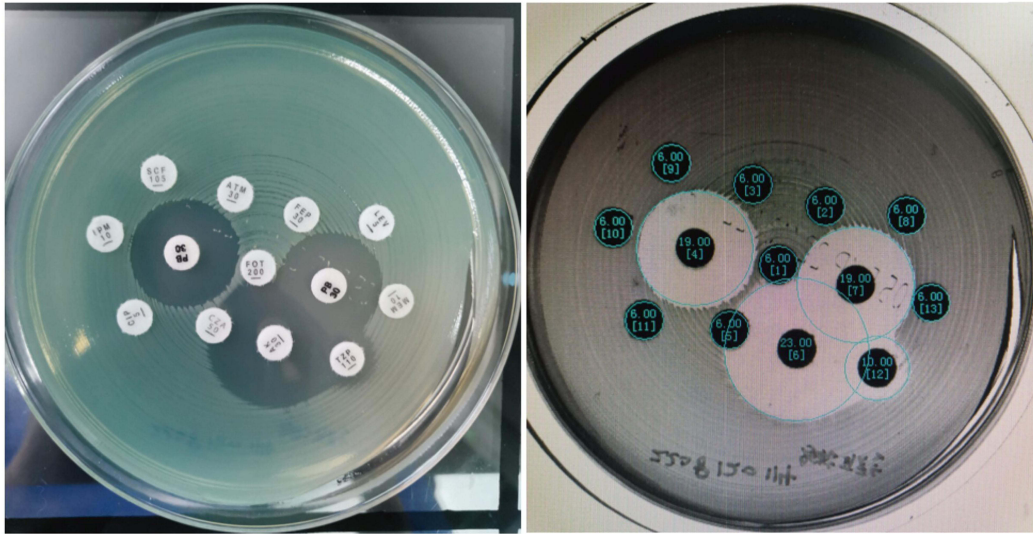
*Bla*_{AFM-1} CRPA strains are relatively rare. In 2018, a subclass B1b (Metallo- β -lactamase) (MBL) was recognized in an *Alcaligenes faecalis* strain and named AFM-1. Subsequently, AFM-1 has been found in *Comamonas testosteroni*, *Stenotrophomonas maltophilia* and *Bordetella trematum*. As a novel MBL, AFM alleles have not been widely disseminated in *P. aeruginosa* (Table 2).^{12–17} Piaopiao Zhang¹⁶ first reported the identification of *bla*_{AFM-1} in the chromosome of *P. aeruginosa*. In a study conducted by Xuefei Zhang,¹⁷ 605 consecutive non-duplicate *P. aeruginosa* isolates were examined, and only three *bla*_{AFM}-positive strains were identified. *Bla*_{AFM-1} is located within a conserved region of *groEL*- Δ *floR*-*bla*_{AFM-1}-*ble*- Δ *trpF*- Δ *ISCR27n2*- Δ *ISPme1* -*msrB2*- *msrA*- *yhgU*-*corA*.¹⁷ An ISCR27-like element, named ISCR29 by Li,¹² inserted into the chromosome of *P. aeruginosa* is a prerequisite for the insertion of the *bla*_{AFM-1}-carrying mobile unit, which would enable it to be intrinsically resistant to β -lactam antibiotics, including carbapenems without being subjected to selective pressures. These ISCR29-*bla*_{AFM} units are highly similar in most plasmids carrying *bla*_{AFM1-3}, indicating that ISCR29 plays a crucial role in the dissemination of *bla*_{AFM}. Studies also reported that the co-existence of KPC and MBL in *P. aeruginosa* can inactivate all β -lactams, making clinical treatment extremely difficult.

Table 1 Susceptibility to Antimicrobial Agents

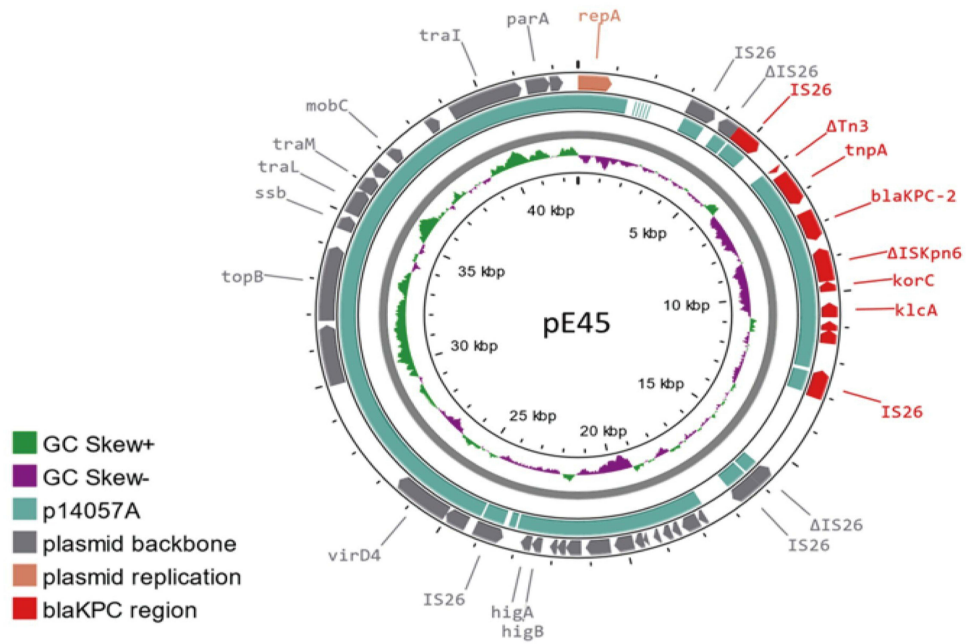
Strain	MICs(mg/L)												
	AZT	FEP	PTZ	CAZ	CZA	IPM	IR4	MEM	MV	LEV	CIP	POL	AK
E45	>128	>128	512/4	>128	>128/4	>128	>128/4	>128	>64/8	64	64	I	4

Abbreviations: MIC, minimum inhibitory concentration; AZT, aztreonam; FEP, cefepime; PTZ, piperacillin/tazobactam; CAZ, ceftazidime; CZA, ceftazidime/avibactam; IPM, imipenem; IR4, imipenem-relebactam; MEM, meropenem; MV, meropenem-vaborbactam; LEV, levofloxacin; CIP, ciprofloxacin; POL, polymyxin B; AK, amikacin.

A



B



C

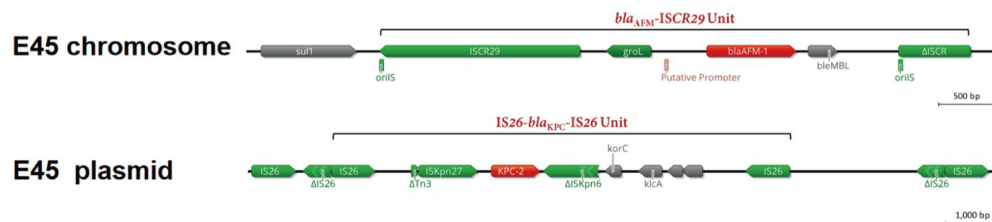


Figure 4 The evidence of pathogenic bacterium and whole-genome sequencing (WGS) analysis. **(A)** showed the antimicrobial disk combined susceptibility tests. **(B)** showed Plasmid ring map of pE45, and **(C)** presented chromosome and plasmid straight lines.

Table 2 Related Literatures of PA Strains Isolated Carrying blaAFM

CASE	Study	Clinical isolate	Sequence Type	Resistanc Egene	Location	GenBank Accession	Source	Hemopathy
1	Zhang X, et al 2021 ¹⁷	HS17-127	ST369	blaIMP-45, blaPER-1 blaOXA1 blaAFM-1	Shanghai, China	No. AYV97588.1	Sputum	Unreported
2	Zhang X, et al 2021 ¹⁷	HS18-89	ST463	blaIMP-45 blaAFM-1	Shanghai, China	No.AYV97588.1	Unreported	Unreported
3	Zhang X, et al 2021 ¹³	RJ19-28	ST708	blaIMP-45 blaOXA-1 blaAFM-1	Shanghai, China	N	Wound fluid	Unreported
4	Zhang P, et al 2022 ¹⁶	UI121	ST463	blaPDC-374 blaOXA-486 blaCARB-2 blaKPC-2 blaAFM-1	Zhejiang, China	No. MZ050803	Urinary	Acute lymphoblastic leukemia
5	Zhang P, et al 2022 ¹⁶	BI122	ST463	blaPDC-374 blaOXA-486 blaCARB-2, blaAFM-1,	Zhejiang, China	No.CP064394	Blood	Acute lymphoblastic leukemia
6	Fang Y, et al 2023 ¹⁴	PA30	ST463	blaIMP-45 blaAFM-1, blaKPC-2	Zhejiang, China	No.LT799039.1	Catheter	No
7	Chen M, et al 2022 ¹⁴	ARI9640,ARI9726, ARI9727,AR23664	ST671	blaAFM-2	Zhejiang, China	No.AYV97588	Rectal swab, Throat swab	Unreported
8	Li Y, et al 2022 ¹²	NDTH10366	ST463	blaAFM-2 blaKPC-2	Nanjing, China	N	Urinary	Unreported
9	Li Y, et al, 2022 ¹²	NDTH9845	ST463	blaCARB-2 blaAFM-2 blaKPC-2	Nanjing, China	N	Urinary	Unreported
10	Li Y, et al, 2022 ¹²	WTJH17	ST260	blaCARB-4 blaAFM-3	Wuhan,China	N	Blood	Unreported

Based on the succeeded treatment process of this patient, the following three points that contributed to his survival are summarized, to help clinicians in the future: a. patients with hematological disorders, especially those with granulocytopenia, have a low positive rate of blood culture after infection. Therefore, it is recommended to perform pathogenic mNGS detection immediately, and adjust antibiotics promptly after obtaining positive results, which will be beneficial for controlling infection; b. for severe infections caused by CRPA, early, adequate, and combination antibiotic therapy is recommended; c. if there is a local soft tissue infection, surgical debridement can be performed if conditions permit, combined with effective anti-infective treatment, which can achieve better results. In addition, we should also keep an eye on side effect of the long-term *polymyxin B* application. In our case, the patient developed acute renal failure on Day +24 ascribe to the combination of nephrotoxic medications (cyclosporine A, etc.), but fortunately recovered completely with a timely withdraw of *polymyxin B* and initiate dialysis, without any recurrence of infection. Nevertheless, in cases where patients exhibit renal impairment and are unable to tolerate *polymyxin B* therapy, a study¹⁸ has shown that *cefiderocol* exhibits promising efficacy against isolates harboring acquired carbapenemases or PDC variants. It may be considered for use in the treatment thus infections. Ultimately, the patient attained profound molecular remission following negative ETO fusion gene testing (0.00%) 19 months after HSCT.

Conclusion

This rare case highlights the importance of infection prevention in transplant recipients, and strengthening the monitoring of multidrug-resistant bacteria to reduce the incidence and mortality of infections. In conclusion, it is particularly

important to identify microbes with rare resistant genes and manage CRPA, especially in immunocompromised patients, using mNGS or WGS. Notably, for CRPA, *Polymyxin B* is one of the few remaining options for the treatment.

Data Sharing Statement

The data used and/or analyzed during the current study are available from the corresponding author (Dijiong Wu) upon a reasonable request.

Ethics Approval and Consent to Participate

This study was approved by the ethical committee of First Affiliated Hospital of Zhejiang Chinese Medical University.

Patient Consent for Publication

Written informed consent was obtained from the patient for publication of this case report and the images. Details of the case can be published without institutional approval.

Author Contributions

All authors made a significant contribution to the work reported, whether that is in the conception, study design, execution, acquisition of data, analysis and interpretation, or in all these areas; took part in drafting, revising or critically reviewing the article; gave final approval of the version to be published; have agreed on the journal to which the article has been submitted; and agree to be accountable for all aspects of the work.

Funding

This study was supported by Zhejiang Provincial Natural Science Foundation (NO.LY21H290003), Zhejiang Traditional Chinese Medicine Scientific Research Foundation (NO. 2020ZB085), Science and Technology Department of Zhejiang Research Foundation (NO.2019C03047), Project of Academic Inheritance Studio of Famous and Aged Chinese Medicine Experts in Zhejiang Province (NO.GZS2021022), Specific Program of Scientific Research of Zhejiang Chinese Medicine University for Affiliated Hospital (NO. 2023FSYYZZ04), Science and Technological Innovation Project for College Students in Zhejiang Province (Xinmiao Talent Plan) (NO. 2023R410003), Zhejiang Medical and Health Science and Technology Plan Project (NO. 2023RC193) and National Natural Science Foundation of China (NO.82304937).

Disclosure

The authors declare that they have no competing interests in this work.

References

1. Lister PD, Wolter DJ, Hanson ND. Antibacterial-resistant *Pseudomonas aeruginosa*: clinical impact and complex regulation of chromosomally encoded resistance mechanisms. *Clin Microbiol Rev.* 2009;22(4):582–610. doi:10.1128/CMR.00040-09
2. Buehrle DJ, Shields RK, Clarke LG, Potoski BA, Clancy CJ, Nguyen MH. Carbapenem-resistant *Pseudomonas aeruginosa* bacteremia: risk factors for mortality and microbiologic treatment failure. *Antimicrob Agents Chemother.* 2017;61(1). doi:10.1128/AAC.01243-16
3. Brodska H, Drabek T, Malickova K, et al. Marked increase of procalcitonin after the administration of anti-thymocyte globulin in patients before hematopoietic stem cell transplantation does not indicate sepsis: a prospective study. *Crit Care.* 2009;13(2):R37. doi:10.1186/cc7749
4. Meletis G. Carbapenem resistance: overview of the problem and future perspectives. *Ther Adv Infect Dis.* 2016;3(1):15–21. doi:10.1177/2049936115621709
5. Tu Y, Wang D, Zhu Y, et al. Emergence of a KPC-90 variant that confers resistance to ceftazidime-avibactam in an ST463 carbapenem-resistant *Pseudomonas aeruginosa* strain. *Microbiol Spectr.* 2022;10(1):e0186921. doi:10.1128/spectrum.01869-21
6. Gomez-Martinez J, Rocha-Gracia RDC, Bello-Lopez E, et al. A plasmid carrying bla(IMP-56) in *Pseudomonas aeruginosa* belonging to a novel resistance plasmid family. *Microorganisms.* 2022;10. doi:10.3390/microorganisms10091863
7. Qi Y, Wei Z, Ji S, Du X, Shen P, Yu Y. ST11, the dominant clone of KPC-producing *Klebsiella pneumoniae* in China. *J Antimicrob Chemother.* 2011;66:307–312. doi:10.1093/jac/dkq431
8. Hagemann JB, Pfennigwerth N, Gatermann SG, von Baum H, Essig A. KPC-2 carbapenemase-producing *Pseudomonas aeruginosa* reaching Germany. *J Antimicrob Chemother.* 2018;73(7):1812–1814. doi:10.1093/jac/dky105
9. Hu Y, Liu C, Wang Q, et al. Emergence and expansion of a carbapenem-resistant *Pseudomonas aeruginosa* clone are associated with plasmid-borne bla KPC-2 and virulence-related genes. *mSystems.* 2021;6(3). doi:10.1128/mSystems.00154-21

10. Hu H, Zhang Y, Zhang P, et al. Bloodstream infections caused by *Klebsiella pneumoniae* carbapenemase-producing p. aeruginosa sequence type 463, associated with high mortality rates in China: a retrospective cohort study. *Front Cell Infect Microbiol.* 2021;11:756782. doi:10.3389/fcimb.2021.756782
11. Zhang X, Tang M, Xu Y, et al. Characteristics of rare ST463 carbapenem-resistant *Pseudomonas aeruginosa* clinical isolates from blood. *J Glob Antimicrob Resist.* 2023;32:122–130. doi:10.1016/j.jgar.2023.01.011
12. Li Y, Zhu Y, Zhou W, et al. *Alcaligenes faecalis* metallo-beta-lactamase in extensively drug-resistant *Pseudomonas aeruginosa* isolates. *Clin Microbiol Infect.* 2022;28(6):880 e1–880 e8. doi:10.1016/j.cmi.2021.11.012
13. Zhang X, Wang L, Li D, et al. An IncP-2 plasmid sublineage associated with dissemination of bla IMP-45 among carbapenem-resistant *Pseudomonas aeruginosa*. *Emerg Microbes Infect.* 2021;10(1):442–449. doi:10.1080/22221751.2021.1894903
14. Fang Y, Wang N, Wu Z, et al. An XDR *Pseudomonas aeruginosa* ST463 strain with an IncP-2 plasmid containing a novel transposon Tn 6485f encoding bla IMP-45 and bla AFM-1 and a second plasmid with two copies of bla KPC-2. *Microbiol Spectr.* 2023;11(1):e0446222. doi:10.1128/spectrum.04462-22
15. Chen M, Cai H, Li Y, et al. Plasmid-borne AFM alleles in *Pseudomonas aeruginosa* clinical isolates from China. *Microbiol Spectr.* 2022;10(5):e0203522. doi:10.1128/spectrum.02035-22
16. Zhang P, Wang J, Shi W, et al. In vivo acquisition of bla(KPC-2) with low biological cost in bla(AFM-1)-harboring ST463 hypervirulent *Pseudomonas aeruginosa* from a patient with hematologic malignancy. *J Glob Antimicrob Resist.* 2022;31:189–195. doi:10.1016/j.jgar.2022.09.004
17. Zhang X, Wang L, Li D, Wang C, Guo Q, Wang M. Characterization of the novel plasmid-encoded MBL gene bla AFM-1, integrated into a bla IMP-45-bearing transposon Tn 6485e in a carbapenem-resistant *Pseudomonas aeruginosa* clinical isolate. *J Antimicrob Chemother.* 2021;77(1):83–88. doi:10.1093/jac/dkab342
18. Satlin MJ, Simner PJ, Slover CM, Yamano Y, Nagata TD, Portsmouth S. Cefiderocol treatment for patients with multidrug- and carbapenem-resistant *Pseudomonas aeruginosa* infections in the compassionate use program. *Antimicrob Agents Chemother.* 2023;67(7):e0019423. doi:10.1128/aac.00194-23

Infection and Drug Resistance

Dovepress

Publish your work in this journal

Infection and Drug Resistance is an international, peer-reviewed open-access journal that focuses on the optimal treatment of infection (bacterial, fungal and viral) and the development and institution of preventive strategies to minimize the development and spread of resistance. The journal is specifically concerned with the epidemiology of antibiotic resistance and the mechanisms of resistance development and diffusion in both hospitals and the community. The manuscript management system is completely online and includes a very quick and fair peer-review system, which is all easy to use. Visit <http://www.dovepress.com/testimonials.php> to read real quotes from published authors.

Submit your manuscript here: <https://www.dovepress.com/infection-and-drug-resistance-journal>