




# Pseudohypoparathyroidism Type IB with Subclinical Hypothyroidism: a Pedigree Investigation and Literature Review

Jie Liu , Lijuan Lu, Yu Wei , Yu Li, Qiong Wang, Lei Yu, Langen Zhuang, Guoxi Jin , Xiaoyan Pei

Department of Endocrinology, the First Affiliated Hospital of Bengbu Medical University, Bengbu, Anhui Province, People's Republic of China

Correspondence: Guoxi Jin; Xiaoyan Pei, Department of Endocrinology, the First Affiliated Hospital of Bengbu Medical University, No. 287 Changhuai Road, Bengbu, Anhui Province, 233000, People's Republic of China, Email [jyzjz1999@163.com](mailto:jyzjz1999@163.com); [245899985@qq.com](mailto:245899985@qq.com)

**Abstract:** Pseudohypoparathyroidism (PHP) is a rare genetic disease characterized by hypocalcemia, hyperphosphatemia, and elevated parathyroid hormone (PTH) in serum. Here, we report a case of a patient with pseudohypoparathyroidism type IB (PHPIB) and subclinical hypothyroidism, analyze the clinical and genetic data of his family members, review the relevant literature, and classify and discuss the pathogenesis and clinical characteristics of each subtype. Finally, we discuss the treatment approach to improve clinicians' understanding of the disease.

**Keywords:** hypocalcemia, parathyroid hormone resistance, GNAS, STX16, molecular genetic mechanism

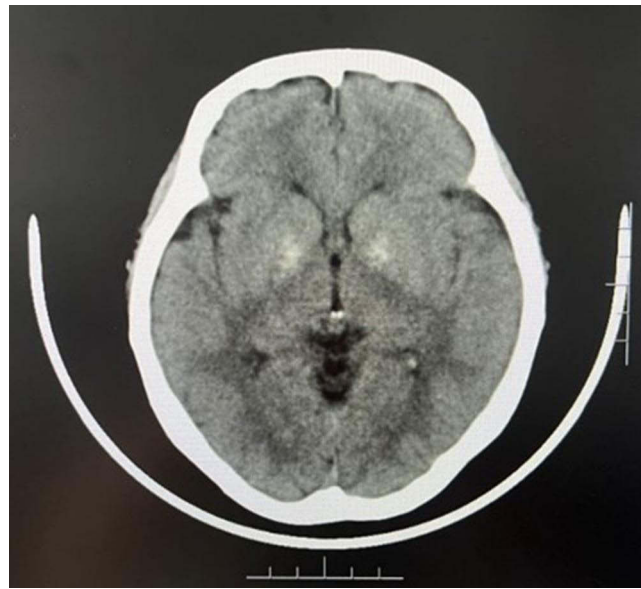## Introduction

Pseudohypoparathyroidism (PHP) is a rare hereditary endocrine disease with high heterogeneity. The molecular genetic mechanism of PHP is related to an inactivation mutation or an epigenetic modification of the GNAS gene, which encodes stimulating G protein  $\alpha$  subunit ( $G\alpha$ ).<sup>1</sup> The change in the GNAS gene leads to a decrease in  $G\alpha$  activity, so it cannot activate the downstream adenylate cyclase system to produce the second messenger cyclic adenosine monophosphate (cAMP). Finally, the inhibition of the  $G\alpha$ /cAMP/protein kinase A (PKA) signaling pathway produces a series of pathological reactions.<sup>2</sup> The first symptoms are usually those of tetany due to low calcium, and some patients have epileptic seizures. In other cases, the first symptoms are skin heterotopic ossification, congenital hypothyroidism, or dwarfism. The main feature of the disease is the resistance of target organs (bone and kidney) to parathyroid hormone (PTH), which results in hypocalcemia, hyperphosphatemia, and elevated serum PTH concentration. Other clinical manifestations include ectopic calcification (especially in the basal ganglia and lens), ectopic ossification (most often in the dermis and subcutaneous fat), and Albright hereditary osteodystrophy (AHO). In some cases, resistance to other hormones such as thyroid-stimulating hormone (TSH), growth hormone-releasing hormone (GHRH), and follicle-stimulating hormone (FSH)/luteinizing hormone (LH) may also occur.<sup>3,4</sup>

## Case Presentation

### Clinical Data

A 32-year-old woman was admitted to the neurology outpatient clinic of our hospital for “dizziness and headache for 2 weeks.” She did not experience nausea and vomiting. Head computed tomography (CT) showed bilateral symmetrical high-density shadows in the basal ganglia that resembled those in metabolic lesions (Figure 1). The concentrations of biochemical parameters were as follows: total calcium, 2.18 (normal range, 2.11–2.52) mmol/L; inorganic phosphorus, 1.40 (normal range, 0.85–1.51) mmol/L; PTH, 231 (normal range, 12–88) pg/mL. She was then transferred to the endocrinology outpatient clinic and admitted to the hospital. Her medical history revealed that she had seen a doctor in



**Figure 1** Head CT.

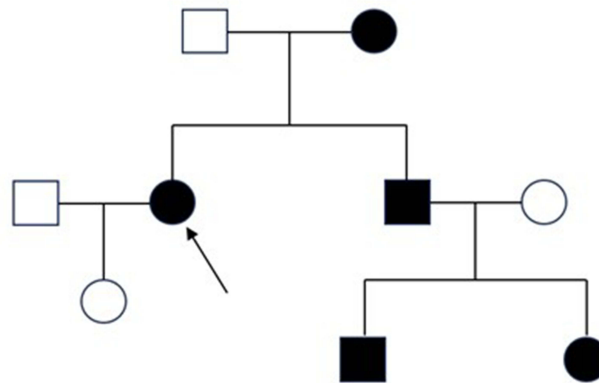
another hospital 4 years ago because of facial and limb convulsions. At that time, the following parameters were measured: calcium, 1.43 (2.11–2.52) mmol/L; PTH, 439.70 (12–88) pg/mL; thyroxine, 84.70 (55.34–160.88) nmol/L; TSH, 5.96 (0.40–4.34) mIU/L; on that basis, the patient was diagnosed with “hypocalcemia” and “subclinical hypothyroidism.” She was discharged with symptomatic treatment, including supplementation of calcium, vitamin D, and thyroid hormone. She usually took calcium tablets (details unknown) and did not undergo follow-up examinations. She denied any history of chronic disease and surgery but reported that her brother had a history of hypocalcemia. There was no genetic history in the family. Physical examination revealed the following: blood pressure, 100/75 mm Hg; height, 160 cm; weight, 55.5 kg; BMI, 21.7 kg/m<sup>2</sup>; clear mind, normal development, good nutrition; no abnormalities of the heart, lungs, and abdomen; no obvious abnormalities of the spine and limbs; Chvostek sign, Trousseau sign, and peroneal nerve reflex were all negative.

## Supplementary Examination

Related examination on the first day of hospitalization: total calcium, 1.96 (2.11–2.52) mmol/L; ionized calcium 1.05 (1.10–1.34) mmol/L; inorganic phosphorus 1.25 (0.85–1.51) mmol/L; 25-hydroxyvitamin D, 19.91 (>20) ng/mL; urinary calcium, 2.91 (2.50–7.50) mmol/L; urinary phosphorus, 7.44 (32.3–38.4) mmol/L; free thyroxine 17.53 (10.43–24.32) pmol/L; TSH, 6.31 (0.40–4.34) mIU/L. There were no obvious abnormalities in blood routine, urine routine, liver and kidney function parameters, bicarbonate, serum potassium, alkaline phosphatase, calcitonin, corticotropin, cortisol, thyroid hormone, thyroid autoantibody, growth hormone, and sex hormone concentrations. Bone mineral density (BMD) was lower than that of the same age group. No obvious abnormalities were found in head and neck computed tomograph angiography, parathyroid emission computed tomography (ECT), color Doppler ultrasound of both kidneys and renal vessels, and radiographs of tibia, fibula, ulna, and radius.

## Genetic Testing

Based on the clinical manifestations and laboratory results, the diagnosis of PHP was considered. After obtaining informed consent, genetic testing of the patient and her family was completed. The full exome of genomic DNA was captured and sequenced by KingMed Diagnostics Co., Ltd. The result revealed a large copy number variation in the genomic DNA of the patient and her mother, whereas the gene detection results of the patient’s father, spouse, and daughter were not abnormal. There were about 2.1 kb copy number deletions in the chromosome 20q13.32 region (chr20:57244296–57246403) in the genomic DNA of the patient and her mother. The copy number deletion variation



**Figure 2** The family genetic map (the arrow points to the patient).

region mainly contains exon 5–7 of the STX16 gene and its adjacent intron. STX16 gene mutation is the main pathogenesis of familial PPHIB, which causes resistance to PTH. Further genetic detection was performed on the patient's brother (whose wife refused to perform genetic testing), nephew, and niece. The result revealed that the copy number of this region was heterozygous deletion in all three individuals. The patient's brother also showed hypocalcemia, hyperphosphatemia and increased PTH, and the others refused to take the examination. The patient's family genetic map is shown in [Figure 2](#), and the mode of inheritance is autosomal dominant.

## Diagnosis and Treatment

Considering all data, the diagnosis of familial PPHIB with subclinical hypothyroidism was made. The therapy included calcitriol (0.5 µg once a day), calcium carbonate D3 (1.2 g once a day), and levothyroxine sodium (50 µg once a day). After discharge, the patient was followed up regularly in the outpatient clinic, and her examination results are shown in [Table 1](#).

**Table 1** Laboratory Examination Results of the Patient Within Half a Year After Discharge

Variable	1 Month Later	3 Months Later	5 Months Later	Reference Value
Ca (mmol/L)	2.16	2.18	2.08	2.11–2.52
P (mmol/L)	1.51	0.79	1.56	0.85–1.51
K (mmol/L)	3.71	3.58	3.83	3.50–5.30
Mg (mmol/L)	0.86	0.88	0.70	0.75–1.02
PTH (pg/mL)	199.00	145.00	93.10	11.00–67.00
FT3 (pmol/L)	–	–	4.49	2.77–6.50
FT4 (pmol/L)	–	–	15.01	10.43–24.32
TSH (mIU/L)	–	–	4.11	0.40–4.43

**Abbreviations:** Ca, calcium; P, phosphorus; K, potassium; Mg, magnesium; PTH, parathyroid hormone; FT3, free triiodothyronine; FT4, free thyroxine; TSH, thyroid-stimulating hormone.

## Discussion

### Diagnostic Typing

Our patient had resistance to PTH, as evidenced by the decreased calcium and increased PTH in serum and decreased urinary phosphorus, increased TSH, normal free thyroxine, decreased BMD, and no AHO signs. PHP can be divided into type I and type II, PHPI can be divided into three subtypes, namely, PHPIA, PHPIB, and PHPIC. There are also pseudopseudohypoparathyroidism (PPHP) and progressive osseous heteroplasia (POH). PHPIB shows resistance to PTH, sometimes also to TSH, but rarely to other hormones. There are no signs of AHO, and the activity of  $G\alpha$  is normal. In addition, due to the increased PTH levels, at least part of the bone tissue of patients with PHPIB is destroyed to some extent, which can manifest as osteopenia, osteosclerosis, and fibrocystic osteitis, whereas individuals with PHPIA show higher BMD.<sup>5,6</sup> Our patient was in accordance with the clinical manifestations of PHPIB. PHPIB can be further divided into familial type (with autosomal dominant inheritance) and sporadic type (without family history). The pathogenesis is related to an epigenetic modification of the GNAS gene, that is, abnormal methylation in differentially methylated region (DMR).<sup>7</sup> At 220 kb upstream of GNAS, there is a remotely imprinted gene, STX16 gene, which encodes synaptic fusion protein 16, which can maintain the DMR methylation of the GNAS gene and affect the expression of  $G\alpha$ .<sup>8</sup> Familial PHPIB is often caused by a deletion of the STX16 or NESP55 loci on maternal alleles.<sup>9</sup> For example, the deletion of large 3.0-kb fragments in exons 4–6 of the STX16 gene leads to the deletion of A/B-DMR methylation in the maternal GNAS gene, which is usually the only molecular defect of familial PHPIB.<sup>8,10</sup> Our patient's gene detection suggested that exons 5–7 of the STX16 gene were deleted, and the deletion mutation originated from the mother, so the diagnosis of familial PHPIB with subclinical hypothyroidism was made. The pathogenesis of sporadic type involves extensive abnormalities in DMR methylation. Considering that sporadic type generally has no gene base sequence change and no family history, it is considered that it is not passed on to future generations.

PHPIA shows resistance to multiple hormones, signs of AHO, and decreased activity of  $G\alpha$ . The pathogenesis involves a maternal inactivation mutation of exons 1–13 of the GNAS gene.<sup>11</sup> In most organs or tissues, even if the maternal GNAS gene is mutated, there is about 50%  $G\alpha$  activity because alleles of both parents can be expressed. However, maternal alleles are specifically expressed in proximal renal tubules, thyroid gland, gonads, and pituitary gland. That means that when the abovementioned mutation occurs, these tissues become resistant to PTH, TSH, GHRH, LH/FSH, and other hormones, because the decreased activity or expression of  $G\alpha$  leads to the impairment of  $G\alpha$ /cAMP/PKA signaling pathway.<sup>7</sup> The insufficient activity of  $G\alpha$  also leads to early closure of tubular epiphysis and growth plate, resulting in signs of AHO, such as short stature, round face, short metacarpal (finger/toe) bones, and heterotopic ossification. The expression of  $G\alpha$  is decreased in the brain and adipose tissue, which leads to mild cognitive impairment and early-onset obesity, which are all classified as AHO signs.<sup>2,12</sup> AHO signs and multiple hormone resistance exist in PHPIC, but the activity of  $G\alpha$  is normal in vitro. The pathogenesis is unclear, and it is speculated that a maternal GNAS gene mutation selectively affects the G-protein-coupled signaling pathway. These mutations are usually concentrated in the  $\alpha 5$ -helix at the carbon terminal of  $G\alpha$ , which is highly conserved among species and is an important region for mediating receptor coupling. Multiple hormone resistance and AHO signs in PHPIC patients may occur because of the receptor coupling defect.<sup>13</sup> PPHP and POH are caused by inactivation mutations in the GNAS gene in the paternal line.<sup>14</sup> Because the paternal GNAS gene is not expressed in proximal renal tubules and the target tissues of other hormones, none of these patients show hormone resistance. Patients with PPHP display AHO signs and decreased activity of  $G\alpha$ , but some patients have mild PTH resistance and TSH resistance. POH patients show progressive heterotopic ossification that can reach connective tissue and skeletal muscle, which is more serious than AHO signs. PHPII is characterized by PTH resistance and lack of AHO signs, but bone deformities may occur due to vitamin D deficiency. PHPII is very rare in clinical practice, and it carries no mutations in the GNAS gene. The pathogenesis may be related to an abnormality in the cAMP downstream signaling pathway. It has been shown that PTH can normally bind to its receptor to produce cAMP, but the subsequent intracellular defects hinder the action of cAMP. Secondary factors such as vitamin D deficiency can also be involved in the pathogenesis, but the specific mechanism needs to be further studied.

The clinical manifestations of the subtypes overlap, so it is difficult to distinguish between the subtypes based on the clinical features alone. Thus, considering the molecular mechanism of PHP, molecular genetic detection is the gold standard for the diagnosis and classification of the disease.

## Treatment

When convulsions occur because of acute hypocalcemia, the most important thing is to relieve symptoms and prevent laryngospasm. Calcium should be supplemented by intravenous drip immediately. During infusion, electrolytes should be checked regularly, and serum calcium should be maintained around 2.0 mmol/L. Patients with chronic hypocalcemia need long-term oral calcium and vitamin D supplementation. It is recommended to supplement calcium 500–1000 mg each time, 2–3 times a day. Calcium carbonate has a high content of elemental calcium; however, it needs to be taken with meals and it easily produces adverse reactions such as constipation. Calcium citrate has a low content of elemental calcium, but can be taken at any time and has fewer adverse reactions, which is why it is more suitable for patients who are taking proton pump inhibitors. The following active vitamin D analogues should be taken: calcitriol 0.25–2.0 µg/day, alpha-calcitriol 0.5–3.0 µg/day, dihydrosterol 0.2–1.0 mg/day. Vitamin D level needs to be maintained at the normal range, and serum calcium is generally maintained at normal or low levels (2.00–2.25 mmol/L) to avoid kidney stones or renal insufficiency caused by high urinary calcium.<sup>15,16</sup> Patients with PHP show disturbance of urinary phosphorus excretion. Phosphorus-rich foods such as milk, meat, and bean products should be avoided, and serum phosphorus should be maintained at a normal or slightly higher level. If present, hypomagnesemia should be corrected in time to improve the sensitivity of target organs to PTH. It is not recommended to use PTH in patients with PHP because serum PTH is already at a high level. It is difficult that exogenous PTH produces beneficial effects due to PTH resistance *in vivo*. PTH should be controlled at a slightly higher level, because distal renal tubules still respond to PTH and can reabsorb calcium. Slightly higher levels of PTH can reduce the risk of high urinary calcium. If PTH is too high, it causes bone destruction.<sup>4</sup> In addition, patients with PHP may have multiple hormone resistance, and corresponding hormones should be supplemented to reduce the incidence of complications.<sup>17</sup>

Our patient showed chronic calcium deficiency, normal serum phosphorus, and normal serum magnesium, so she was mainly treated with oral calcium and active vitamin D; because of subclinical hypothyroidism, thyroid hormone was also supplemented. PTH had to be reduced to a reasonable level to avoid further bone damage. During the follow-up, her serum magnesium level decreased, and the patient was treated with magnesium supplementation in time, and the level of PTH decreased gradually.

## Conclusion

The molecular mechanism of PHP is complex, and its clinical characteristics are different. The presence of hand and foot convulsions as the main manifestation in patients should call for the detection of electrolytes and PTH levels. If necessary, a head CT can be performed, and the body should be carefully examined to determine whether there are signs of AHO. For patients with a high suspicion of PHP, it is recommended to improve genetic testing to make a clear diagnosis in the early stage, to guide treatment and reduce mortality.

## Consent for Publication

The informed consent for publication was obtained from the patient. The hospital did not require ethical clearance for the case report.

## Acknowledgments

We thank LetPub for its linguistic assistance during the preparation of this manuscript.

## Funding

Key Program of Nature Science Foundation of Anhui Education Committee (grant no. 2022AH051524); Key Project of Natural Science Foundation of Bengbu Medical College (grant no. 2021byzd043); Postgraduate Scientific Research and Innovation Program of Bengbu Medical College in 2023 (grant no. Byycx23102).

## Disclosure

The authors report no conflicts of interest in this work.

## References

1. Jüppner H. Molecular Definition of Pseudohypoparathyroidism Variants. *J Clin Endocrinol Metab.* 2021;106(6):1541–1552. doi:10.1210/clinem/dgab060
2. Mantovani G, Spada A, Elli FM. Pseudohypoparathyroidism and Gs $\alpha$ -cAMP-linked disorders: current view and open issues. *Nat Rev Endocrinol.* 2016;12(6):347–356. doi:10.1038/nrendo.2016.52
3. Linglart A, Levine MA, Jüppner H. Pseudohypoparathyroidism. *Endocrinol Metab Clin North Am.* 2018;47(4):865–888. doi:10.1016/j.ecl.2018.07.011
4. Mantovani G, Bastepe M, Monk D, et al. Diagnosis and management of pseudohypoparathyroidism and related disorders: first international Consensus Statement. *Nat Rev Endocrinol.* 2018;14(8):476–500. doi:10.1038/s41574-018-0042-0
5. Wang Y, Lu C, Chen X. Variable Bone Phenotypes in Patients with Pseudohypoparathyroidism. *Curr Osteoporos Rep.* 2023;21(3):311–321. doi:10.1007/s11914-023-00787-6
6. Chu X, Zhu Y, Wang O, et al. Bone Mineral Density and Its Serial Changes Are Associated With PTH Levels in Pseudohypoparathyroidism Type 1B Patients. *J Bone Miner Res.* 2018;33(4):743–752. doi:10.1002/jbmr.3360
7. Turan S, Bastepe M. GNAS Spectrum of Disorders. *Curr Osteoporos Rep.* 2015;13(3):146–158. doi:10.1007/s11914-015-0268-x
8. Bastepe M, Fröhlich LF, Hendy GN, et al. Autosomal dominant pseudohypoparathyroidism type 1b is associated with a heterozygous microdeletion that likely disrupts a putative imprinting control element of GNAS. *J Clin Invest.* 2003;112(8):1255–1263. doi:10.1172/JCI19159
9. Iwasaki Y, Aksu C, Reyes M, Ay B, He Q, Bastepe M. The long-range interaction between two GNAS imprinting control regions delineates pseudohypoparathyroidism type 1B pathogenesis. *J Clin Invest.* 2023;133(8):e167953. doi:10.1172/JCI167953
10. Kiuchi Z, Reyes M, Hanna P, et al. Progression of PTH Resistance in Autosomal Dominant Pseudohypoparathyroidism Type 1b Due to Maternal STX16 Deletions. *J Clin Endocrinol Metab.* 2022;107(2):e681–e687. doi:10.1210/clinem/dgab660
11. Lemos MC, Thakker RV. GNAS mutations in Pseudohypoparathyroidism type 1a and related disorders. *Hum Mutat.* 2015;36(1):11–19. doi:10.1002/humu.22696
12. Hanna P, Grybek V, Perez de Nanclares G, et al. Genetic and Epigenetic Defects at the GNAS Locus Lead to Distinct Patterns of Skeletal Growth but Similar Early-Onset Obesity. *J Bone Miner Res.* 2018;33(8):1480–1488. doi:10.1002/jbmr.3450
13. Thiele S, de Sanctis L, Werner R, et al. Functional characterization of GNAS mutations found in patients with pseudohypoparathyroidism type 1c defines a new subgroup of pseudohypoparathyroidism affecting selectively Gsa-receptor interaction. *Hum Mutat.* 2011;32(6):653–660. doi:10.1002/humu.21489
14. Richard N, Molin A, Coudray N, Rault-Guillaume P, Jüppner H, Kottler ML. Paternal GNAS Mutations Lead to Severe Intrauterine Growth Retardation (IUGR) and Provide Evidence for a Role of XLas in Fetal Development. *J Clin Endocrinol Metab.* 2013;98(9):E1549–E1556. doi:10.1210/jc.2013-1667
15. Osteoporosis and Bone Mineral Diseases Branch of Chinese Medical Association, Metabolic Osteopathy Group, Endocrine Branch of Chinese Medical Association. Guidelines for clinical diagnosis and treatment of hypoparathyroidism. *Chine J Osteoporosis Bone Mineral Dis.* 2018;11(4):323–338.
16. Mantovani G, Bastepe M, Monk D, et al. Recommendations for Diagnosis and Treatment of Pseudohypoparathyroidism and Related Disorders: an Updated Practical Tool for Physicians and Patients. *Horm Res Paediatr.* 2020;93(3):182–196. doi:10.1159/000508985
17. Germain-Lee EL. Management of pseudohypoparathyroidism. *Curr Opin Pediatr.* 2019;31(4):537–549. doi:10.1097/MOP.0000000000000783

Diabetes, Metabolic Syndrome and Obesity

Dovepress

Publish your work in this journal

Diabetes, Metabolic Syndrome and Obesity is an international, peer-reviewed open-access journal committed to the rapid publication of the latest laboratory and clinical findings in the fields of diabetes, metabolic syndrome and obesity research. Original research, review, case reports, hypothesis formation, expert opinion and commentaries are all considered for publication. The manuscript management system is completely online and includes a very quick and fair peer-review system, which is all easy to use. Visit <http://www.dovepress.com/testimonials.php> to read real quotes from published authors.

Submit your manuscript here: <https://www.dovepress.com/diabetes-metabolic-syndrome-and-obesity-journal>