

Bilateral Sutureless Application of Human Dehydrated Amniotic Membrane with a Specialised Bandage Contact Lens for Moderate-to-Severe Dry Eye Disease: A Prospective Study with 1-Month Follow-Up

Sònia Travé-Huarte , James S Wolffsohn 

Optometry and Vision Science Research Group, College of Health and Life Sciences, Aston University, Birmingham, UK

Correspondence: Sònia Travé-Huarte, School of Optometry, Aston University, Birmingham, UK, Tel +44 121 2044400, Email s.trave-huarte@aston.ac.uk

Purpose: To assess changes in symptoms and ocular surface signs following a bilateral sutureless treatment of dehydrated amniotic membrane (dAM) under a specialised bandage contact lens (sBCL) in patients with moderate-to-severe dry eye disease (DED).

Patients and Methods: In this prospective pre-post interventional study, 35 patients diagnosed with moderate-to-severe DED, with an Ocular Surface Disease Index (OSDI) score >30 on current treatment, were enrolled. Assessments were conducted at baseline (day -30), after 30 days run-in with no additional treatment (day 0 – control), and 30 days post sBCL+dAM treatment (day 30 – treatment). Intervention involved two successive bilateral 4-5 day sutureless applications of dAM (17mm diameter, with a 6 mm central aperture, Omnigen® VIEW) under an 18mm sBCL (OmniLenz®). Symptomatology and ocular signs were measured using OSDI, Dry Eye Questionnaire-5 (DEQ-5), Symptom Assessment in Dry Eye (SANDE), and other ocular surface health indicators including non-invasive breakup time, corneal and conjunctival staining, and lid wiper epitheliopathy length and width (LWE).

Results: While symptomatology remained stable during the 30-day no-treatment run-in, 1-month post-dAM treatment, there was a significant reduction in OSDI scores (from 55.8 to 32.3, $p<0.001$), DEQ-5 (from 14.6 to 10.0, $p<0.001$), SANDE frequency (from 65.2 to 43.6, $p<0.001$), and SANDE severity (from 59.8 to 41.1, $p<0.001$). Additionally, there was a notable decrease in the width of LWE staining, from grade 2 (50–75% of the lid wiper) to grade 1 (25–50% of the lid wiper) ($p=0.011$).

Conclusion: A bilateral 8–10-day treatment duration with dAM applied with sBCL demonstrated a 31 to 42% improvement in symptomatology and a decrease in ocular surface signs of mechanical stress. This innovative bilateral treatment approach offers a promising treatment modality for patients with refractory moderate-to-severe DED.

Keywords: dry eye disease, amniotic membrane, bandage contact lens

Introduction

Dry eye disease (DED), a multifactorial disease of the ocular surface, is characterised by a disrupted tear film homeostasis leading to a range of symptoms such as discomfort, visual disturbance, and tear film instability. This instability, accompanied by hyperosmolarity, ocular surface inflammation and damage, and neurosensory abnormalities play pivotal roles in the aetiology of DED.¹

Recent epidemiological data indicate a significant increase in the prevalence of DED over the past decade. Previously affecting 5–35% of individuals aged 50 or older,² current research now suggests a prevalence rate as high as 5–50% in the general population.³ This significant rise, attributed to factors including ageing populations, environmental changes, and increased screen time, underscores DED's escalating status as a public health challenge. The annual healthcare cost

of managing DED in the U.S. alone is estimated at \$3.84 billion, with wider societal cost reaching \$55.4 billion,^{4,5} emphasising the need for more effective and accessible treatment strategies.

The pathophysiology of DED involves a detrimental cycle where tear hyperosmolarity leads to ocular surface epithelial cell damage, triggering inflammatory responses that exacerbate tear film instability, ocular surface damage and symptomatology.^{6,7} This cascade is compounded by goblet cell loss^{8,9} and epithelial cell apoptosis,^{10,11} which impair glycocalyx mucin expression essential for tear film stability. Clinically, this damage manifests as punctate epitheliopathy and lid wiper epitheliopathy (LWE) from mechanical stress between the lid margin and the ocular surface, further worsening symptoms.^{6,7} If untreated, DED can lead to increased corneal nerve stimulation, causing discomfort, increased blinking, and a possible compensatory increase in lacrimal tear film stimulation and secretion.

The Tear Film and Ocular Surface Society (TFOS DEWS II) outlines a stepwise management approach for treating DED ranging from basic education and environmental changes (Step 1) to advanced biologics and surgical interventions (Step 4).¹² Amniotic membrane (AM) transplantation has emerged as a promising step 4 (biologics) treatment option.¹² AM, obtained post-elective caesarean delivery and processed into an allograft material,¹³ possesses unique immunomodulatory, anti-inflammatory, anti-fibrotic, pain-reducing and epithelial healing properties,^{14,15} making it ideal for ocular surface healing,^{16,17} benefits which can be exploited in the management of DED.¹⁸

Traditional AM products in ophthalmology, however, require specialised storage and/or application, limiting their widespread adoption as a DED treatment. Addressing these limitations, this study introduces a novel approach using Omnigen[®], a room-temperature stable dehydrated AM (dAM), applied using a specialised bandage contact lens (sBCL), OmniLenz[®] (both NuVision[®] Biotherapies, Nottingham, UK). This innovative technique allows consistent sutureless and surgery-free application, enhancing accessibility and convenience of AM at an earlier stage of DED. The real-world clinical benefits of this approach have already been demonstrated in refractory persistent epithelial defects,¹⁹ and early intervention in acute chemical burns.²⁰

This study aimed to evaluate the effectiveness of bilaterally applied dAM in managing signs and symptoms of DED in patient's refractory to conventional treatments. This study therefore seeks to fill a critical gap in DED management, potentially reshaping therapeutic strategies for this increasingly prevalent condition.

Materials and Methods

Study Compliance

This study adhered to the tenets of the Declaration of Helsinki and received Aston University Research Ethics Committee (#1612) and governance approval.

Participant Selection

Participants included in the study were at least 18 years old with, more than 1 year of longstanding positive diagnosis of DED intransigent to TFOS DEWS II stage 1 treatment, an Ocular Surface Disease Index (OSDI) score of between 25 and 80, the presence of at least 1 of the following signs; corneal (≥ 5 punctate spots) or conjunctival (≥ 9 punctate spots) staining (oxford scale), or non-invasive Keratograph breakup time (NIK BUT, ≤ 8 seconds), and with no changes in DED therapy in the 6-weeks prior to their baseline visit. Exclusion criteria included a history of ocular herpetic keratitis, ocular surgery or IPL (Intense Pulsed Light) within 6 months prior to baseline visit, current use of glaucoma medication or other medication known to alter the tear film,³ use of moisture chamber goggles, known sensitivity to dAM antibiotics (gentamicin, imipenem, nystatin, polymyxin B and vancomycin), active ocular surface pathologies other than DED, eyelid abnormalities or extensive ocular scarring. Eligible participants were enrolled after providing written informed consent.

Study Design and Powering

This prospective pre-post interventional study was designed to select refractory DED patients who exhibited stable but chronic signs and symptoms in the month leading up to the treatment. This 1-month pre-treatment period served as a control, establishing a baseline against which changes post-treatment were assessed. The study involved 5 visits: Baseline (day -30) – initial measurements to establish control data; Treatment 1 (day 0) – repeat assessment to confirm disease stability, and application

of the intervention; Treatment 2 (day 4–5) – reapplication of the intervention; Treatment removal (day 8–10) – removal of the intervention to transition into post-treatment observation; and, 1-month post-treatment follow-up (day 30) – final assessment to evaluate the outcomes of the intervention.

Both eyes were treated bilaterally, but to ensure consistent and standardised data comparison, only the right eye data was analysed. This approach aligns with common practices in ocular studies and ensures a reliable data set for analysis. The choice of the right eye was based on preliminary findings that suggested similar disease progression in both eyes of the target patient population.²¹

The required sample size was determined to be 33 participants. Power calculations were performed using G*Power v3.1, with OSDI as the primary outcome measure, based on detecting a minimally clinically important difference of 4.5 to 7.3,²² with 95% power ($\beta = 0.05$) at a two-sided statistical significance level of 5% ($\alpha = 0.05$) using a pair t-test.

Intervention

Intervention involved all patients receiving two consecutive 4–5-day bilateral applications of Omnigen[®] VIEW dAM (17mm diameter disc with a 6mm central aperture) applied using OmniLenz[®] sBCL (18mm diameter, 8.80 base radius; plano lens; Menicon 72 material), both from NuVision[®] Biotherapies, Nottingham, UK. The uniqueness of this study lies in its use of a bilateral approach made possible both using a 6mm diameter central window in the dAM disc to reduce the impact on the participant's vision, and a specialised propriety lens modified retain dAM at the ocular surface, which distinguishes it from traditional unilateral methods.

The ocular surface was anaesthetised with proxymetacaine hydrochloride 0.5%, to minimise discomfort during treatment application and treatment was applied as per manufacturer's recommendations. Contact lens fitting, and dAM positioning, were assessed on a digital slit lamp (CSO Phoenix, Firenze, Italy) under 16x magnification, and an assessment of dAM window-to-pupil centration was checked additionally with an anterior segment Optical Coherence Tomographer (Cirrus-HD OCT, Germany). The choice of two consecutive treatments was based on previous findings suggesting that dAM benefits typically last 3–9 days, and to avoid dAM cloudiness due to accumulation of inflammatory coagulum.^{23–26} The OmniLenz[®] and any residual dAM was removed following instillation of anaesthetic after treatment 1 (day 4–5), and after treatment 2 (day 8–10).

Measurements

Clinical assessments were performed at baseline (day –30), on the treatment day (day 0) and 1-month post-treatment (day 30). To ensure consistency in testing conditions, all assessments were conducted by a single clinician at the same location, maintaining a mean \pm SD room temperature of 21.5 \pm 1.5°C and relative humidity of 43.2 \pm 11.6%. Participants acclimatised to the room conditions for a minimum of 15 minutes before testing.²⁷

The sequence of testing followed the TFOS DEWS II recommendations, adhering to an ascending order of invasiveness.²² The testing order involved: OSDI, Dry Eye Questionnaire 5-item (DEQ-5), and Symptoms Analysis in Dry Eye (SANDE, frequency and severity) questionnaires, used as recommended by their respective manufacturers; Tear meniscus height (TMH), measured using infrared light and high magnification digital imaging, with an average of three measurements taken from the lower lid edge below the iris using calibrated digital callipers; NIKBUT, captured by observing the time taken for a >5% distortion in Placido disc reflections, averaged over three readings following two non-forceful blinks; lipid layer thickness (LLT), graded using tear film interferometry on the modified Guillon-Keeler grading system – 0 (non-visible/absent), 1 (open meshwork), 2 (closed meshwork), 3 (wave/flow), 4 (amorphous), or 5 (coloured fringes),²⁸ limbal and bulbar hyperaemia, were automatically and objectively assessed using the R-Scan blood vessel redness detection module and classified using the JENVIS grading scale, to 0.1 precision;²⁹ Corneal staining (CornS) and conjunctival staining (ConjS) evaluated using fluorescein (BioFluoro. Biotech Vision Care Pvt., India)³⁰ observed under blue light with a yellow filter³⁰ and Lissamine strips (GreenGlo, Omni Lens Pvt, India), respectively, and the number of CornS and ConjS punctate spots subjectively graded as per the modified Oxford grading scheme;³¹ lid wiper epitheliopathy staining (LWE) was subjectively graded relative to Korb's grading scale.³² All ocular surface and tear film metrics were assessed with an Oculus Keratograph 5m (Wetzlar, Germany); Visual Acuity was assessed in all visits for safety with an Early Treatment Diabetic Retinopathy Study LogMAR chart.

Statistics

Data analysis was performed using IBM SPSS Statistics version 26 (New York, USA). Where normal distribution had been confirmed by the Kolmogorov–Smirnov test ($p > 0.05$), a repeated paired sample t -test was used. A two-tailed p -value of $p < 0.05$ was considered significant.

Results

A total of 35 eligible participants (23 females, 12 males), with a mean age of 50.3 ± 17.5 years (range: 19–77), were included in the study. This exceeded the target sample size of 33, thus ensuring adequate study power.

All study participants had been diagnosed with DED which had been active for an average of 12.5 ± 4.5 years and were refractory to previous treatments. None of the participants changed their concurrent treatment during the study.

Baseline (day –30), pre- (day 0) and post- (day 30) treatment characteristics are listed in (Table 1). The mean (\pm SD) duration of treatment (sBCL+dAM) remained in the eye was 4.1 ± 1.5 days (range: 1–9) for the first application, and for 4.2 ± 1.6 (range: 1–8) days for the second application, totalling an average of 8.1 ± 2.7 (range: 4–16) days.

Dry Eye Symptomatology

Significant improvements were observed in dry eye symptomatology 1-month post-treatment initiation. OSDI scores (Figure 1) decreased by 42% ($p < 0.01$), whilst SANDE frequency (Figure 2) and severity scores (Figure 3) decreased by 33% and 31% (both $p = 0.01$), respectively. DEQ-5 score (Figure 4) also showed a significant reduction of 32% ($p = 0.045$) at the 1-month visit. A slight score change from baseline to treatment day was noted ($p = 0.035$) even though no treatment was provided in the baseline visit (Table 1).

Ocular Surface Signs

The treatment positively impacted various ocular surface signs (Table 1). At the 1-month follow-up, the sagittal width of the LWE (Figure 5) significantly decreased from grade 1.7 to 1.1 (38% reduction, $p = 0.011$) and a marked, but not significant, reduction in ConjS was also shown from 1.6 to 1.3 ($p = 0.094$).

A small but significant decrease in conjunctival bulbar temporal hyperaemia from 1.10 to 0.98 ($p = 0.031$) was noted from baseline to treatment day. There were no other significant changes on bulbar conjunctival hyperaemia, ocular surface staining or tear film lipid layer thickness pattern.

Table 1 Clinical Measurements Pre and Post (1 Month) of BCL+dAM Treatment.

	Baseline (Day –30)	Treatment Visit (Day 0)	1 Month Post Treatment (Day 30)
OSDI	55.8 \pm 19.0	51.5 \pm 21.1 ($p = 0.035$)*	32.3 \pm 19.5 ($p < 0.001$)*
DEQ-5	14.6 \pm 3.0	13.5 \pm 3.2 ($p = 0.210$)	10.0 \pm 3.9 ($p = 0.045$)*
SANDE frequency	65.2 \pm 21.8	70.0 \pm 19.9 ($p = 0.508$)	43.6 \pm 22.9 ($p = 0.001$)*
SANDE severity	59.8 \pm 19.0	62.6 \pm 20.3 ($p = 0.682$)	41.1 \pm 22.0 ($p = 0.001$)*
Visual acuity (LogMAR)	0.12 \pm 0.15	0.11 \pm 0.15 ($p = 0.627$)	0.08 \pm 0.17 ($p = 0.102$)
Bulbar hyperaemia temporal + nasal (grade)	1.10 \pm 0.44	1.07 \pm 0.51 ($p = 0.644$)	1.15 \pm 0.51 ($p = 0.433$)
Limbus hyperaemia temporal + nasal (grade)	0.80 \pm 0.34	0.76 \pm 0.48 ($p = 0.680$)	0.77 \pm 0.37 ($p = 0.669$)
TMH (mm)	0.26 \pm 0.09	0.25 \pm 0.08 ($p = 0.443$)	0.25 \pm 0.11 ($p = 0.695$)
NIK BUT (s)	7.84 \pm 4.66	6.32 \pm 4.92 ($p = 0.125$)	7.57 \pm 4.77 ($p = 0.777$)
LLT (grade)	4.14 \pm 1.14	3.74 \pm 1.29 ($p = 0.095$)	4.00 \pm 1.26 ($p = 0.516$)
CornS (grade)	1.37 \pm 1.21	1.57 \pm 1.20 ($p = 0.386$)	1.34 \pm 1.26 ($p = 0.879$)
ConjS (grade)	1.80 \pm 1.28	2.00 \pm 1.08 ($p = 0.407$)	1.49 \pm 1.12 ($p = 0.094$)
LWE Width (grade)	1.74 \pm 1.34	1.31 \pm 1.23 ($p = 0.092$)	1.09 \pm 1.07 ($p = 0.011$)*
LWE Length (grade)	1.97 \pm 1.40	2.11 \pm 1.62 ($p = 0.619$)	1.83 \pm 1.58 ($p = 0.619$)

Notes: Average \pm SD (p -value). *Statistical significant of changes observed.

Abbreviations: ConjS, Conjunctival Staining; CornS, Corneal Staining; DEQ-5, Dry Eye Questionnaire; LLT, Lipid Layer Thickness; LogMAR, Logarithm of the Minimum Angle of Resolution; LWE, Lid Wiper Epitheliopathy; NIK BUT, Non-Invasive Keratometric BreakUp Time; OSDI, Ocular Surface Disease Index; TMH, Tear Meniscus Height; SANDE, Symptoms Analysis in Dry Eye.

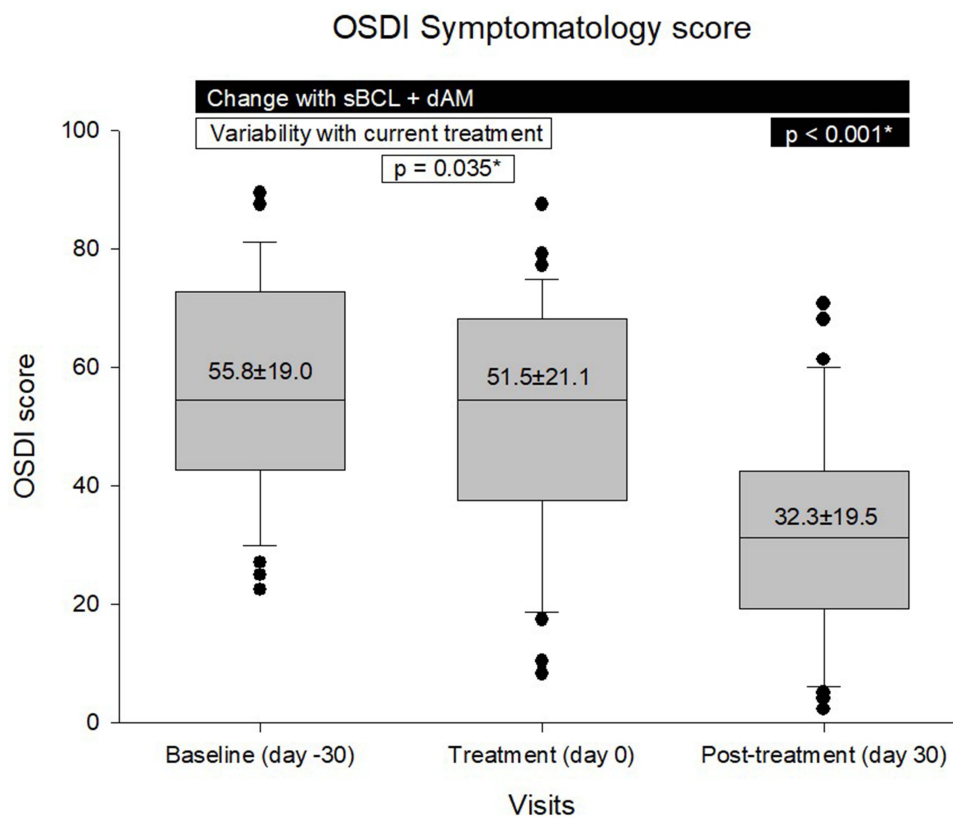


Figure 1 Subjective OSDI symptomatology score change from baseline to after treatment. *Denotes statistical significance.

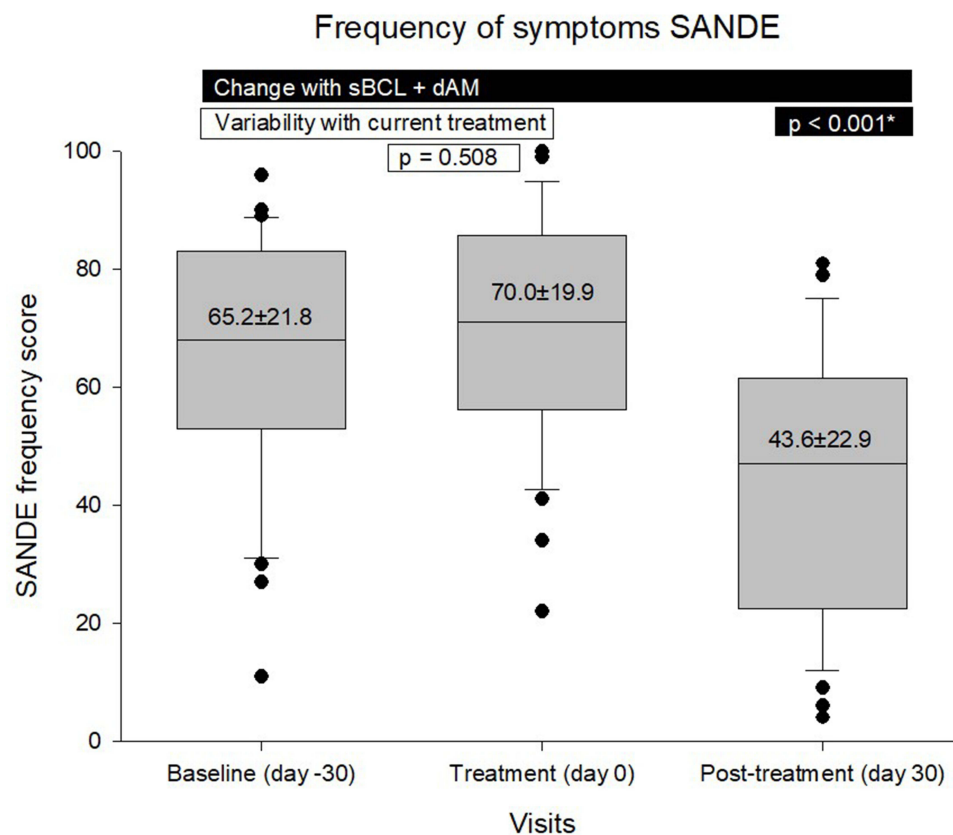


Figure 2 Subjective frequency of symptoms change from baseline to after treatment. *Denotes statistical significance.

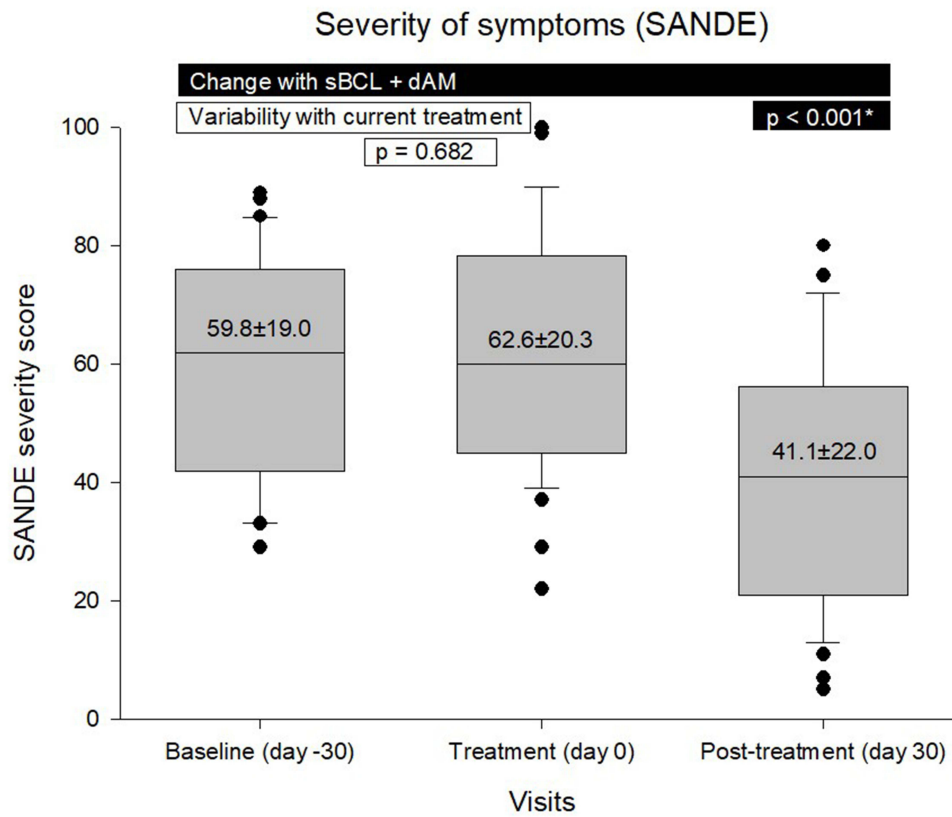


Figure 3 Subjective severity of symptoms change from baseline to after treatment. *Denotes statistical significance.

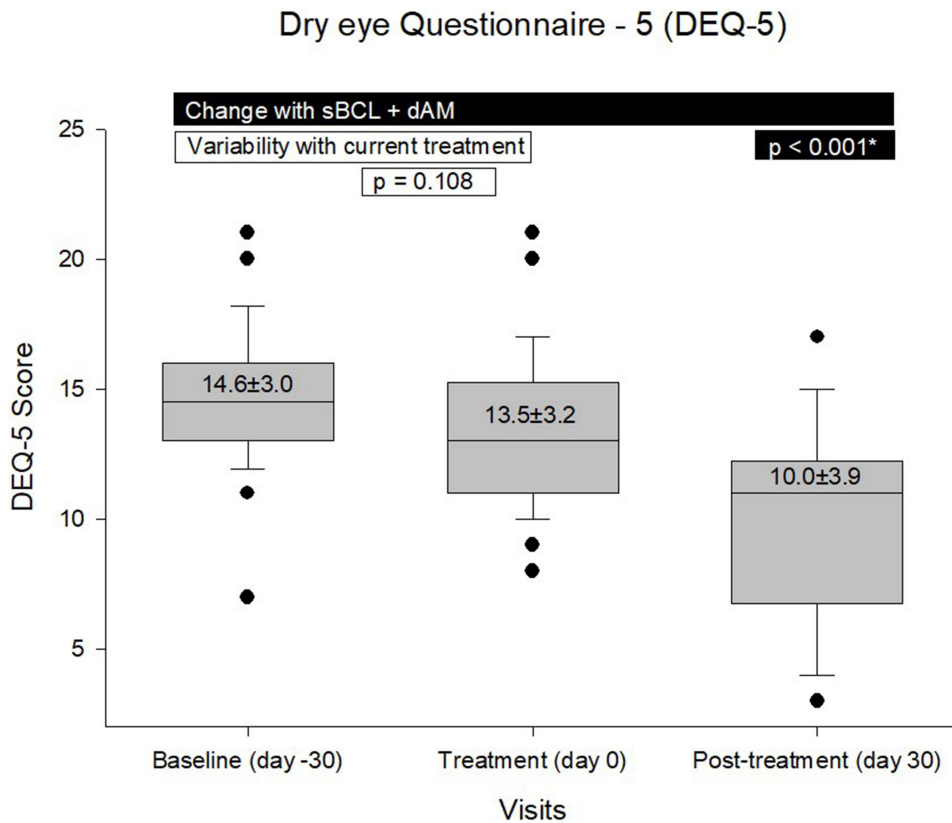


Figure 4 Subjective DEQ-5 symptomatology score change from baseline to after treatment. *Denotes statistical significance.

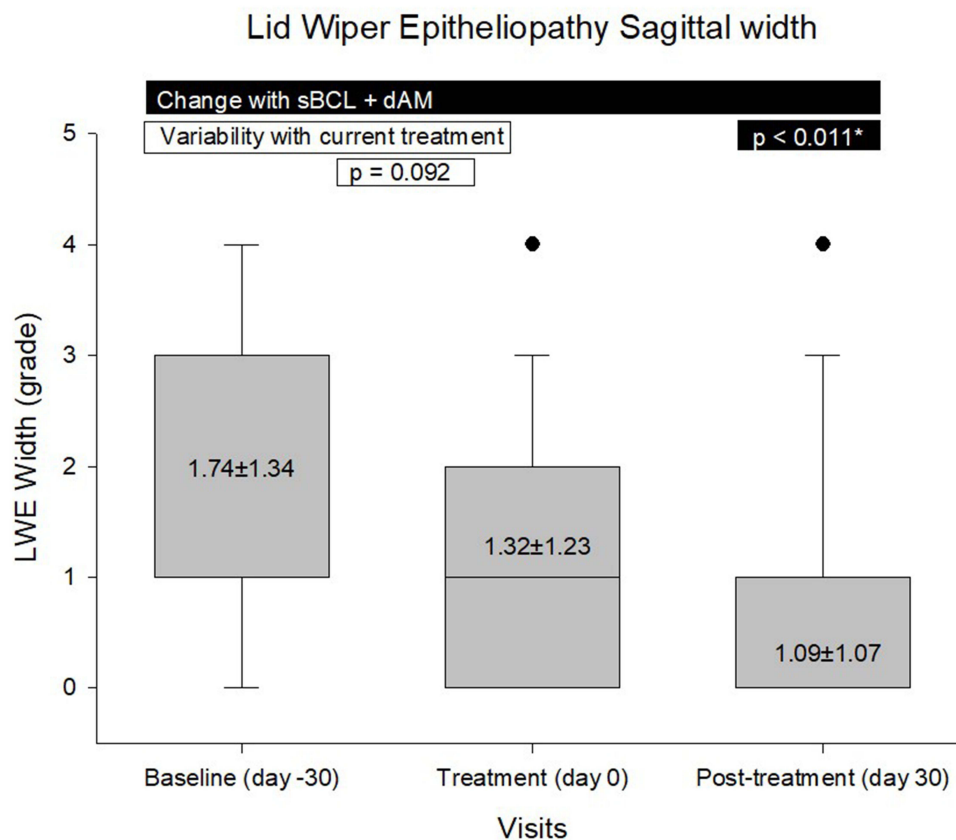


Figure 5 Objective epitheliopathy score change from baseline to after treatment.*Denotes statistical significance.

Safety

There were no significant changes in visual acuity between visits ($p=0.627$ and $p=0.102$), suggesting that the treatment was well-tolerated without adverse effects on vision. No safety concerns were raised from the treatment.

Discussion

The use of AM in clinical ophthalmology is a well-established practice for various ocular surface disorders.^{16,17} Sutureless applications of AM are also gaining traction, particularly in disorders such as, persistent corneal epithelial defects,^{19,33} chemical and thermal burns,^{25,34} Stevens-Johnson/toxic epidermal necrolysis,^{35,36} neurotrophic keratitis,³⁷ ulcerative keratitis,³⁸ limbal stem cell deficiency,³⁹ neuropathic corneal pain,⁴⁰ and recently, DED.^{18,41}

Recently, the use of Omnigen[®] dAM applied with sBCL (OmniLenz[®]), has expanded its application, especially in treating of persistent corneal epithelial defects and acute chemical burns.^{19,20,42} These advancements demonstrated the safety and efficacy of extended application periods of 7 to 22 days, yielding more enhanced healing responses compared to traditional self-retained sutureless AM (Prokera, BioTissue, USA).^{19,20,42}

This study contributes significantly to the literature by being the first to employ dAM and using bilateral sutureless application in moderate-to-severe DED treatment. This approach not only leverages the benefits of dAM without surgical intervention but also aligns with the trend towards less invasive treatments in ophthalmology, whilst presenting a more accessible, cost-effective, and patient-friendly option for DED management.^{18,41}

The notable 42% (23.5 point) improvement in OSDI scores, observed in this study is comparable to, and in some cases exceeds, the outcomes from other treatments involving sutureless cryopreserved AM, such as Prokera, for DED management (Table 2). For example, in a retrospective case series by Cheng et al,⁴³ reported immediate 46% (15.3 points) improvement in OSDI scores following the removal of Prokera. However, the long-term benefit was not sustained, with OSDI scores reverting to baseline within an average of 4.2 ± 4.7 months. Notably, the initial severity

Table 2 Comparison of Published Moderate-to-Severe DED Study Data.

	Current study	Cheng ⁴⁴	John ⁴⁵	Morkin ⁴⁰	McDonald ¹⁸	McDonald ⁴¹
Year	2023	2018	2017	2018	2018	2023
Study	Prospective pre-post	Retro	Prospective RCT	Retro	Retro	Retro
Participants (eyes)	35 (70)	1 (10)	17–9 study/8 control	9 (10)	84 (97)	77 (89)
Sutureless treatment	Omnigen®	Prokera SLIM	Prokera SLIM	Prokera Slim 8 /Clear 2	Prokera SLIM	Prokera SLIM
Time point	1-month	Day 0	1 month	-	1 month	1 month
Treatment duration- days (range)	8.1±2.7 (4–16)	7.2 ± 2.3 8.5 ± 2	3.4±0.7 (3–5)	6.4±1.1	5.4±2.8 (2–11)	4.9 ± 1.8
OSDI Change – points (%)	55.8±19.0 to 32.3±19.5 –23.5 (42.2%)	- -	- -	- -	- -	- -
Pain score Change – points (%)	59.8±19.0 to 41.09±22.0, 18.72 (31%)	- -	7.1±1.5 to 2.2±1.1, 4.9 (69%)	6.3±0.8 to 1.9±0.6, 4.4 (72.5%)	- -	- -

Abbreviations: OSDI, Ocular surface Disease Index; RCT, Randomised Controlled Trial.

of DED in this study, indicated by an OSDI score of 51.5, was higher than that reported by Cheng et al, where the OSDI score was 33 (Table 2). This suggests that, relative to the starting severity, this study achieved a more substantial improvement in symptomatology, as measured by OSDI.

Additionally, John et al⁴⁵ reported a reduction in patient symptomatology measured by the Visual Analog Scale (VAS) from 7.1±1.5 to 2.2±1.1, one month post-treatment with Prokera Slim, though OSDI was not a measured outcome in their study. In a retrospective case series of 10 eyes, Morkin et al⁴⁰ applied Prokera Slim and Prokera Clear (2 eyes) in a study on DED-related neuropathic corneal pain, reporting effective pain control in 80% of tested eyes at 6.0±2.1 months.

In contrast, this study not only improved overall OSDI scores but it has also effectively reduced pain frequency and severity, as measured by the SANDE questionnaire, suggesting a more comprehensive and sustained symptom relief using bilateral dAM application.⁴⁰ The limited improvement in signs matches that found by Craig et al, where symptoms improved within a month of artificial tear treatment, LWE within two months, but NIKBUT and corneal/conjunctival staining took 4 months to improve.⁴⁶ Hence, the lack of change within these tear film homeostasis indicators would be expected.

The safety profile of both dehydrated and cryopreserved AM placements has been well documented, with no significant adverse reactions.⁴⁷ The use of sutureless sBCL as a delivery mechanism in this study potentially enhances patient comfort and treatment efficacy,^{19,33} in contrast to previous methods involving more rigid delivery systems, such as Prokera, associated with discomfort and shorter treatment durations.^{40,48} Though previously associated with reduced pain relief,^{40,45} recent research suggests that the duration of treatment might not correlate with treatment benefits,⁴¹ which is possibly due to the rapid loss of beneficial proteins in cryopreserved amnion, a limitation not present in dAM.^{23,49,50}

The ability to deliver bilateral treatment with the dAM discs central 6mm aperture and sBCL amnion retention capability, is a unique aspect of this study, allowing clear visual axis maintenance and enabling patients to continue daily activities, thereby improving quality-of-life. This feature distinguishes the current study from other treatments that can potentially decrease vision from -0.22 ± 0.06 to 0.92 ± 0.45 (logMAR).⁴⁸ Though Prokera Clear previously offered similar visual and clinical benefits (in 2 cases), it was not applied bilaterally.⁴⁰ Furthermore, this bilateral treatment approach offers practical advantages in terms of potentially reducing the number of appointments or providing the option to increase the number of treatments in the current care pathway.

While soft “bandage” contact lenses have been used to protect the cornea, improve comfort, tear film stability, pain and aid epithelial recovery in many ocular surface disease states,^{51,52} research demonstrated the benefit in symptoms over no lens (after cataract surgery) was <5 OSDI points.⁵³ Hence, the substantial improvements in symptomatology observed in this study (of ~20 points) can be reasonably attributed to the combined use of dAM and sBCL, emphasising the efficacy of this novel treatment approach.

The increasing prevalence of DED and its impact on patient quality-of-life and healthcare systems, especially post-COVID-19, further underscores the need for effective and efficient treatment strategies.⁵⁴ The novel outpatient application of sutureless AM offers potential clinical service benefits,¹⁹ and may be preferable to current standard treatments like cyclosporin due to better clinical outcomes and lower societal costs.⁵⁵ The methodology presented in this study, applicable in a primary care setting by trained eye care practitioners, such as optometrists, offers the potential for reduced treatment costs and improved patient outcomes, thereby alleviating the economic burden on public healthcare systems.^{54,55}

While this prospective pre-post study offers promising standardised results, it is limited by its short-term post-treatment assessment and the lack of a more rigorous randomised control group. Further research is necessary to explore the long-term benefits of the treatment in DED including in its impact on subclinical inflammation and corneal nerves.⁴⁵

Conclusion

In conclusion, this is the first study to demonstrate the effectiveness of bilateral application of sutureless dAM using a specialised lens vehicle in reducing symptomatology and improving ocular surface health in moderate-to-severe DED. This approach has the potential to transform therapeutic strategies for DED, offering an effective and patient-friendly treatment alternative.

Disclosure

This study was an investigator-initiated study, funded by NuVision[®] Biotherapies Ltd, UK. The dAM (Omnigen[®]) and bandage contact lenses (OmniLenz[®]) were provided by NuVision[®] Biotherapies as part of the study. NuVision[®] Biotherapies were not involved in the study design, collection, analysis, and interpretation of data, or presentation of the results. ST-H has received consultancy from Alcon, Santen and Thea in the past, she is deputy academic chair and fellowship lead of the British Contact Lens Association. JSW has funding from 3M, Alcon, Allergan, CooperVision, Johnson and Johnson Vision, Rayner, M2C Pharmaceuticals, Menicon, Novartis, Scope Ophthalmic, SightGlass, Thea and the Eye Doctor; he is a consultant to AOS, Bausch and Lomb, Alcon, CooperVision, CSIDryEye, DopaVisin, Medmont, Novartis, NuVision[®], Santen, Scope Ophthalmic, SightGlass, Thea and TRB Chemedica International; he is academic chair of the British Contact Lens Association, chief scientific officer of the International Myopia Institute and on the executive of the Tear Film and Ocular Surface Society; he is a founder and has stock ownership in Aston Vision Sciences, Eyoto and Wolffsohn Research Ltd. The authors report no other conflicts of interest in this work.

References

1. Craig JP, Nichols KK, Akpek EK, et al. TFOS DEWS II definition and classification report. Review. *Ocular Surface*. 2017;15(3):276–283. doi:10.1016/j.jtos.2017.05.008
2. Smith JA, Albeitz J, Begley C, et al. The epidemiology of dry eye disease: report of the epidemiology subcommittee of the international dry eye workshop (2007). Article. *Ocul Surf*. 2007;5(2):93–107.
3. Stapleton F, Alves M, Bunya VY, et al. TFOS DEWS II epidemiology report. Review. *Ocul Surf*. 2017;15(3):334–365. doi:10.1016/j.jtos.2017.05.003
4. Bradley JL, Özer Stillman I, Pivneva I, Guerin A, Evans AM, Dana R. Dry eye disease ranking among common reasons for seeking eye care in a large US claims database. *Clin Ophthalmol*. 2019;13:225–232. doi:10.2147/oph.s188314
5. Yu J, Asche CV, Fairchild CJ. The economic burden of dry eye disease in the United States: a decision tree analysis. *Cornea*. 2011;30(4):379–387. doi:10.1097/ICO.0b013e3181f7f363
6. Bron AJ, de Paiva CS, Chauhan SK, et al. TFOS DEWS II pathophysiology report. Review. *Ocul Surf*. 2017;15(3):438–510. doi:10.1016/j.jtos.2017.05.011
7. De Paiva CS, Corrales RM, Villarreal AL, et al. Corticosteroid and doxycycline suppress MMP-9 and inflammatory cytokine expression, MAPK activation in the corneal epithelium in experimental dry eye. *Exper Eye Res*. 2006;83(3):526–535. doi:10.1016/j.exer.2006.02.004
8. Brignole F, Pisella PJ, Goldschild M, De Saint Jean M, Goguel A, Baudouin C. Flow cytometric analysis of inflammatory markers in conjunctival epithelial cells of patients with dry eyes. Article; Proceedings Paper. *Invest Ophthalmol*. 2000;41(6):1356–1363.
9. Kunert KS, Tisdale AS, Gipson IK. Goblet cell numbers and epithelial proliferation in the conjunctiva of patients with dry eye syndrome treated with cyclosporine Article. *Archives of Ophthalmology*. 2002;120(3):330–337.
10. Li DQ, Chen Z, Song XJ, Luo LH, Pflugfelder SC. Stimulation of matrix metalloproteinases by hyperosmolarity via a JNK pathway in human corneal epithelial cells. Article. *Invest Ophthalmol*. 2004;45(12):4302–4311. doi:10.1167/iops.04-0299
11. Yeh S, Song XJ, Farley W, Li DQ, Stern ME, Pflugfelder SC. Apoptosis of ocular surface cells in experimentally induced dry eye. Article. *Invest Ophthalmol*. 2003;44(1):124–129. doi:10.1167/iops.02-0581
12. Jones L, Downie LE, Korb D, et al. TFOS DEWS II management and therapy report. Review. *Ocul Surf*. 2017;15(3):575–628. doi:10.1016/j.jtos.2017.05.006

13. Hopkinson A, Britchford ER, Sidney LE. Preparation of dried amniotic membrane for corneal repair. In: Ahearne M, editor. *Corneal Regeneration Methods and Protocols*. Springer protocols; 2020:143–157.
14. Dua HS, Gomes JAP, King AJ, Maharajan VS. The amniotic membrane in ophthalmology. *Surv Ophthalmol*. 2004;49(1):51–77. doi:10.1016/j.survophthal.2003.10.004
15. Hao YX, Ma DHK, Hwang DG, Kim WS, Zhang F. Identification of antiangiogenic and antiinflammatory proteins in human amniotic membrane. *Cornea*. 2000;19(3):348–352. doi:10.1097/00003226-200005000-00018
16. Walkden A. Amniotic membrane transplantation in ophthalmology: an updated perspective. *Clin Ophthalmol*. 2020;14:2057–2072. doi:10.2147/OPTH.S208008
17. Sanders FWB, Huang J, Alió Del Barrio JL, Hamada S, McAlinden C. Amniotic membrane transplantation: structural and biological properties, tissue preparation, application and clinical indications. *Eye*. 2023. doi:10.1038/s41433-023-02777-5
18. McDonald MB, Sheha H, Tighe S, et al. Treatment outcomes in the DRy Eye Amniotic Membrane (DREAM) study. *Clin Ophthalmol*. 2018;12:677–681. doi:10.2147/OPTH.S162203
19. Maqsood S, Elsayah K, Dhillon N, et al. Management of persistent corneal epithelial defects with human amniotic membrane-derived dry matrix. *Clin Ophthalmol*. 2021;15:2231–2238. doi:10.2147/oph.s299141
20. Lotfy NM, Al Rashidi S, Hagra S. Clinical outcomes of vacuum-dehydrated amniotic membrane (Omnigen) mounted on contact lens (Omnilenz) in eyes with acute chemical eye injuries. *Graefes Arch Clin Exp Ophthalmol*. 2023;2023. doi:10.1007/s00417-023-06151-9
21. Mollan SP, Homer V, Gates S, Brock K, Sinclair AJ. One eye or two: statistical considerations in ophthalmology with a focus on interventional clinical trials. *J Neuroophthalmol*. 2021;41:4.
22. Wolffsohn JS, Arita R, Chalmers R, et al. TFOS DEWS II diagnostic methodology report. Review. *Ocul Surf*. 2017;15(3):539–574. doi:10.1016/j.jtos.2017.05.001
23. Allen CL, Clare G, Stewart EA, et al. Augmented dried versus cryopreserved amniotic membrane as an ocular surface dressing. *PLoS One*. 2013;8(10):e78441. doi:10.1371/journal.pone.0078441
24. Liu T, Zhai HL, Xu YY, et al. Amniotic membrane traps and induces apoptosis of inflammatory cells in ocular surface chemical burn. *Mol Vision*. 2012;18:220–225.
25. Kheirhah A, Johnson DA, Paranjpe DR, Raju VK, Casas V, Tseng SCG. Temporary sutureless amniotic membrane patch for acute alkaline burns. *Arch Ophthalmol*. 2008;126(8):1059–1066. doi:10.1001/archoph.126.8.1059
26. Kim JS, Kim JC, Na BK, Jeong JM, Song CY. Amniotic membrane patching promotes healing and inhibits proteinase activity on wound healing following acute corneal alkali burn. *Exp Eye Res*. 2000;70(3):329–337. doi:10.1006/exer.1999.0794
27. Teson M, Lopez-Miguel A, Neves H, Calonge M, Gonzalez-Garcia MJ, Gonzalez-Mejome JM. Influence of climate on clinical diagnostic dry eye tests: pilot study. *Optometry Vision Sci*. 2015;92(9):E284–E289. doi:10.1097/oxp.0000000000000673
28. Guillon JP. Use of the tearscope plus and attachments in the routine examination of the marginal dry eye contact lens patient. Article; Proceedings Paper. *Lacrimal Gland Tear Film Dry Eye Synd 2*. 1998;438:859–867.
29. Wu SQ, Hong JX, Tian LJ, Cui XH, Sun XH, Xu JJ. Assessment of bulbar redness with a newly developed keratograph. *Optometry Vision Sci*. 2015;92(8):892–899. doi:10.1097/oxp.0000000000000643
30. Peterson RC, Wolffsohn JS, Fowler CW. Optimization of anterior eye fluorescein viewing. Article. *Am J Ophthalmol*. 2006;142(4):572–575. doi:10.1016/j.ajo.2006.04.062
31. Bron AJ, Evans VE, Smith JA. Grading of corneal and conjunctival staining in the context of other dry eye tests. *Cornea*. 2003;22(7):640–650. doi:10.1097/00003226-200310000-00008
32. Korb DR, Herman JP, Finnemore VM, Greiner JV, Olson MC, Scaffidi RC. Lid wiper epitheliopathy and associated dry eye symptoms. Meeting Abstract. *Invest Ophthalmol*. 2004;45:U123–U123.
33. Mimouni M, Trinh T, Sorkin N, et al. Sutureless dehydrated amniotic membrane for persistent epithelial defects. *Euro J Ophthalmol*. 2022;32(2):875–879. doi:10.1177/11206721211011354
34. Suri K, Kosker M, Raber IM, et al. Sutureless amniotic membrane prokera for ocular surface disorders: short-term results. Article. *Eye*. 2013;39(5):341–347. doi:10.1097/ICL.0b013e3182a2f8fa
35. Shanbhag SS, Chodosh J, Saeed HN. Sutureless amniotic membrane transplantation with cyanoacrylate glue for acute Stevens-Johnson syndrome/toxic epidermal necrolysis. *Ocul Surf*. 2019;17(3):560–564. doi:10.1016/j.jtos.2019.03.001
36. Mahmood AH, Alharbi AS, Almanea BA, Alsaati AF. Sutureless Amniotic Membrane (ProKera (R)) and Intravenous Immunoglobulin in the Management of Ocular Complications of Stevens-Johnson Syndrome-Toxic Epidermal Necrolysis Overlap. *Cureus*. 2021;13(8):e16989. doi:10.7759/cureus.16989
37. Mead OG, Tighe S, Tseng SCG. Amniotic membrane transplantation for managing dry eye and neurotrophic keratitis. *Taiwan J Ophthalmol*. 2020;10(1):13–21. doi:10.4103/tjo.tjo_5_20
38. Sheha H, Liang LY, Li JJ, Tseng SCG. Sutureless amniotic membrane transplantation for severe bacterial keratitis. *Cornea*. 2009;28(10):1118–1123. doi:10.1097/ICO.0b013e3181a2abad
39. Kheirhah A, Casas V, Raju VK, Tseng SCG. Sutureless amniotic membrane transplantation for partial limbal stem cell deficiency. *Am J Ophthalmol*. 2008;145(5):787–794. doi:10.1016/j.ajo.2008.01.009
40. Morkin MI, Hamrah P. Efficacy of self-retained cryopreserved amniotic membrane for treatment of neuropathic corneal pain. *Ocul Surf*. 2018;16(1):132–138. doi:10.1016/j.jtos.2017.10.003
41. McDonald M, Janik SB, Bowden FW, et al. Association of treatment duration and clinical outcomes in dry eye treatment with sutureless cryopreserved amniotic membrane. *Clin Ophthalmol*. 2023;17:2697–2703. doi:10.2147/oph.s423040
42. Mehta A, Pradhan S, Figueiredo F. Low temperature vacuum-dehydrated amniotic membrane (Omnigen) - Case series for the treatment of ocular surface burn and related complications at a tertiary eye unit in the UK. *Invest Ophthalmol Visual Sci*. 2021;62(8):1258.
43. Cheng AMS, Zhao D, Chen R, et al. Accelerated restoration of ocular surface health in dry eye disease by self-retained cryopreserved amniotic membrane. *Ocul Surf*. 2016;14(1):56–63.
44. Cheng AMS, Tighe S, Sheha H, Tseng SCG. Adjunctive role of self-retained cryopreserved amniotic membrane in treating immune-related dry eye disease. *Int Ophthalmol*. 2018;38(5):2219–2222. doi:10.1007/s10792-017-0708-y

45. John T, Tighe S, Sheha H, et al. Corneal nerve regeneration after self-retained cryopreserved amniotic membrane in dry eye disease. *J Ophthalmol.* 2017;20176404918. doi:10.1155/2017/6404918
46. Craig JP, Muntz A, Wang MTM, et al. Developing evidence-based guidance for the treatment of dry eye disease with artificial tear supplements: a six-month multicentre, double-masked randomised controlled trial. *Ocul Surf.* 2021;20:62–69. doi:10.1016/j.jtos.2020.12.006
47. Paolin A, Cogliati E, Trojan D, et al. Amniotic membranes in ophthalmology: long term data on transplantation outcomes. *Cell Tissue Bank.* 2016;17(1):51–58. doi:10.1007/s10561-015-9520-y
48. Ijiri S, Kobayashi A, Sugiyama K, Tseng SCG. Evaluation of visual acuity and color vision in normal human eyes with a sutureless temporary amniotic membrane patch. *Am J Ophthalmol.* 2007;144(6):938–942. doi:10.1016/j.ajo.2007.08.003
49. Hopkinson A, McIntosh RS, Shanmuganathan V, Tighe PJ, Dua HS. Proteomic analysis of amniotic membrane prepared for human transplantation: characterization of proteins and clinical implications. *J Proteome Res.* 2006;5(9):2226–2235. doi:10.1021/pr050425q
50. Hopkinson A, McIntosh RS, Tighe PJ, James DK, Dua HS. Amniotic membrane for ocular surface reconstruction: donor variations and the effect of handling on TGF-beta content. *Invest Ophthalmol Vis Sci.* 2006;47(10):4316–4322. doi:10.1167/iops.05-1415
51. Sánchez-González J-M, López-Izquierdo I, Gargallo-Martínez B, De-Hita-Cantalejo C, Bautista-Llamas M-J. Bandage contact lens use after photorefractive keratectomy. *J Cataract Refract Surg.* 2019;45:8.
52. Chaudhary S, Ghimire D, Basu S, Agrawal V, Jacobs DS, Shanbhag SS. Contact lenses in dry eye disease and associated ocular surface disorders. *Indian J Ophthalmol.* 2023;71(4):1142–1153. doi:10.4103/ijo.ijo_2778_22
53. Wu X, Ma Y, Chen X, et al. Efficacy of bandage contact lens for the management of dry eye disease after cataract surgery. *Int Ophthalmol.* 2021;41(4):1403–1413. doi:10.1007/s10792-021-01692-6
54. Tavakoli A, Flanagan JL. Dry eye disease: an (in)convenient truth. *Clin Exp Optometry.* 2022;105(2):222–229. doi:10.1080/08164622.2021.1945410
55. Voigt J. Cost utility analysis of cryopreserved amniotic membrane versus topical cyclosporine for the treatment of moderate to severe dry eye syndrome. *Cost Eff Resour Allocation.* 2020;18(1):56. doi:10.1186/s12962-020-00252-6

Clinical Ophthalmology

Dovepress

Publish your work in this journal

Clinical Ophthalmology is an international, peer-reviewed journal covering all subspecialties within ophthalmology. Key topics include: Optometry; Visual science; Pharmacology and drug therapy in eye diseases; Basic Sciences; Primary and Secondary eye care; Patient Safety and Quality of Care Improvements. This journal is indexed on PubMed Central and CAS, and is the official journal of The Society of Clinical Ophthalmology (SCO). The manuscript management system is completely online and includes a very quick and fair peer-review system, which is all easy to use. Visit <http://www.dovepress.com/testimonials.php> to read real quotes from published authors.

Submit your manuscript here: <https://www.dovepress.com/clinical-ophthalmology-journal>