

Factors Affecting the Diagnostic Discordance Between Frozen and Permanent Sections in Mucinous Ovarian Tumors

Hua Shao^{1,*}, Na Wang^{2,*}, Guoyan Liu^{3,4,*}

¹Clinical Psychology Department, Tianjin Medical University General Hospital, Tianjin, People's Republic of China; ²Gynecology and Obstetrics Department, Tianjin Haihe Hospital, Tianjin, People's Republic of China; ³Gynecology and Obstetrics Department, Tianjin Medical University General Hospital, Tianjin, People's Republic of China; ⁴Gynaecological Oncology Department, Tianjin Medical University Cancer Institute and Hospital, Tianjin, People's Republic of China

*These authors contributed equally to this work

Correspondence: Guoyan Liu, Tel +86 15510993428, Email liuguoyan2023@163.com

Purpose: To investigate the accuracy of intraoperative frozen section (FS) diagnosis for predicting the permanent section (PS) diagnosis of mucinous ovarian tumors and evaluate the factors affecting the diagnostic discordance.

Patients and Methods: This retrospective cohort study was performed in Tianjin Medical University General Hospital. All women who underwent ovarian surgery with FS between January 2011 and December 2022 were identified, and those with a diagnosis of mucinous ovarian tumor (MOT) by FS or PS were reviewed. Clinical and pathologic data were extracted.

Results: A total of 180 women were included, of which 141 (78.33%) had diagnostic concordance between FS and PS, yielding a sensitivity of 83.43% and a positive predictive value (PPV) of 92.76%. Under- and over-diagnosis occurred in 28 cases (15.56%) and 11 cases (6.11%). Tumor size > 13cm (OR 3.79, 95% CI 1.12–12.73) was an independent risk factor for under-diagnosis, and tumor size ≤ 13cm (OR 16.78, 95% CI 0.01–0.49), laparoscopic surgery (OR 0.14, 95% CI 0.02–0.92), the combination of other tumor components (including serous, Brenner tumor, and chocolate cyst; OR 7.00, 95% CI 1.19–41.12) were independently associated with over-diagnosis. The Kaplan-Meier survival curves and the Log rank test showed no significant difference between misdiagnosed and accurately diagnosed patients (all $P > 0.05$).

Conclusion: Intraoperative frozen pathology of MOT is problematic for under- and over-diagnosis. The incorrect diagnosis of FS was related to determining the extent of surgery but had no impact on the patients' long-term recurrence and survival outcomes. In future clinical practice, surgeons need to obtain material accurately and enhance communication with pathologists during the operation to improve the accuracy of FS diagnosis.

Keywords: mucinous ovarian tumors, frozen section, diagnosis

Introduction

Ovarian mucinous tumors (MOT) occur in 10–15% of all ovarian tumors¹ and represent a heterogeneous group of neoplasms, of which benign cystadenomas constitute about 80%, borderline tumors are 10–15%, and less than 10% are malignant tumors.^{2–4} The five-year survival rate of borderline mucinous ovarian tumors has been reported to be as high as 100%; however, it is also affected by the length of the follow-up period, and up to 13% of patients with borderline tumors progress to carcinoma within ten years.^{5–7} Surgical treatment is the primary treatment modality, and surgical approaches and extent of resection vary based on tumor pathology.^{8,9} Ultrasound is the initial and preferred imaging modality used for MOT, and it can be complemented by magnetic resonance imaging (MRI).^{10,11} However, high-quality images cannot be obtained due to abdominal gas, making the identification of ovarian tumors challenging. Several tumor markers are commonly used to evaluate patients with ovarian cancer, including CA125, CA199, CA153, HE4, CEA, and AFP.¹² In particular, CA199 is a sensitive indicator for diagnosing MOT, primarily associated with borderline and

malignant tumors, and can be used as a complementary marker to identify benign, borderline, or malignant MOT.¹³ The combined testing of multiple indicators can increase diagnostic accuracy, but the preoperative diagnosis of MOT is difficult due to the low specificity and sensitivity.^{14–18} Intraoperative frozen section (FS) is a common and effective examination with the advantage that the pathologic results can be obtained at the time of surgery so that the surgical procedure and extent of surgery can be determined.¹⁹

Surgery and chemotherapy are the basis of ovarian cancer treatment, and the specific treatment plan varies according to the pathologic stage of MOT.²⁰ Primary treatment for stage I patients consists of complete staging surgery and postoperative therapy, and an appendix with an abnormal appearance should be removed. Observation is usually adequate after surgery for patients in stages IA or IB. Either observation or chemotherapy is appropriate for stage IC, and patients with stages II–IV require whole-body systemic therapy.²¹ About 90% of MOT are stage I, and fertility-sparing surgery can be feasible in women of reproductive age.²² Preserving the uterus and contralateral ovary is recommended in patients with MOT who desire future fertility.^{23,24} For patients with borderline ovarian tumors, cyst excision is preferable rather than adnexectomy, which needs long-term and close follow-up.²⁵ In addition, intraperitoneal thermal perfusion tube placement is applied after ovarian cancer surgery, followed by intraperitoneal thermal perfusion chemotherapy.²⁶ Therefore, a correct and timely FS pathological diagnosis is a prerequisite for selecting an appropriate surgical approach and optimizing patient prognosis.

In this retrospective study, our institution's clinical and pathological electronic databases were reviewed to identify all MOT patients who had undergone FS diagnosis and received a permanent section (PS) diagnosis in the last decade. Specifically, we aimed to analyze the differences in diagnosis between FS and PS and the factors affecting the accuracy of FS and to evaluate the clinical outcomes of patients with under- or over-diagnosis of FS.

Materials and Methods

Study Design and Participants

Data concerning patients treated from January 2011 to December 2022 at Tianjin Medical University General Hospital for ovarian neoplasms who had FS evaluation were identified, and women were included in the case of an MOT at frozen or final pathology. MOT was defined and classified according to the World Health Organization Classification of tumors. Recurrence was defined as a clinical relapse based on the National Comprehensive Cancer Network's ovarian cancer guidelines. Cases were excluded if: (1) FS or PS diagnosis was missing; (2) combined with another primary malignancy; (3) primary surgery was performed in another hospital. Fresh specimens were sent for intra-operative examination separated by five minutes, and the rest of the specimens from the same surgery were interpreted by the same senior pathologist with more than five years' experience. The reports of FS and PS were divided into benign, borderline, and malignant.

To evaluate the agreement between frozen and final histological diagnoses, sensitivity, specificity, positive predictive value (PPV), negative predictive value (NPV), false positive rate (FPR), and false negative rate (FNR) were calculated.

This study was approved by the Ethics Committee of Tianjin Medical University General Hospital (IRB2022-YX-095-01) and was conducted in accordance with the 1964 Helsinki Declaration and its later amendments. We confirmed that all the data was anonymized and maintained with confidentiality; therefore, the requirement for informed consent has been waived because of the retrospective nature of the current study.

Statistical Analysis

For statistical analysis, patients were classified into same-diagnosis, under-diagnosis, and over-diagnosis groups according to the accuracy of FS. The clinicopathological characteristics included age, primary symptoms, tumor size, Serum CA125, CA199, HE4 levels, onset side, ovarian cyst fluid, rupture, ascites quantity, and combination of other tumor components. The treatment information involved surgical methods, appendectomy, and surgical approach. We also analyzed the International Federation of Gynecology and Obstetrics (FIGO) stage, median follow-up time, and the status of patients at the time of the last follow-up. Progression-free survival (PFS) was calculated as the number of months from the completion of primary treatment to the date of clinical recurrence. Overall survival (OS) was defined as the number of

months from completing primary treatment to the date of death. The survival curves were plotted using the Kaplan-Meier method to show OS and PFS with a Log rank test used for statistical comparison between groups.

The chi-squared or Fisher's exact test assessed clinicopathological factors associated with the reclassification of pathologic diagnosis. Multivariate analysis included significant parameters in univariate analysis and other associated factors. Statistical significance was assumed at $p < 0.05$ in two-sided tests. JMP Pro 16 software (SAS Institute, Cary, NC) and R (version 4.2.3) with an RStudio interface were used for all statistical analyses. The statistical review of the study was performed by a biomedical statistician.

Results

Participants Characteristics

The study was conducted on 180 patients who underwent ovarian surgery with FS and were diagnosed as MOT by frozen or permanent sections. Clinical and pathologic characteristics are outlined in Table 1. The median age was 53 years (15–80 years). The median levels of serum CA125, CA199, and HE4 were 21.1 U/mL (4.6–1100 U/mL), 18.78 U/mL (1.73–1522 U/mL), and 44.93 pmol/L (11.96–417.10 pmol/L). Initial permanent section diagnosis showed that 73 tumors were benign (40.56%), 82 were borderline (45.56%), and 25 were malignant (13.89%). The median size of the tumor was

Table 1 Baseline Characteristics of the 180 Patients

Characteristics	N (%)
Age (year) (Mean±SD)	49.11±18.13
Median CA125 level (range in U/mL)	21.1 (4.6–1100)
Median CA199 level (range in U/mL)	18.78 (1.73–1522)
Median HE4 level (range in pmol/L)	44.93 (11.96–417.10)
Histological subtypes	
Benign	73 (40.56)
Borderline	82 (45.56)
Malignant	25 (13.89)
Onset side	
Lateral	173 (96.11)
Bilateral	7 (3.89)
Median tumor size (range in cm)	15 (3–62)
FIGO stage	
I	101 (56.11)
II–IV	6 (3.33)
Unstaged	73 (40.56)
Ascites quantity (mL)	
<100 mL	157 (87.22)
≥100 mL	23 (12.78)
Ovarian cyst fluid	
Thin	43 (23.89)
Thick	137 (76.11)
Surgical methods	
Hysterectomy plus bilateral adnexectomy	64 (35.56)
Complete staging surgery	32 (17.78)
Oophorocystectomy	20 (11.11)
Bilateral adnexectomy	19 (10.56)
Lateral adnexectomy	45 (25.00)
Surgical approach	
Laparoscopic surgery	50 (27.78)
Transabdominal surgery	130 (72.22)

(Continued)

Table 1 (Continued).

Characteristics	N (%)
Rupture	
Unruptured	147 (81.67)
Intraoperative rupture	12 (6.67)
Spontaneous rupture	21 (11.67)
Appendectomy	
No	93 (51.67)
Yes	87 (48.33)
Combination of other tumor components	
None	145 (80.56)
Serous	16 (8.89)
Appendix tumor	5 (2.78)
Brenner tumor	5 (2.78)
Chocolate cyst	4 (2.22)
Teratoma	5 (2.78)
Median follow-up (range in months)	38 (2–128)
Status at time of last follow-up	
No evidence of disease	167 (92.78)
Clinical recurrence	11 (6.11)
Dead of disease	2 (1.11)

15 cm (3–62 cm). Median follow-up time was 38 months (2–128 months), with 178 patients (98.89%) patients alive at the time of last follow-up, two patients (1.11%) dead of disease, and 11 patients (6.11%) had clinical recurrence.

Accuracy of Frozen Section Diagnosis

The comparison between FS and PS diagnosis is shown in [Table 2](#). The overall agreement between FS and PS diagnosis was observed in 141/180 cases (78.33%), yielding a sensitivity and a PPV of 83.43% and 92.76%, respectively. Of note, under-diagnosis was identified in 28 cases (15.56%), whereas over-diagnosis was identified in 11 cases (6.11%). In the under-diagnosis group, 8 cases were borderline through FS/ malignant through PS, and 20 were benign through FS/ borderline through PS. In the over-diagnosis group, 11 cases were borderline through FS/ benign through PS. The diagnostic value of frozen sections according to the malignancy status is shown in [Table 3](#).

Factors Associated with Diagnostic Discordance Between Frozen Sections and Permanent Sections

Univariate analysis determined the factors associated with diagnostic discordance between FS and PS ([Table 4](#)). Histological subtypes ($P < 0.001$), FIGO stage ($P < 0.001$), tumor size ($P = 0.005$), and combination of other tumor components ($P = 0.047$) were significantly associated with the diagnostic discordance between FS and PS. Significant

Table 2 Comparison of Frozen and Permanent Section Diagnosis for Mucinous Ovarian Tumors (n=180)

Frozen Section Results	Permanent Section Results			Total
	Benign	Borderline	Malignant	
Benign	62	20	0	82
Borderline	11	62	8	81
Malignant	0	0	17	17
Total	73	82	25	180

Table 3 Diagnostic Values of Frozen Section in the Diagnosis of Mucinous Ovarian Tumor, Stratified by the Malignancy Status

Diagnostic Values (%)	Malignancy Status		
	Benign (n=73)	Borderline (n=82)	Malignant (n=25)
Sensitivity	84.93	75.61	68
Specificity	81.31	80.61	100
PPV	75.61	76.54	100
NPV	88.78	79.8	95.09
FPR	18.69	19.39	0
FNR	15.07	24.39	32
Accuracy	82.78	78.33	95.56

Abbreviations: PPV, positive predictive value; NPV, negative predictive value; FPR, false positive rate; FNR, false negative rate.

Table 4 Univariate Analyses for Risk Factors of Pathologic Reclassification

Characteristics	Same-Diagnosis	Under-Diagnosis	Over-Diagnosis	P-value
Age (years) [†]				
≤32	38 (77.44)	9 (19.15)	0	0.083
>32	103 (77.44)	19 (14.29)	11 (8.27)	
Histological Subtypes				
Benign	62 (84.93)	0	11 (15.07)	<0.001*
Borderline	62 (75.61)	20 (24.39)	0	
Malignant	17 (68.00)	8 (32.00)	0	
CA125 (U/mL)				
≤35	90 (78.95)	16 (14.04)	8 (7.02)	0.639
>35	51 (77.27)	12 (18.18)	3 (4.55)	
CA199 (U/mL)				
≤37	101 (78.29)	20 (15.50)	8 (6.20)	0.997
>37	40 (78.43)	8 (15.69)	3 (5.88)	
HE4 (pmol/L)				
≤140	135 (78.49)	26 (15.12)	11 (6.40)	0.773
>140	6 (75.00)	2 (25.00)	0	
Tumor size (cm) [†]				
≤13	65 (80.25)	7 (8.64)	59 (11.11)	0.005*
>13	76 (76.77)	21 (21.21)	2 (2.02)	
Ascites quantity (mL)				
<100	123 (78.34)	24 (15.29)	10 (6.37)	0.914
≥100	18 (78.26)	4 (17.39)	1 (4.35)	
Onset side				
Lateral	135 (78.03)	27 (15.61)	11 (6.36)	0.999
Bilateral	6 (85.71)	1 (14.29)	0	
Surgical approach				
Laparoscopic	40 (80.00)	6 (12.00)	4 (8.00)	0.609
Transabdominal	101 (77.69)	22 (16.92)	7 (5.38)	
Appendectomy				
No	69 (74.19)	17 (18.28)	7 (7.53)	0.374
Yes	72 (82.76)	11 (12.64)	4 (4.60)	

(Continued)

Table 4 (Continued).

Characteristics	Same-Diagnosis	Under-Diagnosis	Over-Diagnosis	P-value
Rupture				
Unruptured	117 (79.59)	20 (13.61)	10 (6.80)	0.187
Intraoperative rupture	7 (58.33)	5 (41.67)	0	
Spontaneous rupture	17 (80.95)	3 (14.29)	1 (4.76)	
FIGO stage				
I	75 (74.26)	26 (25.74)	0	<0.001*
II–IV	4 (66.67)	2 (33.33)	0	
Unstaged	62 (84.93)	0	11 (15.07)	
Surgical methods				
Hysterectomy plus bilateral adnexectomy	49 (76.56)	12 (18.75)	3 (4.69)	0.977
Adnexectomy [†]	50 (78.13)	9 (14.06)	5 (7.81)	
Complete staging surgery	26 (81.25)	4 (12.50)	2 (6.25)	
Oophorocystectomy	16 (80.00)	3 (15.00)	1 (5.00)	
Combination of other tumor components				
None	114 (78.62)	25 (17.24)	6 (4.14)	0.047*
Others [□]	27 (77.14)	3 (8.57)	5 (14.29)	
Ovarian cyst fluid				
Thin	39 (90.70)	3 (6.98)	1 (2.33)	0.086
Thick	102 (74.45)	25 (18.25)	10 (7.30)	

Notes: *Difference reached statistical significance. [†]The optimum cut-off value was determined using the ROC curve analysis with the highest Youden index. [‡]Including lateral and bilateral adnexectomy. [□]Including serous, Brenner tumor, teratoma, appendix tumor, and chocolate cyst.

factors from the univariate analysis and priori essential factors such as onset side, surgical approach, and rupture were included in the multivariate analysis. As shown in [Figure 1](#), tumor size > 13cm (odds ratio (OR) 3.79, 95% confidence interval (CI) 1.12–12.73, P = 0.032) was an independent risk factor for under-diagnosis. Tumor size > 13cm (OR 0.05, 95% CI 0.01–0.49, P = 0.010), laparoscopic surgery (OR 0.14, 95% CI 0.02–0.92, P = 0.041), the combination of other

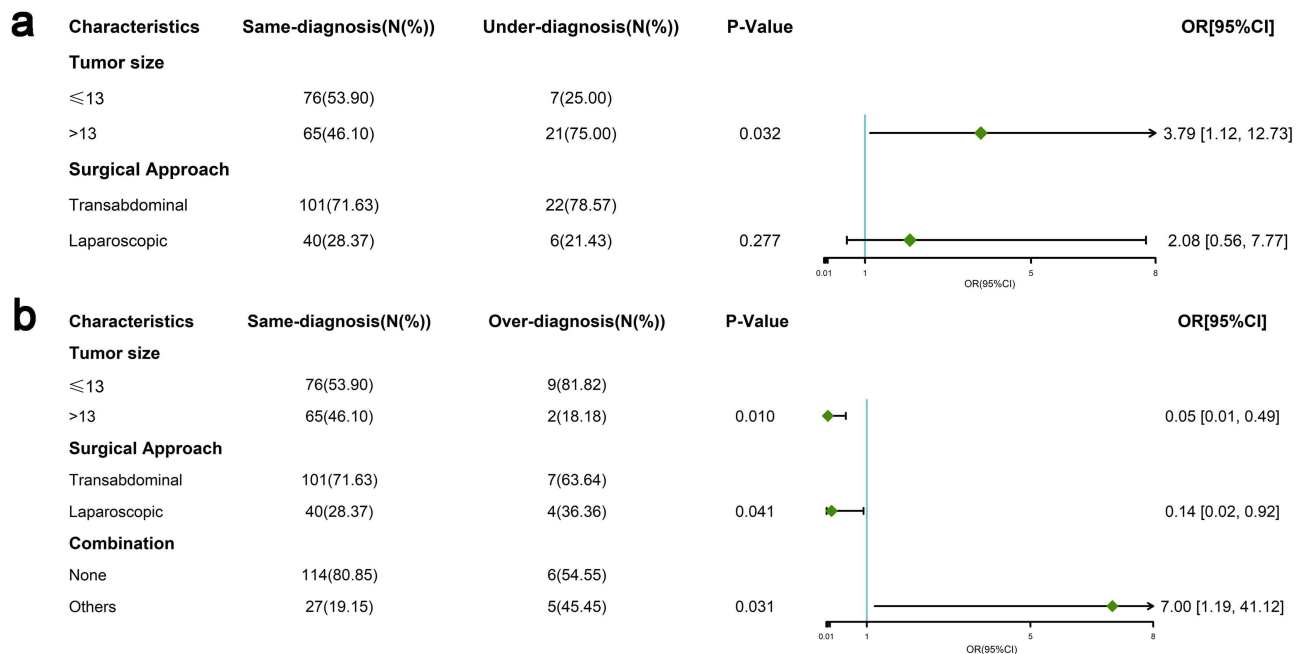


Figure 1 Forest plot of multivariate analysis for risk factors of diagnostic discordance between FS and PS. Odds ratio > 1 indicates a higher risk, and odds ratio < 1 indicates a lower risk. **(a)** under-diagnosis; **(b)** over-diagnosis. **Abbreviations:** OR, odds ratio; CI, confidence interval.

tumor components (including serous, Brenner tumor, and chocolate cyst; OR 7.00, 95% CI 1.19–41.12, $P = 0.031$) were independently associated with over-diagnosis.

Frozen section slides were reviewed for the reclassified cases on final pathology. Sampling issues caused under-diagnosis in large tumors rather than errors in interpretation. The FS slides in 19 cases showed mucinous cystadenoma but were reclassified as borderline mucinous tumors on PS (Figures S1 and S2). One case was diagnosed as mature cystic teratoma on FS, however, on final pathology, additional sections from the large mass revealed a borderline mucinous tumor (Figure 2). For malignant ovarian mucinous tumors, 8 out of 25 cases (32%) were diagnosed as borderline mucinous tumors because the areas of invasive carcinoma were not sampled on FS (Figure S3). All cases of over-diagnosis were suspected as borderline on FS and reclassified as benign on PS (Figure S4).

In the under-diagnosed group, one patient (3.57%) died due to the recurrence of the disease. For patients in the same-diagnosed group, 11 (7.80%) had a recurrence, and 1 (0.71%) finally died because of the disease, whereas none of the over-diagnosed group experienced a recurrence of cancer or death. The Kaplan-Meier PFS and OFS curves showed no statistical significance between misdiagnosed and accurately diagnosed patients (Figure 3, all $P > 0.05$).

Discussion

The priority of intraoperative rapid pathological diagnosis using frozen tissue sections is to determine the real-time surgical planning by providing reasonable information on benign or malignant. Inappropriate diagnosis may lead to severe consequences and cause difficulties in clinical treatment, so improving the accuracy of frozen pathological diagnosis is particularly critical.

The accuracy of FS can be affected by various factors, including sampling error, quality of the frozen section, and experience of pathologists.^{27,28} Most previous studies concluded that misdiagnosis was more common in mucinous tumors due to the large size and high heterogeneity, while it has also been suggested that tumor size does not correlate with the incorrect diagnosis of frozen pathology.^{29–32} The present study found that tumor size was an independent risk factor for misdiagnosis, either over-diagnosis or under-diagnosis. This may be because the entire ovarian tissue is permanently removed as completely as possible when performing debulking surgery for ovarian tumors, and the excessive tumor volume directly leads to an inaccurate extraction scope.

Moroney et al reported that discordance between FS and PS was associated with diagnoses other than benign, and 93.5% of discordant cases were borderline or malignant, compared with 30.5% of concordant cases.³³ Our study also proved that histopathology is one of the factors affecting the accuracy of frozen pathology. However, the sensitivity and PPV of FS diagnosis for malignant MOT were 100%, and the NPV and accuracy reached more than 95% in the present study. It suggests that frozen pathology is more accurate in diagnosing malignant MOT, which may be associated with the high specificity of malignant tumor cells. In a retrospective study of 1032 patients, Park et al stated that mixed tumor histology, multilocular tumor, and a solid component in the tumor were independent risk factors for PS diagnosis upgrade based on FS diagnosis, which was consistent with our study.³⁴ We found that the combination of other tumor components, including serous, Brenner tumor, and chocolate cyst, were independently associated with over-diagnosis.

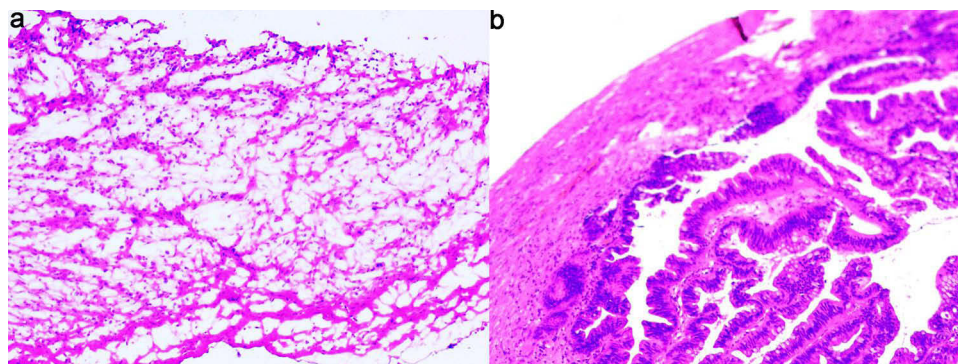


Figure 2 (a) FS showed areas of mature cystic teratoma; (b) borderline mucinous cystadenoma combined with mature cystic teratoma were noted on PS.

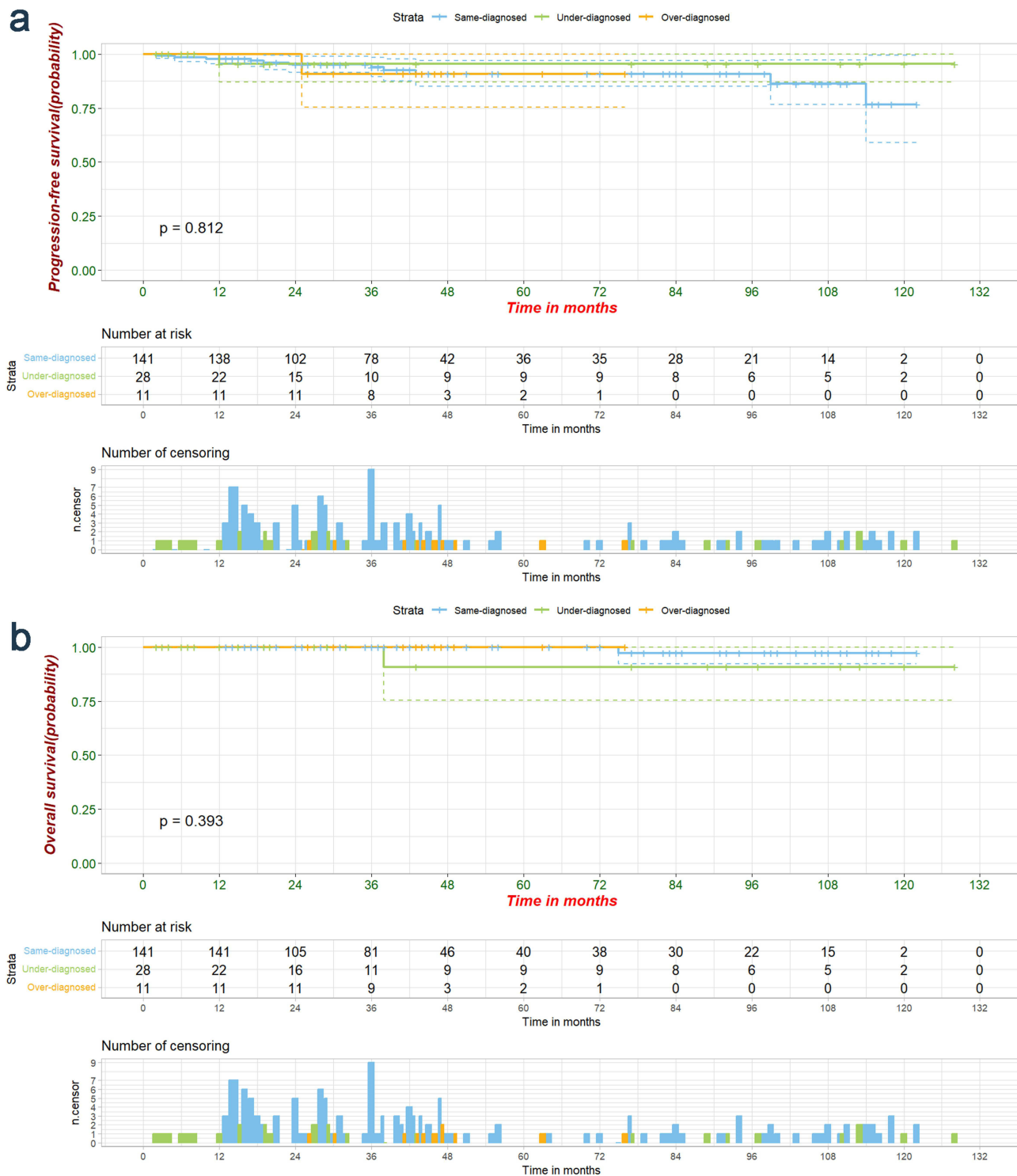


Figure 3 The progression-free (a) and overall (b) survival of patients between the subgroups divided by the diagnostic accuracy of FS.

The varied tumor components cause difficulties in the reading of FS. Thus, pathologists must have a high level of experience and expertise to make quick and accurate decisions.

Our results showed that the incorrect diagnosis of FS would affect the determination of the extent of surgery but had no impact on the patients’ long-term recurrence and survival outcomes. Similarly, Huang et al revealed that the clinical impacts of misdiagnosis by FS are minimal in MOT patients.³⁰ It may be related to the general choice among clinicians

to perform secondary surgery in the short term to enlarge the extent of lesion resection after under-diagnosis. The residual lesion was removed in time, resulting in the same clinical outcome as the first radical surgery.

The most crucial reason for the under-diagnosis of frozen pathology is improper sampling. Since the tumor volume is large, sampling at the edge or necrotic area can easily lead to under-diagnosis. Particularly for the MOT, the local differences in the lesions were highly significant because of the large size of the epithelial tumors. The structure of the lesion can not be sufficiently assessed if obtaining an inadequate amount of tissues, which is tempting to misdiagnose the pathology. For example, the biopsy for FS was taken from the low-grade areas of the malignant MOT, so the pathologist reported it as a borderline tumor, while examination of the tissue sent for PS revealed the high-grade characteristics of the tumor, and the diagnosis was changed to mucinous ovarian cancer.³⁵ Zhang et al found that the laterality of the tumor was associated with the underdiagnosis of malignant MOT, supporting that the sampling of frozen pathology directly impacted diagnostic accuracy.³⁶

In recent years, with the popularization of minimally invasive surgical procedures, most of the tumor tissues delivered through laparoscopic surgery are a mixture of solid tissue, papillae, and fragmented capsule walls. If only a portion of this mixture is taken for frozen pathology, it can lead to misdiagnosis and missed diagnosis. An incorrect FS diagnosis affects all aspects of surgery, from the surgical approach to whether fertility-preserving surgery is used. Since fertility-sparing surgery is only meaningful in patients with type I epithelial ovarian cancer, under-diagnosis may increase reoperation risk and, therefore, must be vigorously avoided.^{37,38}

Over-diagnosis is less frequent than under-diagnosis and occurs mainly in the pathologic diagnosis of borderline tumors.³¹ Because of the invasive nature of borderline tumors, they are easily misdiagnosed as ovarian cancer, with a higher rate of misdiagnosis than benign and malignant tumors.^{39–41} In addition, the limitations of tissue-preparation conditions during surgery using frozen specimens are also associated with pathological misdiagnosis. The presence of unfixed cells, large cell size, and unclear cytoplasmic background in FS result in benign and borderline tumors that may be confused with well-differentiated high-grade tumors. Consequently, there is an urgent need to avoid over-diagnosis to prevent MOT patients from unnecessary surgical procedures and financial burdens.

Despite informing patients of the limitations of FS, we also recommend strengthening the communication between the surgeon and the pathologist during the operation to improve the pathological accuracy. Before the samples are sent for examination, the pathology test request form should be accurately completed, with detailed descriptions of the patient's basic information, medical history, history of related examinations, and treatment. Especially for women of childbearing age, menstrual status, marital status, and endocrine disorder should be recorded utterly. Surgeons need to clarify the tumor size, shape, location, anatomical relationship with adjacent organs, whether infiltration occurred, with or without ascites, and whether the tumor implants on the omentum. The above information should be recorded in detail on the pathology request form and communicated with the pathologist promptly so that the pathologist can make an accurate judgment. The mass removal from the surrounding tissue should be as complete as possible. Tissue samples should be collected from appropriate sites within surgically resected specimens without disturbing the features on which pathological diagnosis is based, avoiding hemorrhage or necrosis. The tissues with different textures should be sampled separately, and all the broken tissues should be sent for examination. Ascites fluid samples should be sent off promptly, which may have diagnostic value for malignant or borderline tumors with malignant transformation. The color of ascites and the heterogeneity of smear cells can assist in determining the benign or malignant nature of the tumor as well as the origin of the tissue.

A well-experienced pathologist familiar with the histologic pattern of different MOT types is indispensable to the treatment team. When encountering suspicious cases, pathologists should perform special staining and communicate with clinicians to make a diagnosis by combining intraoperative information and clinical data, which can minimize the possibility of misdiagnosis. Meanwhile, frequently using words such as “not excluded” should be avoided so as not to confuse clinicians and thus affect clinical decision-making. If the pathologic diagnosis fails to match the clinical diagnosis, the tissue should be resampled and resubmitted for examination.

The retrospective nature and sample size limit the present study. As a single-center cohort of MOT patients, the time span of pathology diagnosis is large, which cannot comprehend the content of intraoperative communication between clinicians and pathologists.

Conclusion

In conclusion, this study investigated the factors affecting the diagnostic discordance between FS and PS in MOT and assessed clinical outcomes through long-term follow-up. Like other tumors, the frozen pathology of MOT had problems of under-diagnosis and over-diagnosis. The histologic subtype, laparoscopic surgery, tumor size, and combination of other tumor components were significantly correlated with the reclassification of pathologic diagnosis. Although misdiagnosis of FS affects the determination of surgical extent, it is irrelevant to patients' long-term recurrence and survival outcomes. We recommend paying attention to the accuracy of frozen pathology sampling and strengthening communication between the surgeons and the pathologists to reduce the rate of misdiagnosis, misoperation, and reoperations.

Acknowledgments

This manuscript has been released as a pre-print on Authorea and can be accessed at <https://doi.org/10.22541/au.170055030.09541126/v1>.

Disclosure

The authors report no conflicts of interest in this work.

References

- Purwoto G, Anggraeni TD, Rustamadji P, Surya IU, Julianti K, Herlambang N. Histopathological discrepancy and variation of surgical management in mucinous ovarian cystadenoma and pseudomyxoma peritonei. *Int J Surg Case Rep*. 2022;94:107141. doi:10.1016/j.ijscr.2022.107141
- Moon AS, DeAngelis AM, Fairbairn M, et al. Removal of 132-pound ovarian mucinous cystadenoma: a case report. *SAGE Open Med Case Rep*. 2020;8:2050313X2090673. doi:10.1177/2050313X20906738
- Frumovitz M, Schmeler KM, Malpica A, Sood AK, Gershenson DM. Unmasking the complexities of mucinous ovarian carcinoma. *Gynecologic Oncol*. 2010;117(3):491–496. doi:10.1016/j.ygyno.2010.02.010
- Hart WR. Mucinous tumors of the ovary: a review. *Int J Gynecol Pathol*. 2005;24(1):4–25.
- Koensgen D, Weiss M, Assmann K, et al. Characterization and management of borderline ovarian tumors - results of a retrospective, single-center study of patients treated at the department of gynecology and obstetrics of the University Medicine Greifswald. *Anticancer Res*. 2018;38(3):1539–1545. doi:10.21873/anticancer.12382
- Khunamornpong S, Settakorn J, Sukpan K, Suprasert P, Siriaunkgul S. Mucinous tumor of low malignant potential (“borderline” or “atypical proliferative” tumor) of the ovary: a study of 171 cases with the assessment of intraepithelial carcinoma and microinvasion. *Int J Gynecol Pathol*. 2011;30(3):218–230. doi:10.1097/PGP.0b013e3181fcf01a
- Koskas M, Uzan C, Gouy S, et al. Prognostic factors of a large retrospective series of mucinous borderline tumors of the ovary (Excluding Peritoneal Pseudomyxoma). *Ann Surg Oncol*. 2011;18(1):40–48. doi:10.1245/s10434-010-1293-8
- Colombo N, Sessa C, du Bois A, et al. ESMO-ESGO consensus conference recommendations on ovarian cancer: pathology and molecular biology, early and advanced stages, borderline tumours and recurrent disease†. *Ann Oncol*. 2019;30(5):672–705. doi:10.1093/annonc/mdz062
- Cadron I, Leunen K, Van Gorp T, Amant F, Neven P, Vergote I. Management of borderline ovarian neoplasms. *JCO*. 2007;25(20):2928–2937. doi:10.1200/JCO.2007.10.8076
- Franchi D, Boveri S, Radice D, et al. Ultrasonographic diagnosis and longitudinal follow-up of recurrences after conservative surgery for borderline ovarian tumors. *Am J Obstet Gynecol*. 2016;215(6):756.e1–756.e9. doi:10.1016/j.ajog.2016.07.024
- Nishio N, Kido A, Kataoka M, et al. Longitudinal changes in magnetic resonance imaging of malignant and borderline tumors associated with ovarian endometriotic cyst comparing with endometriotic cysts without arising malignancy. *Eur J Radiol*. 2018;105:175–181. doi:10.1016/j.ejrad.2018.06.007
- Huang Y, Xu J, Li K, Wang J, Dai Y, Kang Y. A novel, personalized drug-screening system for platinum-resistant ovarian cancer patients: a preliminary clinical report. *Cancer Manag Res*. 2021;13:2849–2867. doi:10.2147/CMAR.S276799
- Kyung MS. Serum CA19-9 as a predictor of malignancy in primary ovarian mucinous tumors: a matched case-control study. *Med Sci Monit*. 2014;20:1334–1339. doi:10.12659/MSM.890954
- Zhang T, Pang A, Lyu J, et al. Application of nonlinear models combined with conventional laboratory indicators for the diagnosis and differential diagnosis of ovarian cancer. *J Clin Med*. 2023;12(3):844. doi:10.3390/jcm12030844
- Sánchez Vega JF, Murillo Bacilio M, Vintimilla Condoy AS, Palta González AM, Crespo Astudillo JA, Mora-Bravo FG. Predictive equation of metastasis in patients with malignant ovarian epithelial tumors with the Ca-125 marker. *BMC Cancer*. 2018;18(1):587. doi:10.1186/s12885-018-4499-y
- Varras M. Benefits and limitations of ultrasonographic evaluation of uterine adnexal lesions in early detection of ovarian cancer. *Clin Exp Obstet Gynecol*. 2004;31(2):85–98.

17. Necula L, Matei L, Dragu D, et al. Collagen family as promising biomarkers and therapeutic targets in cancer. *Int J Mol Sci.* 2022;23(20):12415. doi:10.3390/ijms232012415
18. Wakahara F, Kikkawa F, Nawa A, et al. Diagnostic efficacy of tumor markers, sonography, and intraoperative frozen section for ovarian tumors. *Gynecol Obstet Invest.* 2001;52(3):147–152. doi:10.1159/000052963
19. Maheshwari A, Gupta S, Kane S, Kulkarni Y, Goyal BK, Tongaonkar HB. Accuracy of intraoperative frozen section in the diagnosis of ovarian neoplasms: experience at a tertiary oncology center. *World J Surg Oncol.* 2006;4(1):12. doi:10.1186/1477-7819-4-12
20. Huang J, Zhou H, Tan C, Mo S, Liu T, Kuang Y. The overexpression of actin related protein 2/3 complex subunit 1B(ARPC1B) promotes the ovarian cancer progression via activation of the Wnt/ β -catenin signaling pathway. *Front Immunol.* 2023;14:1182677. doi:10.3389/fimmu.2023.1182677
21. Armstrong DK, Alvarez RD, Bakkum-Gamez JN, et al. Ovarian cancer, version 2.2020, NCCN clinical practice guidelines in oncology. *J National Compr Cancer Network.* 2021;19(2):191–226. doi:10.6004/jnccn.2021.0007
22. Gershenson DM. Management of borderline ovarian tumours. *Best Pract Res Clin Obstet Gynaecol.* 2017;41:49–59. doi:10.1016/j.bpobgyn.2016.09.012
23. Berek JS, Kehoe ST, Kumar L, Friedlander M. Cancer of the ovary, fallopian tube, and peritoneum. *Intl J Gynecology & Obste.* 2018;143(S2):59–78. doi:10.1002/ijgo.12614
24. Gulzar R, Shahid R, Mumtaz S, Hassan JA. Significance of peritoneal washing cytology in the accurate staging of malignant ovarian tumors. *Pak J Med Sci.* 2022;38(1):128–132. doi:10.12669/pjms.38.1.4393
25. Vasconcelos I, De Sousa Mendes M. Conservative surgery in ovarian borderline tumours: a meta-analysis with emphasis on recurrence risk. *Eur J Cancer.* 2015;51(5):620–631. doi:10.1016/j.ejca.2015.01.004
26. Kim JH, Ha HI, Kim MH, Han MR, Park SY, Lim MC. A modified intraperitoneal chemotherapy regimen for ovarian cancer: technique and treatment outcomes. *Cancers.* 2021;13(19):4886. doi:10.3390/cancers13194886
27. Palakkan S, Augustine T, Valsan M, Vahab KA, Nair L. Role of frozen section in surgical management of ovarian neoplasm. *Gynecol Minim Invasive Ther.* 2020;9(1):13. doi:10.4103/GMIT.GMIT_2_19
28. Stewart CJR, Brennan BA, Hammond IG, Leung YC, McCartney AJ. Intraoperative assessment of ovarian tumors: a 5-year review with assessment of discrepant diagnostic cases. *Int J Gynecol Pathol.* 2006;25(3):216–222. doi:10.1097/01.pgp.0000215295.45738.ed
29. Gol M, Baloglu A, Yigit S, Dogan M, Aydin C, Yensel U. Accuracy of frozen section diagnosis in ovarian tumors: is there a change in the course of time? *Int J Gynecol Cancer.* 2003;13(5):593–597. doi:10.1136/ijgc-00009577-200309000-00004
30. Huang Z, Li L, Li C, et al. Diagnostic accuracy of frozen section analysis of borderline ovarian tumors: a meta-analysis with emphasis on misdiagnosis factors. *J Cancer.* 2018;9(16):2817–2824. doi:10.7150/jca.25883
31. Karataşlı V, Can B, Çakır İ, et al. Effect of tumor size on the accuracy of frozen section in the evaluation of mucinous borderline ovarian tumors. *J Gynecol Obstet Hum Reprod.* 2020;49(6):101765. doi:10.1016/j.jogoh.2020.101765
32. Basaran D, Salman MC, Boyraz G, et al. Accuracy of intraoperative frozen section in the evaluation of patients with adnexal mass: retrospective analysis of 748 cases with multivariate regression analysis. *Pathol Oncol Res.* 2015;21(1):113–118. doi:10.1007/s12253-014-9795-5
33. Moroney MR, Post MD, Berning AA, Sheeder J, Corr BR. An evaluation of frozen section and lymph node dissection results for mucinous ovarian tumors. *Int J Gynecol Cancer.* 2018;28(1):92–98. doi:10.1097/IGC.0000000000001150
34. Park JY, Lee SH, Kim KR, Kim YT, Nam JH. Accuracy of frozen section diagnosis and factors associated with final pathological diagnosis upgrade of mucinous ovarian tumors. *J Gynecol Oncol.* 2019;30(6):e95. doi:10.3802/jgo.2019.30.e95
35. Pongsuvareeyakul T, Khunamornpong S, Settakorn J, Sukpan K, Suprasert P, Siriaunkgul S. Accuracy of frozen-section diagnosis of ovarian mucinous tumors. *Int J Gynecol Cancer.* 2012;22(3):400–406. doi:10.1097/IGC.0b013e31823dc328
36. Zhang W, Jia S, Xiang Y, Yang J, Jia C, Leng J. Factors associated with misdiagnosis of frozen section of mucinous borderline ovarian tumor. *J Int Med Res.* 2019;47(1):96–104. doi:10.1177/0300060518795582
37. Jiang X, Yang J, Yu M, et al. Oncofertility in patients with stage I epithelial ovarian cancer: fertility-sparing surgery in young women of reproductive age. *World J Surg Oncol.* 2017;15:154. doi:10.1186/s12957-017-1222-4
38. Groen RS, Gershenson DM, Fader AN. Updates and emerging therapies for rare epithelial ovarian cancers: one size no longer fits all. *Gynecologic Oncol.* 2015;136(2):373–383. doi:10.1016/j.ygyno.2014.11.078
39. Gadducci A, Tana R, Landoni F, et al. Analysis of failures and clinical outcome of advanced epithelial ovarian cancer in patients with microscopic residual disease at second-look reassessment following primary cytoreductive surgery and first-line platinum-based chemotherapy. *Eur J Gynaecol Oncol.* 2013;34(3):213–217.
40. Ureyen I, Turan T, Cirik DA, et al. Frozen section in borderline ovarian tumors: is it reliable? *Eur J Obstetrics Gynecol Reprod Biol.* 2014;181:115–118. doi:10.1016/j.ejogrb.2014.07.039
41. Tempfer CB, Polterauer S, Bentz EK, Reinhaller A, Hefler LA. Accuracy of intraoperative frozen section analysis in borderline tumors of the ovary: a retrospective analysis of 96 cases and review of the literature. *Gynecol Oncol.* 2007;107(2):248–252. doi:10.1016/j.ygyno.2007.06.008