

Fourth-generation spinal instrumentation: experience with adolescent idiopathic scoliosis at a tertiary care hospital in Pakistan

Akil Fazal¹
Riaz H Lakdawala²

¹Hospital for Joint Disease, New York University, New York, USA; ²Section of Orthopaedics, Department of Surgery, The Aga Khan University Hospital, Karachi, Pakistan

Objective: To evaluate the radiological and functional outcome of surgical treatment of adolescent idiopathic scoliosis using fourth-generation posterior spinal instrumentation at The Aga Khan University, Karachi, Pakistan.

Design: Case series.

Place and duration of study: The Aga Khan University Hospital after a minimum of 2 years postoperatively.

Patients and methods: A total of 20 patients with adolescent idiopathic scoliosis were recruited into the study and evaluated for radiological and functional outcome. The study period was from 2000 to 2005. Radiological outcome was assessed using Cobb angle measurement pre and postoperatively, hence assessing percentage correction. The lower instrumented vertebra was taken as the neutral vertebra and the level was recorded. Functional outcome was determined using the Scoliosis Research Society patient administered questionnaire. All patients were called to the clinic and asked to fill in the form. Those patients who were out of the city were mailed the forms and requested via telephone to complete and return.

Results: Of the 20 patients operated on, twelve were female and eight were male. The average age at operation was 12.7 years. The mean Cobb angle was 69° preoperatively and 20° postoperatively, representing a percentage correction of 71%. The average duration of follow-up was 3.6 years. There was one major complication involving neurological injury post-op and two minor complications involving wound infection. The average Scoliosis Research Society score (on a scale of 1–5, with 5 being best) for pain was 4.5, self-image was 4.2, functional status was 4.1, mental status was 3.8, and satisfaction was 4.4. There was no relationship between the percentage correction of scoliosis and the functional outcome. Those patients with a high preoperative Cobb angle tended to have a better outcome for functional and mental status postoperatively. There was no relation between the lower instrumented vertebra and functional outcome.

Conclusion: In the correct indications, fourth-generation posterior instrumentation and fusion is a reliable and satisfactory technique to treat adolescent idiopathic scoliosis.

Keywords: scoliosis, adolescent, idiopathic, spine, instrumentation, Pakistan

Introduction

Idiopathic scoliosis is the most common type of spinal deformity confronting orthopedic surgeons. Its onset is usually insidious, its progression often relentless, and its results may be deadly.¹ Thus, timely recognition and treatment of idiopathic scoliosis is essential to optimize patient outcomes.

Scoliosis is the presence of one or more lateral rotatory curves measuring >10° of the spine as measured by the Cobb method in the coronal plane. Although defined as a side-to-side deformity, it is actually a three-dimensional rotational deformity. Many causes

Correspondence: Akil Fazal
NYU-Hospital for Joint Disease,
301 East 17th Street, New York,
NY 10003, USA
Email akilfazal@gmail.com

of scoliosis are known; however, 80% of cases are idiopathic. According to age distribution, scoliosis is described in three forms: infantile, juvenile, and adolescent.²

The adolescent form, which is the subject of this paper, is seen between 10 years of age and maturity. This is the most common type of idiopathic scoliosis, accounting for 80% of all cases.³

Scoliosis results in cosmetic deformity, disability, pain, and severe restriction of the patient's capacity to work. Cardiorespiratory compromise occurs in severe scoliosis (curves $>60^\circ$) typically in the form of cor pulmonale.⁴

The magnitude of the curve is best determined by measurement of the Cobb angle, which is derived from a standard posteroanterior standing radiograph of the spine.⁵

Management consists of observation, bracing, and operative treatment. As per international guidelines, curves $<25^\circ$ are observed. Those between 25° and 40° are braced and those above 40° undergo surgery.⁶

Surgical correction was revolutionized by Harrington in 1962 who introduced the first effective instrumentation system for scoliosis.⁷ For more than 30 years, use of the Harrington distraction rod, combined with a thorough posterior arthrodesis and immobilization in a cast or brace for 6 to 9 months, had been the standard surgical treatment for adolescent idiopathic scoliosis. Despite its success, the Harrington instrumentation system has several disadvantages including implant displacement, poor sagittal contour, and the need for post-op bracing.

These problems paved the way for second-generation implant systems which involved attaching sublaminar wires to the Harrington rods to help maintain lordosis as distraction is applied.⁸ In spite of these techniques, distraction across the lumbar spine inevitably leads to the loss of some degree of lumbar lordosis, plus there was the added risk of neurological injury as the wires were inserted.

Third-generation implants consists of instrumentation with the Cotrel-Dubousset system. This construct uses segmental hooks reinforced with cross-linked double rods. It has many advantages over first and second-generation instrumentation, in that no postoperative bracing is required and correction is achieved in all three planes – frontal, sagittal, and horizontal.⁹ It also has a lower rate of implant failure and pseudarthrosis. (See Figure 1).

The development of monoaxial and polyaxial pedicle screws led to the development of fourth-generation instrumentation which we have used in our patients.¹⁰ This is similar to the Cotrel-Dubousset system but the screws used have an enormous pull-out strength compared to standard hooks, which makes the construct very strong.¹¹

The aim of this study was to assess the radiological and functional outcomes of patients operated on for adolescent idiopathic scoliosis. Radiological outcome was determined by measurement of the Cobb angle preoperatively and postoperatively to calculate percentage correction of deformity. Functional outcome was determined using the Scoliosis Research Society questionnaire (SRS-24),¹² a patient administered questionnaire which objectively scores the patients on five functional domains: pain, self-image, activity, mental health, and satisfaction with management. This is scored from 1–5, with 5 being best.

Methods

This is a case series study of all patients with adolescent idiopathic scoliosis who had been operated on at the Aga Khan University Hospital using fourth-generation instrumentation (Medtronic Corp, Minnesota, MN) with a minimum 2-year follow-up from 2000 to 2005.

Exclusion criteria included those patients who were not adolescents; who had a type of scoliosis different from idiopathic; who did not have a 2 year minimum follow-up; and

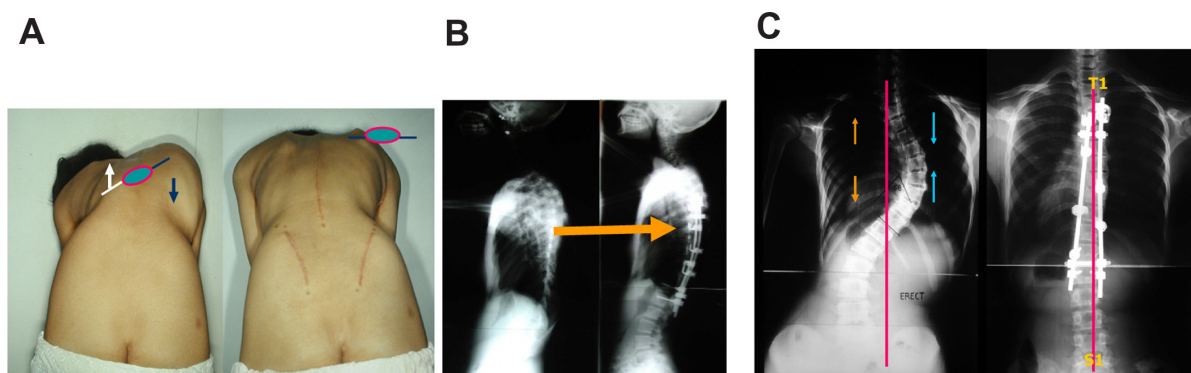


Figure 1 (A) Horizontal plane correction, (B) sagittal plane correction, (C) frontal plane correction.

who did not have fourth-generation spinal instrumentation employed.

Cases that had been operated on for scoliosis were identified through the hospital in-patient database. Data collection and analysis was done by a single researcher (AF) who had not been part of the surgical team. Basic demographic data of all patients was retrieved from medical record files.

Surgery was carried out by a single surgeon (RL). Intraoperative monitoring of somatosensory evoked potentials was performed for continuous observation of spinal cord function, especially during screw insertion and manipulations when injury to the cord may occur. This was supplemented with Stagnara's wake-up test.¹³ (Figure 2).

The upper instrumented level was the upper end vertebra and lower instrumented level was the neutral vertebra. Standard surgical techniques were followed, consisting of exposure of the spine from tip to tip of the spinous process of upper and lowermost affected vertebrae. This was followed by facetectomy. Pedicle screws were then placed at each level, and a concave rod contoured to physiological kyphosis engaged and turned through 90°. This achieves sagittal and horizontal plane correction. This is followed by sequential distraction on the concave side and compression on the convex side to correct frontal plane balance and therefore achieve a three dimensional correction. Bone graft was taken from either the iliac crest or the tips of the spinous processes of the vertebrae and placed around the instrumentation to facilitate fusion. In no patient was costoplasty done.

We studied two main outcome variables – radiographic and functional. Radiographic data was assessed by measuring the Cobb angle on the anteroposterior radiographs. The Cobb

angle is the angle formed by a line drawn perpendicular to the upper vertebra upper end plate of the scoliotic curve and a similar perpendicular line drawn from the lower vertebra lower end plate.

Preoperative Cobb angle was then compared to the postoperative Cobb angle to calculate the percentage change. In our service, postoperative X-rays are normally done on the second or third post-op day when the patient has been mobilized.

The lower instrumented vertebra for each surgery was also recorded.

The Scoliosis Research Society questionnaire, as modified by Asher in 2000, was used as our functional outcome measurement tool.¹² The questionnaire is a disease-specific, reliable, and validated questionnaire used to assess outcomes in adolescent idiopathic scoliosis. The questionnaire consists of 24 questions designed to assess five domains: pain, self-image/appearance, function/activity, mental health, and satisfaction with surgery. All questions are rated 1 to 5, with 5 being the optimal response. For the purpose of our statistical analysis, each domain was analyzed using a mean score as has been done in other similar studies.¹⁴

All patients in our study were invited for a free follow-up clinic at our hospital where they were asked to fill out the questionnaire. Those patients who were out of the city had the forms mailed to them and were reminded via telephone to complete and return the forms.

Statistics

The data was analyzed using SPSS (SPSS version 14.0; IBM, Armonk, NY). Analyses were performed for correlations between the Cobb angle, percentage improvement,

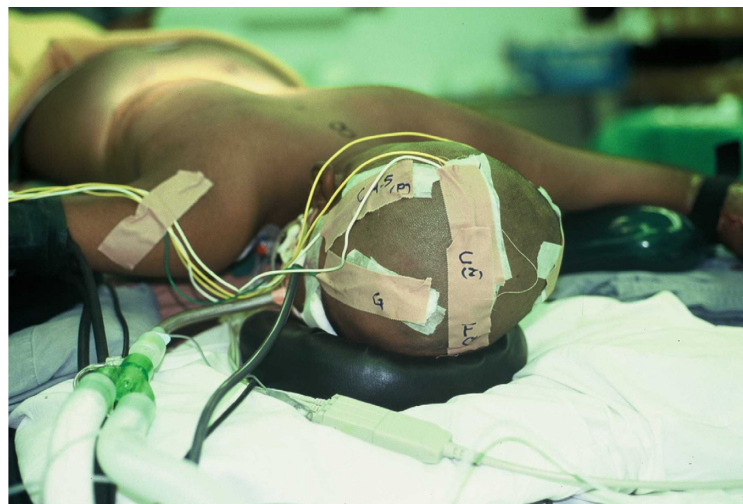

Figure 2 Setup for intraoperative somatosensory evoked potentials monitoring, which involves stimulating electrodes attached to the feet and recording electrodes on the scalp.

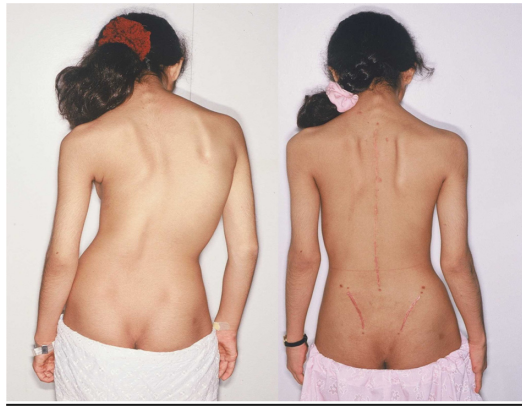

Figure 3 Thirteen-year-old female before and after correction and fusion with posterior iliac crest grafting.

and functional outcome using Spearman's rank correlation. A *P*-value of less than 0.05 was taken to be significant.

Results

A total of 20 patients matched the inclusion criteria. Twelve were female and eight were male. The average age was 12.7 ± 3 years. The mean follow-up was 3.6 years (range 2 months to 8 years).

The average preoperative Cobb angle was $69^\circ \pm 18^\circ$ and the average postoperative angle was $20^\circ \pm 5^\circ$. This represents a percentage correction of $71^\circ \pm 9^\circ$.

Three patients had a lower instrument vertebra level of L2, twelve of L3, and five of L4. The lower instrument vertebra did not have any impact on functional outcome at 2 years.

The average scores on the Scoliosis Research Society questionnaire on a scale of 1–5 (5 being best) were 4.5 for pain, 4.2 for self-image, 4.1 for function, 3.8 for mental

health status, and 4.4 for satisfaction with treatment. (Table 1).

Analysis was performed for correlations between the Cobb angle, percent correction and pain, self-image, mental score, function score, and satisfaction. Significant correlation ($P < 0.05$) was found between a high preoperative Cobb angle and subsequent favorable postoperative improvement in mental health (Spearman's $R = 0.4$, $P < 0.05$) and functional status (Spearman's $R = 0.4$, $P < 0.05$). However, no correlation was found between the percentage correction and postoperative functional scores.

There were three complications noted. One patient had a neurological injury consistent with weakness of the right hip flexion postoperatively. This was investigated with CT scan and found to be a malpositioned L2 pedicle screw, which was subsequently revised. This patient had 90% neurological recovery at 2 years. There were two cases of superficial wound infection. One case settled with intravenous antibiotics, whilst the other required one visit to the operating room for a wound washout.

Discussion

Fourth-generation instrumentation and fusion for the correction of adolescent idiopathic scoliosis has only recently become available in Pakistan. This is the first study of its kind in this country that has evaluated the outcome of this nature of surgical treatment.

In the radiological outcome score, the percentage correction of 71% was on par with other studies on the same subject.¹⁷ An important observation is that there was no correlation between percentage correction and postoperative functional scores. Therefore, those with larger correction don't necessarily do better functionally. This goes with the traditional axiom in scoliosis surgery that the surgeon should only correct to a point that is safe to do so. Overzealous correction does not yield better results and may predispose the young patients to postoperative complications, especially neurological injury.

This study, however, only looked at correction in the antero-posterior plane. Future studies should look at correction in other planes as well.

Most of the patients scored as well for functional outcome. Patients scored us more than 4/5 on four criteria: pain, self-image, function, and satisfaction with treatment. This is consistent with findings in other studies (Table 1).

There was a positive correlation between a high preoperative Cobb angle and subsequent improvement in postoperative mental and functional scores. Patients with large Cobb

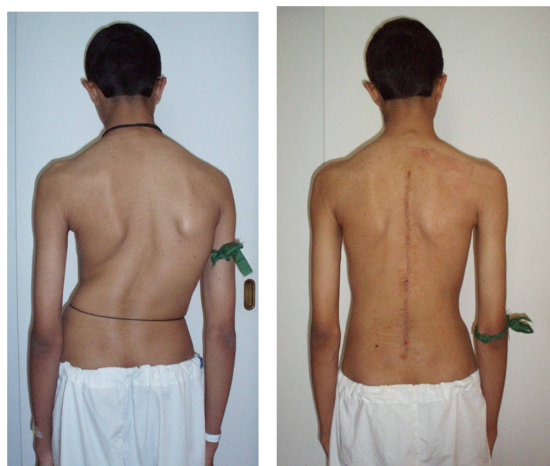

Figure 4 Fourteen-year-old boy after posterior correction and fusion using local bone.

Table 1 SRS scores from different studies

Study	Number of patients	Pain	Self-image	Function	Mental health	Satisfaction with treatment
Asher et al ¹²	30	4.21	4.20	4.27	3.91	4.4
Merola et al ¹⁵	242	4.63	4.5	4.33	3.82	4.7
Marc et al ¹⁶	58	4.1	4.3	3.9	4.2	4.5
This study	20	4.5	4.2	4.1	3.8	4.4

angles are known to have lower levels of activity and self-esteem.¹⁸ Correction of curves in this population therefore understandably has a more profound effect on the patient.

Though in this study the lower instrumented vertebra did not have an outcome on functional status, other studies have shown that patients fused to L4 and below had poorer outcome scores for function and pain.¹⁹ Most of these studies were of long term follow-up when problems with long fusions tend to manifest. As our follow-up period was 2 years only, this may not capture the long-term scenario.

Conclusion

Scoliosis surgery can be done safely and effectively in a developing country like Pakistan. As more orthopedic surgeons receive training and the cost of implants becomes affordable, it is reasonable to expect that scoliosis surgery will become more readily available in other developing countries.

Disclosure

The authors report no conflicts of interest in this work.

References

- Theologis TN, Fairbank JC, Turner-Smith AR, Pantazopoulos T. Early detection of progression in adolescent idiopathic scoliosis by measurement of changes in back shape with the Integrated Shape Imaging System scanner. *Spine (Phila Pa 1976)*. 1997;22(11):1223–1227.
- Lenke LG, Betz RR, Harms J, et al. Adolescent idiopathic scoliosis: a new classification to determine extent of spinal arthrodesis. *J Bone Joint Surg Am*. 2001;83-A(8):1169–1181.
- Roach J. Adolescent idiopathic scoliosis. *Orthop Clin North Am*. 1999;30(3):353–365.
- Swank SM, Winter RB, Moe JH. Scoliosis and cor pulmonale. *Spine (Phila Pa 1976)*. 1982;7(4):343–354.
- Peterson LE, Nachemson AL. Prediction of progression of the curve in girls who have adolescent idiopathic scoliosis of moderate severity. Logistic regression analysis based on data from The Brace Study of the Scoliosis Research Society. *J Bone Joint Surg Am*. 1995;77(6):823–827.
- Lonstein JE. Adolescent idiopathic scoliosis. *Lancet*. 1994;344:1407–1412.
- Harrington PR. Treatment of scoliosis. Correction and internal fixation by spine instrumentation. *J Bone Joint Surg*. 1962;44-A:591–610.
- La Grone MO. Loss of lumbar lordosis. A complication of spinal fusion for scoliosis. *Orthop Clin North Am*. 1988;19(2):383–393.
- Ghanem I, Hagnere F, Dubousset J, et al. Intraoperative optoelectronic analysis of three-dimensional vertebral displacement after cotrel-dubousset rod rotation. A preliminary report. *Spine (Phila Pa 1976)*. 1997;22(16):1913–1921.
- Webb J, Burwell R, Cole A, Lieberman I. Posterior instrumentation in scoliosis. *Euro Spine J*. 1995;4(1):2–5.
- Hamill CL, Lenke LG, Bridwell KH. Use of pedicle screw fixation to improve correction in the lumbar spine in patients with idiopathic scoliosis. *Is it warranted? Spine (Phila Pa 1976)*. 1996;21(10):1241–1249.
- Asher MA, Min LS, Burton DC. Further development and validation of the Scoliosis Research Society (SRS) outcomes instrument. *Spine (Phila Pa 1976)*. 2000;25(18):2381–2386.
- Owen J. The application of intraoperative monitoring during surgery for spinal deformity. *Spine (Phila Pa 1976)*. 1999;24(24):2649–2662.
- Raed A, Boachie A, Bernard A. Functional and radiological outcomes after surgery for adult scoliosis using third-generation instrumentation techniques. *Spine (Phila Pa 1976)*. 2003;28(11):1163–1170.
- Merola A, Haher T, Brkaric M, et al. A multicenter study of the outcomes of the surgical treatment of adolescent idiopathic scoliosis using the Scoliosis Research Society (SRS) outcome instrument. *Spine (Phila Pa 1976)*. 2002;27(18):2046–2051.
- Marc A, Min Lai S, Burton D. Scoliosis research society-22 patient questionnaire: responsiveness to change associated with surgical treatment. *Spine (Phila Pa 1976)*. 2003;28(1):70–73.
- D'Andrea L, Betz R, Lenke L, et al. Do radiographic parameters correlate with clinical outcomes in adolescent idiopathic scoliosis? *Spine (Phila Pa 1976)*. 2000;25(14):1795–1802.
- Payne W, Ogilvie J, Resnick M, et al. Does scoliosis have a psychological impact and does gender make a difference. *Spine (Phila Pa 1976)*. 1997;22(12):1380–1384.
- Sanchez-Raya J, Bago J, Pellise F, Cuxart A, Villanueva C. Does the lower instrumented vertebra have an effect on lumbar mobility, subjective perception of trunk flexibility, and quality of life in patients with idiopathic scoliosis treated by spinal fusion? *J Spinal Disord Tech*. 2011. [Epub ahead of print.]

International Journal of General Medicine

Publish your work in this journal

The International Journal of General Medicine is an international, peer-reviewed open-access journal that focuses on general and internal medicine, pathogenesis, epidemiology, diagnosis, monitoring and treatment protocols. The journal is characterized by the rapid reporting of reviews, original research and clinical studies across all disease areas.

Submit your manuscript here: <http://www.dovepress.com/international-journal-of-general-medicine-journal>

Dovepress

A key focus is the elucidation of disease processes and management protocols resulting in improved outcomes for the patient. The manuscript management system is completely online and includes a very quick and fair peer-review system. Visit <http://www.dovepress.com/testimonials.php> to read real quotes from published authors.