

Recurrent Posterior Capsular Opacification in Adults: A Case Report and an Overview of Literature

Majid Moshirfar^{1,3}, Alex H Brown⁴, Garrett N Manion⁵, Kayvon A Moin¹, Phillip C Hoopes¹

¹Hoopes Vision Research Center, Hoopes Vision, Draper, UT, USA; ²John A. Moran Eye Center, University of Utah School of Medicine, Salt Lake City, UT, USA; ³Utah Lions Eye Bank, Murray, UT, USA; ⁴Department of Ophthalmology, University of Arizona College of Medicine – Phoenix, Phoenix, AZ, USA; ⁵Department of Ophthalmology, Creighton University School of Medicine, Omaha, NE, USA

Correspondence: Majid Moshirfar, Hoopes Vision Research Center, 11820 S State St #200, Draper, UT, 84020, USA, Tel +1 801-568-0200, Fax +1 801-563-0200, Email cornea2020@me.com

Abstract: Posterior capsular opacification (PCO), also known as “secondary cataract”, is a common complication following cataract surgery that can significantly impair visual acuity. The incidence of PCO varies widely in the literature, influenced by intraocular lens (IOL) type and patient risk factors. Neodymium-doped yttrium-aluminum-garnet (YAG) laser posterior capsulotomy is the standard treatment for PCO-related visual impairment. Recurrence of PCO after initial treatment with YAG capsulotomy, though more common in children, is rare in adults. Its underlying pathophysiological mechanisms are similar to that of primary PCO, which includes proliferation, migration, and/or clustering of lens epithelial cells (LECs), with subsequent reclosure of the posterior aperture. Potential risk factors for PCO recurrence that have been speculated through a comprehensive search of the current literature include younger age, female sex, high myopia, diabetes, vitrectomized status, uveitis, low-diopter IOLs, and certain IOL types with higher water content. We present a case of recurrent PCO in a highly myopic 48-year-old male following cataract surgery and implantable collamer lens (ICL) explantation who received a hydrophobic acrylic lens with 4% water content. Surgical techniques that may reduce recurrent PCO occurrence and appropriate postoperative care are emphasized to assist surgeons in their approach to patients at high-risk for this complication.

Keywords: recurrent posterior capsule opacification, recurrent PCO, implantable collamer lens, ICL, repeat neodymium-doped yttrium-aluminum-garnet, repeat Nd:YAG, cataract surgery, posterior capsule reclosure, posterior capsule re-opacification, intraocular lens water content, IOL water content

Introduction

Posterior capsular opacification (PCO), or “secondary cataract”, is a well-known and common complication that can occur following cataract surgery and can lead to a significant decrease in visual acuity. The rate of PCO occurrence after cataract surgery at six months, one, three, five, and nine years has been reported as 2.1%, 4.0%, 18.0%, 31.2%, and 43.5%, respectively.¹ However, the rate of PCO formation varies widely in the literature depending on the intraocular lens (IOL) type and patient risk factors.^{2,3}

PCO has been categorized into two main types: fibrous and pearl.⁴ The fibrous type is caused by the proliferation and migration of lens epithelial cells (LECs) that have undergone epithelial-to-mesenchymal transition (EMT), causing folds and wrinkles in the posterior capsule. The pearl type is due to residual LECs from the equatorial lens region that cluster together and form Elschnig pearls, easily seen in retro-illumination.^{5,6} Both types of PCO can lead to a decrease or obstruction of the visual axis. The treatment for a visually significant PCO, regardless of type, is generally neodymium-doped yttrium-aluminum-garnet (YAG) laser capsulotomy.⁷

There have been several reports in the literature of PCO recurring after a prior YAG capsulotomy.^{8–21} Various terms have been used to name this complication, such as “posterior capsule reopacification”,^{9,13} “recurrent PCO”,¹⁷ “posterior capsule aperture reclosure”,²¹ “regenerative PCO”,¹⁵ “after after-cataract”,¹⁹ and “secondary closure of posterior capsulotomy”.¹²

These terms are interchangeable and refer to the repeated obstruction of the posterior aperture following a YAG capsulotomy. PCO recurrence that impacts the visual axis and requires a second YAG capsulotomy treatment, although common in children, is rare in adults.²² Studies reporting the incidence of repeat YAG capsulotomy due to re-opacification in adult patients vary, ranging between 0.31% and 0.7% of patients that initially required YAG capsulotomy treatment.^{9,18}

While risk factors of primary PCO have been thoroughly investigated, those associated with PCO recurrence remain poorly understood due to the infrequency of the event and the scarcity of literature on the subject.^{1,6,17,23–26} Studies have indicated that several factors may be associated with recurrence, including IOLs with higher water content, younger age, female sex, diabetes, vitrectomized status, and uveitis.^{8,9,14,15,18,21}

We present the case of a patient who developed recurrent PCO after combined cataract surgery and implantable collamer lens (ICL) explantation that required a second YAG capsulotomy. We also provide an overview of the existing literature on recurrent PCO to assist in a more comprehensive understanding of this rare complication and its associated risk factors.

Case Report

A healthy 48-year-old male with a non-contributory medical history and no systemic medications presented for evaluation of decreased visual acuity and monocular diplopia in the right eye. His past ocular history was significant for ICL surgery eight years prior in both eyes for high myopia ($-8.25\text{ D} -2.50\text{ D} \times 178^\circ$ OD and $-8.00\text{ D} -3.25\text{ D} \times 175^\circ$ OS). Examination revealed an uncorrected distance visual acuity (UDVA) of 20/60 OD and 20/25 OS and a best-corrected distance visual acuity (BDVA) of 20/30 OD and 20/20 OS. His manifest refraction was $0.00\text{ D} -1.00\text{ D} \times 12^\circ$ OD and $+0.50\text{ D} -1.00 \times 170^\circ$ OS. Slit-lamp examination (SLE) revealed a central anterior subcapsular cataract in his right eye. Preoperative biometric indices were axial length of 27.09 mm, K1 of 42.21 D, K2 of 42.66 D, and anterior chamber depth of 3.12 mm. The ICL vault at the time of cataract surgery was 260 μm centrally using anterior segment optical coherence tomography. The decision was made after informed consent to proceed with ICL explantation and concurrent cataract extraction. The IOL selection was performed with the ESCRS IOL Calculator (<https://iolcalculator.es CRS.org>; London, United Kingdom). Of note, as this patient was highly myopic and at high-risk for retinal detachment and other complications, a dilated fundus examination was performed before and after all surgical procedures presented in this case report, including both YAG capsulotomies. No significant retinal findings or complications were observed in any of these examinations.

At the time of surgery, a 2.4 mm temporal clear corneal incision was created followed by the injection of a dispersive viscoelastic agent to protect the endothelium and maintain the anterior chamber. A cohesive viscoelastic agent was injected between the ICL and crystalline lens. An O’Gawa instrument was used to carefully lift the proximal end of the ICL away from the crystalline lens to avoid inadvertent damage to the capsular integrity. The two proximal foot plates were brought over the iris in the vicinity of the corneal incision. Subsequently, the ICL was grasped by 0.12 mm-toothed forceps, folded upon itself, and carefully removed from the anterior chamber through the corneal incision. Additional dispersive viscoelastic agent was injected into the anterior chamber through the same incision. A 5.5 mm continuous curvilinear capsulorhexis (CCC) was then successfully created. Using an irrigation cannula, hydrodissection and hydrodelineation were performed. The cataract and cortical lens material were subsequently removed using phacoemulsification and irrigation and aspiration handpieces followed by thorough anterior, posterior, and equatorial capsular polishing using bimanual technique, as well as further capsular polishing utilizing a curved 27-gauge Jensen capsule polisher cannula (Ambler Surgical, Exton, PA, USA). Cohesive viscoelastic agent was then injected into the capsular bag. A one-piece Bausch & Lomb (St. Louis, MO, USA) enVista[®] MX60E 12.0 D IOL was placed inside the capsular bag in such a manner that the entire optic edge was completely covered with the overlying CCC. Any residual viscoelastic agent was then removed. All wounds were confirmed to be self-healing. The surgical procedure was uneventful and well tolerated.

The patient was placed on moxifloxacin 0.5% ophthalmic solution, four times daily for one week. Prednisolone acetate 1% ophthalmic suspension drops were used four times daily, which were tapered weekly over one month following surgery. Ketorolac 0.5% ophthalmic solution was used twice daily for six weeks. His postoperative course continued as expected. The patient’s 1-month and 1-year postoperative manifest refractions were both -1.00 D sphere OD, UDVA 20/50, and BDVA 20/15.

Two years and seven months after cataract surgery, the patient presented with complaints of blurred vision in his right eye for several months. UDVA in the right eye was 20/60 and BDVA was 20/25. SLE showed a fibrous and wrinkled PCO without evidence of Elschnig pearls in the right eye. The decision was made after informed consent to proceed with YAG capsulotomy.

After sufficient dilation, an uneventful YAG capsulotomy was performed with the UltraQ machine (Ellex, Minneapolis, MN, USA). A cruciate pattern was created in single pulse mode at 4.0 mJ power. Brimonidine 0.2% solution was administered following the procedure. The eye pressure was confirmed to be normal at 15 mmHg. He was prescribed prednisolone acetate 1% ophthalmic suspension four times daily for four days. His 1-week postoperative refractive and visual outcomes were -1.00 D sphere OD, UDVA 20/40, and BDVA 20/15.

The patient returned eight months later with a gradual decline in vision over several months. SLE revealed a recurrent PCO in his right eye. Elschnig pearls were present on the edge of the original capsulotomy opening, and the area within the original capsulotomy was opacified by a thin fibrous membrane (Figure 1a–c). This was treated by repeat YAG capsulotomy following the same procedure above, using single pulse mode at 3.8 mJ power. At the 1-week and 3-month follow-up visits, the patient remained asymptomatic with no signs of recurrent posterior fibrous membrane formation and subjective and objective improvement in visual acuity.

Discussion

A systematic search for articles regarding recurrent PCO was conducted. The databases utilized for this search included PubMed, Scopus, and Google Scholar, which were last accessed on April 18, 2024. A representation of our search strategy is included in Figure 2. The following search terms were used: (recurrent OR reopacification OR close OR secondary closure OR regenerat* OR Elschnig OR proliferat*) AND (PCO OR posterior capsule OR posterior capsule opacific*) AND (YAG OR neodymium OR capsulotomy). The initial search yielded 716 total articles across all databases. Two authors (AB and GM) independently reviewed and included any studies that reported eyes with visually obstructing, recurrent PCO that required a second YAG capsulotomy or other surgical intervention in adult patients. Abstracts and titles were screened by those that appeared relevant to recurrent PCO. Duplicate studies, irrelevant articles, animal studies, non-English publications, studies with PCO formation after primary posterior capsulorhexis, and studies with only cases of recurrent PCO without surgical intervention were excluded. After these exclusions, 14 studies met the inclusion criteria. The subjects in these included studies were characterized by age, sex, IOL type and percentage of water content, average time between surgical interventions, and associated risk factors in Table 1. Any patient or eye in the 14 studies that did not undergo a second YAG capsulotomy or other surgical intervention to treat recurrent PCO was excluded from Table 1. Eyes that underwent posterior capsulorhexis during cataract surgery were also excluded.

Recurrent PCO has been described as pearl or fibrous-type, similar to those in primary PCO.¹¹ In pearl-type formation, LECs can cluster together after the initial YAG capsulotomy, progressing to form a ring of Elschnig pearls around the posterior aperture. In most cases, the proliferation of these cells is self-limiting. However, on occasion, the proliferation and migration of LECs is severe enough to impact the visual axis and potentially reclose the posterior

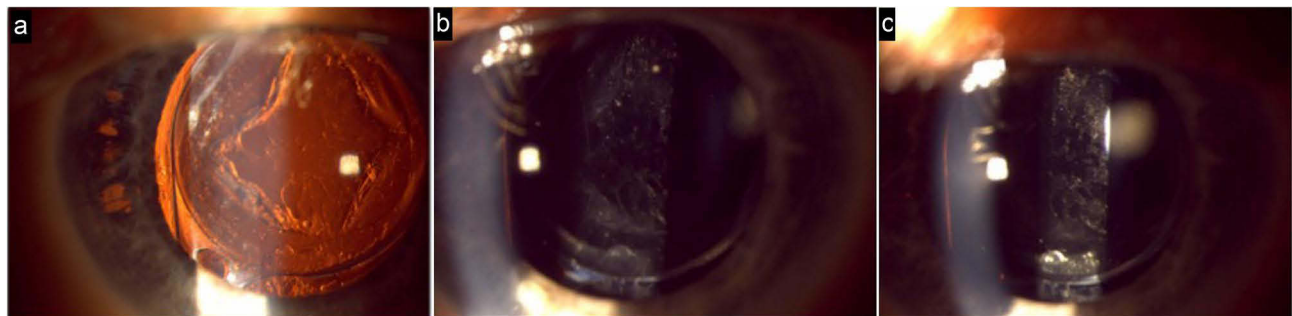


Figure 1 (a) Retro-illumination reveals the recurrent PCO with Elschnig pearls on the edge of the original capsulotomy opening and a thin fibrous membrane over the posterior aperture. (b and c) Recurrent PCO with the thin fibrous membrane covering the posterior aperture.

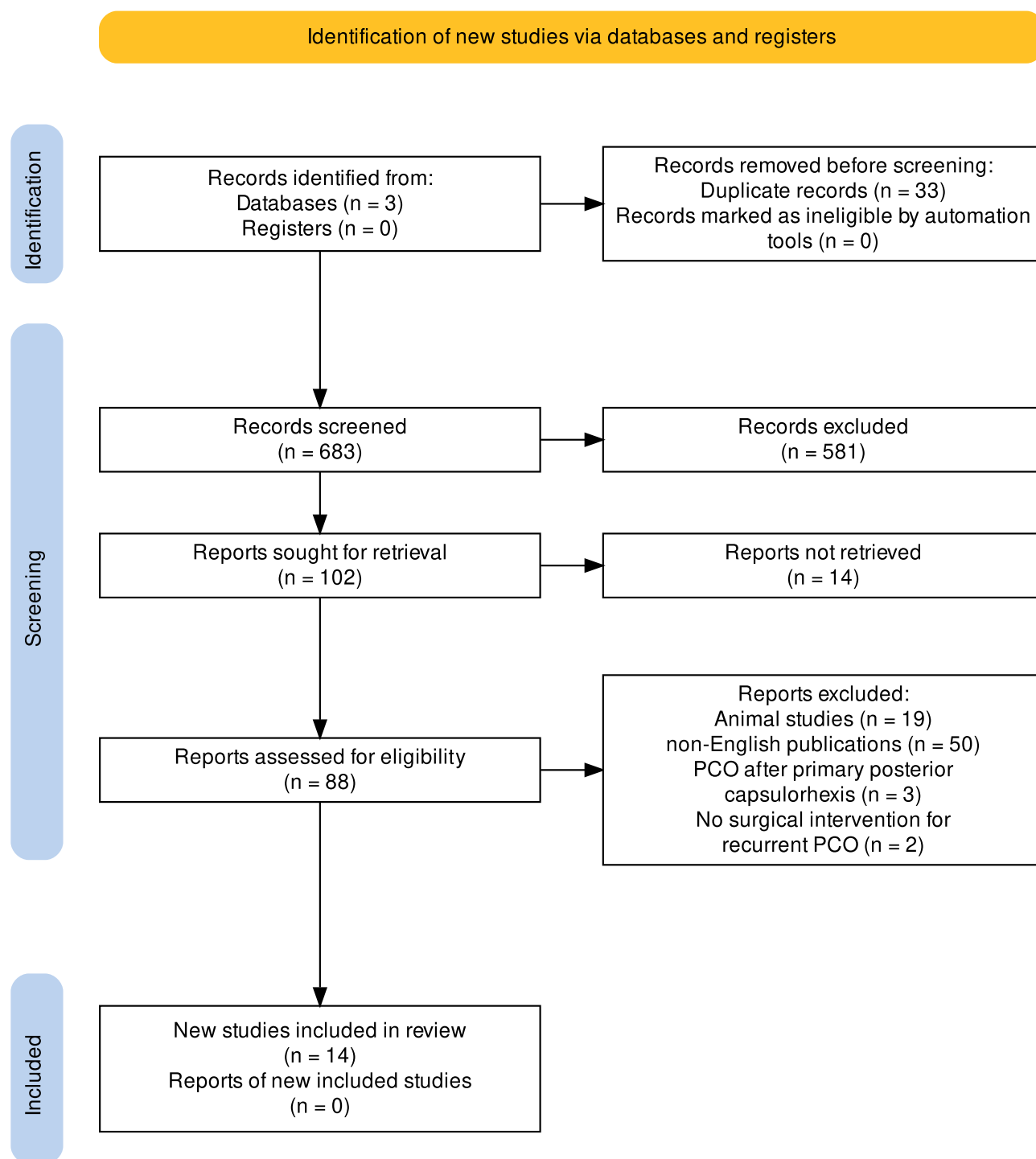


Figure 2 A representation of our literature review process.²⁷

aperture.¹⁴ In our patient's case, the recurrent PCO observed was most consistent with that of the fibrous-type. The mechanism behind LEC proliferation and migration over the posterior aperture, despite the absence of the posterior capsule as a scaffold, is still under investigation. A possible explanation was provided by an in vitro study investigating the causes of posterior capsulorhexis closure. They observed the proliferation and migration of residual LECs on a basal lamina of vitreous origin, believed to be the anterior hyaloid membrane, which provided a surface for the LECs to

Table 1 Cases of Recurrent PCO and Reported Risk Factors in the Current Literature

Authors & Year	Type of Study	# of Eyes/ Patients	Mean Age (Y) ± CI Sex	IOL Model (Material, Manufacturer, % Water Content)	YAG-1 Mean Time (M) ± CI [Range]	YAG-2 Mean Time (M) ± CI [Range]	Risk Factors & Findings
Jones et al, 1995 ⁸	Case series	6/6*	42.8 ± 12.0 3 Female 3 Male	–	–	11.5 ± 4.5 [4–18]	-Proliferative diabetic retinopathy -Prior vitrectomy -Familial exudative vitreoretinopathy -Retinopathy of prematurity
McPherson et al, 1995 ⁹	Case report	1/1*	44 1 Female	-PMMA biconvex (Model & Manufacturer not reported, <1%)	13	8	-Age under 50 -Recurrent PCO incidence of 0.7%
Caballero et al, 1997 ¹⁰	Case series	4/2	61 ± 13.7 1 Female 1 Male	-PMMA (Model & Manufacturer not reported, <1%)	14.5 ± 4.0 [10–18]	16.3 ± 3.9 [13–21]	-Myopic maculopathy -Elschnig pearls can spontaneously disappear over time
Kato et al, 1997 ¹¹	Retrospective study	17/17*	–	–	–	–	-IOL implantation -Continuous curvilinear capsulorhexis -Phacoemulsification
Oshika et al, 2001 ¹²	Case report	1/1	67 1 Male	-AcrySof® MA60BM (Hydrophobic Acrylic by Alcon, <0.2%)	12	6	-Diabetic retinopathy
Chatterjee and Garg, 2002 ¹³	Case report	1/1	48 1 Male	-PMMA biconvex (Model & Manufacturer not reported, <1%)	16	8	-Age under 50 -IOL diameter exceeding anterior capsulorhexis -Nonproliferative diabetic retinopathy
Kurosaka et al, 2002 ¹⁴	Retrospective study	18/18*	61.2 ± 16 14 Female 4 Male	–	–	16.1 ± 6.8 [7–29]	-80% of string of pearls disappear 8 years after first YAG -20% of patients required a second capsulotomy, usually within 2 years after the first
Georgopoulos et al, 2003 ¹⁵	Prospective study	2/2*	–	-Hydroview® H60M (Hydrophilic Acrylic by Bausch & Lomb, 18%)	–	–	-Hydrogel (hydrophilic acrylic) IOL -Silicone IOLs cause greater formation of Elschnig pearls on capsulotomy margin but not in the visual axis
Dietlein, 2003 ¹⁶	Prospective case series	2/2	74.5 ± 4.9 1 Female 1 Male	-Acrylic (Model & Manufacturer not reported) -PMMA (Model & Manufacturer not reported, <1%)	–	Within 2 months	-Prior vitrectomy -Silicone oil tamponade -Proliferative vitreoretinopathy
Garrot et al, 2004 ¹⁷	Case series	3/2*	38.5 ± 20.6 2 Male	-SK18UB (PMMA by Intraopics, <1%) -SI-40NB (Silicone by Allergan, <1%)	6.3 ± 3.6 [4–10]	26 ± 2 [24–27]	-Myotonic dystrophy
Jayaram et al, 2005 ¹⁸	Case series	5/5	54.2 ± 21.6 1 Female 4 Male	-6842B (PMMA by IOLAB, later bought by Chiron, <1%) -MC550 (PMMA by Chiron, <1%) -Hydroview® H60M (Hydrophilic Acrylic by Storz, 18%)	22.8 ± 4.8 [15–30]	33.8 ± 26.9 [11–82]	-Age under 50 -Uveitis -Myotonic dystrophy -Hydrogel (hydrophilic acrylic) IOLs -PMMA IOLs -Recurrent PCO incidence of 0.31%

(Continued)

Table I (Continued).

Authors & Year	Type of Study	# of Eyes/ Patients	Mean Age (Y) ± CI Sex	IOL Model (Material, Manufacturer, % Water Content)	YAG-1 Mean Time (M) ± CI [Range]	YAG-2 Mean Time (M) ± CI [Range]	Risk Factors & Findings
Kalliath et al, 2016 ¹⁹	Case report	1/1	60 1 Male	-AcrySof® IQ (Hydrophobic Acrylic by Alcon, <0.5%)	2	3	-Prior vitrectomy -Silicone oil tamponade
Rajesh, 2019 ²⁰	Case series	1*	70 1 Female	-Hydrophilic (Model & Manufacturer not reported)	8	7	-Capsulorhexis should cover edge of IOL for recurrent PCO prevention -Hydrophilic IOL
Ota et al, 2023 ²¹	Case series	22/18	67 ± 6.4 12 Female 6 Male	-Eternity® X-60, X-70, NX-60, NX-70S (Hydrophobic Acrylic by Santen, 4%) -SY60WF (Hydrophobic Acrylic by Clareon, 1.5%) -AcrySof® IQ SN60WF (Hydrophobic Acrylic by Alcon, 0.4%) -ZA9003 (Hydrophobic Acrylic by Tecnis, <1%) -iSert® 255 (Hydrophobic Acrylic by HOYA, 0.24%) -Vivinex™ iSert® XYI (Hydrophobic Acrylic by HOYA, 0.79%)	19.6 ± 3.6 [2.4–37.3]	10.4 ± 2.4 [4.3–26.6]	-Hydrophobic IOLs with higher water content (4%) -Female sex
Moshirfar et al, 2024	Case report	1/1	48 1 Male	-enVista® MX60E (Hydrophobic Acrylic by Bausch & Lomb, 4%)	31	8	-ICL explantation -Age under 50 -Hydrophobic IOL with higher water content (4%) -High myopia -Long axial length -Low-diopter IOL
Total(s)	5 Case reports 6 Case series 2 Retrospective 2 Prospective	85/78	59.7 [†] ± 3.7 34 Female 25 Male	Hydrophobic Acrylic (4%) = 17 PMMA = 13 Hydrophobic Acrylic (<1.5%) = 8 Hydrophilic Acrylic = 3 Hydrophilic, unspecified = 1 Acrylic, unspecified = 1 Silicone = 1 Unreported material = 41	17.6 [‡] ± 2.7 [2–37.3]	14.6 [§] ± 3.2 [2–82]	

Notes: Compiled from these studies.^{8–21} Symbols: –, not reported; *, the associated study has more than the listed eyes/patients in Table I but all others were excluded if they did not receive a 2nd YAG capsulotomy for recurrent PCO that obscured the visual axis; [†], calculated from the 59 patients with reported ages; [‡], calculated from the 40 eyes with reported YAG-1 times; [§], calculated from the 60 eyes with reported YAG-2 times.

Abbreviations: CI, confidence interval; Y, year; M, month; YAG-1, time between cataract surgery and first YAG capsulotomy; YAG-2, time between first and second YAG capsulotomy or other surgical intervention.

obstruct the posterior aperture.²⁸ A case report by Kalliath et al supported this idea, hypothesizing that an anterior hyaloid face of vitreous origin was responsible for recurrent PCO formation.¹⁹

IOLs with high water content have been reported as a possible risk factor for recurrent PCO. A prospective study found that hydrogel lenses, composed of hydrophilic acrylic material with 38% water content, had a higher incidence of reclosure of the capsulotomy area when compared to other lens materials.¹⁵ Two other studies also reported recurrent PCO in patients with high water content IOLs.^{18,20} A study on primary PCO formation revealed similar findings, in which higher water content IOLs composed of hydrophilic acrylic material were shown to have denser and increased rates of primary PCO formation when compared to their hydrophobic acrylic counterparts. The authors proposed that this was due to the greater fibronectin binding between the hydrophobic acrylic IOL and posterior capsule, preventing LEC migration between the two surfaces.²⁹ Another possible explanation focuses more on lens design rather than material, with sharp optic edges being associated with fewer PCO and lower rates of laser capsulotomy. Hydrophilic acrylic IOLs have difficulty maintaining this sharp posterior edge.^{30–32} While the above explanations may be satisfactory for patients with primary PCO formation, it is still unknown how hydrophilic IOL materials promote re-opacification in cases of recurrent PCO.

Cases of recurrent PCO have also been observed in hydrophobic IOLs with higher water content than normally found in other hydrophobic IOLs. A recent case series of 22 eyes by Ota et al displayed that despite using IOLs with 4% water content in only 14% of their clinic patients, 73% of the eyes with recurrent PCO in their study had these IOLs. Some of these patients required three YAG capsulotomies. The authors proposed that although hydrophobic IOLs were used, the higher water content of 4% relative to other hydrophobic IOLs potentially predisposed patients to develop recurrent PCO.²¹ When comparing our presented case, our patient also received a 4% water content hydrophobic acrylic lens. Other than the case series by Ota et al and our own case report, no other studies have reported recurrent PCO in patients with 4% water content hydrophobic IOLs. It is possible that despite being composed of hydrophobic material, the higher water content could have contributed to our patient's recurrent PCO. Further research on PCO recurrence in patients with hydrophobic IOLs with higher water content is needed to confirm these findings.

Polymethyl methacrylate (PMMA), a hydrophobic IOL material with less than 1% water content, has also been associated with recurrent PCO. In a case series by Jayaram et al, it was noted that 4 of the 5 patients who developed recurrent PCO had received an IOL made of PMMA.¹⁸ Several other studies also reported recurrent PCO in patients with PMMA-based IOLs.^{9,10,13,16,17} PCO recurrence in PMMA-based lenses may be more associated with its design and optic edges rather than its actual material. Square-edge PMMA lenses have been found to have significantly fewer PCO than their round-edge counterparts.³³ The studies included in Table 1 that reported the use of PMMA IOLs did not always mention if square-edge or round-edge designs were used, making it difficult to provide further analysis on this topic.

Patient age appears to be an important factor in recurrent PCO formation. In our review of the literature, the average age was 59.7 ± 3.7 years for 59 patients with reported ages (Table 1). Three studies reported that age under 50 may be associated with PCO recurrence.^{9,13,18} Our patient, at 47-years-old, supports these findings. A similar trend of increased risk has also been observed in cases of primary PCO formation after cataract surgery in children and those under the age of 60.^{6,34,35} LECs in younger patients have pro-EMT characteristics and a higher proliferative state than their older counterparts, allowing PCO formation to occur more easily after surgery.³⁶ Because both primary and recurrent PCO form from residual LECs, similar mechanisms could explain the increased cases of recurrent PCO in younger patients.

Female sex, a known risk factor for primary PCO, has also been investigated for its association with recurrent PCO.^{1,35} Ota et al reported that the majority of their patients were female.²¹ Conversely, Kato et al reported that sex was not associated with recurrent PCO.¹¹ Patient sex was listed in 12 of the 14 studies regarding recurrent PCO, with a total of 25 males and 34 females after including our patient (Table 1). Our review of the literature showed a greater number of reported cases of recurrent PCO requiring a second YAG capsulotomy in female patients. However, further investigation is needed with a larger sample size to determine if female sex is an attributable risk factor.

Pro-inflammatory or post-surgical states such as proliferative diabetic retinopathy, uveitis, and prior vitrectomy have been reported in patients with recurrent PCO.^{8,12,18} Similarly, Tassignon et al observed a higher rate of posterior aperture reclosure after posterior continuous curvilinear capsulorhexis in patients with diabetes, uveitis, and other inflammatory conditions than in those without.³⁷ Pro-inflammatory states from these diseases can result in cytokines and other

chemical mediators that seem to allow greater proliferation of LECs.³⁸ The presence of other systemic diseases that affect the eyes and may be implicated in recurrent PCO development, such as myotonic dystrophy, are also important to consider.^{17,18,39} Conversely, our patient was in excellent medical health and lacked a history of diabetes, uveitis, retinal pathology, or prior vitrectomy. This observation highlights the importance for ophthalmologists to recognize that recurrent PCO may occur even in patients without systemic diseases or pro-inflammatory states.

Some additional factors rarely investigated or reported by studies about recurrent PCO are long axial length, high myopia, and implantation of low-diopter IOLs. All three have been observed to be risk factors for primary PCO formation following cataract surgery.¹ Caballero et al reported a patient with myopic maculopathy who required a repeat YAG capsulotomy in both eyes.¹⁰ Kato et al, however, had contradictory findings, reporting that high myopia did not increase the incidence of Elschnig pearl development following YAG capsulotomy.¹¹ Many of the 14 studies in our review on recurrent PCO did not report the power of IOLs implanted in their patients. Our patient was highly myopic with an axial length of 27.09 mm and had a low-diopter IOL of 12.0 D implanted. Further investigation is needed to determine if high myopia, long axial length, and low-diopter IOL implantation are risk factors for recurrent PCO. Regular retinal evaluations are recommended in patients with high axial length and in those that have received a YAG capsulotomy in efforts to address potential complications such as retinal detachment.

Time to re-opacification after an initial YAG capsulotomy is another important consideration in patients with recurrent PCO. The 22 total eyes in Ota et al had an average time from surgery to the first YAG capsulotomy (YAG-1) of 19.6 ± 3.6 months and an average of 10.4 ± 2.4 months after the first YAG capsulotomy to the second YAG capsulotomy (YAG-2) (Table 1).²¹ When only comparing the six eyes with 4% water content IOLs and no prior history of vitrectomy, YAG-1 and YAG-2 times were about the same as all of the other eyes in the study group, at 23.6 ± 5.2 and 8.15 ± 3.6 months, respectively. Only one patient in our search of the literature, a 59-year-old female, matched our patient's history of a 4% water content IOL with no significant ocular or systemic diseases. Her YAG-1 and YAG-2 times were 17.7 and 14.5 months, respectively.²¹ McPherson and Govan reported a similar case of a 44-year-old female with no significant ocular or systemic diseases but was implanted with a PMMA IOL. Her times for YAG-1 and YAG-2 were 13 and 8 months, respectively.⁹ In comparison, our patient's YAG-1 time was 31 months, which was several months longer than the average YAG-1 time for all eyes observed in Ota et al. However, our patient's YAG-2 time of 8 months was very similar to the average YAG-2 time for all eyes in Ota et al.²¹ Our review of the literature revealed that out of the 40 eyes with specified times, the average YAG-1 time was 17.6 ± 2.7 months. The average YAG-2 time was 14.6 ± 3.2 months in 60 eyes with specified times (Table 1). These findings, supporting those observed in our patient, follow an interesting pattern noted by Ota et al, where the mean YAG-2 time is generally shorter than the mean YAG-1 time.²¹

Various surgical techniques have been investigated as possible ways to prevent primary PCO formation. Some of these techniques include hydrodissection,⁴⁰ sealed capsular irrigation,⁴¹ irrigation with trypan blue dye in the capsular bag,⁴² and bag-in-the-lens implantation.^{43,44} Other potential surgical techniques are also being investigated. A retrospective study found that posterior capsular vacuuming in addition to anterior, equatorial, and posterior capsular polishing, significantly reduced PCO development rate.⁴⁵ A prospective case series found that the 360-degree rotation of an IOL after placement in the capsular bag lowered PCO formation. However, the authors noted that this technique should be tried by expert surgeons and has an increased risk of posterior capsule rent and zonular dehiscence.⁴⁶ While these techniques may decrease primary PCO formation, further investigation is needed to determine if they can also prevent recurrent PCO formation. The surgeon in our present study utilized hydrodissection, hydrodelineation, anterior, posterior, and equatorial capsular polishing. Surgeons may choose to utilize any of the above surgical techniques to reduce PCO formation given the patient's specific risk factors and needs.

Determining the optimal YAG capsulotomy size and its impact on patients with recurrent PCO may be a point of further investigation. Our patient's original capsulotomy was an appropriately large size, with a diameter of approximately 4.5–5.0 mm, which was slightly smaller than the intraocular lens. However, despite a large capsulotomy size, there is still the possibility of reclosure of the posterior aperture due to further proliferation of the LECs, similar to what occurred in our patient's case. Most of the studies in our literature review did not specify the exact size of the first or second YAG capsulotomies in their patients. One study stated that a large YAG capsulotomy should be performed in patients so that if a massive proliferation were to occur there would be less chance of visual axis involvement.⁸ Two

studies performed their YAG capsulotomies without mydriatics and reported diameters between 2.0 and 3.0 mm. Both stated that their small capsulotomy sizes may have contributed to the high incidence of clinical symptoms in their studies.^{11,14} It has been reported that contrast and glare visual acuity is better when the YAG capsulotomy is larger than the pupillary size.⁴⁷ Given these findings, creating a capsulotomy that is smaller than the pupil size is likely suboptimal in patients at high risk for PCO and recurrent PCO formation. It is our recommendation that surgeons create a larger YAG capsulotomy in high-risk patients, potentially between 4.5 and 5.0 mm in diameter, in an effort to decrease the chance of recurrent PCO and subsequent obstruction of the visual axis. However, it is important to recognize that creating too large of a capsulotomy may introduce additional unnecessary complications. Surgeons are encouraged to avoid creating a capsulotomy that is larger than the intraocular lens. Further studies are needed to determine the ideal YAG capsulotomy size to prevent recurrent PCO formation.

It is important for ophthalmologists to be cognizant of the possible increased risk of recurrent PCO in ICL populations who may eventually undergo cataract surgery. This demographic may be predisposed to this complication due to the 12.1% incidence of cataract formation within 10 years of ICL implantation,⁴⁸ younger age, high myopia, and a likelihood for low-diopter posterior chamber IOL implantation. An additional consideration in ICL patients is the type of IOL selected for implantation. The use of hydrophobic IOLs with higher percent water content is becoming more widespread and may further increase their risk of PCO recurrence. In regard to our patient, a third occurrence of PCO is conceivable given his reported risk factors (Table 1). A third YAG capsulotomy or possible IOL exchange with vitrectomy may be required. Long-term follow-up should be considered in these patients to ensure optimal postoperative visual outcomes.

Conclusion

To our knowledge, this is a novel case report of recurrent PCO in a patient following concurrent ICL explantation and cataract surgery. We also provide an updated overview of recurrent PCO in the literature. Although recurrent PCO is an uncommon postoperative complication after cataract surgery, it is important that ophthalmologists are aware of its existence and associated risk factors. While hydrophilic IOLs, younger age, and pro-inflammatory conditions appear to predispose patients to recurrent PCO formation, other factors such as female sex, long axial length, high myopia, and low-diopter IOLs require further investigation. Specialized surgical techniques such as capsular polishing and vacuuming and thorough postoperative monitoring may help prevent and manage recurrent PCO in adult patients. Tailored approaches for high-risk patients, such as those with high myopia and younger age, are crucial. Regular retinal evaluations are recommended, especially for patients with high axial lengths and those who have undergone YAG laser capsulotomy, to preemptively address potential complications like retinal detachment. Continued research with larger sample sizes should focus on the long-term outcomes of the various surgical techniques available to prevent primary and recurrent PCO and identify additional risk factors that contribute to PCO recurrence. It is our hope that cataract surgeons will utilize this information in preoperative planning and postoperative care to reduce the likelihood of PCO recurrence in their patients.

Publication Originality Statement

We confirm that this publication is original.

Compliance with Ethics Guidelines

This case report was approved by the Hoopes Vision Ethics Board.

Patient Consent

Informed and written consent was acquired from the patient for the publication of this case report and all accompanying details and images herein.

Author Contributions

All authors made a significant contribution to the work reported, whether that is in the conception, design, execution, acquisition of data, analysis and interpretation, or in all these areas; took part in drafting, revising, or critically reviewing the article; gave final approval of the version to be published; have agreed on the journal to which the article has been submitted; and agree to be accountable for all aspects of the work.

Funding

No funding or grant support.

Disclosure

The authors report no conflicts of interest in this work.

References

- Donachie PHJ, Barnes BL, Olaitan M, Sparrow JM, Buchan JC. The Royal College of Ophthalmologists' National Ophthalmology Database study of cataract surgery: report 9, risk factors for posterior capsule opacification. *Eye*. 2023;37(8):1633–1639. doi:10.1038/S41433-022-02204-1
- Leydolt C, Schartmüller D, Schwarzenbacher L, Röggl V, Schriefl S, Menapace R. Posterior capsule opacification with two hydrophobic acrylic intraocular lenses: 3-year results of a randomized trial. *Am J Ophthalmol*. 2020;217:224–231. doi:10.1016/j.ajo.2020.04.011
- Ursell PG, Dhariwal M, O'Boyle D, Khan J, Venerus A. 5 year incidence of YAG capsulotomy and PCO after cataract surgery with single-piece monofocal intraocular lenses: a real-world evidence study of 20,763 eyes. *Eye*. 2020;34(5):960–968. doi:10.1038/S41433-019-0630-9
- Apple DJ. Influence of intraocular lens material and design on postoperative intracapsular cellular reactivity. *Trans Am Ophthalmol Soc*. 2000;98:257. doi:10.1016/s0002-9394(01)00944-8
- McDonnell PJ, Zarbin MA, Green WR. Posterior capsule opacification in pseudophakic eyes. *Ophthalmology*. 1983;90(12):1548–1553. doi:10.1016/S0161-6420(83)34350-5
- Wu S, Tong N, Pan L, et al. Retrospective analyses of potential risk factors for posterior capsule opacification after cataract surgery. *J Ophthalmol*. 2018;2018. doi:10.1155/2018/9089285
- Bhargava R, Kumar P, Sharma SK, Kaur A. A randomized controlled trial of peeling and aspiration of Elschmig pearls and neodymium: yttrium-aluminum-garnet laser capsulotomy. *Int J Ophthalmol*. 2015;8(3):590. doi:10.3980/J.ISSN.2222-3959.2015.03.28
- Jones NP, McLeod D, Boulton ME, et al. Massive proliferation of lens epithelial remnants after Nd:YAG laser capsulotomy. *Br J Ophthalmol*. 1995;79(3):261. doi:10.1136/BJO.79.3.261
- McPherson RJE, Govan JAA. Posterior capsule reopacification after neodymium:YAG laser capsulotomy. *J Cataract Refract Surg*. 1995;21(3):351–352. doi:10.1016/S0886-3350(13)80146-0
- Caballero A, Salinas M, Marin JM. Spontaneous disappearance of Elschmig pearls after neodymium:YAG laser posterior capsulotomy. *J Cataract Refract Surg*. 1997;23(10):1590–1594. doi:10.1016/S0886-3350(97)80035-1
- Kato K, Kurosaka D, Bissen-Miyajima H, Negishi K, Hara E, Nagamoto T. Elschmig pearl formation along the posterior capsulotomy margin after neodymium:YAG capsulotomy. *J Cataract Refract Surg*. 1997;23(10):1556–1560. doi:10.1016/S0886-3350(97)80029-6
- Oshika T, Santou S, Kato S, Amano S. Secondary closure of neodymium:YAG laser posterior capsulotomy. *J Cataract Refract Surg*. 2001;27(10):1695–1697. doi:10.1016/S0886-3350(01)00782-9
- Chatterjee S, Garg P. "String of pearls" following Nd:YAG laser posterior capsulotomy. *Indian J Ophthalmol*. 2002;50(2):140–142.
- Kurosaka D, Kato K, Kurosaka H, Yoshino M, Nakamura K, Negishi K. Elschmig pearl formation along the neodymium: YAG laser posterior capsulotomy margin - Long-term follow-up. *J Cataract Refract Surg*. 2002;28(10):1809–1813. doi:10.1016/S0886-3350(02)01222-1
- Georgopoulos M, Findl O, Menapace R, Buehl W, Wirtitsch M, Rainer G. Influence of intraocular lens material on regenerative posterior capsule opacification after neodymium:YAG laser capsulotomy. *J Cataract Refract Surg*. 2003;29(8):1560–1565. doi:10.1016/S0886-3350(03)00345-6
- Dietlein TS, Lüke C, Jacobi PC, Kirchhof B, Krieglstein GK. Neodymium:YAG laser capsulotomy in vitrectomized pseudophakic eyes with persistent endotamponade. *J Cataract Refract Surg*. 2003;29(12):2385–2389. doi:10.1016/S0886-3350(03)00248-7
- Garrott HM, Walland MJ, O'Day J. Recurrent posterior capsular opacification and capsulorhexis contracture after cataract surgery in myotonic dystrophy. *Clin Exp Ophthalmol*. 2004;32(6):653–655. doi:10.1111/J.1442-9071.2004.00919.X
- Jayaram H, Uppal G, Hugkulstone CE, Gibbons MV, Watt L. YAG curies #1: repeat Nd:YAG laser posterior capsulotomy. *Acta Ophthalmol Scand*. 2005;83(2):242–244. doi:10.1111/J.1600-0420.2005.00405.X
- Kalliath J, Prakash G, Avadhani K, Shakuntala A. An after after-cataract: a curious case of visual axis re-opacification. *Saudi J Ophthalmol*. 2016;30(4):264–267. doi:10.1016/J.SJOPT.2016.11.002
- Rajesh SJ. Reopacification of posterior capsular opening after ND: YAG capsulotomy: 2 cases with the different presentation. *Rom J Ophthalmol*. 2019;63(4):387–390.
- Ota A, Ota I, Kachi S, et al. Factors associated with reclosure of posterior capsule aperture by flat opacifications with pearls after Nd:YAG laser posterior capsulotomy. *Diseases*. 2023;11(2). doi:10.3390/DISEASES11020082
- Hutcheson KA, Drack AV, Ellish NJ, Lambert SR. Anterior hyaloid face opacification after pediatric Nd:YAG laser capsulotomy. *J AAPOS*. 1999;3(5):303–307. doi:10.1016/S1091-8531(99)70027-3
- Rahman I, Jones NP. Long-term results of cataract extraction with intraocular lens implantation in patients with uveitis. *Eye*. 2005;19(2):191–197. doi:10.1038/SJ.EYE.6701450
- Hayashi K, Hayashi H, Nakao F, Hayashi F. Posterior capsule opacification after cataract surgery in patients with diabetes mellitus. *Am J Ophthalmol*. 2002;134(1):10–16. doi:10.1016/S0002-9394(02)01461-7

25. Krishnamachary M, Rath V, Gupta S. Management of traumatic cataract in children. *J Cataract Refract Surg*. 1997;23(5):681–687. doi:10.1016/S0886-3350(97)80054-5
26. Auffarth GU, Nimsger C, Tetz MR, Krastel H, Völcker HE. Erhöhte Nachstarrate und Besonderheiten der Nd:YAG-Laserkapsulotomie bei Retinitis pigmentosa [Increased cataract rate and characteristics of Nd:YAG laser capsulotomy in retinitis pigmentosa]. *Ophthalmologe*. 1997;94(11):791–795. German. doi:10.1007/S003470050205
27. Haddaway NR, Page MJ, Pritchard CC, McGuinness LA. PRISMA2020: an R package and Shiny app for producing PRISMA 2020-compliant flow diagrams, with interactivity for optimised digital transparency and Open Synthesis. *Campbell Syst Rev*. 2022;18(2). doi:10.1002/CL2.1230
28. De Groot V, Vrensen GFJM, Willekens B, Van Tenten Y, Tassignon MJ. In vitro study on the closure of posterior capsulorrhexis in the human eye. *Invest Ophthalmol Vis Sci*. 2003;44(5):2076–2083. doi:10.1167/IOVS.02-0525
29. Chang A, Kugelberg M. Posterior capsule opacification 9 years after phacoemulsification with a hydrophobic and a hydrophilic intraocular lens. *Eur J Ophthalmol*. 2017;27(2):164–168. doi:10.5301/EJO.5000831
30. Tetz M, Jorgensen MR. New hydrophobic IOL materials and understanding the science of glistenings. *Curr Eye Res*. 2015;40(10):969–981. doi:10.3109/02713683.2014.978476
31. Maedel S, Evans JR, Harrer-Seely A, Findl O. Intraocular lens optic edge design for the prevention of posterior capsule opacification after cataract surgery. *Cochrane Database Syst Rev*. 2021;8(8). doi:10.1002/14651858.CD012516.PUB2
32. Cheng JW, Wei RL, Cai JP, et al. Efficacy of different intraocular lens materials and optic edge designs in preventing posterior capsular opacification: a meta-analysis. *Am J Ophthalmol*. 2007;143(3). doi:10.1016/J.AJO.2006.11.045
33. Haripriya A, Chang DF, Vijayakumar B, et al. Long-term posterior capsule opacification reduction with square-edge polymethylmethacrylate intraocular lens: randomized controlled study. *Ophthalmology*. 2017;124(3):295–302. doi:10.1016/J.OPHTHA.2016.11.010
34. Atkinson CS, Hiles DA. Treatment of secondary posterior capsular membranes with the Nd:YAG laser in a pediatric population. *Am J Ophthalmol*. 1994;118(4):496–501. doi:10.1016/S0002-9394(14)75802-7
35. Lindholm JM, Laine I, Tuuminen R. Intraocular lens power, myopia, and the risk of Nd:YAG capsulotomy after 15,375 cataract surgeries. *J Clin Med*. 2020;9(10):1–7. doi:10.3390/JCM9103071
36. Wei Z, Gordon P, Hao C, et al. Aged lens epithelial cells suppress proliferation and epithelial–mesenchymal transition-relevance for posterior capsule opacification. *Cells*. 2022;11(13). doi:10.3390/CELLS11132001
37. Tassignon MJ, De Groot V, Vercken F, Van Tenten Y. Secondary closure of posterior continuous curvilinear capsulorrhexis in normal eyes and eyes at risk for postoperative inflammation. *J Cataract Refract Surg*. 1998;24(10):1333–1338. doi:10.1016/S0886-3350(98)80224-1
38. Awasthi N, Guo S, Wagner BJ. Posterior capsular opacification: a problem reduced but not yet eradicated. *Archives of Ophthalmology*. 2009;127(4):555–562. doi:10.1001/ARCHOPHTHALMOL.2009.3
39. Machuca-Tzili L, Brook D, Hilton-Jones D. Clinical and molecular aspects of the myotonic dystrophies: a review. *Muscle Nerve*. 2005;32(1):1–18. doi:10.1002/MUS.20301
40. Peng Q, Apple DJ, Visessook N, et al. Surgical prevention of posterior capsule opacification. Part 2: enhancement of cortical cleanup by focusing on hydrodissection. *J Cataract Refract Surg*. 2000;26(2):91–96. doi:10.1016/S0886-3350(99)00354-5
41. Rabsilber TM, Limberger IJ, Reuland AJ, Holzer MP, Auffarth GU. Long-term results of sealed capsule irrigation using distilled water to prevent posterior capsule opacification: a prospective clinical randomised trial. *Br J Ophthalmol*. 2007;91(7):912–915. doi:10.1136/BJO.2006.106468
42. Sharma P, Panwar M. Trypan blue injection into the capsular bag during phacoemulsification: initial postoperative posterior capsule opacification results. *J Cataract Refract Surg*. 2013;39(5):699–704. doi:10.1016/J.JCRS.2012.11.025
43. Leysen I, Coeckelbergh T, Gobin L, et al. Cumulative neodymium:YAG laser rates after bag-in-the-lens and lens-in-the-bag intraocular lens implantation. Comparative Study. *J Cataract Refract Surg*. 2006;32(12):2085–2090. doi:10.1016/J.JCRS.2006.07.025
44. Dragnea DC, Truța RN, Goemaere J, Tassignon MJ, Dhubghaill SN. Intraocular bag-in-the-lens exchange: indications, outcomes, and complications. *J Cataract Refract Surg*. 2022;48(5):568–575. doi:10.1097/J.JCRS.0000000000000787
45. Ucar F, Cetinkaya S. Posterior capsular vacuuming to avoid PCO formation. *Int Ophthalmol*. 2022;42(10):3089–3095. doi:10.1007/S10792-022-02295-5
46. Joshi R, Chavan S. Rotation versus non-rotation of intraocular lens for prevention of posterior capsular opacification. *Indian J Ophthalmol*. 2019;67(9):1428. doi:10.4103/IJO.IJO_1854_18
47. Hayashi K, Nakao F, Hayashi H. Influence of size of neodymium:Yttrium-aluminium-garnet laser posterior capsulotomy on visual function. *Eye*. 2009;24(1):101–106. doi:10.1038/eye.2009.41
48. Choi JH, Lim DH, Nam SW, Yang CM, Chung TY. Ten-year clinical outcomes after implantation of a posterior chamber phakic intraocular lens for myopia. *J Cataract Refract Surg*. 2019;45(11):1555–1561. doi:10.1016/J.JCRS.2019.06.015

International Medical Case Reports Journal

Dovepress

Publish your work in this journal

The International Medical Case Reports Journal is an international, peer-reviewed open-access journal publishing original case reports from all medical specialties. Previously unpublished medical posters are also accepted relating to any area of clinical or preclinical science. Submissions should not normally exceed 2,000 words or 4 published pages including figures, diagrams and references. The manuscript management system is completely online and includes a very quick and fair peer-review system, which is all easy to use. Visit <http://www.dovepress.com/testimonials.php> to read real quotes from published authors.

Submit your manuscript here: <https://www.dovepress.com/international-medical-case-reports-journal-journal>