

# Feasibility of abdominoplasty with Cesarean section

Wael Naeem Thabet<sup>1</sup>  
Ahmad Samir Hossny<sup>1</sup>  
Nadine Alaa Sherif<sup>2</sup>

<sup>1</sup>Department of General Surgery,  
<sup>2</sup>Department of Obstetrics and  
Gynecology, Cairo University, Cairo,  
Egypt

**Abstract:** Abdominoplasty is an esthetic surgical procedure that restores abdominal contouring. Repeated pregnancies combined with advancing maternal age usually lead to lower abdominal skin redundancy and excess fat accumulation. Delivery via Cesarean section adds weakness to the lower abdominal wall muscles and yields a lower transverse Cesarean scar. Some patients request whether abdominoplasty can be performed with Cesarean section in the same setting, to avoid a future surgery. This study was designed to evaluate the outcome of combined abdominoplasty with Cesarean section. The study included 50 pregnant women from September 2009 to June 2010 with an average follow-up period of 9 months. Nine patients (18%) developed wound infection; three of them (6%) developed wound dehiscence. Six patients (12%) developed lower abdominal skin necrosis; three of them (6%) were treated conservatively and healed by secondary intention, while surgical debridement and secondary sutures were needed in the other three patients (6%). Residual abdominal skin redundancy in nine patients (18%), outward bulging of the abdomen and lack of waist definition in 16 patients (32%), and outward bulging of the umbilicus in twelve patients (24%) were the reported unesthetic results. The results were compared with results of 50 abdominoplasties in nonpregnant women.

**Keywords:** abdominoplasty, Cesarean section, pregnancy

## Introduction

Recently, abdominoplasty has frequently been requested to be done at the same time as a Cesarean delivery. The size and shape of the abdomen during pregnancy is quite different from the abdomen of the nonpregnant woman. In late pregnancy, and especially in multiparous women, the muscles of the abdominal wall are subjected to progressive tension, and the rectus muscles divaricate in the midline, creating diastasis recti of varying extent. If severe, a considerable portion of the anterior uterine wall is covered by only a layer of skin, attenuated fascia, and peritoneum.<sup>1</sup> Furthermore, vascular changes in the muscles of the abdominal wall in the late pregnancy are evident due to the high level of estrogen. High levels of estrogen are believed to be responsible for the proliferation of blood vessels and congestion within the muscles and abdominal skin.<sup>2</sup>

Cesarean delivery is performed for maternal or fetal indications, or both. The leading indications for Cesarean delivery are previous Cesarean delivery, breech presentation, dystocia, and fetal distress. These indications are responsible for 85% of all Cesarean deliveries.<sup>3</sup> Cesarean delivery yields a lower transverse abdominal scar and variable degrees of weakness of the abdominal muscles, especially if the patient has repeated Cesarean deliveries.<sup>1,4</sup> These changes contribute directly to a disturbed abdominal contour.<sup>4,5</sup>

Correspondence: Nadine Alaa Sherif  
Department of Obstetrics and  
Gynecology, Faculty of Medicine, Cairo  
University, 8 Abdel Hamid Lotfi Street,  
Mohandessin, Cairo, Egypt  
Tel +20122 3170245  
Fax +202 33374281  
Email nadsherif@hotmail.com

## Patients and methods

This study included 50 pregnant women who underwent abdominoplasty combined with Cesarean delivery in the same setting upon their request. The age of the patients ranged from 33 years to 39 years with a mean of 37.5 years. The study was conducted from September 2009 to June 2010 in Kasr Al Aini teaching hospitals in Cairo, Egypt. The average follow-up period was 9 months. The indications for Cesarean delivery were as follows: previous two or more Cesarean sections (26 cases), breech presentation (six cases), cephalopelvic disproportion (eight cases), placenta previa (four cases), transverse lie (one case), oversized abdomen (three cases), previous myomectomy scar (one case), and previous hysterotomy scar (one case). In all cases, delivery was planned via elective Cesarean section. Most of the patients ( $n = 27$ ) reported that they had completed their family and had no desire to have more children. However, they were instructed to wait at least 1 year after the procedure before getting pregnant, and vaginal birth after cesarean section was clearly explained to them. The total body weight of the patients at full-term pregnancy ranged from 61 kg to 69 kg with a mean of 64.7 kg. The study did not include overweight patients; all patients had a normal body mass index (BMI), with a mean BMI of 24.4. A preoperative workup, including complete blood numbers, liver and kidney functions, fasting blood sugar, and bleeding profiles, was done for every patient. Hemoglobin level ranged from 11.2 g/dL to 14.5 g/dL with a mean of 12.3 g/dL. Fasting blood sugar, liver and kidney functions, and bleeding profiles were within normal ranges. Diabetic, hypertensive, and anemic patients were excluded from the study.

All patients were subjected to regular antenatal care. At the time of delivery, all patients were at full term, and ultrasound examination revealed a mature baby. We informed every patient that the result of abdominoplasty might be less than perfect. Two patients were excluded from the study and abdominoplasty was halted because they developed intrapartum uterine atony and bleeding. Routine preoperative and postoperative photographs were taken.

The results of 80 abdominoplasty procedures in nonpregnant women during the same period of the study and performed by the first two authors were collected. The exclusion criteria were the same as those of the patients who underwent abdominoplasty combined with Cesarean delivery. There was no statistically significant difference between the two groups regarding mean age, body weight, and BMI (Table 1;  $P > 0.05$ ). Abdominoplasty of nonpregnant women ranged from 350 cc to 650 cc with a mean

**Table 1** Demographic data of the two groups showing that there is no statistically significant difference between the two groups ( $P > 0.05$ )

| Measurement          | Group 1 | Group 2 | P value |
|----------------------|---------|---------|---------|
| Mean age             | 37.5    | 34      | 0.3117  |
| Mean body weight     | 64.7    | 67.4    | 0.5569  |
| Mean body mass index | 24.4    | 24.7    | 0.4963  |

of 420 cc. The weight of skin excised ranged from 680 g to 2100 g with a mean of 1330 g.

This is a prospective study in which informed consent was taken from each patient (the whole 130 patients), and approval of the Kasr Al Aini ethics committee was also obtained beforehand.

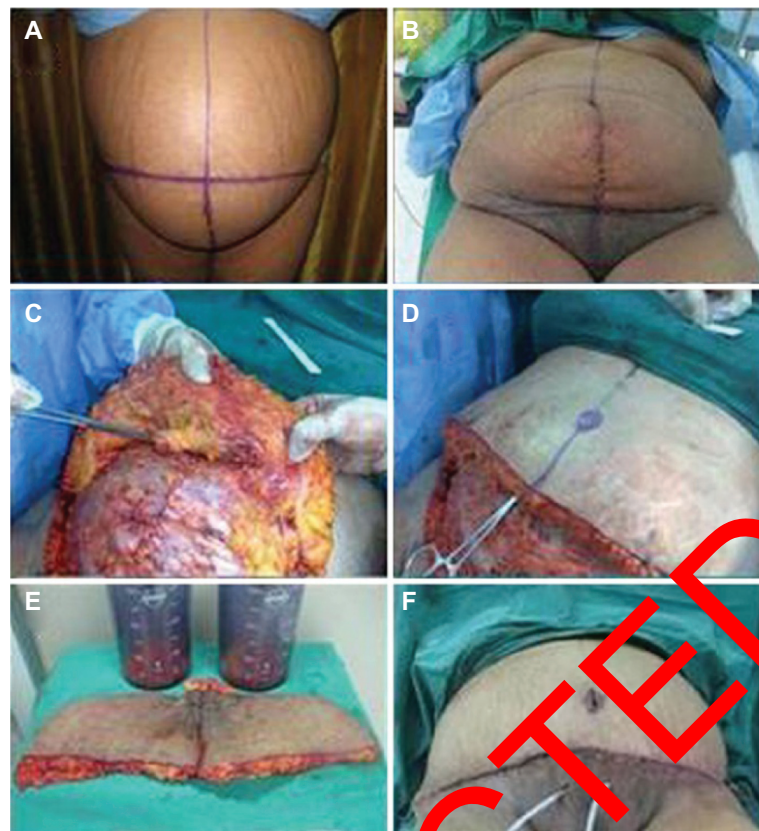
## Marking and preparation

Marking was performed with the patient in the standing position (Figure 1A). Marking included the lower abdominoplasty incision line, the midline, and the proposed upper resection line. The lower abdominoplasty incision line was drawn 7 cm above the upper vulvar commissure. Marking and measurements of the full-term pregnant abdomens were difficult in the standing position; therefore, revision of the marking was checked in the supine position. After induction of anesthesia, 1 g of third-generation cephalosporin was given intravenously, and a urinary catheter was inserted.

## Operative technique

All patients were operated on while under general anesthesia. The approach for Cesarean delivery was either a transverse abdominal incision (a Joel Cohen incision, which is a straight skin incision 3 cm above the symphysis pubis; subsequent tissue layers are opened bluntly and, if necessary, extended with scissors and not a knife) (43 patients) or a midline lower abdominal incision (seven patients). Cesarean section performed using a transverse abdominal incision is associated with less postoperative pain and improved cosmetic effect compared with a midline incision; also, it is associated with shorter operating times and reduced postoperative febrile morbidity. After completion of the Cesarean delivery, the third author sutured the rectus muscles with 1/0 absorbable sutures and the rectus sheath with 2/0 nonabsorbable sutures. The Cesarean incision was closed by staples (Figure 1B).

Resterilization and toweling of the abdomen was done for abdominoplasty. Limited liposuction of the supraumbilical paramedian area and flanks was carried out using the superwet technique. The amount of lipoaspirate ranged from 300 cc to 500 cc with a mean of 375 cc. The abdominoplasty incision



**Figure 1** (A) The preoperative front view of a full-term pregnant woman with marking performed in the standing position. (B) Marking rechecked in the supine position. (C) Further dissection of the anterior abdominal wall after completion of Cesarean section. (D) Plication of the rectus sheath and relocation of the umbilicus. (E) The excised skin and liposiphate. (F) The shape of the abdomen after performing full abdominoplasty.

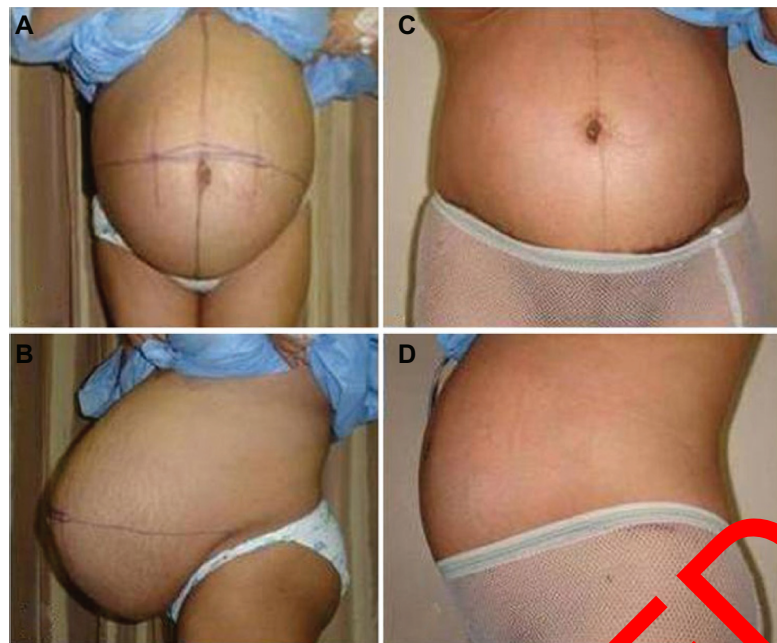
was carried out within the marked line 7 cm from the upper vaginal commissure. The level of the abdominoplasty incision was always below the level of the lower segment of Cesarean section or the lower end of the midline incision (Figure 1B). Dissection of the abdominal flap was carried out, reaching the umbilicus. An elliptical incision around the umbilicus was done, followed by dissection and separation of the umbilicus from the abdominal skin. Dissection of the abdominal flap was continued to the xiphisternum in the paramedian area with minimal lateral dissection. After completion of dissection, midline rectus sheath plication was carried out in two layers using 1/0 nonabsorbable sutures (Figure 1C). The operating table was bent to 45°, and an equal resection of the abdominal skin flap was performed. The abdominoplasty incision was temporarily closed with staples, and the operating table was returned to the flat position. Marking of the new umbilical site was performed at the level of the original umbilical stump. A 2 cm × 2 cm piece of elliptical skin was excised for the new umbilicus (Figure 1D). The skin underneath the new umbilical site was defatted, and the original umbilicus was delivered through it. With 2/0 Vicryl, three stitches were taken into the subdermis of the new umbilical hole at

3 o'clock, 6 o'clock, and 9 o'clock and tucked into the fascia of the anterior abdominal wall around the umbilical stump. The umbilicus was sutured with subcutaneous 4/0 Vicryl and 4/0 nonabsorbable interrupted stitches for the skin. The excised skin from each side was weighed and compared, in order to achieve symmetry. The total weight of skin excised ranged from 720 g to 1800 g with a mean of 1250 g. There was no statistically significant difference between the mean volume of liposuction and the weight of excised skin of the abdominoplasties combined with Cesarean delivery and that of nonpregnant women ( $P > 0.05$ ).

After insertion of two suction drains, the staples were removed and the abdominoplasty incision was sutured in layers: Scarpa's fascia with 1/0 Vicryl, the subcutaneous layer with 2/0 Vicryl, and the intradermal layer with 3/0 monocryl sutures (Figure 1E). A pressure garment was applied after cessation of surgery and worn for 2 months.

## Results

Of the 50 pregnant women included in this study, 24 patients (48%) were satisfied with the results after an average follow-up period of 9 months. Sixteen patients (32%)

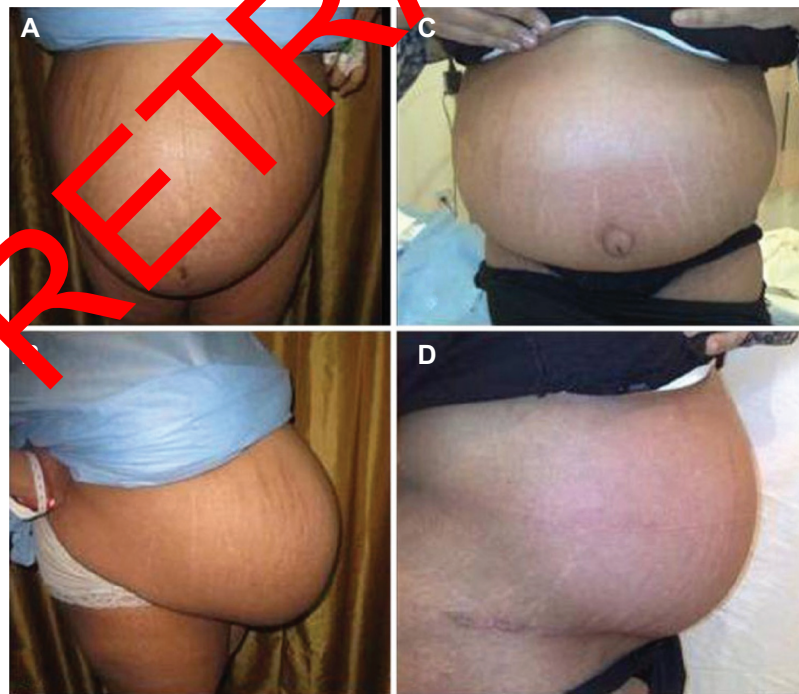


**Figure 2** The preoperative (A) front and (B) lateral views, of a 39-year-old, full-term pregnant woman. The (C) front and (D) lateral views, respectively, 6 months postoperatively.

**Note:** The patient has bulging of the abdomen and lack of waist definition.

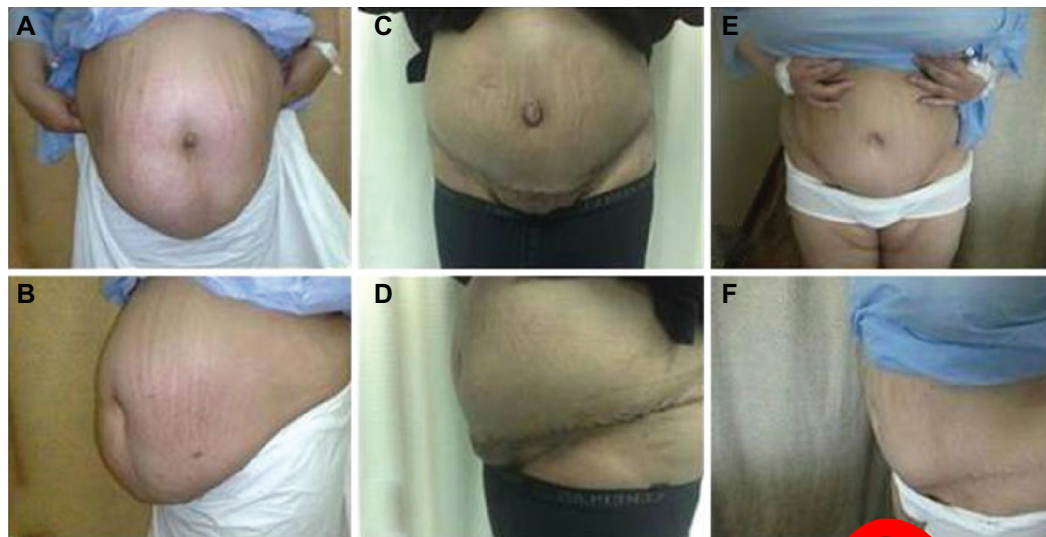developed persistent bulging of the abdomen, had lack of waist definition, and were not satisfied with the shape of their abdomen (Figures 2–4). Bulging of the umbilicus was reported in twelve patients (24%) (Figure 3). Excess skin redundancy was reported in nine patients (18%).

There were some postoperative complications (Table 2). Nine patients (18%) developed wound infection; three of them (6%) developed wound dehiscence. Wound infection was treated by frequent dressing and specific antimicrobials according to the culture and antibiotic sensitivity tests. Wound



**Figure 3** The preoperative (A) front and (B) lateral views of a 37-year-old, full-term pregnant woman. The (C) front and (D) lateral views 6 months postoperatively.

**Note:** The patient still has bulging of the abdomen, excess fat at the flanks, and bulging umbilicus.



**Figure 4** The preoperative (A) front and (B) lateral views of a 41-year-old, full-term pregnant woman. The (C) front and (D) lateral views 2 months postoperatively. Six months postoperatively, the patient still has (E) bulging of the abdomen and (F) residual skin redundancy.

dehiscence was treated by secondary sutures. Six patients (12%) developed a distal necrosis of the abdominal skin, some with skin infection. The largest area of skin necrosis measured 5 cm × 7 cm. Three patients healed by secondary intention after several weeks of conservative management. The other three patients needed surgical debridement and secondary sutures.

The results of 50 pregnant women were compared with the results of the abdominoplasties in 80 nonpregnant women with a normal BMI, which were done by the first two authors. Wound infection, wound dehiscence, and skin necrosis were reported in four (7.5%), two (2.5%), and three (3.7%) cases, respectively (Table 3). The aesthetics of the results were also compared with those of the nonpregnant women. Persistent abdominal bulging, outward bulging of the umbilicus, and abdominal skin redundancy were reported in seven (6.75%), four (8.75%), and three (3.75%) cases, respectively (Table 4).

**Table 2** Postoperative complications and their treatment

| No of patients (%) <sup>a</sup> | Complication         | Treatment   |
|---------------------------------|----------------------|---|
| 9 (18%)                         | Wound infection      | Frequent dressing and specific systemic antimicrobials  |
| 3 (6%)                          | Wound dehiscence     | Secondary sutures   |
| 6 (12%)                         | Distal skin necrosis | Conservative treatment in three patients and debridement with secondary sutures in the other three patients |

**Note:** <sup>a</sup>Total number of patients was 50.

The complication and unesthetic results as wound infection, wound dehiscence, and distal skin necrosis were higher in abdominoplasty combined with Cesarean section patients than in those with abdominoplasty alone, as shown in Table 3. However, although wound dehiscence was higher than that of abdominoplasty in nonpregnant women, the difference was statistically insignificant ( $P > 0.05$ ).

## Discussion

A pregnant full-term uterus (not including the baby, placenta, and fluids) weighs approximately 1000 g. In the 6 weeks following delivery, the uterus recedes to a weight of 50–100 g.<sup>6</sup> Immediately postpartum, the fundus of the uterus is palpable at or near the level of the maternal umbilicus.<sup>6,7</sup> Thereafter, most of the reduction in size and weight occurs in the first 2 weeks after delivery, at which time the uterus has shrunk enough to return to the true pelvis. Over the next several weeks, the uterus slowly returns to its nonpregnant state, although the overall uterine size remains larger than prior to gestation. The abdominal wall remains soft and poorly toned for many weeks. Recovery to the nonpregnant state requires several weeks.<sup>6</sup>

Before our study, a comprehensive search in the literature revealed no reports about abdominoplasty combined with Cesarean delivery. The main reason to combine abdominoplasty with Cesarean delivery is to contour the abdomen in the same setting as Cesarean delivery, avoiding a future surgical procedure under general anesthesia. This seems to be a good reason; however, it is good clinical practice for Cesarean deliveries to be performed under regional anesthesia as a first choice, and for general anesthesia to be reserved for patients

**Table 3** Comparison of the complications between abdominoplasty combined with Cesarean delivery and abdominoplasty in nonpregnant women

| Complication         | Abdominoplasty combined with Cesarean delivery (N = 50) (%) | Abdominoplasty in nonpregnant women (N = 80) (%) | P value |
|----------------------|---|--|---------|
| Wound infection      | 4 (18%)   | 4 (5%)   | 0.00294 |
| Wound dehiscence     | 3 (6%)  | 2 (2.5%)   | 0.497   |
| Distal skin necrosis | 6 (12%)   | 3 (3.75%)  | 0.0174  |

with contraindications or patient request, as Cesarean section under regional anesthesia is safer and results in less maternal and neonatal morbidity than under general anesthesia. This includes women who have a diagnosis of placenta previa according to the Royal College of Obstetricians and Gynaecologists/National Institute for Health and Clinical Excellence guidelines for Cesarean section in 2004, which were revised in 2011. In this study, 24 patients (48%) were satisfied with the overall results. More than 50% of the patients developed either postoperative complications or some unfavorable results.

Persistent bulging of the abdomen with lack of waist definition was the main unesthetic result. This may be due to limited liposuction from the supraumbilical paramedian areas and flanks, as well as inadequate contouring of the abdominal muscles due to a bulky uterus and congested muscles.<sup>1,4,5,8</sup> Outward bulging of the umbilicus is explained by the postpartum congested abdominal muscles and/or the increased intra-abdominal pressure in late pregnancy.<sup>1,8,9</sup> Lower abdominal excess skin redundancy was evident in a number of patients. This may be due to postpartum bulkiness of the uterus, which stretches the abdominal skin and minimizes the ability of the surgeon to properly estimate the extent of needed skin resection. A few months following delivery and after involution of the uterus, the skin relaxes and excess redundant abdominal skin becomes more apparent.

Wound infection, wound dehiscence, and distal skin necrosis were the reported postoperative complications. The increased rate of infection may be explained by the prolonged surgical time and contamination from the vaginal lochia.<sup>6,7,10</sup> Distal abdominal skin necrosis was the most

serious complication despite limited liposuction and limited undermining of the abdominal flap. We tried to find an explanation for the occurrence of skin necrosis at the distal abdominal skin. Intraoperative blood loss during abdominoplasty and the normal blood loss of Cesarean delivery may lead to postoperative anemia, which may be a contributing factor.<sup>10</sup> The other explanation might be ischemia reperfusion injury, which may occur at the abdominal skin flap due to the normal high vascularity in late pregnancy followed by a latent time of ischemia during dissection of the abdominal flap followed by reperfusion of the skin.<sup>11,12</sup> Combining liposuction with abdominoplasty may increase the risk of skin necrosis.<sup>13-15</sup> In this study, the mean volume of lipoaspirate was 375 cc in abdominoplasty combined with Cesarean delivery and 420 cc in abdominoplasties of nonpregnant women with no statistically significant difference ( $P < 0.05$ ). Despite liposuction in abdominoplasty of nonpregnant women, skin necrosis was less than that reported in abdominoplasty combined with Cesarean delivery.

We evaluated the advantages and the disadvantages of this practice in terms of ethics, pathology, and esthetics. All patients were at full-term pregnancy with complete fetal maturity. Although it may appear that it is quite worthy to combine two surgical procedures in the same setting, saving the patient from future surgery and general anesthesia, the higher incidence of postoperative complications, unesthetic results, and the dissatisfaction results in this study render this practice not recommended and not encouraged. Therefore, we recommend that this practice be limited and restricted to patients wishing to undergo only one surgical setting for both procedures, after clear

**Table 4** Comparison of unaesthetic results of abdominoplasty combined with Cesarean delivery versus those of abdominoplasty in nonpregnant women

| Complication                        | Abdominoplasty combined with Cesarean delivery (N = 50) (%) | Abdominoplasty in nonpregnant women (N = 80) (%) | P value |
|-------------------------------------|---|--|---------|
| Persistent bulging of abdomen       | 16 (32%)  | 7 (8.75%)  | 0.0002  |
| Bulging of umbilicus                | 12 (24%)  | 4 (5%)   | 0.0002  |
| Recurrent abdominal skin redundancy | 6 (12%)   | 3 (3.75%)  | 0.0174  |

explanation and emphasis on the side effects and the possible unsatisfactory esthetic results.

## Disclosure

The authors report no conflicts of interest in this work.

## References

1. Coldron Y, Stokes MJ, Newham DJ, Cook K. Postpartum characteristics of rectus abdominis on ultrasound imaging. *Man Therapy*. 2008;13(2):112–121.
2. Muallem MM, Rubeiz NG. Physiological and biological skin changes in pregnancy. *Clin Dermatol*. 2006;24(2):80–88.
3. Placek PJ, Taffel SM. Recent patterns in Cesarean delivery in the United States. *Obstet Gynecol Clin North Am*. 1988;15(4):607–627.
4. Al-Qattan MM. Abdominoplasty in multiparous women with severe musculoaponeurotic laxity. *Br J Plast Surg*. 1997;50(6):450–455.
5. Borg-Stein J, Dugan SA. Musculoskeletal disorders of pregnancy, delivery and postpartum. *Phys Med Rehabil Clin N Am*. 2007;18(3):459–476.
6. Oppenheimer LW, Sherriff EA, Goodman JD. The duration of lochia. *Br J Obstet Gynaecol*. 1986;93(7):754–757.
7. Sherman D, Lurie S, Frenkel E. Characteristics of normal lochia. *Am J Perinatol*. 1999;16(8):399–402.
8. Jozwik M, Lotocki W, Józwik M. Vascular anatomy of the anterior abdominal wall in gynecology and obstetrics. *Am J Obstet Gynecol*. 1995;172(6):1944–1945.
9. Paramore RH. The intra-abdominal pressure in pregnancy. *Lancet*. 1913;181(4686):1725–1727.
10. Kryger ZB, Dumanian GA, Howard MA. Safety issues in combined gynecologic and plastic surgical procedures. *Int J Gynecol Obstet*. 2007;99(3):257–263.
11. Harris NR, Rumbaut RE. Age-related responses of the microcirculation to ischemia-reperfusion and inflammation. *Pathophysiology*. 2001;8(1):1–10.
12. Van den Heuvel MG, Buurman WA, Bast A, van der Hulst RR. Review: ischaemia-reperfusion injury in flap surgery. *J Plast Reconstr Aesthet Surg*. 2009;62(6):721–726.
13. Matarasso A. Abdominoplasty: a system of classification and treatment for combined abdominoplasty and suction-assisted lipectomy. *Aesthet Plast Surg*. 1991;15(2):111–121.
14. Stewart KJ, Stewart DA, Coolidge B, Harrison DH, Jones BM, Waterhouse N. Complication of 278 consecutive abdominoplasties. *J Plast Reconstr Aesthet Surg*. 2006;59(11):1152–1155.
15. Heller JB, Teng E, Kroll BJ, Persing J. Outcome analysis of combined lipoabdominoplasty versus conventional abdominoplasty. *Plast Reconstr Surg*. 2008;121(5):1824–1829.

RETRACTED

International Journal of Women's Health

Publish your work in this journal

The International Journal of Women's Health is an international, peer-reviewed open-access journal publishing original research, reports, reviews and commentaries on all aspects of women's healthcare including gynecology, obstetrics, and breast cancer. Subject areas include: Chronic conditions (migraine headaches, arthritis, osteoporosis);

Submit your manuscript here: <http://www.dovepress.com/international-journal-of-womens-health-journal>

Endocrine and autoimmune syndromes; Sexual and reproductive health; Psychological and psychosocial conditions. The manuscript management system is completely online and includes a very quick and fair peer-review system. Visit <http://www.dovepress.com/testimonials.php> to read real quotes from published authors.