

Retinal ganglion cell function after repeated intravitreal injections of ranibizumab in patients with age-related macular degeneration

Tomoharu Nishimura
Shigeki Machida
Tomomi Harada
Daijiro Kurosaka

Department of Ophthalmology,
Iwate Medical University School
of Medicine, Morioka, Iwate, Japan

Background: The purpose of this study was to evaluate the safety of intravitreal ranibizumab injection in patients with age-related macular degeneration.

Materials and methods: We examined retinal ganglion cell function using the photopic negative response of the electroretinogram (ERG) in patients with age-related macular degeneration (AMD) treated with intravitreal injections of ranibizumab. We studied 32 eyes of 32 patients with AMD and aged 50–84 years with a mean of 71 years. An intravitreal ranibizumab injection was given three times at monthly intervals. Additional injections were given according to an optical coherence tomography-guided variable dosing regimen. ERG recordings were made before treatment (baseline) and at 3, 6, 9, and 12 months postoperatively. Full-field cone ERGs were elicited by red stimuli on a blue background. The focal macular ERGs were elicited by a 15 degree white stimulus spot centered on the macular region. We measured the amplitudes of the a and b waves, oscillatory potentials, and the photopic negative response of the full-field cone and focal macular ERGs.

Results: Visual acuity was significantly better than the baseline acuity, and macular thickness was significantly reduced after the intravitreal injections of ranibizumab. The amplitudes and implicit times of each wave of the full-field cone ERGs were not significantly changed after intravitreal ranibizumab injections. However, the amplitudes of each wave of the focal macular ERGs were increased after the injections. The implicit times of the a and b waves of the focal macular ERGs were significantly shortened after intravitreal injections of ranibizumab. The ratio of the full-field and focal photopic negative response/b-wave amplitude was not significantly changed after the injections.

Conclusion: The amplitudes of the focal macular ERGs, including the photopic negative response improved after repeated intravitreal ranibizumab injections, accompanied by a recovery of visual acuity and macular structure. The results of the full-field cone ERGs indicate that retinal ganglion cell function was not altered by repeated intravitreal ranibizumab injection.

Keywords: age-related macular degeneration, retinal ganglion cell, photopic negative response, electroretinogram, ranibizumab

Introduction

Vascular endothelial growth factor A (VEGF-A) plays an important role in the retina under physiological and pathological conditions. VEGF-A is a mitogenic factor that is known to be an inducer of pathological neovascularization in intraocular diseases, such as in age-related macular degeneration (AMD). However, a number of studies have shown that VEGF-A can act favorably as a neurotrophic or survival-promoting factor for different cell types, including neural, glial, and vascular endothelial cells.¹ Anti-VEGF-A monoclonal antibody inhibits all biologically active isoforms

Correspondence: Shigeki Machida
Department of Ophthalmology,
Iwate Medical University School of
Medicine, 19-1 Uchimaru, Morioka,
Iwate 020-8505, Japan
Tel +81 | 9651 5111 ext 6902 or 8691
Fax +81 | 9653 2864
Email smachida@iwate-med.ac.jp

of VEGF-A. Repeated intravitreal injections of anti-VEGF-A monoclonal antibody have been reported to cause degeneration of retinal ganglion cells in rats.²

Anti-VEGF-A therapy has emerged as a new and promising treatment for exudative AMD. Large, multicenter, randomized, double-masked, controlled clinical trials have shown that intravitreal injections of ranibizumab (IVR), a recombinant, humanized monoclonal anti-VEGF-A antibody antigen-binding fragment (Fab), significantly improves central vision in patients with AMD.³⁻⁵ To maintain the benefit from IVR on vision in AMD patients, multiple injections are needed based on the evidence from clinical trials.⁶ Thus, a toxic effect of the anti-VEGF-A monoclonal antibody on retinal ganglion cells has been a concern when repeated injections of ranibizumab are used to treat AMD patients.^{2,7}

There are a few objective methods used to measure the function of retinal ganglion cells. The photopic negative response (PhNR) of the full-field cone electroretinograms (ERGs) is a functional indicator of retinal ganglion cells.⁸ The PhNR consists of a negative-going wave that follows the photopic cone b wave. The PhNR is selectively attenuated in patients with optic nerve disease and glaucoma,⁹⁻¹³ indicating that the PhNR can be an objective functional measure reflecting the sum of the total response of the retinal ganglion cells in the entire retina.

Miyake et al¹⁴ developed an ERG eliciting and recording system which allowed them to record responses from focal retinal areas while viewing the location of small stimulus spots on the ocular fundus. Previous studies have demonstrated that the PhNR of the focal macular ERG represents the retinal ganglion cell function of the macula.¹⁵⁻²⁰ Therefore, examinations of both full-field and focal macular ERG recordings should allow us to test the retinal ganglion cell function of the entire retina and the macular area.

The results of animal and clinical experiments have shown that the retinal function evaluated by the ERGs is not affected by IVR.²¹⁻²³ Sheybani et al²³ have demonstrated that the pattern ERG driven by retinal ganglion cells^{24,25} did not alter in AMD patients treated with IVR, indicating that repeated VEGF inhibition does not lead to retinal ganglion cell damage in the posterior pole of the retina. However, the PhNR representing retinal ganglion cell function after IVR has been under investigation. To evaluate the safety of IVR, we examined retinal ganglion cell function using the PhNR of full-field and focal macular ERGs in patients with AMD treated with IVR.

Materials and methods

Subjects

We studied 32 eyes of 32 patients with choroidal neovascularization secondary to AMD. There were 25 men and seven women of mean age 70.7 ± 7.8 (range 50–84) years. The patients were treated in the Retina Unit of Iwate Medical University Hospital. Twenty-one eyes had typical AMD and 11 had polypoidal choroidal vasculopathy. All patients had ophthalmological examinations, including measurement of the visual acuity by a Snellen chart, indirect ophthalmoscopy, and biomicroscopic slit-lamp examination of the fundus.

This research was conducted in accordance with the institutional guidelines of Iwate Medical University, and the procedures conformed to the tenets of the Declaration of Helsinki. An informed consent was obtained from all subjects after a full explanation of the nature of the experiments.

Angiography and OCT

Fluorescein angiography and indocyanine green angiography were performed before and 3 months after the treatments. The retinal morphology was evaluated by spectral-domain optical coherence tomography (SD-OCT, Spectralis, Heidelberg Engineering, Heidelberg, Germany). The SD-OCT scans passed through the fovea horizontally and vertically. The foveal thickness was measured from the inner limiting membrane to outer border of the retinal pigment epithelium. When a retinal pigment epithelial detachment was present, the foveal thickness was measured from the inner limiting membrane to Bruch's membrane instead of the retinal pigment epithelium. The averaged foveal thickness was obtained by averaging the horizontal and vertical thickness.

Treatments and follow-up regimen

Ranibizumab 0.5 mg was injected into the vitreous with a 30 G needle through the pars plana at monthly intervals for 3 months. The patients were examined monthly for the following 9 months. At each visit, the best-corrected visual acuity, OCT, and ophthalmoscopy of the ocular fundus were determined. Additional IVR was given according to the OCT-guided variable-dosing regimen used in the PRONTO study.²⁶

ERG recordings

The pupils were dilated to approximately 8 mm in diameter by topical 0.5% tropicamide and 0.5% phenylephrine HCL. The recordings of the full-field and focal ERGs were made on the same day. The stimulus conditions for the recordings of

the full-field cone ERGs and focal ERGs have been reported in detail.^{13,16}

The full-field cone ERGs were elicited by red stimuli of 1600 cd/m² ($\lambda_{\text{max}} = 644$ nm, half-amplitude bandwidth = 35 nm) on a blue background of 40 cd/m² ($\lambda_{\text{max}} = 470$ nm, half-amplitude bandwidth = 18 nm). The duration of the stimulus was 3 msec. The stimulus and background lights were produced by light emitting diodes embedded in the contact lens (Mayo Company Nagoya, Japan). Thirty to 50 responses were averaged for full-field cone ERGs.

Immediately after recording the full-field cone ERGs, we started to prepare for recording of the focal macular ERGs. The interval between the full-field and focal macular ERGs was approximately 5 minutes. Focal ERGs were recorded from the macular area. The stimulus system was integrated into the infrared fundus camera (Mayo Co, Nagoya, Japan) developed by Miyake et al.¹⁴ The stimulus spot was 15 degrees in diameter and was centered on the macula, and the position was confirmed by viewing the ocular fundus on a monitor. The intensity of the white stimulus and background lights was 165 cd/m² and 6.9 cd/m², respectively. The stimulus duration was 10 msec. The focal ERGs were recorded with a Burian-Allen bipolar contact lens electrode (Hansen Ophthalmic Laboratories, Iowa City, IA). Approximately 300 responses were averaged for focal macular ERGs.

The a wave and b wave amplitudes were measured from baseline to the trough of the first negative response and from the first trough to the peak of the following positive wave, respectively. The PhNR amplitude was measured from the baseline to the negative trough at 65 msec for the full-field and at 70 msec for the focal PhNR according to the findings in earlier studies.^{11,13,16} For the oscillatory potentials (OPs), the ERGs were digitally filtered between 100 and 1000 Hz for the full-field cone ERGs and between 50 and 500 Hz for the focal ERGs. The amplitudes of OP1, OP2, and OP3 were measured and summed, and designated as Σ OPs, as previously reported.^{16,27}

Statistical analyses

Two-tailed paired Student's *t*-tests were used to compare the pretreatment and post-treatment data to determine the statistical significance of the differences. $P < 0.05$ was taken to be statistically significant. Pearson's coefficient of correlation was calculated to determine the degree of correlation between the number of injections and postoperative changes in the ERGs.

Results

Representative case

The ERGs from a representative case treated with three IVR without additional treatments in a year are shown in Figure 1. This case had an occult choroidal neovascularization with late dye leakage on fluorescein angiography. Indocyanine green angiography showed late staining in the area corresponding to the occult choroidal neovascularization. OCT demonstrated a serous retinal detachment. After the three IVR, the serous retinal detachment disappeared, with improvement in best-corrected visual acuity. The a wave and b wave amplitudes of the focal macular ERGs gradually increased postoperatively. The full-field cone ERGs were unchanged throughout the observation period.

Changes in best-corrected visual acuity and foveal thickness

Changes in best-corrected visual acuity and foveal thickness with increasing post-injection times are shown in Figure 2. Best-corrected visual acuity (in logMAR units) improved significantly compared with baseline at 3 months after IVR ($P < 0.005$). Thereafter, best-corrected visual acuity did not change significantly, but at 12 months it was still significantly better than the best-corrected visual acuity at baseline ($P < 0.05$, Figure 2A).

Foveal thickness measured by OCT decreased significantly at 3 months post-injection ($P < 0.05$) and remained unchanged until 6 months (Figure 2B). At 6 months, it was still significantly thinner than at baseline ($P < 0.0005$). There was no significant difference in best-corrected visual acuity and foveal thickness between eyes with typical AMD and polypoidal choroidal vasculopathy.

Comparison of preoperative and postoperative ERGs

Changes in the amplitudes and implicit times of each component of the focal macular and full-field cone ERGs as a function of months after IVR are shown in Figures 3–6. For the full-field ERGs, the amplitudes and implicit times were not significantly different from baseline values at any time (Figures 3, 5A, 6A, and B).

The changes of each parameter of the focal macular ERGs as a function of months after initiation of IVR are shown in Figure 4. Before IVR, the amplitudes of the a waves and b waves, Σ OPs, and PhNR of the focal macular ERGs were significantly decreased in affected eyes compared with unaffected eyes ($P < 0.000001$). After the IVR, the

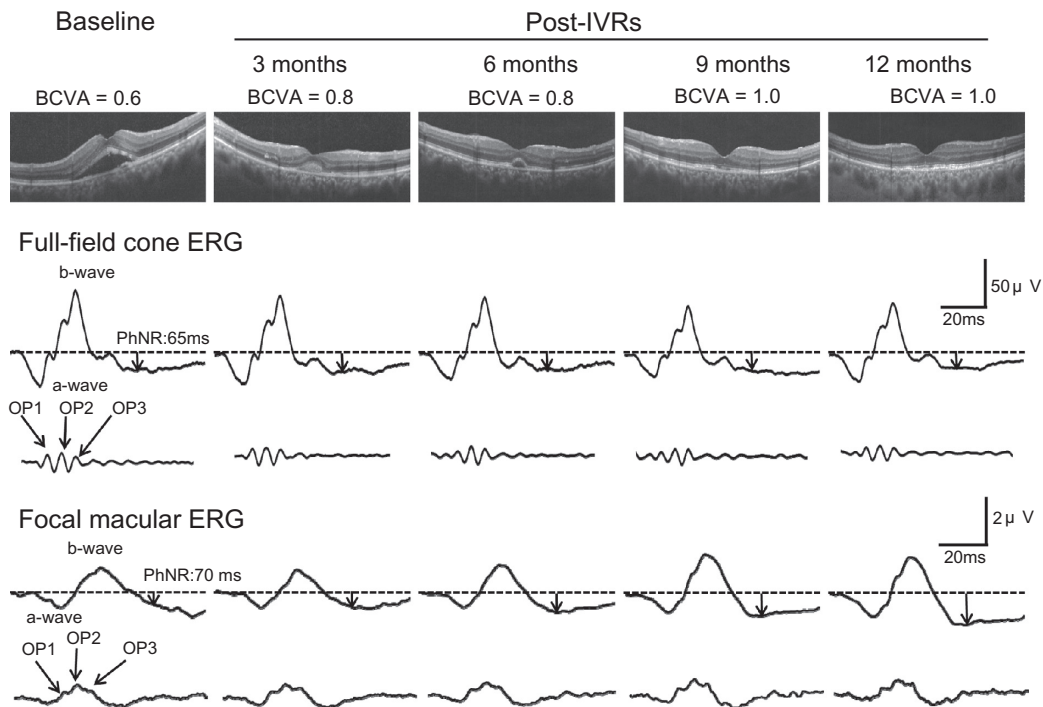


Figure 1 Findings in a representative case of age-related macular degeneration associated with an occult choroidal neovascularization. The eye was treated with three-monthly intravitreal injections of ranibizumab. The serous retinal detachment promptly disappeared after three injections. There was no change in waveforms and amplitudes of the full-field cone electroretinograms after three intravitreal injections of ranibizumab. The amplitudes of the focal macular electroretinograms are slightly larger at 6 months and thereafter.

Abbreviations: IVRs, intravitreal injections of ranibizumab; BCVA, best corrected visual acuity; ERG, electroretinogram; PhNR, photopic negative response; OP, oscillatory potential.

averaged amplitude of the focal macular ERGs increased, and significant recovery was observed at 3, 6, and 12 months after starting the IVR (Figure 4, $P < 0.05-0.0005$). The degree of recovery of the b wave and PhNR after the IVR was not significantly different. As a result, the PhNR/b wave

amplitude ratio was unchanged throughout the observation period (Figure 5B).

Before IVR, the averaged implicit times of the a waves and b waves of the focal macular ERGs were significantly longer in affected eyes than in unaffected eyes ($P < 0.005$

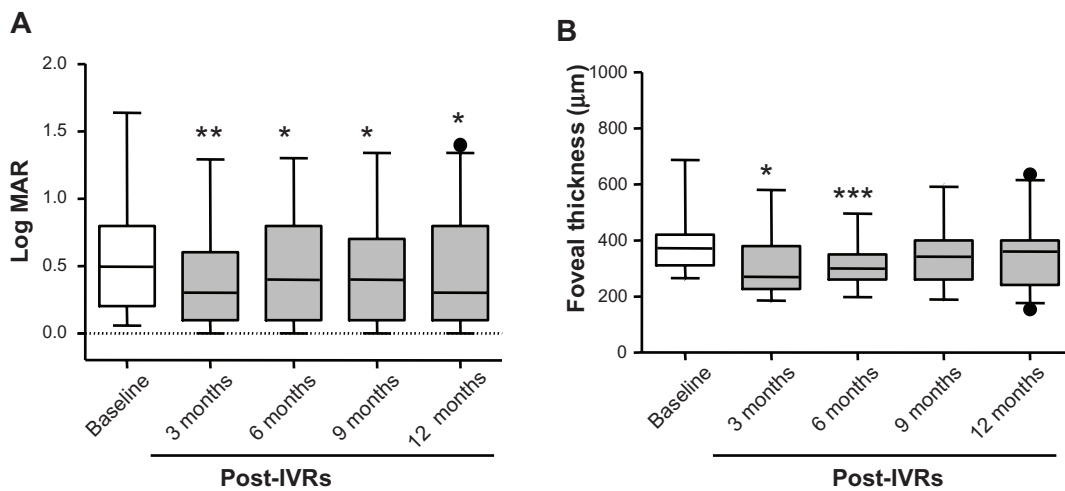


Figure 2 Averaged best-corrected visual acuity in logarithm of the minimum angle resolution (logMAR) units before and after intravitreal injections of ranibizumab (IVRs). **(A)** Averaged foveal thickness measured by optic coherence tomography before and after IVRs. **(B)** The white boxes represent the values before (baseline) and the gray boxes the values after IVRs.

Notes: The boxes represent the 25%–75% interquartile ranges. The horizontal line represents median values, and the bars represent the 5% and 95% confidence intervals. Filled circles represent data beyond the confidence intervals. * $P < 0.05$; ** $P < 0.005$; *** $P < 0.0005$.

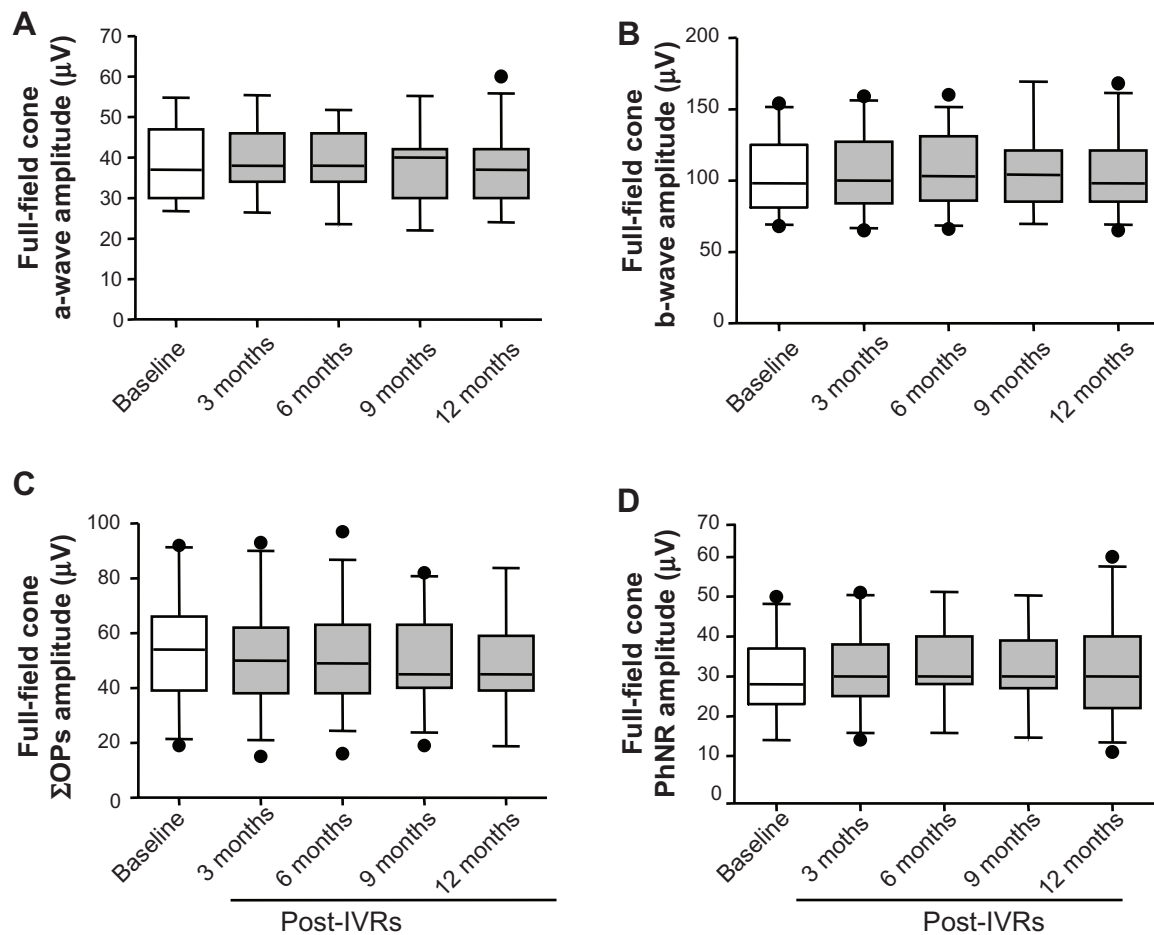


Figure 3 Averaged amplitudes of a waves (A) and b waves (B), oscillatory potentials (OPs), (C) and photopic negative response (PhNR), (D) for full-field cone electroretinograms. **Notes:** The white boxes represent values before (baseline) and the gray boxes after intravitreal injections of ranibizumab (IVRs). The boxes represent 25%–75% interquartile ranges. The horizontal line represents median values, and the bars represent the 5% and 95% confidence intervals. Filled circles represent data beyond the confidence intervals.

for a wave; $P < 0.05$ for b wave). After IVR, the implicit times were significantly shortened compared with baseline values ($P < 0.05$ – 0.005 , Figures 6C and D). There was no significant difference in amplitudes and implicit times of all ERG components in eyes with typical AMD and polypoidal choroidal vasculopathy.

Correlation of number of treatments with ERG changes

The number of IVR ranged from three to seven, with a mean of 4.09 for the 12-month observation period. The differences in PhNR amplitude and PhNR/b wave amplitude ratio between baseline and 12 months after the IVR were plotted against numbers of IVR for the full-field (Figure 7A and B) and focal macular ERGs (Figure 7C and D). There was no significant correlation between the number of IVR and changes in PhNR amplitude and PhNR/b wave amplitude ratio for the full-field ERG. Focal PhNR amplitude was significantly reduced with numbers of IVR ($r = 0.21$; $P < 0.01$). However,

the focal PhNR/b wave amplitude ratio was not significantly correlated with number of IVR.

Discussion

We examined the photopic full-field and focal macular ERGs in AMD patients before and after three consecutive monthly IVR. Our results demonstrate that full-field cone ERGs did not change significantly after IVR at any time. However, focal macular ERGs were significantly improved, and accompanied by recovery of central vision and the anatomical structure of the macula. These findings indicate that IVR did not have adverse effects on any retinal layers, including the retinal ganglion cells.

Full-field and focal macular ERG changes

The full-field cone ERGs represent the sum of the electrical activities of all of the retinal neurons in the cone pathway. Therefore, the absence of any significant changes in the amplitudes and implicit times of the a waves and b waves, OPs, and

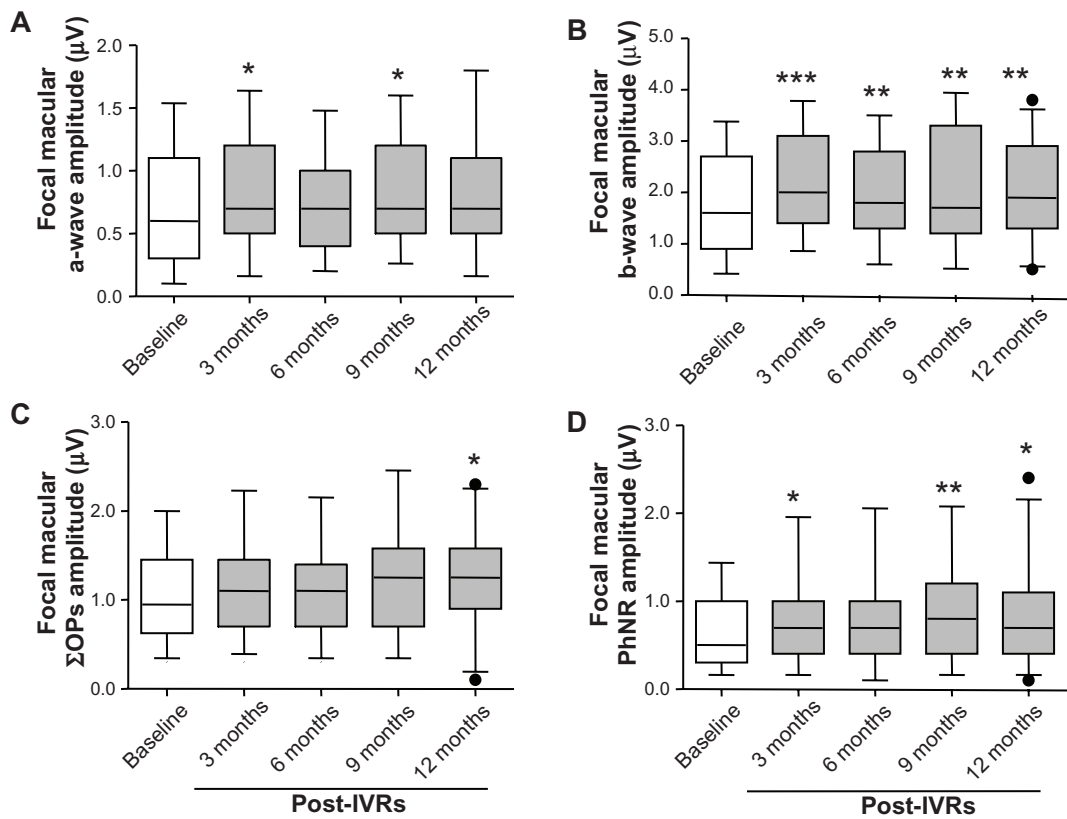


Figure 4 Averaged amplitudes of a waves (A) and b waves (B), oscillatory potentials (OPs), (C) and photopic negative response (PhNR), (D) for focal macular electroretinograms. **Notes:** The white boxes represent values before (baseline) and the gray boxes after intravitreal injections of ranibizumab (IVRs). The boxes represent 25%–75% interquartile ranges. The horizontal line represents the median values, and the bars represent 5% to 95% confidence intervals. Filled circles represent data beyond the confidence intervals. * $P < 0.05$; ** $P < 0.005$; *** $P < 0.0005$.

PhNR indicate that cells in each retinal layer, including the cone photoreceptors, cone bipolar cells, amacrine cells, and retinal ganglion cells of the entire retina, were not affected by IVR.

On the other hand, the amplitudes and implicit times of the focal macular ERGs did improve in association with recovery

of central vision and disappearance of exudative changes. These findings are compatible with an earlier report that the amplitude of multifocal ERGs increased after anti-VEGF therapy.^{22,28} Recovery of outer retinal function probably led to an increase in signals to the inner retina, resulting in an

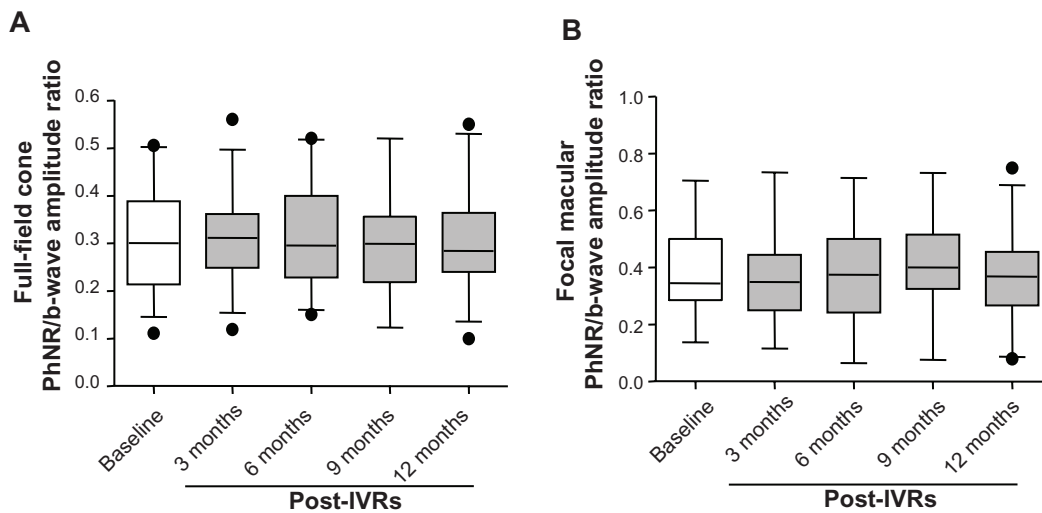


Figure 5 Averaged amplitude ratio of the photopic negative response (PhNR)/b wave for the full-field cone (A) and focal macular electroretinograms. (B) The white boxes represent values before (baseline) and the gray boxes after the intravitreal injections of ranibizumab (IVRs). **Notes:** The boxes represent the 25%–75% interquartile ranges. The horizontal line represents median values, and the bars represent 5% and 95% confidence intervals. Filled circles represent data beyond the confidence intervals.

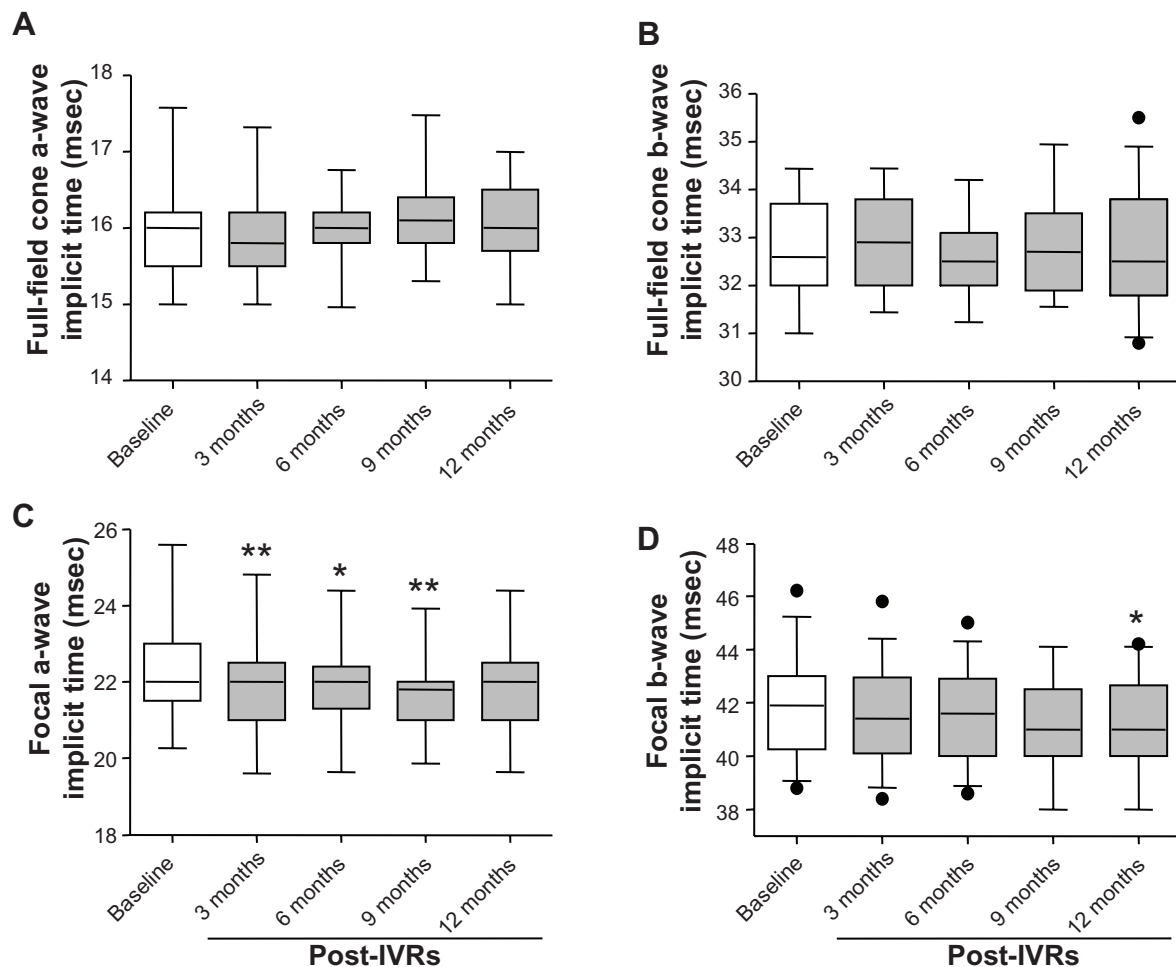


Figure 6 Averaged implicit times of a waves and b waves for full-field cone (A and B) and focal macular electroretinograms. (C and D).

Notes: The white boxes represent the values before (baseline) and the gray boxes after the intravitreal injections of ranibizumab (IVRs). The boxes represent the 25%–75% interquartile ranges. The horizontal line represents median values, and the bars represent 5% and 95% confidence intervals. Filled circles represent data beyond the confidence intervals. * $P < 0.05$; ** $P < 0.005$.

increase of Σ OPs and PhNR amplitudes in the focal macular ERGs. However, the increased PhNR amplitude of the focal macular ERG does not necessarily indicate an increase in the activity of retinal ganglion cells. Because of this, we used the PhNR/b wave amplitude ratio as a functional indicator of retinal ganglion cells in the focal macular ERGs. The amplitude ratio did not change after treatment, suggesting that IVR did not adversely affect the retinal ganglion cell function of the macula.

Comparison with results of earlier studies

It has been reported that repeated intravitreal injections of anti-VEGF-A monoclonal antibody lead to degeneration of retinal ganglion cells in rats.² This is inconsistent with our observation that the amplitude of the PhNR of the full-field and focal macular ERGs did not decrease. There are several possible reasons for this difference. First, there

was a difference in the protocol of injections between these studies. Nishijima et al injected anti-VEGF-A monoclonal antibody weekly for 6 weeks, in contrast with our monthly injections for the first 3 months and additional injections when needed.^{2,26} Second, ranibizumab is a Fab with a lower molecular weight than the full-length antibody, and its half-life in the vitreous is approximately one-half of that of full-length bevacizumab.^{29,30} Therefore, intraocular ranibizumab is quickly leached out after each injection, which may be less toxic to retinal ganglion cells.

The number of injections was not significantly correlated with changes in the full-field cone ERG components, including PhNR. These findings indicate that the dose-dependent toxic effect was not seen in patients after multiple IVR. This is consistent with the results of an earlier study demonstrating that an average of 16 IVR did not adversely affect retinal nerve fiber layer thickness around the optic nerve head, as measured by OCT.³¹

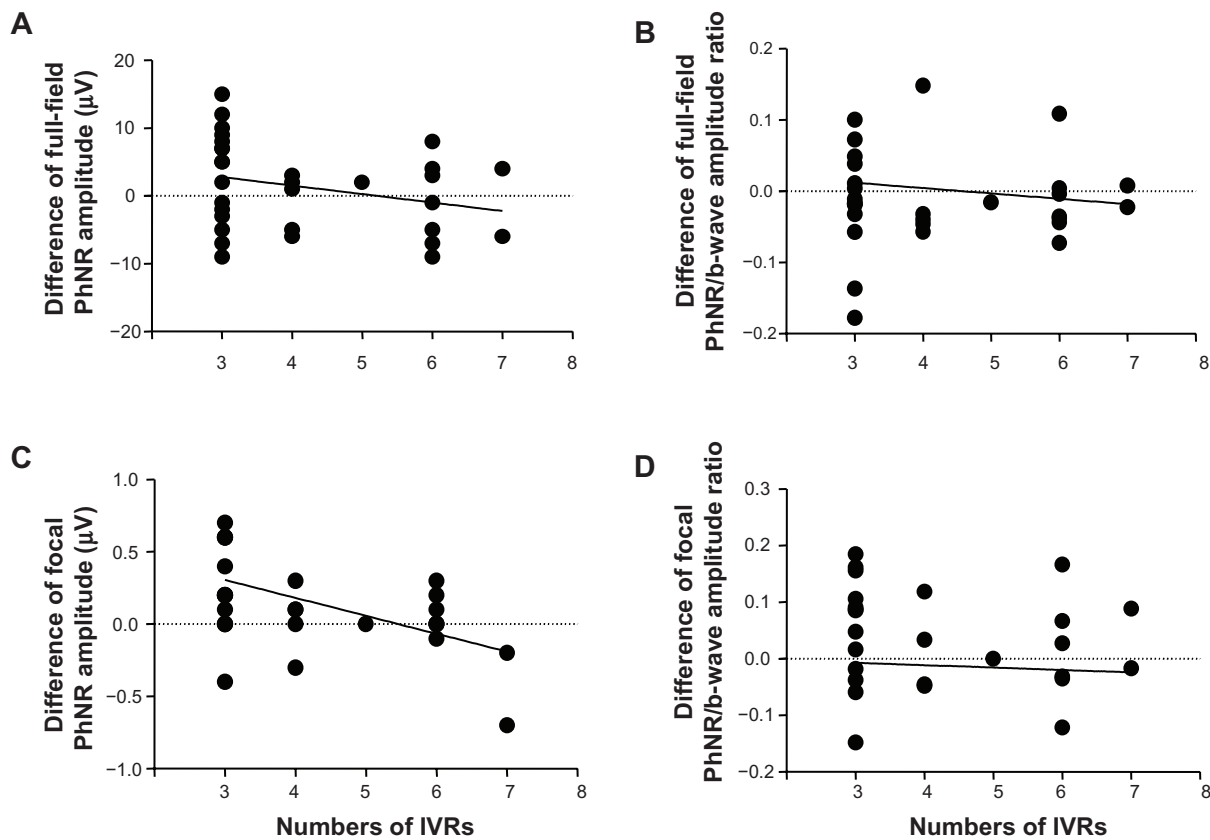


Figure 7 Photopic negative response (PhNR) amplitudes and PhNR/b wave amplitude ratios of the baseline and 12 months after the intravitreal injections of ranibizumab (IVRs) are plotted against the number of IVRs for the full-field (A and B) and focal macular electroretinograms (C and D).

Effect of vasoconstriction and retinal ischemia on PhNR and OPs

We have reported that, after a central retinal artery occlusion, PhNR amplitude was predominantly reduced with relatively good preservation of the b wave.³² It has also been reported that PhNR is reduced in eyes with a central retinal vein occlusion or with diabetic retinopathy.^{27,33,34} These observations indicate that the PhNR could be a good indicator of retinal function in ischemic diseases of the retina. The OPs represent the neural activity of the inner retina and has been used as a sensitive indicator of retinal ischemia, such as in eyes with diabetic retinopathy.³⁵

It was shown that IVR can induce retinal arteriolar vasoconstriction that worsens with time.³⁶ In an animal experiment, it was shown that intravitreal injections of anti-VEGF-A antibody resulted in closure of retinal capillaries.³⁷ Previous clinical reports have suggested that retinal ischemia became worse following intravitreal administration of anti-VEGF-A antibody.^{38–40} Taken together, if retinal ischemia develops after IVR, this is important because it can lead to glutamate excitotoxicity, to which retinal ganglion cells are particularly susceptible.⁴¹ The ischemia should then reduce

the amplitudes of the PhNR and OPs, but our results show that they were not significantly changed, indicating that retinal ischemia after the IVR, if it occurred, did not alter the function of the inner retina of our AMD patients.

Correlation between PhNR changes and number of IVR

In cases that required additional IVR, focal macular ERG amplitudes were reduced despite the treatments because of recurrences of exudative changes. We found a significant correlation between changes in PhNR amplitudes of the focal macular ERGs and the number of IVR. However, this does not indicate a decrease in retinal ganglion cell function because the focal PhNR/b wave amplitude ratio was not significantly correlated with the number of treatments. This suggests that exudation affected the outer retina which then reduced the signal to the middle and inner retina in the macular area.

Study limitations

One limitation of this study is the fact that we recorded only cone-mediated ERGs. Therefore, we cannot rule out

possible impairment of retinal ganglion cell function in the rod-mediated pathway. The scotopic threshold response^{42,43} is a negative-going wave recorded by very weak stimuli under dark adaptation, representing retinal ganglion cell function in the rod-mediated pathway.⁴⁴ Recording the scotopic threshold response is difficult in the clinic because complete dark adaptation is required for the recordings. In addition, the cellular origin of the scotopic threshold response is still controversial in humans.⁴⁵ Therefore, we decided to evaluate the retinal ganglion cell function by analyzing the PhNR.

Conclusion

The amplitudes of focal macular ERGs, including PhNR, improved after repeated IVR, accompanied by recovery of visual acuity and macular structure. Results of the full-field cone ERG indicate that retinal ganglion cell function in the cone-mediated pathway is not altered by repeated IVR.

Acknowledgment

This study was supported by a Grant-in-Aid for Scientific Research to SM from the Ministry of Education, Science, and Culture in Japan (20592056).

Disclosure

The authors report no conflicts of interest in this work.

References

1. Storkebaum E, Lambrechts D, Carmeliet P. VEGF: once regarded as a specific angiogenic factor, now implicated in neuroprotection. *Bio Essays*. 2004;26:943–954.
2. Nishijima K, Ng YS, Zhong L, et al. Vascular endothelial growth factor-A is a survival factor for retinal neurons and a critical neuroprotectant during the adaptive response to ischemic injury. *Am J Pathol*. 2007; 171:53–67.
3. Brown DM, Kaiser PK, Michels M, et al. Ranibizumab versus verteporfin for neovascular age-related macular degeneration. *N Engl J Med*. 2006;355:1432–1444.
4. Rosenfeld PJ, Brown DM, Heier JS, et al. MARINA study group: ranibizumab for neovascular age-related macular degeneration. *N Engl J Med*. 2006;355:1419–1431.
5. Brown DM, Michels M, Kaiser PK, et al. ANCHOR study group: ranibizumab versus verteporfin photodynamic therapy for neovascular age-related macular degeneration: two-year results of the ANCHOR study. *Ophthalmology*. 2009;116:57–65.
6. Mitchell P, Korobelnik JF, Lazzetta P, et al. Ranibizumab (Lucentis) in neovascular age-related macular degeneration: evidence from clinical trials. *Br J Ophthalmol*. 2010;94:2–13.
7. Van Wijngaarden P, Coster DJ, Williams KA. Inhibitors of ocular neovascularization: promises and potential problems. *JAMA*. 2005;293: 1509–1513.
8. Viswanathan S, Frishman LJ, Robson JG, et al. The photopic negative response of the macaque electroretinogram: reduction by experimental glaucoma. *Invest Ophthalmol Vis Sci*. 1999;40:1124–1136.
9. Viswanathan S, Frishman LJ, Robson JG, Walter JW. The photopic negative response of the flash electroretinogram in primary open angle glaucoma. *Invest Ophthalmol Vis Sci*. 2001;42:514–522.
10. Gotoh Y, Machida S, Tazawa Y. Selective loss of the photopic negative response in patients with optic nerve atrophy. *Arch Ophthalmol*. 2004; 122:341–346.
11. Rangaswamy NV, Frishman LJ, Dorotheo EU, et al. Photopic ERGs in patients with optic neuropathies: comparison with primate ERGs after pharmacological blockade of inner retina. *Invest Ophthalmol Vis Sci*. 2004;45:3827–3837.
12. Miyata K, Nakamura M, Kondo M, et al. Reduction of oscillatory potentials and photopic negative response in patients with autosomal dominant optic atrophy with OPA1 mutations. *Invest Ophthalmol Vis Sci*. 2007;48:820–824.
13. Machida S, Gotoh Y, Toba Y, et al. Correlation between photopic negative response and retinal nerve fiber layer thickness and optic disc topography in glaucomatous eyes. *Invest Ophthalmol Vis Sci*. 2008;49: 2201–2207.
14. Miyake Y, Yanagida K, Kondo K, Ota I. Subjective scotometry and recording of local electroretinogram and visual evoked response. System with television monitor of the fundus. *Jpn J Ophthalmol*. 1981;25:439–448.
15. Colotto A, Falsini B, Salgarello T, et al. Photopic negative response of the human ERG: losses associated with glaucomatous damage. *Invest Ophthalmol Vis Sci*. 2000;41:2205–2211.
16. Machida S, Toba Y, Ohtaki A, et al. Photopic negative response of focal electroretinogram in glaucomatous eyes. *Invest Ophthalmol Vis Sci*. 2008;49:5636–5644.
17. Machida S, Tamada K, Oikawa T, et al. Sensitivity and specificity of photopic negative response of focal electroretinograms in detecting glaucomatous eyes. *Br J Ophthalmol*. 2010;94:202–208.
18. Machida S, Tamada K, Oikawa T, et al. Comparison of photopic negative response between full-field and focal electroretinograms in detecting glaucomatous eyes. *J Ophthalmol*. September 30, 2010. [Epub ahead of print.]
19. Kondo M, Kurimoto Y, Sakai T, et al. Recording focal macular photopic negative response (PhNR) from monkeys. *Invest Ophthalmol Vis Sci*. 2008;49:3544–3550.
20. Tamada K, Machida S, Oikawa T, et al. Correlation between photopic negative response of focal electroretinograms and local loss of retinal neurons in glaucoma. *Curr Eye Res*. 2010;35:155–164.
21. Bhurayanontachai P, Ratanasukon M, Jirattanasopa P. Electrophysiologic changes after intravitreal ranibizumab injection for the treatment of choroidal neovascular membrane (CNVM). *Clin Ophthalmol*. 2011;5:567–572.
22. Lüke M, Januschowski K, Lüke J, et al. Effects of ranibizumab (Lucentis) on retinal function in isolated vertebrate retina. *Br J Ophthalmol*. 2009;93:1396–1400.
23. Sheybani A, Brantley MA Jr, Apte RS. Pattern electroretinography in age-related macular degeneration. *Arch Ophthalmol*. 2011;129:580–584.
24. Mafei L, Fiorrentini A, Bisti S, Holländer H. Pattern ERG in the monkey after section of the optic nerve. *Exp Brain Res*. 1985;59:423–425.
25. Mafei L, Fiorrentini A. Electroretinographic responses to alternating gratings before and after section of the optic nerve. *Science*. 1981;211: 953–955.
26. Lalwani GA, Rosenfeld PJ, Fung AE, et al. A variable-dosing regimen with intravitreal ranibizumab for neovascular age-related macular degeneration: year 2 of the PrONTO study. *Am J Ophthalmol*. 2009;148:43–58.
27. Kizawa J, Machida S, Kobayashi T, et al. Changes of oscillatory potentials and photopic negative response in patients with early diabetic retinopathy. *Jpn J Ophthalmol*. 2006;50:367–373.
28. Moschos MM, Brouzas D, Apostolopoulos M, et al. Intravitreal use of bevacizumab (Avastin) for choroidal neovascularization due to ARMD: a preliminary multifocal-ERG and OCT study. Multifocal-ERG after use of bevacizumab in ARMD. *Doc Ophthalmol*. 2007;114: 37–44.
29. Bakri SJ, Snyder MR, Reid JM, Pulido JS, Ezzat MK, Singh RJ. Pharmacokinetics of intravitreal bevacizumab (Avastin). *Ophthalmology*. 2007;114:855–859.

30. Bakri SJ, Snyder MR, Reid JM, Pulido JS, Ezzat MK, Singh RJ. Pharmacokinetics of intravitreal ranibizumab (Lucentis). *Ophthalmology*. 2007;114:2179–2182.
31. Horsley MB, Mandava N, Maycotte MA, Kahook MY. Retinal nerve fiber layer thickness in patients receiving chronic anti-vascular endothelial growth factor therapy. *Am J Ophthalmol*. 2010;150:558–561.
32. Machida S, Gotoh Y, Tanaka M, Tazawa Y. Predominant loss of the photopic negative response in central retinal artery occlusion. *Am J Ophthalmol*. 2004;37:938–940.
33. Chen H, Wu D, Huang S, Yan H. The photopic negative response of the flash electroretinogram in retinal vein occlusion. *Doc Ophthalmol*. 2006;113:53–59.
34. Chen H, Zhang M, Huang S, Wu D. The photopic negative response of flash ERG in nonproliferative diabetic retinopathy. *Doc Ophthalmol*. 2008;117:129–135.
35. Yonemura D, Aoki T, Tsuzuki K. Electroretinogram in diabetic retinopathy. *Arch Ophthalmol*. 1962;68:19–24.
36. Papadopoulou DN, Medrinos E, Mangioris G, Donati G, Pouraras CJ. Intravitreal ranibizumab may induce retinal arteriolar vasoconstriction in patients with neovascular age-related macular degeneration. *Ophthalmology*. 2009;116:1755–1761.
37. Ameri H, Chader GJ, Kim JG, et al. The effects of intravitreal bevacizumab on retinal neovascular membrane and normal capillaries in rabbits. *Invest Ophthalmol Vis Sci*. 2007;48:5708–5715.
38. Kim KS, Chang HR, Song S. Ischemic change after intravitreal bevacizumab (Avastin) injection of macular for macular oedema secondary to non-ischemic central retinal vein occlusion. *Acta Ophthalmol*. 2008;86:925–927.
39. Yokoyama K, Choshi T, Kimoto K, et al. Retinal circulatory disturbances following intracameral injection of bevacizumab for neovascular glaucoma. *Acta Ophthalmol*. 2008;86:927–928.
40. Shimura M, Yasuda K. Macular ischaemia after intravitreal bevacizumab injection in patients with central retinal vein occlusion and a history of diabetes and vascular disease. *Br J Ophthalmol*. 2010;94:381–383.
41. Siliprandi R, Canella R, Carmignoto G, et al. N-methyl-D-aspartate-induced neurotoxicity in the adult rat retina. *Vis Neurosci*. 1992;8:567–573.
42. Sieving PA, Frishman LJ, Steinberg RH. Scotopic threshold response of proximal retina in cat. *J Neurophysiol*. 1986;56:1049–1061.
43. Sieving PA, Nino C. Scotopic threshold response (STR) of the human electroretinogram. *Invest Ophthalmol Vis Sci*. 1988;29:1608–1614.
44. Frishman LJ, Shen FF, Du L, et al. The scotopic electroretinogram of macaque after retinal ganglion cell loss from experimental glaucoma. *Invest Ophthalmol Vis Sci*. 1996;37:125–141.
45. Sieving PA. Retinal ganglion cell loss does not abolish the scotopic threshold response (STR) of the cat and the human ERG. *Clin Vision Sci*. 1991;6:149–158.

Clinical Ophthalmology

Publish your work in this journal

Clinical Ophthalmology is an international, peer-reviewed journal covering all subspecialties within ophthalmology. Key topics include: Optometry; Visual science; Pharmacology and drug therapy in eye diseases; Basic Sciences; Primary and Secondary eye care; Patient Safety and Quality of Care Improvements. This journal is indexed on

Submit your manuscript here: <http://www.dovepress.com/clinical-ophthalmology-journal>

Dovepress

PubMed Central and CAS, and is the official journal of The Society of Clinical Ophthalmology (SCO). The manuscript management system is completely online and includes a very quick and fair peer-review system, which is all easy to use. Visit <http://www.dovepress.com/testimonials.php> to read real quotes from published authors.