

# Increased macular choroidal blood flow velocity during systemic corticosteroid therapy in a patient with acute macular neuroretinopathy

Yuki Hashimoto<sup>1</sup>  
Wataru Saito<sup>1,2</sup>  
Shohei Mori<sup>1</sup>  
Michiyuki Saito<sup>1</sup>  
Susumu Ishida<sup>1,2</sup>

<sup>1</sup>Department of Ophthalmology,

<sup>2</sup>Department of Ocular Circulation and Metabolism, Hokkaido University Graduate School of Medicine, Sapporo, Japan

**Purpose:** The precise mechanism causing outer retinal damage in acute macular neuroretinopathy (AMN) remains unclear. In this study, choroidal blood flow velocity was quantitatively evaluated using laser speckle flowgraphy (LSFG) in a patient with AMN who received systemic corticosteroid therapy.

**Methods:** Corticosteroids were systemically administered across 4 months for an AMN patient. LSFG measurements were taken ten consecutive times before treatment and at 1 week and 1, 3, and 10 months after the onset of therapy. The square blur rate, a quantitative index of relative blood flow velocity, was calculated using LSFG in three regions: Square 1, the macular lesion with findings of severe multifocal electroretinography amplitude reduction, and Squares 2 and 3, funduscopically normal-appearing retinal areas with findings of moderate and mild multifocal electroretinography amplitude reduction, respectively.

**Results:** The AMN lesion gradually decreased after treatment and improved results were detected on the Amsler chart, as well as on optical coherence tomography and scanning laser ophthalmoscopy. When the changing rates of the macular flow were compared with the mean square blur rate level before treatment (100%), 14.6%, 24.5%, 12.9%, and 16.3% increases were detected in Square 1 (macular lesion) at 1 week and 1, 3, and 10 months after treatment, respectively. Similarly, in Square 2 (normal-appearing area next to the lesion), 12.6%, 18.6%, 6.7%, and 8.3% increases were also noted at 1 week and 1, 3, and 10 months after treatment, respectively. In Square 3 (normal-appearing area apart from the lesion), 16.0%, 15.1%, 19.1%, and 3.8% increases were measured at 1 week and 1, 3, and 10 months after treatment, respectively.

**Conclusion:** In a patient with AMN, choroidal blood flow velocity at the lesion site, which was examined with LSFG, sequentially increased during systemic corticosteroid therapy, together with improvement of visual function. The present findings suggest that choroidal circulation impairment relates to the pathogenesis of AMN, extending over a wider area in the posterior pole than the site of an AMN lesion per se.

**Keywords:** laser speckle flowgraphy, choroidal circulation, multifocal electroretinography, square blur rate

## Introduction

Acute macular neuroretinopathy (AMN) is a rare disease characterized by a wedge-shaped, dark, reddish-brown lesion in the macula that is clearly revealed by scanning laser ophthalmoscope (SLO) infrared imaging. Young women are predisposed to AMN with bilateral involvement. When this disease was first described in 1975, it was named AMN because it was thought that the lesions were present at the level of the inner retina.<sup>1</sup> Recently, the development of spectral domain optical coherence

Correspondence: Wataru Saito  
Department of Ocular Circulation and Metabolism, Hokkaido University Graduate School of Medicine, Nishi 7, Kita 15, Kita-ku, Sapporo 060-8638, Japan  
Tel +81 11 706 5944  
Fax +81 11 706 5948  
Email wsaito@med.hokudai.ac.jp

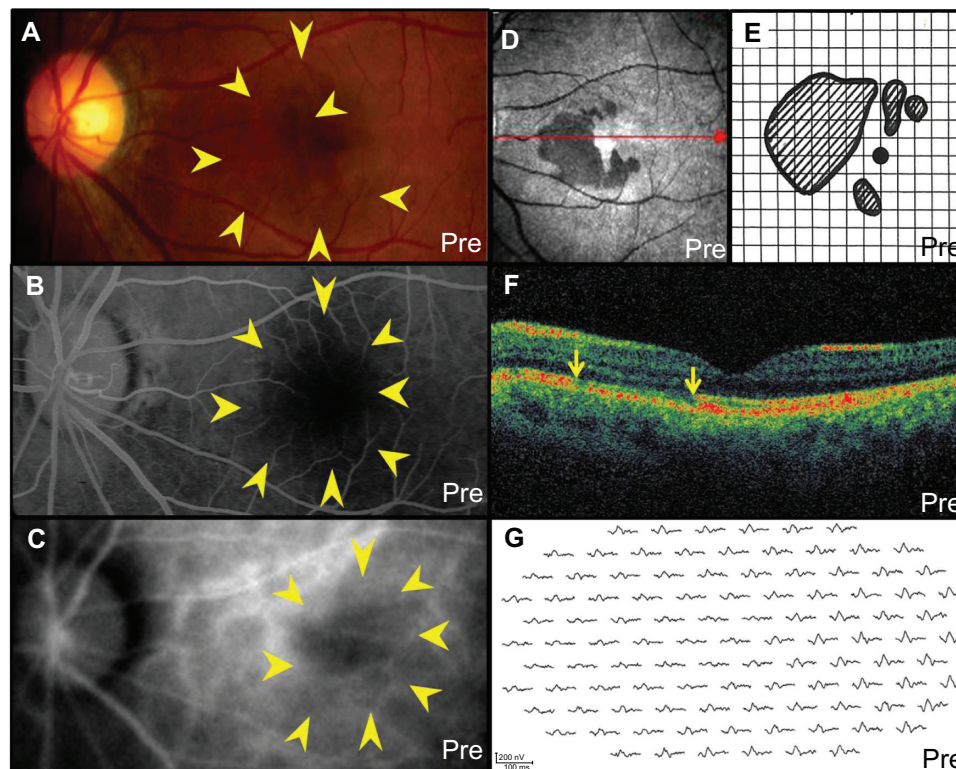
tomography (OCT) was able to demonstrate that the affected AMN layer was mainly in the outer retina, not in the inner retina.<sup>2-4</sup> However, the exact mechanism causing outer retinal damage in AMN remains unknown, and there is no specific treatment for this disease, although various factors that may be related to its onset (eg, trauma, the use of oral contraceptives, contrast agents, and adrenaline or noradrenaline) have been reported.<sup>5</sup>

Laser speckle flowgraphy (LSFG) can noninvasively investigate blood flow velocity of ocular tissues including retinal vessels or choroid without the administration of contrast agents.<sup>6</sup> In addition, LSFG can measure the same areas every time once the squares are registered, because of its automatic function of memorizing the topographic features of retinal vasculature. The reproducibility of blood velocity and flow measurements in ocular tissues by the laser speckle method is high, and the measurement time is shorter than that of laser Doppler velocimetry.<sup>7,8</sup> The LSFG method is therefore suitable for monitoring changes in ocular tissue circulation at the same site in the same eye at various intervals in the time course of the disease.<sup>9</sup> In the present study, the authors

quantitatively measured choroidal blood flow velocity in the macular lesion using LSFG while administering systemic corticosteroid therapy in a patient with AMN.

## Case report

A 41-year-old woman noticed acute central vision loss with photopsia in her left eye. The patient had taken oral contraceptives for endometriosis. Her visual acuity was 1.5 in both eyes with no refractive error. A fundoscopic examination revealed a wedge-shaped, dark, reddish-brown lesion centered on the macula with the central fovea spared in both eyes (Figure 1A). Hypofluorescence from the initial phase that corresponded to the lesion was revealed through fluorescein angiography and indocyanine green angiography (Figure 1B and C). Also, SLO infrared imaging revealed an abnormal dark area corresponding to the lesion (Figure 1D). An Amsler chart test and Humphrey Swedish interactive threshold algorithm standard 10-2 visual field test showed scotomata corresponding to the lesion area in both eyes (Figure 1E). In addition, OCT revealed a disruption of the photoreceptor inner segment–outer segment (IS-OS) junction with thinning (Figure 1F). In addition, OCT revealed a disruption of the photoreceptor inner segment–outer segment (IS-OS) junction with thinning

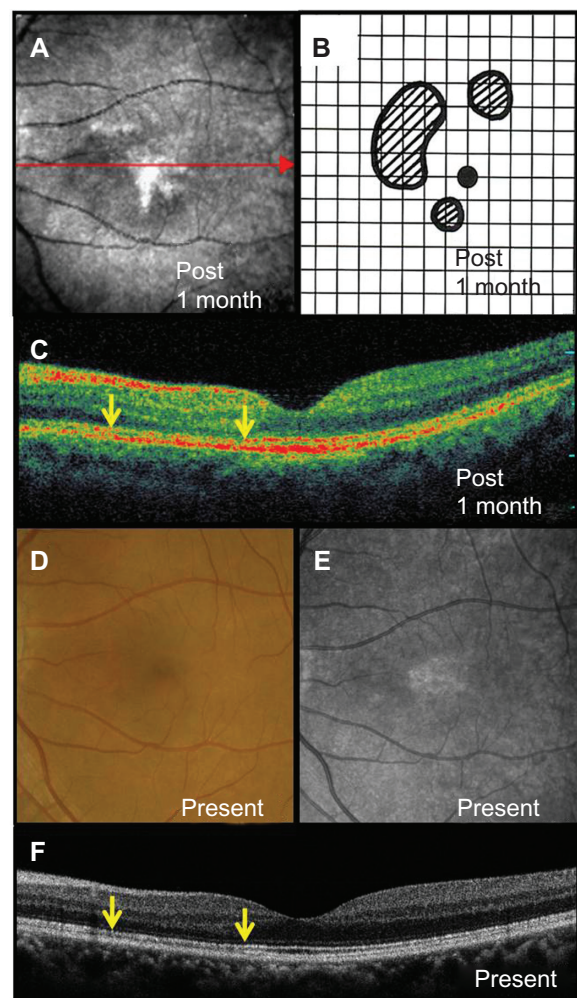


**Figure 1** The left eye before treatment in a patient with acute macular neuroretinopathy: (A) fundus photograph shows a wedge-shaped, dark, reddish-brown lesion (indicated by arrows) in the macula; (B) fluorescein angiography in the late phase and (C) indocyanine green angiography in the initial phase show a hypofluorescence corresponding to the lesion (indicated by arrows); (D) scanning laser ophthalmoscope infrared imaging shows the dark area; (E) Amsler chart shows scotomata corresponding to the acute macular neuroretinopathy lesion; (F) horizontal image of optical coherence tomography through the fovea (indicated by arrow of figure 1D) shows a disruption of the photoreceptor inner segment–outer segment junction (indicated by arrows) and thinning of the outer nuclear layer corresponding to the lesion; (G) in multifocal electroretinography, decreased amplitude was present at the posterior pole, extending especially from the central fovea toward the nasal side.

of the outer nuclear layer corresponding to the lesion area in both eyes (Figure 1F). In multifocal electroretinography (mfERG), decreased amplitude was present at the posterior pole, extending especially from the central fovea toward the nasal side, in both eyes (Figure 1G). All these findings in the left eye (Figure 1) were more evidently detected than those in the right eye (data not shown). A diagnosis of AMN was made in both eyes. After informed consent was obtained, methylprednisolone (1000 mg/day) followed by prednisolone (30 mg/day) was administered for 3 days and was continued with gradual tapering over a 4-month period. Amsler chart and perimetry testing showed improvement of the scotomata within 1 week after initiation of treatment. At 4 weeks after treatment, the lesion area and the dark area visible by SLO reduced, as measured by the Amsler chart and perimetry in both eyes (Figure 2A and B). There was also a recovery of IS-OS disruption, as shown by OCT (Figure 2C). At present, 45 months after the initial visit, the lesion has almost resolved, with disappearance of the dark area that had been visible by SLO and recovery of the IS-OS junction (Figure 2D–F). The patient's visual acuity remained stable at 1.5 in both eyes throughout the follow-up period. No recurrence has been observed so far.

## LSFG

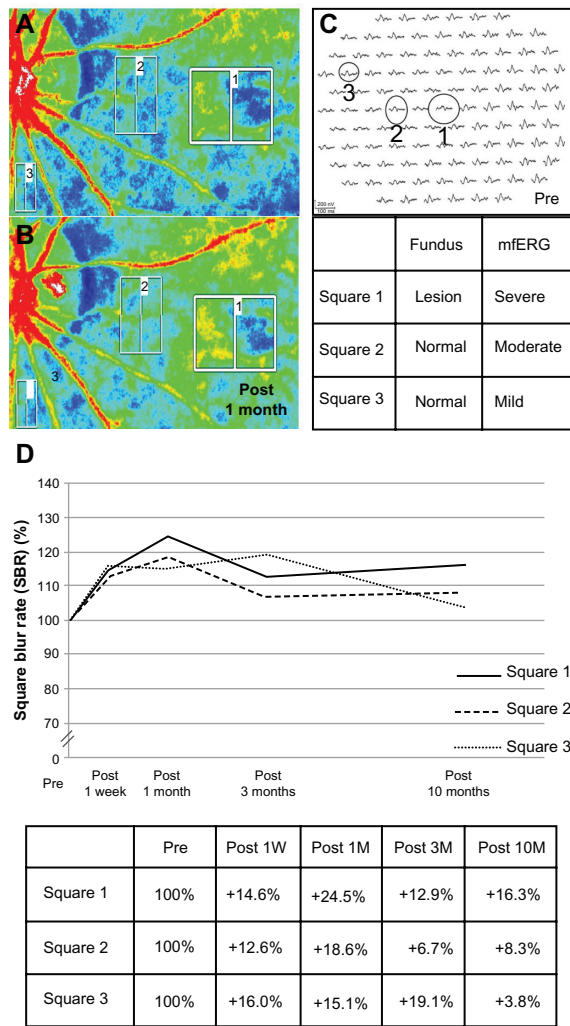
Measurement by LSFG (Kyushu Institute of Technology, Iizuka, Japan) in the patient's left eye was conducted ten consecutive times before treatment, at 1 week and 1, 3, and 10 months after initiation of corticosteroid pulse therapy. Informed consent was obtained after an explanation of the nature and possible consequences of the study, which followed the standard of care outlined in the Declaration of Helsinki. To evaluate the change in the relative blood flow velocity at sites of the fundus, a square was set according to the severity of mfERG amplitude reduction (Figures 1G and 3C – these are identical): Square 1 indicates the macula, including the acute macular neuroretinopathy lesion with severe mfERG findings; Squares 2 and 3 indicate fundoscopically normal-appearing retinal sites with moderate and mild mfERG findings, respectively (Figure 3A and B). The square blur rate (SBR), a quantitative index of relative blood flow velocity, was calculated using LSFG in Squares 1–3. It must be noted that as the SBR values are in arbitrary units, it is difficult to make direct comparisons among data obtained from different sites of measurement. The changes in a composite pseudo-color map and the mean SBR during systemic corticosteroid therapy at each square are shown in Figure 3A–D. When the changing rates of the macular flow



**Figure 2** Photographs at 4 weeks after systemic corticosteroid therapy (A–C) and at the final visit (D–F): (A) reduction of the dark area visible by scanning laser ophthalmoscope and (B) scotomata in the Amsler chart; (C) improvement in the disruption of the inner segment–outer segment junction (indicated by arrows) on optical coherence tomography (indicated by arrow of figure 2A); (D) the lesion and (E) dark area visible by scanning laser ophthalmoscope almost resolved with further recovery of (F) the inner segment–outer segment line (indicated by arrows) on optical coherence tomography.

were compared with the mean SBR levels before treatment (100%), 14.6%, 24.5%, 12.9%, and 16.3% increases were detected in Square 1 (macular lesion) at 1 week and 1, 3, and 10 months after treatment, respectively. Similarly, in Square 2 (normal-appearing area next to the lesion), 12.6%, 18.6%, 6.7%, and 8.3% increases were also noted at 1 week and 1, 3 and 10 months after treatment, respectively. In Square 3 (normal-appearing area apart from the lesion), 16.0%, 15.1%, 19.1%, and 3.8% increases were measured at 1 week and 1, 3, and 10 months after treatment, respectively.

Since the authors' parallel data show that in normal fellow eyes corticosteroid pulse therapy tends to increase choroidal blood flow velocity 1 month after the initiation of the therapy (manuscript submitted for publication, 2012), the difference



**Figure 3** (A and B) Composite color map using square blur rate (SBR) measured by laser speckle flowgraphy; (C) squares were set corresponding to the severity of multifocal electroretinography (mfERG) amplitude reduction; and (D) the changes of the mean SBR at Squares 1–3 during systemic corticosteroid therapy and after 10 months in the left eye. Square 1 indicates the macula, including the acute macular neuroretinopathy lesion with severe mfERG findings; Squares 2 and 3 (moderate and mild mfERG findings, respectively) indicate the sites of funduscopically normal-appearing retinal areas. The red indicates high SBR; the blue indicates low SBR. The SBR in all squares increased 4 weeks after the start of treatment (B) compared with the SBR before treatment (A). The laser speckle flowgraphy was measured ten consecutive times at each visit before treatment, at 1 week and 1, 3, and 10 months after treatment. The mean SBR within each square was calculated at each evaluation point. The mean SBR of all the squares sequentially showed 16.3%, 8.3%, and 3.8% increases at 10 months after treatment compared with the pretreatment level (D). **Note:** Figure 3C is identical to Figure 1G. **Abbreviations:** 1 W, 1 week; 1 M, 1 month; 3 M, 3 months; 10 M, 10 months.

in SBR elevation between 1 and 10 months at each area (8.2%, 10.3%, and 11.3% in Squares 1, 2, and 3, respectively) is likely to be the influence of corticosteroids per se, but not the response to the impaired circulation. Importantly, the mean SBR reached a plateau after 3 months in Squares 1 and 2, and the 10-month value at each square was still higher than the pretreatment value (16.3%, 8.3%, and 3.8% increases in Squares 1, 2, and 3, respectively), showing a close link

between the degree of choroidal circulation changes and the severity of retinal function damages. Reasonably, at 10 months, the influence of corticosteroids per se (pulse therapy followed by prednisolone tapered up to 4 months) waned sufficiently enough to allow precise evaluation. Ocular perfusion pressure (OPP) was 50.7, 40.7, and 47.0 mmHg before treatment, at 1 week after treatment, and at 1 month after treatment, respectively. OPP was calculated from blood pressure and intraocular pressure as described previously.<sup>10</sup>

### Discussion

In this study, LSFG was performed before and after systemic corticosteroid therapy in a patient with AMN. During treatment, the mean SBR sequentially increased at an AMN macular lesion and at normal-appearing areas with abnormal mfERG findings, and 16.3%, 8.3%, and 3.8% increases were noted at 10 months after treatment according to the severity of the retinal function damages. Because there are no large retinal vessels near the foveal area, the SBR refers mainly to choroidal blood flow velocity. In this patient, OPP after treatment either remained unchanged or decreased compared with that before treatment. Therefore, the increase of the mean SBR in the macula suggests an increase of choroidal blood flow velocity in the region after treatment. In this patient, indocyanine green angiography showed a hypofluorescence that corresponded to the lesion. Since blocked fluorescence within inner choroid or choroidal hypoperfusion is speculated to be the etiology of this hypofluorescence, choroidal hypoperfusion seems more applicable from the LSFG results. All of the posttreatment data including the improvement of LSFG results concurrent with recoveries of the dark area visible by SLO, the IS-OS line on OCT, and visual function suggest that impairment of choroidal blood flow velocity is related to the pathogenesis of AMN. Furthermore, the mean SBR increase was seen not only in the macular lesion but also in the other retina within the posterior pole. Similarly, there was a decreased mfERG response in the wider area of the fundus compared with the lesion site. These findings suggest that choroidal circulation disorder in this patient extended over a wider area in the posterior pole than the site of an AMN lesion per se.

Recently, spectral domain OCT demonstrated a focal signal reduction in the outer retina, including the IS-OS junction and retinal pigment epithelium, but no morphological abnormality of the inner retinal layers, corresponding to the site of AMN lesions.<sup>2–4</sup> These observations suggest that AMN lesions mainly affect the outer retinal layers. However, the precise mechanism of outer retinal damage remains unclear.

If ischemia is related to the pathogenesis of outer retinal damage in AMN, the association of ischemia in the choroidal level, but not in the retinal level, can be speculated.<sup>5-7,9</sup> Actually, outer retinal neurons (ie, photoreceptors) are maintained by diffusion of nutrients and oxygen from the choriocapillaris. Previous reports have suggested a choroidal-filling delay in the fluorescein angiography of AMN patients. In concert with these reports, the present findings suggest that photoreceptor damage in AMN develops secondary to choroidal circulation disorder.

The pathogenesis of choroidal circulation impairment in AMN remains unresolved, whereas various factors that may be related to its onset (eg, trauma, the use of oral contraceptives, contrast agents, and adrenaline or noradrenaline) have been reported.<sup>5</sup> An inflammatory mechanism such as choroidal vasculitis may be another factor to consider, given that predilection for young women and bilateral involvement in AMN suggest an autoimmune mechanism. The authors previously reported that macular choroidal blood flow velocity using LSFG increased significantly during systemic corticosteroid therapy in patients with Vogt-Koyanagi-Harada disease characterized by choroidal vasculitis.<sup>11</sup> Therefore, inflammation could be involved in the pathogenesis of choroidal circulation impairment observed in the AMN patient in the present study.

However, the authors could not exclude the possibility that outer retinal neurons were primarily damaged, followed by choroidal circulation impairment. Furthermore, since some cases with AMN show spontaneous regression, the authors' present observation on anatomical and functional improvements after corticosteroid therapy may result partly from the natural history of the disease. Therefore, further study is required to clarify the cause-effect relationship.

## Conclusion

In conclusion, choroidal blood flow velocity in the lesion site sequentially increased after the initial stage of treatment

with systemic corticosteroid therapy in a patient with AMN. In parallel, visual function and retinal morphology on OCT and scanning laser ophthalmoscopy rapidly recovered. These results suggest that choroidal circulation impairment is related to the pathogenesis of AMN.

## Disclosure

The authors report no conflicts of interest in this work.

## References

1. Bos PJ, Deutman AF. Acute macular neuroretinopathy. *Am J Ophthalmol.* 1975;80(4):573-584.
2. Neuhann IM, Inhoffen W, Koerner S, Bartz-Schmidt KU, Gelissen F. Visualization and follow-up of acute macular neuroretinopathy with the Spectralis® HRA + OCT device. *Graefes Arch Clin Exp Ophthalmol.* 2010;248(7):1041-1044.
3. Grover S, Brar VS, Murthy RK, Chalam KV. Infrared imaging and spectral-domain optical coherence tomography findings correlate with micropigmentometry in acute macular neuroretinopathy: a case report. *J Med Case Rep.* 2011;5:536.
4. Baumüller S, Holz FG. Early spectral-domain optical coherence tomography findings in acute macular neuroretinopathy. *Retina.* 2012;32(2):409-410.
5. Turbeville SD, Cowan LD, Gass JDM. Acute macular neuroretinopathy: a review of the literature. *Surv Ophthalmol.* 2003;48(1):1-11.
6. Tamaki Y, Araie M, Kawamoto E, Eguchi S, Fujii H. Noncontact, two-dimensional measurement of retinal microcirculation using laser speckle phenomenon. *Invest Ophthalmol Vis Sci.* 1994;35(11):3825-3834.
7. Nagahara M, Tamaki Y, Tomidokoro A, Araie M. In vivo measurement of blood velocity in human major retinal vessels using the laser speckle method. *Invest Ophthalmol Vis Sci.* 2011;52(1):87-92.
8. Tamaki Y, Araie M, Tomita K, Nagahara M, Tomidokoro A, Fujii H. Real-time measurement of human optic nerve head and choroid circulation, using the laser speckle phenomenon. *Jpn J Ophthalmol.* 1997;41(1):49-54.
9. Sugiyama T, Araie M, Riva CE, Schmetterer L, Orgul S. Use of laser speckle flowgraphy in ocular blood flow research. *Acta Ophthalmol.* 2010;88(7):723-729.
10. Okuno T, Sugiyama T, Kohyama M, Kojima S, Oku H, Ikeda T. Ocular blood flow changes after dynamic exercise in humans. *Eye (Lond).* 2006;20(7):796-800.
11. Hirose S, Saito W, Yoshida K, et al. Elevated choroidal blood flow velocity during systemic corticosteroid therapy in Vogt-Koyanagi-Harada disease. *Acta Ophthalmol.* 2008;86(8):902-907.

### Clinical Ophthalmology

### Publish your work in this journal

Clinical Ophthalmology is an international, peer-reviewed journal covering all subspecialties within ophthalmology. Key topics include: Optometry; Visual science; Pharmacology and drug therapy in eye diseases; Basic Sciences; Primary and Secondary eye care; Patient Safety and Quality of Care Improvements. This journal is indexed on

Submit your manuscript here: <http://www.dovepress.com/clinical-ophthalmology-journal>

Dovepress

PubMed Central and CAS, and is the official journal of The Society of Clinical Ophthalmology (SCO). The manuscript management system is completely online and includes a very quick and fair peer-review system, which is all easy to use. Visit <http://www.dovepress.com/testimonials.php> to read real quotes from published authors.