

# Imaging of cervicothoracic junction trauma

Sirote Wongwaisayawan<sup>1</sup>  
Ruedeekorn Suwannanon<sup>2</sup>  
Rathachai Kaewlai<sup>1</sup>

<sup>1</sup>Department of Radiology,  
Ramathibodi Hospital and Mahidol  
University, Bangkok, Thailand;

<sup>2</sup>Department of Radiology, Faculty of  
Medicine, Prince of Songkla University,  
Hat Yai, Thailand

**Abstract:** Cervicothoracic junction trauma is an important cause of morbidity and mortality in trauma patients. Imaging has played an important role in identifying injuries and guiding appropriate, timely therapy. Computed tomography is currently a method of choice for diagnosing cervicothoracic junction trauma, in which the pattern of injuries often suggests possible mechanisms and potential injuries. In this article, the authors describe and illustrate common and uncommon injuries that can occur in the cervicothoracic junction.

**Keywords:** cervicothoracic junction, cervical spine, trauma, imaging, radiology

## Introduction

Cervical spine injury has long been recognized as a significant cause of mortality and morbidity in trauma patients. The cervicothoracic junction is well recognized as a potential area of significant injuries.<sup>1-9</sup> Early diagnosis can lead to appropriate treatment and improved outcome. Imaging has played a critical role in diagnosing bony injuries and clearing cervical spine in patients presenting with blunt trauma. The advent of cross-sectional imaging such as multidetector computed tomography (CT) and magnetic resonance imaging (MRI) has revolutionized cervical spine imaging in trauma patients by allowing visualization of structures commonly obscured on conventional radiography, particularly the cervicothoracic junction. In this article, the authors discuss incidence, epidemiology, injury pattern and classification of cervicothoracic junction trauma, and illustrate cross-sectional imaging findings of various injuries.

## Incidence and epidemiology

The incidence of all types of cervical spine injury is approximately 4.3% in blunt trauma and ranges from 2.7% to 22% in penetrating neck trauma. The prevalence of cervical spine injury increases with age.<sup>10</sup> Motor vehicle collisions, motorcycle collisions, falls, recreation, and assaults can result in cervical spine trauma. Certain injury mechanisms, particularly traffic accident- and sport activity-related injuries, may be more closely associated with cervical spine injury. Between 11 and 70 years of age, male patients are more likely to have cervical spine injury, but after 70 years of age, in contrast, female patients tend to have higher incidence.<sup>11</sup>

Injuries to the cervical spine often occur at the craniocervical and cervicothoracic junctions. According to one report, the most common location for cervical spine fracture is C2 (23.9%), followed by C6 (20.3%) and C7 (19.08%), while the most common location for dislocation and subluxation is C5/C6 (25.11%), followed

Correspondence: Rathachai Kaewlai  
Department of Radiology, Ramathibodi  
Hospital and Mahidol University,  
270 Rama VI Road, Ratchatewi,  
Bangkok 10400, Thailand  
Tel +66 2 201 0338  
Fax +66 2 201 1297  
Email rathachai@gmail.com

by C6/C7 (23.37%) and C4/C5 (16.45%) (Figure 1).<sup>12</sup> Many of these injuries can be obscured on both clinical examination and initial radiographic evaluation. Delayed or missed diagnosis of cervical spine trauma can be devastating because of the potential for neurological damage associated with it. The overall rate of delayed or missed diagnosis ranges from 0.01% to 26%, but is generally believed to be 5%–20% of all cases.<sup>13–19</sup>

The incidence of cervicothoracic junction trauma has been reported ranging from 2.4% to 50% of all cervical spine fractures.<sup>5,9,18</sup> Detection of injuries in this location is very important because of a very high risk of neurological deficit due to spinal cord injury, reportedly as high as 59%–78%.<sup>5,9</sup> The injury is commonly overlooked on radiographic evaluation because of suboptimal imaging (especially in obese patients, muscular men, and with other distracting injuries) and subtlety.<sup>2,5,9,20</sup>

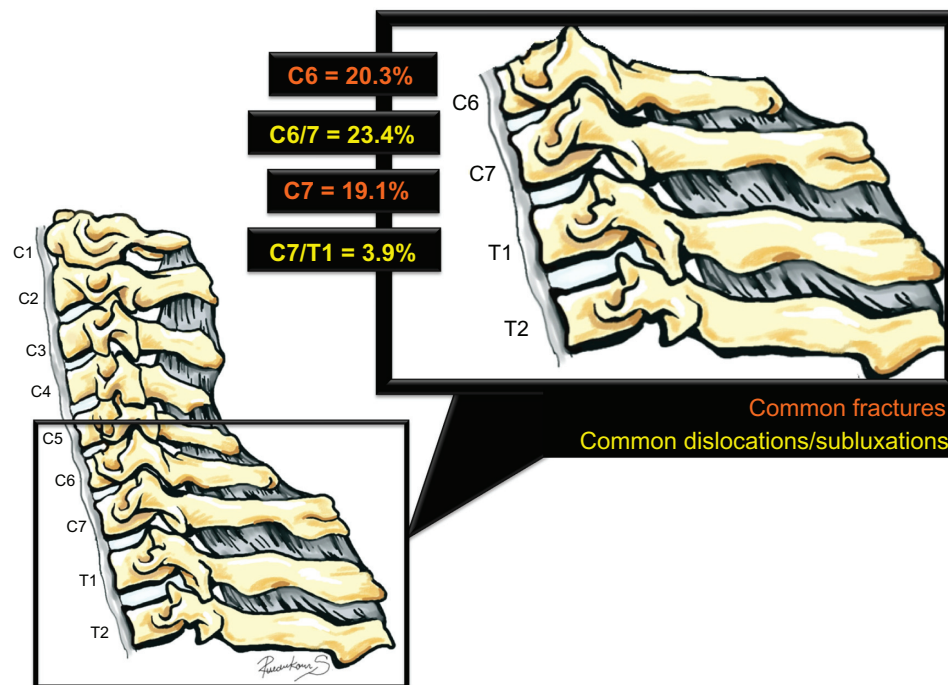
Many factors may contribute to cervical spine injury. Cervical motion decreases with age, making the cervical spine of older individuals more susceptible to injury. Spondylotic degeneration produces some changes in either mechanical character or morphology of the spinal column. In these patients, the most severe level of injury is often adjacent to the region of maximal degenerative changes because of increased local stiffness. Osteopenia, osteoporosis, congenital spinal stenosis and some arthritides (such as

ankylosing spondylitis) also increase susceptibility to injury after a relatively minor trauma.<sup>21</sup>

## Cervical spine imaging: when and how

There is a wide range of clinical presentation of cervical spine injury, from no symptoms, midline neck tenderness, limited neck movement, to significant neurological deficit. In patients with distracting injuries or minor symptoms, important clues to the diagnosis include age older than 50 years, concomitant severe head injury, high-energy trauma mechanism, altered or depressed mental status, and focal neurological deficit referable to the spine.<sup>22,23</sup> Two well-known clinical prediction rules used in current practice are the National Emergency X-Radiography Utilization Study (NEXUS) criteria and the Canadian C-spine Rule (CCR).

The authors of the NEXUS study developed low-risk criteria based on five clinical factors: no midline cervical spine tenderness, no focal neurological deficit, normal alertness, no intoxication, and no painful or distracting injury. Patients who met all of these five criteria were classified as having a low probability of injury and imaging was not necessary. Based on 34,069 trauma patients evaluated with these criteria in their study (818 patients had cervical spine injury, prevalence 2.4%), the sensitivity and negative predictive value were 99% and 99.8%, respectively.<sup>24</sup> The CCR used three high-risk criteria (age > 65 years, dangerous



**Figure 1** Diagram of the cervicothoracic junction illustrating the incidence of injuries (percentages presented are from separate category for fractures and dislocations), based on Goldberg et al.<sup>12</sup>

mechanism, paresthesias in extremities), five low-risk criteria (simple rear-end motor vehicle collision, sitting position in the emergency department, ambulatory at any time, delayed onset of neck pain, absence of midline cervical spine tenderness), and the ability to actively rotate the neck 45° left and right to determine the need for imaging.<sup>25</sup>

Direct comparison between these two clinical prediction rules showed that the CCR was superior to the NEXUS in terms of sensitivity and specificity for detecting clinically significant cervical spine injury. However, the CCR is relatively extensive, so it is difficult to apply to daily practice. Emergency physicians should use any of these two clinical prediction rules (NEXUS or CCR), based on their institutional preferences.<sup>26–32</sup>

## Conventional radiography vs computed tomography

Multidetector CT (MDCT) scan is the modality of choice to assess bony injuries in high-risk patients. However, three-view cervical spine radiography (anteroposterior [AP], lateral, and open-mouth odontoid views) may be the primary examination in low-risk cases.<sup>33</sup> The lateral view of the three-view radiographic series has the highest yield for injury detection. However, overlapping of the shoulder girdle and rib cages can result in inadequate visualization of the cervical spine. An adequate lateral radiograph must include all cervical spines from C1 to the C7–T1 junction. A swimmer's view can be done if the lateral view fails to demonstrate the C7–T1 junction, but this view is adequate in only 55% of cases.<sup>34</sup> Despite additional views and repeated examinations, a significant number of cervical spine radiography is inadequate. The data from many studies collaborate this fact suggesting that the rate of inadequate cervical radiographs might be as high as 37%–72%.<sup>35–37</sup> Radiography is also a time-consuming procedure, and most importantly has a variable sensitivity for detecting cervical spine injury.<sup>5,9,38</sup> Reported sensitivity of

cervical spine radiography for detection of fractures ranges from 36% to 98%.<sup>24,36,39–42</sup>

The use of MDCT for detection of cervical spine injury has increased worldwide, owing to its high accuracy, speed, wide availability, and proven clinical values. Thin-slice MDCT with sagittal and coronal reformations revolutionize the assessment of cervical spine injury. It is cost-effective, with faster image-acquisition time and higher sensitivity than conventional radiography.<sup>36,39,40,43–50</sup> The American College of Radiology and the Eastern Association of Surgery for Trauma recommend MDCT as a first-line imaging modality for diagnosis of cervical spine injury in high-risk patients.<sup>23,51,52</sup> MDCT is also indicated in trauma patients with abnormal conventional radiographs, inadequate lateral radiographs, or unexplained focal neurological deficit with negative plain radiographs.<sup>53</sup> A summary of recommendations for selection of appropriate imaging methods is provided in Table 1.

## Flexion/extension radiography

Flexion/extension (F/E) cervical radiography is a dynamic evaluation for potential ligamentous instability. If patients have adequate cervical motion, which is defined by greater than 30° movement from neutral position, the F/E views have a very low negative rate. In the acute setting, F/E radiography is not recommended because of a high frequency of inadequate neck movement. It often adds little information in the acute diagnosis. F/E views may be useful in delayed evaluation after pain and muscle spasm has subsided. It is indicated in conscious patients who have persistent neck pain in the absence of abnormality on standard views.<sup>51,54–59</sup>

## Magnetic resonance imaging

MRI gives better soft-tissue details and contrast than a CT scan; therefore, it is useful for evaluation of injuries to the spinal cord, disk, ligaments, and other soft tissues. Acute spinal epidural hematoma and traumatic disc herniation are

**Table 1** Recommendations for use of appropriate imaging in cervical spine injuries

Techniques	Suggested use
MDCT with coronal and sagittal reformations	High-risk individuals
Three-view conventional radiography	Low-risk individuals
CT angiography	Fractures involving transverse foramen, subluxation/dislocation Penetrating injury adjacent to vascular structures
Flexion/extension radiography	Not recommended in acute setting Conscious patients who have persistent neck pain in the absence of abnormality on standard views
Magnetic resonance imaging	Acute neurological deficits referable to cervical spine after negative CT Obtunded patients with negative CT Presence of moderate-to-severe spinal degenerative disease

**Abbreviation:** MDCT, multidetector computed tomography.

well demonstrated on MRI. MRI is generally indicated in trauma patients with acute neurological deficits referable to cervical spine who have negative CT scan. It may be performed for cervical spine clearance in (1) obtunded patients with negative CT since the neurological examination is unreliable and (2) when it is difficult to interpret CT, such as in the presence of moderate-to-severe spinal degenerative disease.<sup>23,60,61</sup>

## Cervicothoracic junction trauma

The cervicothoracic junction is a region between the C6 and T3 vertebra. It is a unique location of the spine in terms of anatomy, biomechanics, and imaging appearance.<sup>1,7</sup> It is a transition zone from a mobile cervical lordotic curve to a more rigid thoracic kyphosis with a gradual change of bony anatomy. Much stress is put on the cervicothoracic junction in both static and dynamic states, making it predisposed to deformity and instability.<sup>1,2,8,11,20,62,63</sup>

On imaging evaluation, abnormalities in this area are frequently overlooked because of distracting injury and suboptimal technique, especially in muscular or very obese patients.<sup>2,5,9</sup> Surgical fixation of this area can be technically difficult, so it needs complete and thorough preoperative evaluation with special attention.<sup>2</sup> Accurate and timely diagnosis of cervicothoracic junction injury inevitably depends on a high index of suspicion, use of appropriate imaging techniques, and attention to adequacy of imaging.

## Biomechanics

The basic functions of the spinal system are to allow movement, to carry loads, and to protect the spinal cord and nerve roots. These functions are established via three interdependent subsystems: bone, disk, and ligamentous structures; muscle and tendon; and neural control.<sup>64</sup> If one of these subsystems fails, other subsystems will compensate to maintain needed spinal stability. When the force exceeds the spine's absorption capability, soft- and hard-tissue components will fail and may result in osseous injury or cord injury. The cervical spine is generally viewed as a two-column structure with regard to anatomical stability. The anterior column consists of vertebral bodies, disks, and anterior and posterior longitudinal ligaments. Facet joints, spinous processes, and lamina and posterior ligamentous structures are in the posterior column. Stability defines symmetrical movement and configuration whether the spinal column is normal or abnormal, and does not change with time. Mechanical compromise of the individual element may result in deformation under physiologic loads. By determining the extent of injury to soft tissues and

bony components of a column, physicians may be able to assess the risk of injury to the neural structures that lie within the spinal canal.

Many different force vectors may be applied to the cervicothoracic junction, including extension, flexion, axial load, lateral bending, and rotation. Distractive and compressive forces produce a unique pattern of expected injuries. The former often results in soft-tissue/ligamentous injuries, while the latter causes bony fractures. It is important to note that more than a single force vector may be seen in the same patient, and what we observe in a patient may not always be representative of injuries at the moment of impact (when the cervical spine and spinal canal undergo major transient geometric changes).

## Fracture classification

Classification of lower cervical spine injury (Table 2 and Figure 2) is based on a dominant mechanism of injury in an individual patient.<sup>65</sup> Most injuries are due to hyperextension or hyperflexion, either alone or in combination with rotation. Imaging is used to predict the mechanism of injury, which may have a distinct biomechanical aspects and stability.<sup>66</sup>

## Hyperextension injuries

Hyperextension is the most common mechanism of injury of lower cervical spine trauma, particularly cervicothoracic junction, accounting for up to 50% of all cervical spine injuries.<sup>66,67</sup> The hyperextension force can be of a direct-contact or noncontact mechanism. It produces anterior distraction, posterior compression, or both, with maximal force being in the lower cervical region. The direct-contact mechanism is an impacted force to the forehead or face, producing significant extension of the spine and subsequent hyperextension injury, whereas the noncontact mechanism (also known as whiplash injury) occurs in unrestrained neck motion during rear-end motor vehicle collision without direct impact to the head-and-neck complex. These two mechanisms can produce similar radiographic patterns. Extension teardrop fracture, hyperextension dislocation, hyperextension sprain, and hyperextension/rotation are examples of cervicothoracic junction injuries from the hyperextension mechanism.

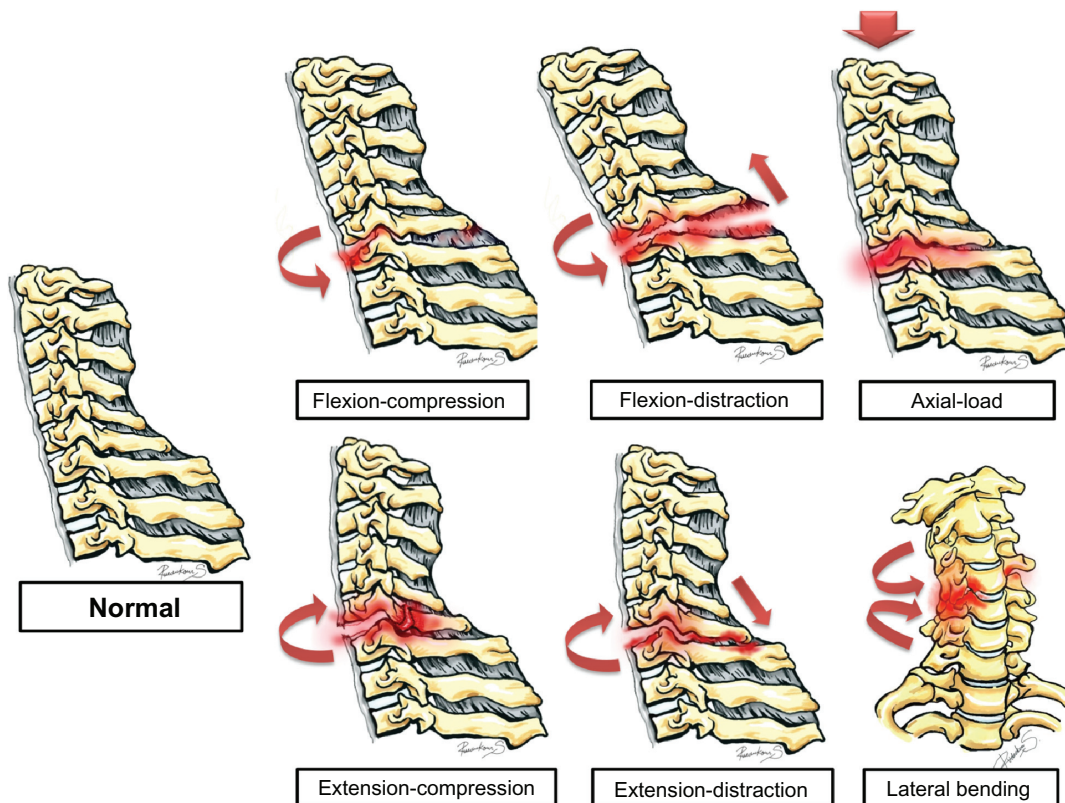
## Extension teardrop fracture

Extension teardrop fracture (Figure 3) is an avulsion of the anteroinferior corner of a vertebral body. In elderly patients with underlying osteoporosis, it typically involves C2. However, in younger individuals this injury often involves

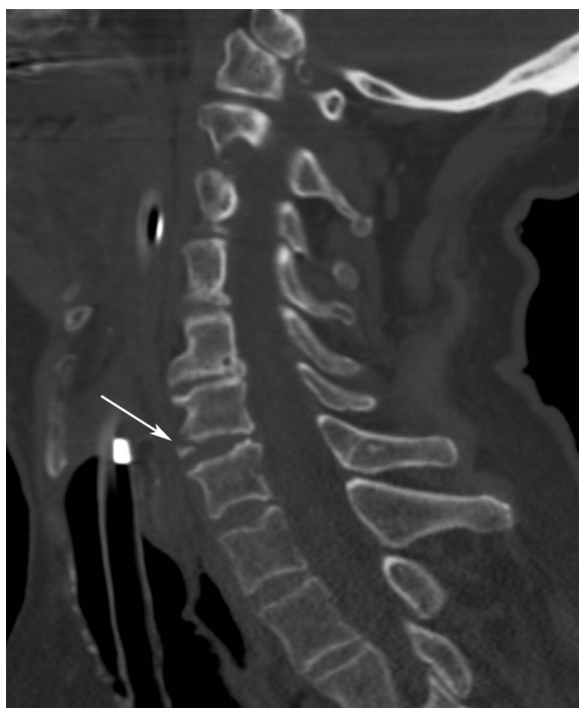

**Table 2** Classification of lower cervical spine injuries

Mechanism of injuries	Imaging characteristics
Hyperextension injuries	
Extension teardrop fracture	<ul style="list-style-type: none"> <li>– Triangular fragment from anteroinferior aspect</li> <li>– Vertical dimension of the fragment is equal to or greater than horizontal dimension</li> <li>– Size does not exceed one-quarter of the diameter of the vertebral body</li> </ul>
Hyperextension dislocation	<ul style="list-style-type: none"> <li>– Thin linear shadow of avulsed fragment at anteroinferior vertebral end plate</li> <li>– Neurological deficit, but subtle change in normal radiographs</li> </ul>
Hyperextension sprain	<ul style="list-style-type: none"> <li>– No significant disruption of ligaments and disks, but sustained neurological deficit</li> <li>– Occurs in patient with degenerative disease</li> </ul>
Extension/rotation injuries	<ul style="list-style-type: none"> <li>– Unilateral fracture of the posterior bony structures</li> </ul>
Hyperflexion injuries	
Bilateral facet dislocation	<ul style="list-style-type: none"> <li>– Bilateral “naked facet” or “reversed hamburger-bun sign”</li> <li>– Anterolisthesis of superior vertebra greater than half of the sagittal diameter of the vertebral body</li> </ul>
Flexion teardrop fracture	<ul style="list-style-type: none"> <li>– Anterior teardrop fragment</li> <li>– Kyphotic deformity at level of injury</li> <li>– Disruption of posterior ligamentous structures</li> </ul>
Hyperflexion sprain	<ul style="list-style-type: none"> <li>– Anterior subluxation</li> <li>– Localized kyphotic angulation</li> </ul>
Anterior wedge compression fracture	<ul style="list-style-type: none"> <li>– Simple compression fracture of one or more vertebrae</li> </ul>
Clay-shoveler’s fracture	<ul style="list-style-type: none"> <li>– Oblique fracture of the spinous process</li> <li>– “Double spinous sign”</li> </ul>
Flexion/rotation injuries	<ul style="list-style-type: none"> <li>– Anterolisthesis of the superior vertebra</li> <li>– “Bow tie” appearance of the articular facet</li> <li>– Unilateral “naked facet”</li> </ul>
Axial-loading injuries	
Burst fracture	<ul style="list-style-type: none"> <li>– Compression fracture of anterior and middle columns with retropulsion of the posterior vertebral body into the spinal canal</li> </ul>
Lateral hyperflexion injuries	
	<ul style="list-style-type: none"> <li>– Fractures of the transverse process, uncinete process, lateral wedge-type fracture of the vertebral body</li> </ul>



**Figure 2** Diagram showing different types of cervicothoracic junction based on mechanism of injury.



**Figure 3** Extension teardrop fracture.

**Notes:** A sagittal-reformatted computed tomography image shows a small triangular bone fragment (arrow) arising from the anteroinferior corner of C6. Note the vertical dimension of the fragment is equal to the horizontal dimension, and size does not exceed a quarter of the vertebral body diameter. No kyphotic deformity or evidence of posterior structure injuries.

the lower cervical spine and usually requires a greater force. Extensive soft-tissue injury and spinal cord injury tend to occur in younger patients, causing acute spinal cord syndrome, seen in up to 80% of cases. A typical radiographic feature is a triangular bone fragment avulsed from the anteroinferior aspect of the vertebral body. This is an avulsion of the intact fibers of the anterior longitudinal ligament from the anteroinferior end plate of the vertebral body. The vertical dimension of the fragment is equal to or greater than its horizontal dimension, and its size does not exceed one-quarter of the diameter of the vertebral body.<sup>66,67</sup>

### Hyperextension dislocation

Severe hyperextension force applied to the spine without any associated compression may cause hyperextension dislocation. The most commonly affected level is C5/C6, followed by C4/C5.<sup>66</sup> There is a tear of the anterior longitudinal ligament, intervertebral disk ruptures, or avulsion fracture at the site of insertion of the annulus fibrosus. Neurological deficit is almost always present, but the radiographs may be normal or show very subtle changes because of immediate realignment after removal of the traumatic force. Therefore, radiographs may underestimate the extent of the dislocation.

In up to 30% of cases, the only radiographic finding is prevertebral hematoma, making it the most reliable indicator, especially when diffuse prevertebral soft-tissue swelling with normally aligned vertebra is observed. Retrolisthesis above the level of injury may be seen in 20% of patients, but may be of minimal degree. The characteristic of the avulsed fragment is thin, linear shadow at the anteroinferior vertebral end plate. This fragment is produced by avulsion at the site of attachment of Sharpey's fibers and typically wider than tall, making it distinguishable from hyperextension teardrop fracture. MRI is indicated in most patients due to the high prevalence of spinal cord injury and may show extensive soft-tissue injury, spinal cord involvement, ligamentous/disk injury, edema, and susceptibility artifact from hemorrhage.<sup>66,67</sup>

### Hyperextension sprain

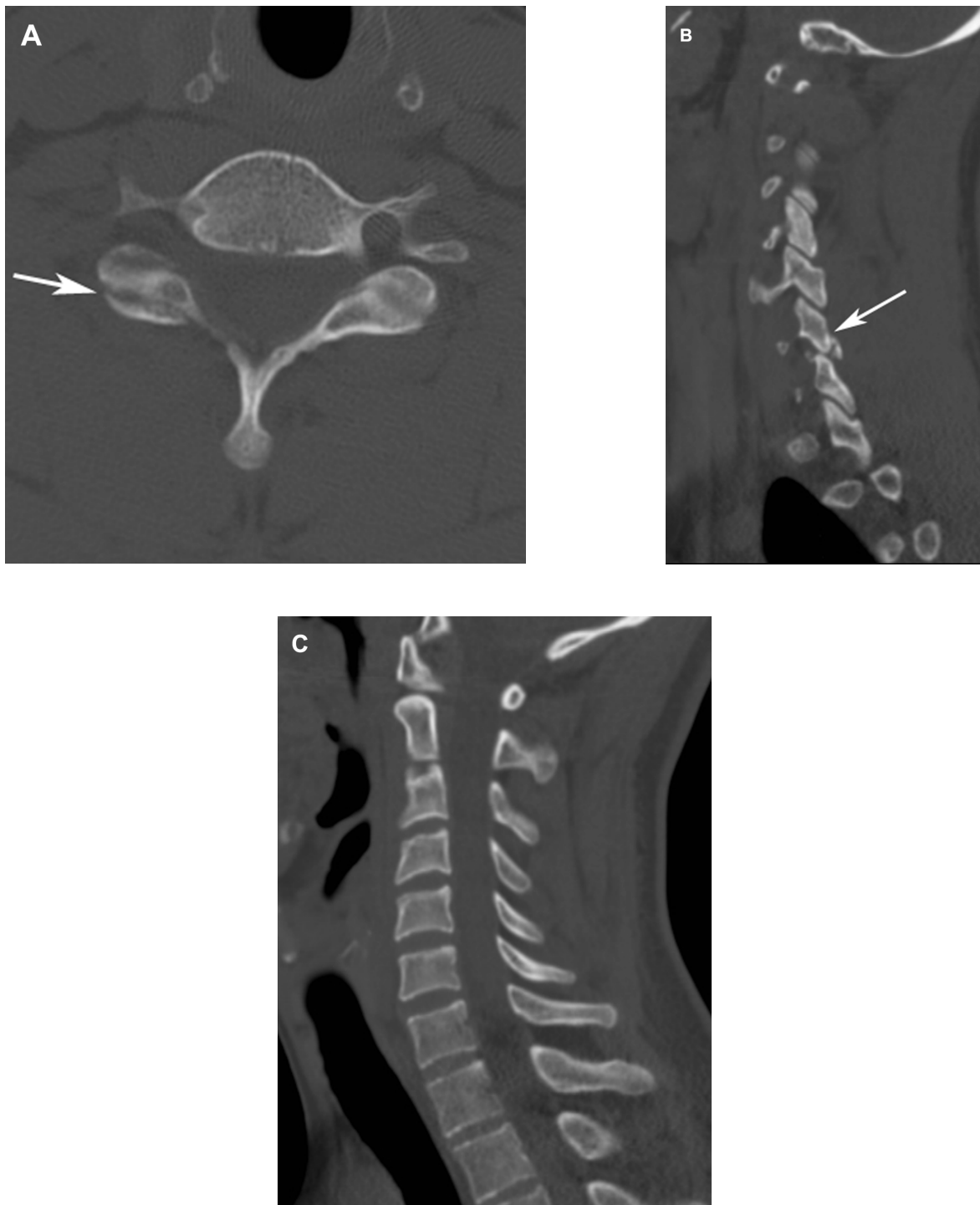
Hyperextension sprain is different from hyperextension dislocation in that it does not result in significant disruption of the ligaments or disks, but the neurological deficit is sustained. This injury often occurs in patients with underlying degenerative spine disease. The spinal stability is maintained during the injury, and the characteristic neurodeficit is central cord syndrome, believed to be spinal cord compression between the posterior osteophytes and infolded ligamentum flava. The radiographs may be normal, and no fracture is seen on CT. MRI plays a significant role to confirm the diagnosis when neurological injuries are present but not explained by radiographic and CT findings.<sup>66</sup>

### Extension/rotation injuries

A combination of extension, compression, and rotation results in unilateral fracture of the posterior bony structures (articular pilla or lateral mass, lamina; Figure 4), which occurs in about 3%–11% of all cervical spine fractures.<sup>66</sup> The true prevalence is probably underestimated because they are difficult to detect on both frontal and lateral radiographs unless severely comminuted or displaced.<sup>66,68,69</sup> The most common sites of injury are C6/C7 and C5/C6 levels.<sup>70–73</sup> CT scans can readily show these fractures, which may extend into the adjacent facets, transverse foramen, transverse process, pedicle, or lamina.<sup>66,68</sup> Vertebral artery injury and spinal cord injury can occur.<sup>69,74</sup>

### Hyperflexion injuries

Hyperflexion injuries are a common mechanism of injury of the cervical spine, accounting for up to 46% of cervical spinal injuries. The traumatic force is usually directed against the occiput, forcing the face towards the chest, and resulting primarily in distraction of the posterior structures,



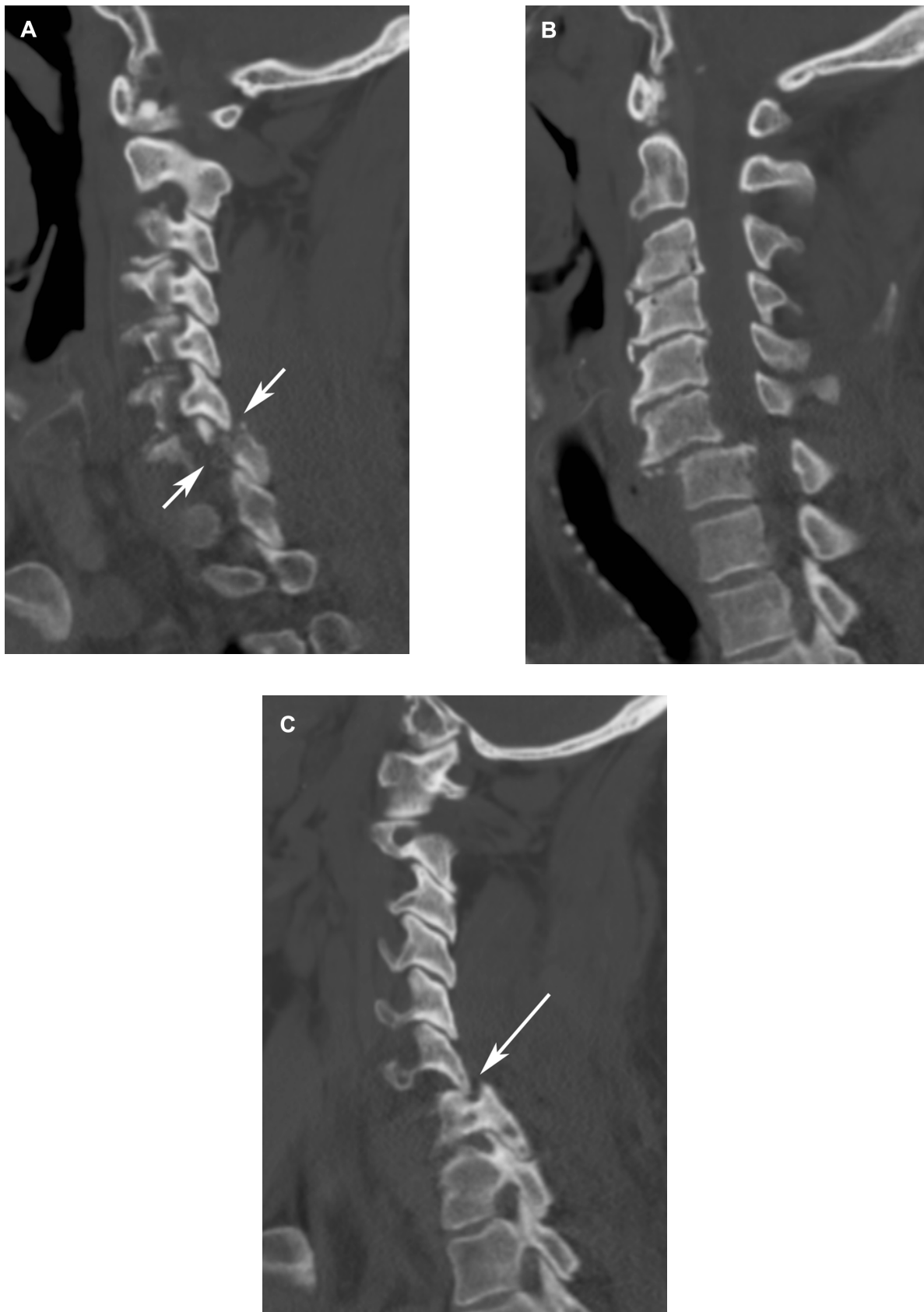
**Figure 4** Extension/rotation injuries. An axial (A) and sagittal-reformatted (B and C) computed tomography images show a mildly displaced fracture of the right inferior articular process of C6 (arrows) without spondylolisthesis.

with a lesser force vector resulting in compression of the anterior column.

#### Bilateral facet dislocations

Bilateral facet dislocations (bilateral facet lock; Figure 5) are most commonly found at C6/C7 because it is the most

mobile segment of the cervical spine.<sup>75,76</sup> Bilateral facet dislocation represents an unstable injury resulting from a combination of flexion and axial loading that causes severe disruption of the posterior and middle spinal ligamentous structures. Variable disruption of the anterior spinal column may occur, and rupture of the posterior annulus fibrosus,



**Figure 5 (A–C)** Bilateral facet fractures/dislocations.

**Notes:** Sagittal-reformatted computed tomography images from right to left demonstrate a fracture of the right C7 superior articular process (short arrows), perched right C6/7 facet, grade II/III anterolisthesis of C6 on C7, and dislocation of the left C6/7 facet (arrow).

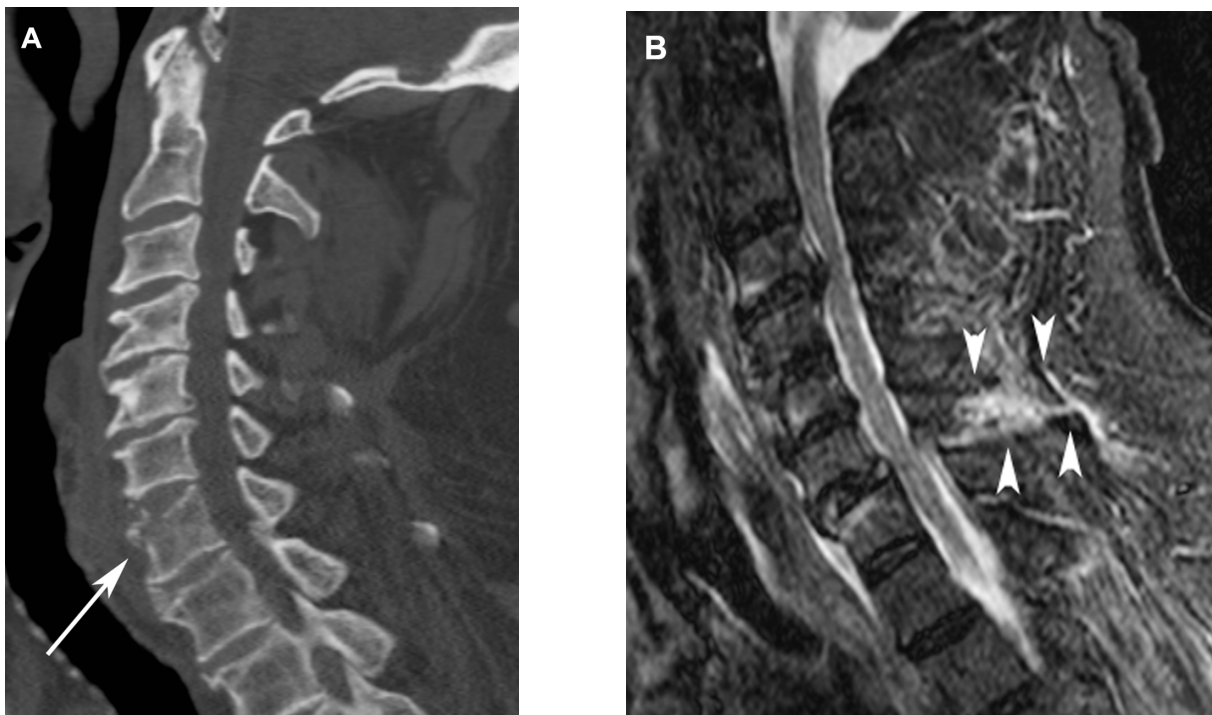


posterior longitudinal ligament, and capsular, interspinous, and supraspinous ligaments is present. Bilateral inferior articular processes of the superior vertebra translate anteriorly to the superior articular processes of the inferior vertebra. There is narrowing of the central spinal canal and intervertebral foramina, leading to severe neurological deficit up to 75%–90% of cases.<sup>66,77</sup> Bilateral facet dislocations are easily detected on lateral radiographs due to severe malalignment. Anterolisthesis is greater than half of the sagittal diameter of the vertebral body. On AP radiographic view, widening of interspinous space with little or no displacement of spinous process from midline is characteristic.<sup>75</sup> On axial CT images, the “naked facet sign” or “reversed hamburger-bun sign” is a hallmark, representing an inferior articular process of superior vertebra lying anterior to the superior articular process of the inferior vertebra.<sup>75,78</sup> Sagittal reformation is helpful to demonstrate abnormal facet alignment. Prereduction MRI may be performed to evaluate for any potential soft-tissue and spinal cord injuries.<sup>79</sup> Disk herniation and vertebral artery injury are a common complication.

### Flexion teardrop fracture

Flexion teardrop fractures (Figure 6) are a highly unstable injury with a high chance of neurological deficit, which can

occur in up to 87% of cases.<sup>80</sup> Anterior cord syndrome is characteristic, in which patients have complete paralysis, partial sensory dysfunction, and loss of pain, touch, and temperature sensation but preserved posterior column function.<sup>66,80</sup> The injury results from a combination of flexion and axial compression force, typically occurring at the lower cervical spine. The most common level of injury is C5 and less frequently at C4 and C6 levels.<sup>80</sup> On lateral radiographs, the injured vertebral body is divided into a smaller anterior fragment and a larger posterior fragment. The posterior fragment is displaced posteriorly and inferiorly relative to the vertebral body below. The anterior teardrop fragment may be large and often involves one-third to one-half of the vertebral body. It typically remains aligned with the vertebral body below. The vertebrae above the level of injury are also displaced backward in relation to the ones below the level of injury. As a result, kyphotic deformity at the level of injury may be seen.<sup>66</sup> Associated widening of the facet joint space and interlaminar and interspinous joint spaces is indicative of complete disruption of posterior ligamentous structures and is supportive of the diagnosis of flexion teardrop fracture. The distinction from extension teardrop fracture can be made because the extension teardrop fracture has no kyphotic deformity and the posterior ligamentous structures are intact.<sup>66,80</sup>



**Figure 6 (A and B)** Flexion teardrop fracture. A sagittal-reformatted computed tomography image (**A**) shows a triangular bone fragment (arrow) arising from the anterosuperior corner of the C7 vertebral body with localized prevertebral soft-tissue swelling. Posterior ligamentous injuries (arrowheads in **B**) are better appreciated on sagittal short-tau inversion-recovery magnetic resonance image (**B**).

**Notes:** Disruption of the interspinous ligament of C6/7. Degenerative disk disease and compressive myelopathy are incidental.



Other commonly associated injuries are laminar fractures and sagittal-plane fracture of the vertebral body, which are best seen on CT scan.<sup>80,81</sup>

### Hyperflexion sprain

Hyperflexion sprain or anterior subluxation of the cervical spine is characterized by localized pure disruption of posterior ligamentous structures. The injury commonly occurs below C4.<sup>82</sup> The bony injury is typically absent, although minor wedge compression on the anterior portion of the vertebral body may coexist. Neurological deficit is usually mild and reversible.<sup>82</sup> About 20%–33% of patients with posterior ligamentous disruption who received conservative treatment developed progressive kyphosis and delayed spinal instability due to impaired healing of the ligaments.<sup>66,83</sup> Radiographs are frequently normal or may show widening of the interspinous space, localized kyphotic angulation of the cervical spine, anterior narrowing and posterior widening of disk space, and anterior rotation or displacement of the subluxated vertebra.<sup>66,83</sup> Diagnosis may be missed initially if the sprain is mild and the patient is in a recumbent position. Repeated lateral radiograph should be done after pain and

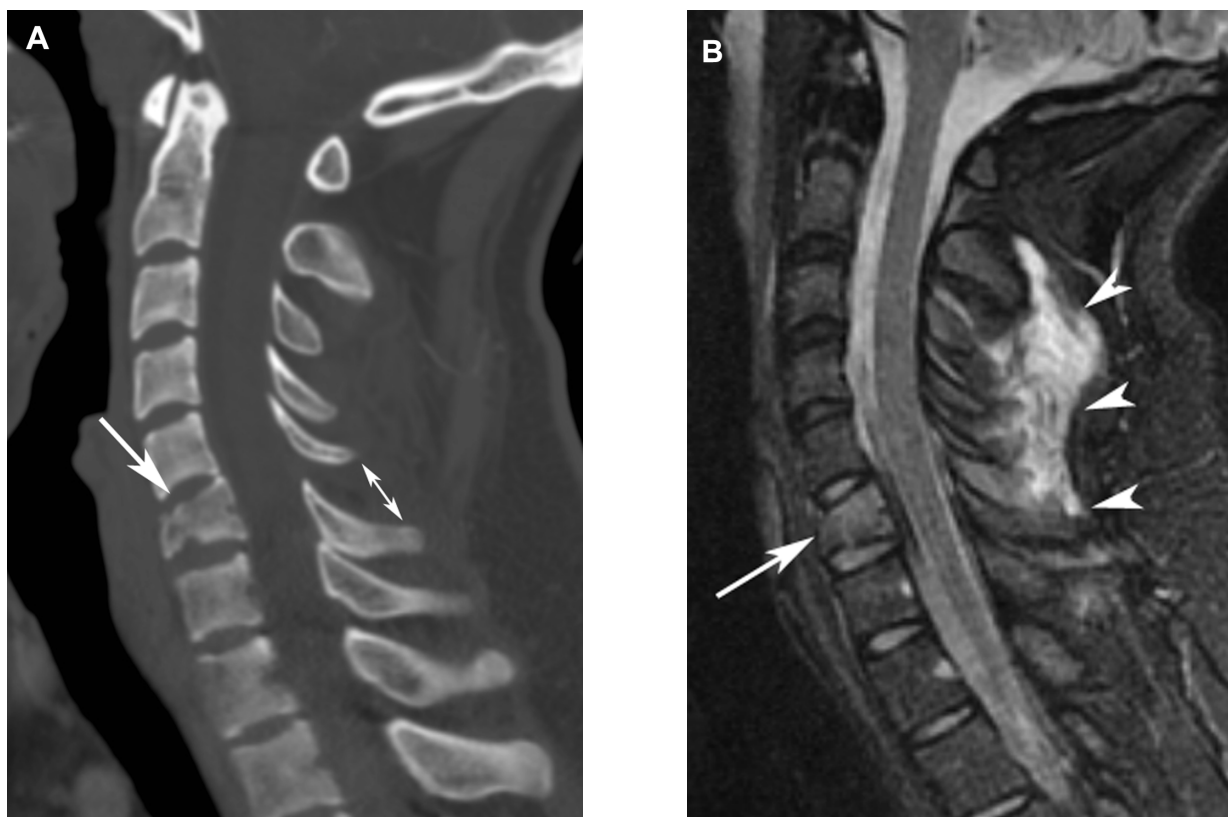
muscle spasm has disappeared and it may reveal kyphotic angulation.<sup>82</sup>

### Anterior wedge compression fracture

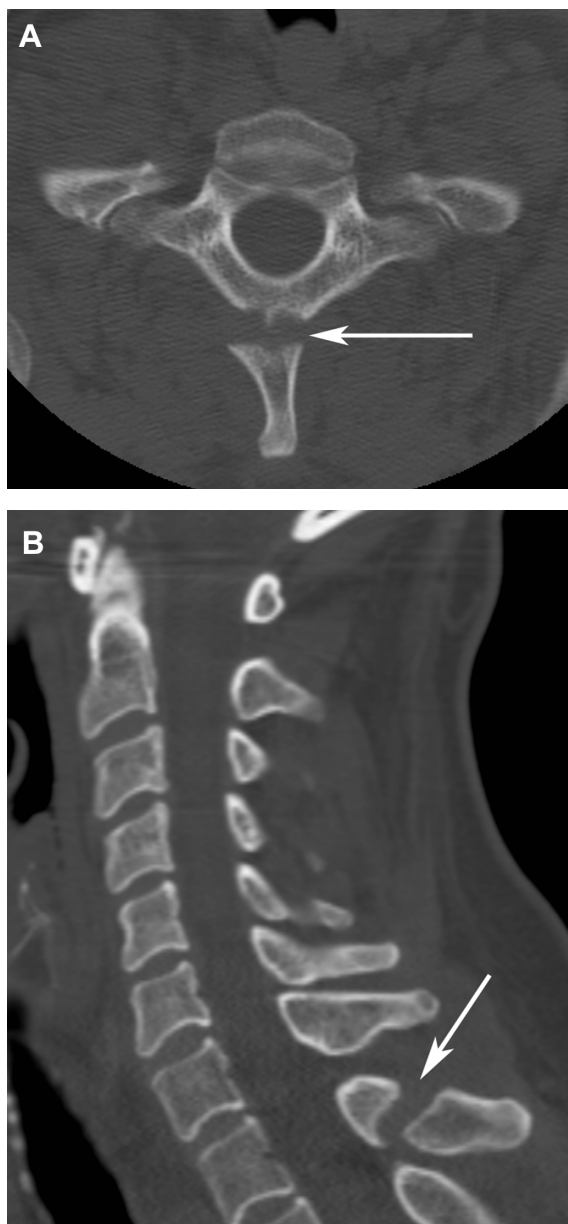
Occasionally, a pure hyperflexion force may completely spare posterior ligaments and result in osseous disruption of only the anterior column of the cervical spine, manifesting as a simple compression fracture (Figure 7) of one or more vertebrae. The compression fracture consists of comminution of the anterosuperior aspect of the vertebral body, without injury to the posterior portion of the vertebral body or posterior ligaments. This type of injury is considered stable, and neurological sequelae are uncommon. The fracture is best demonstrated on lateral radiographs as a loss of anterior vertebral height, buckling of the anterior or superior end plate or both, and soft-tissue swelling.<sup>66</sup>

### Clay-shoveler's fracture

Clay-shoveler's fracture (Figure 8) was initially described in Australian miners by McKellar Hall in the 1940s.<sup>84</sup> It is an oblique fracture of the spinous process of the lower cervical and upper thoracic vertebrae. The most common site is C7,



**Figure 7 (A and B)** Anterior wedge compression fracture. A sagittal-reformatted computed tomography image (A) demonstrates an anterior wedge compression fracture of C6 (arrow) and widening of the C5/6 interspinous space (double-headed arrow). Posterior ligamentous injuries are directly visualized at several levels above C5/6 (arrowheads) on a sagittal short-tau inversion-recovery magnetic resonance image (B).



**Figure 8 (A and B)** Clay-shoveler's fracture. Axial (A) and sagittal-reformatted (B) computed tomography images show a distracted fracture of the spinous process of T1 (arrows).

but it can occur anywhere from C6 to T3.<sup>66,85</sup> The fracture may involve single or multiple spinous processes and usually occurs at the narrowest part, which is the weakest point of the spinous process. These fractures are best demonstrated on a lateral view as an obliquely orientated lucent line midway between the spinous process tip and spinolaminar line, with the distal spinous fragment being displaced posteriorly or posteroinferiorly. The AP view may show inferior displacement of the tip of the involved spinous process, also known as “double spinous sign.” This represents simultaneous visualization of the fractured base and the caudally displaced

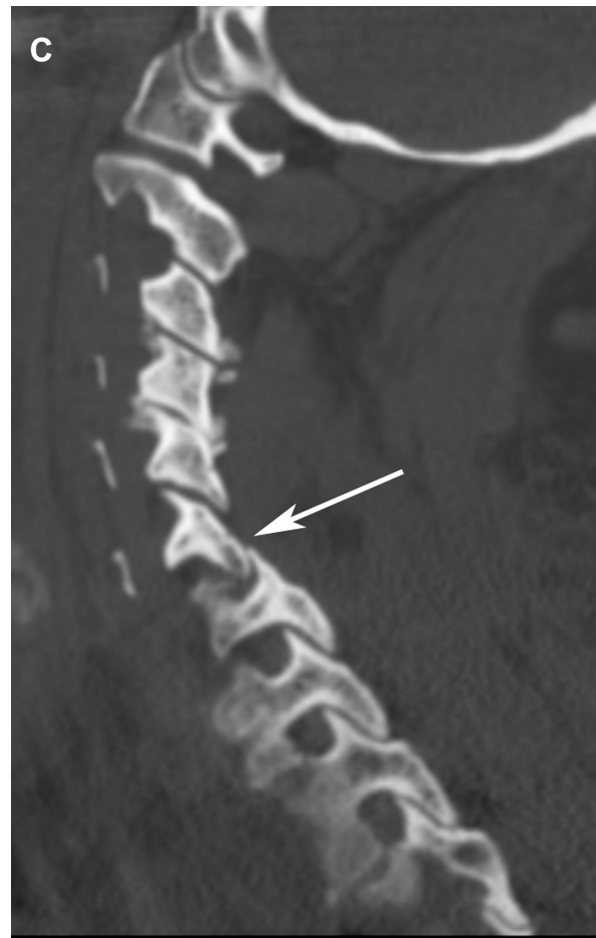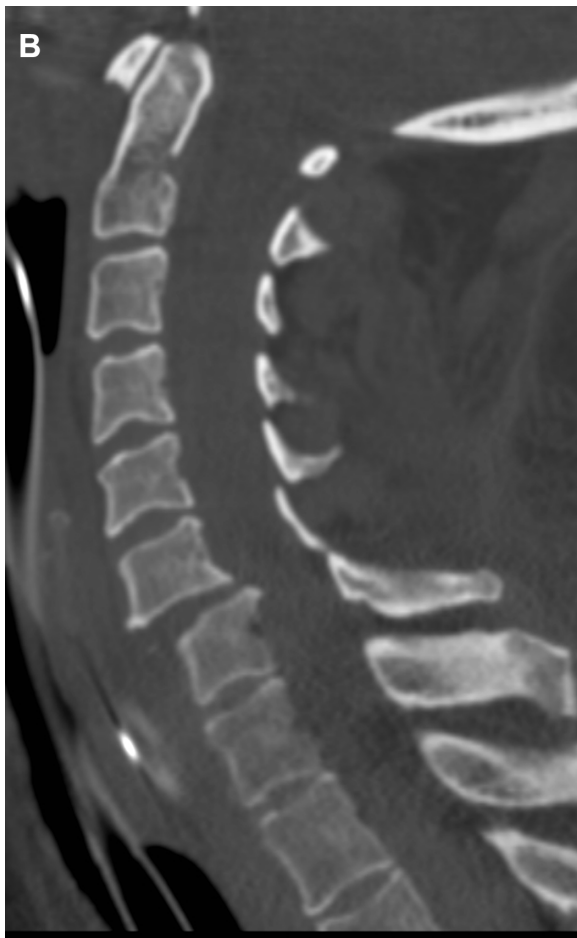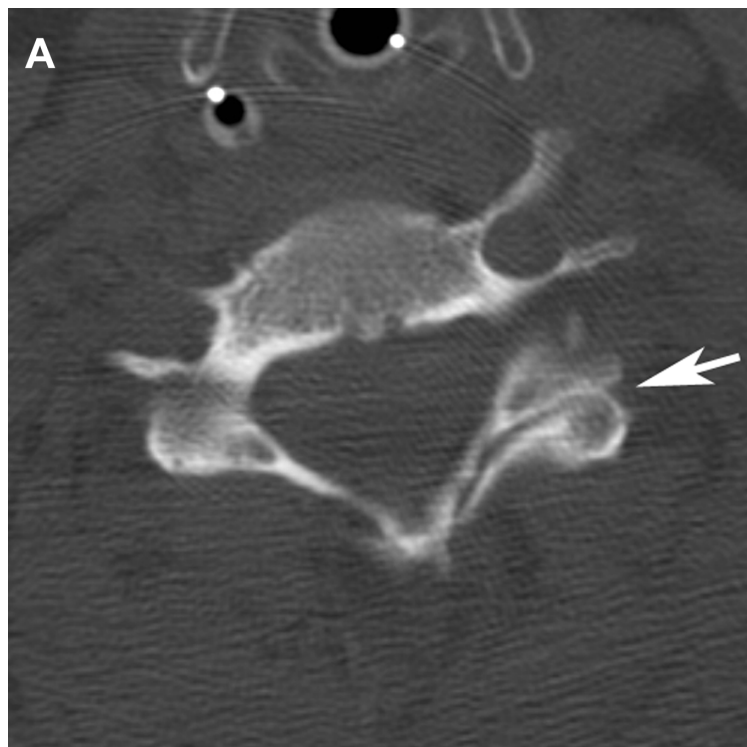
tip of the spinous process tip.<sup>66,85,86</sup> This is a stable fracture because only the spinous process is involved. However, if the fracture line extends beyond the spinolaminar line, one should always exclude the possibility of instability, coexistent fracture, or spinal cord injury by CT scan or MRI.

### Flexion/rotation injuries

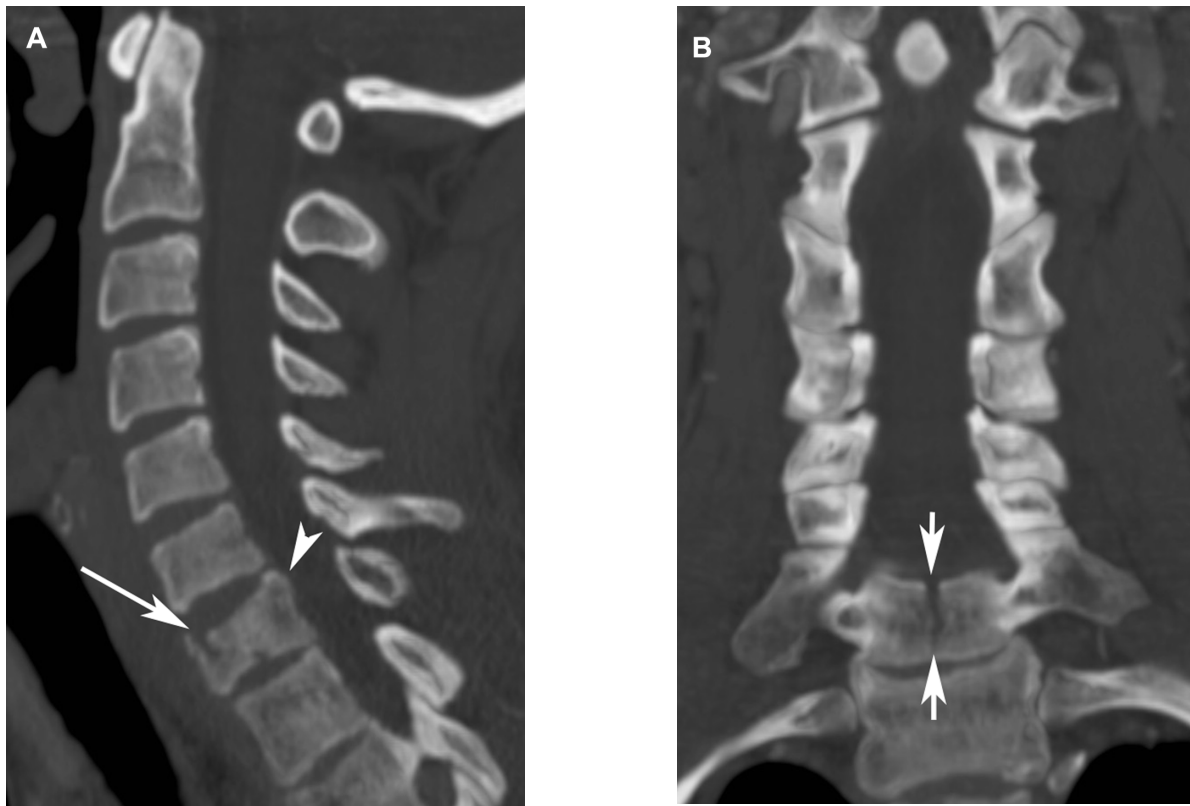
Unilateral facet dislocation (Figure 9) is a common cervical injury produced by a combination of flexion and rotation, accounting for 4%–16% of all cervical spine injuries.<sup>66</sup> Rupture of the interspinous ligament and facet capsule on one side allows the inferior articular process of superior vertebra to slide anteriorly to the superior articular process.<sup>66,75</sup> The most common levels of involvement are C4/C5, C5/C6 and C6/C7.<sup>66,70</sup> This type of injury is generally considered stable, but there is a potential mechanical and neurological instability. The lateral radiograph demonstrates abrupt rotation of the vertebra at the level of the dislocation, with loss of normal superimposition of the paired facets at and superior to the level of injury. Displacement and rotation of the articular facets produce the “bow tie” appearance, representing an anteriorly displaced facet above and the normally positioned facet below. Anterolisthesis of the superior vertebra also occurs, but to a lesser degree than that of bilateral facet dislocations. The degree of anterolisthesis is about one-quarter of the sagittal diameter of the vertebral body and not exceeding half of the diameter. The AP view demonstrates lateral displacement of the spinous process of superior vertebra to the side of injury. On axial CT scan, the unilateral “naked facet sign” or “reversed hamburger-bun sign” is also seen.<sup>66,75</sup>

### Axial-loading injuries

Cervical burst fractures (Figure 10) are typically the result of a combination of flexion and axial-loading injuries. The most common location is the cervicothoracic junction.<sup>87</sup> The characteristic imaging features are compression fracture of the anterior and middle columns with retropulsion of the posterior vertebral body into the spinal canal. Neurological deficit is common due to a compromised spinal canal.<sup>87</sup> On lateral radiographs, the presence of sagittal vertebral body widening and retropulsed bone may lead to confusion with flexion teardrop injury, but the burst fracture lacks the anteroinferior triangular fragment, exhibits loss of vertebral height, and is not associated with kyphotic deformity or injuries to posterior ligamentous structures.<sup>66</sup> On the AP view, the sagittal fracture line may be demonstrated and extends across the entire height of the involved vertebra body.<sup>66</sup>



**Figure 9 (A–C)** Unilateral facet dislocation. An axial computed tomography image (A) reveals a reversed hamburger-bun sign (arrow) of the left C6/7 facet. Sagittal-reformatted computed tomography images (B and C) show grade I anterolisthesis of C6 on C7 and a jumped C6/7 left facet (long arrow).



**Figure 10 (A and B)** Burst fracture. A sagittal-reformatted computed tomography image (**A**) demonstrates a burst fracture (arrow) of the C7 vertebral body with mild posterior cortex retropulsion (arrowhead). Note a sagittally oriented fracture line (short arrows) extending to the posterior half of the C7 body, better seen on the coronal-reformatted image (**B**).

CT readily confirms the nature of this fracture and demonstrates the degree of posterior retropulsion and spinal canal compromise.

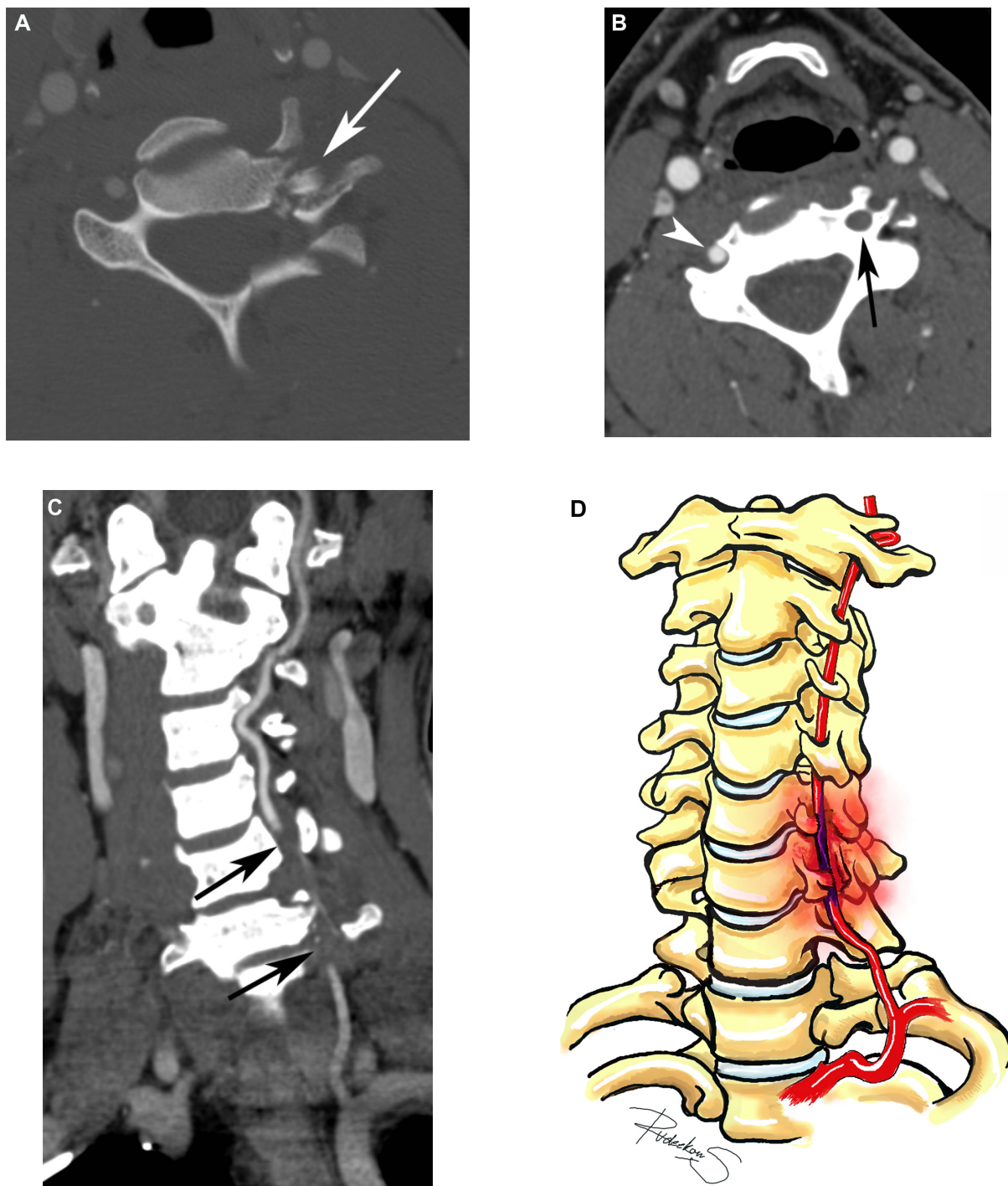
### Lateral hyperflexion injuries

Lateral hyperflexion injuries, also known as lateral bending injuries, are uncommon and often unrecognized cervical spine trauma. These injuries represent only 6% of all cervical spine injuries.<sup>66</sup> A direct force delivered to the lateral aspect of the cervical spine produces these injuries, which include fractures of the transverse process, uncinat process, lateral wedge-type fracture of the vertebral body, and brachial plexopathy in association with cervical spine fracture or dislocation.<sup>66,88</sup> The most common injury is transverse-process fracture, which accounts for approximately 35% of cases. The most frequently involved level is C7.<sup>88</sup> Associated fracture of the vertebral arch may also occur. The presence and degree of neurological deficit varies, depending on the level of injury and its severity, ranging from minor transient neurological deficit to complete quadriplegia or even death.<sup>66,88</sup> This injury was probably under-reported because it is not often demonstrated on lateral cervical radiographs, but is now readily detected with CT.<sup>88</sup>

### Vertebral artery injury in blunt cervical trauma

Injuries to the vertebral artery (Figure 11) may be a complication of cervicothoracic junction trauma. The overall incidence of vertebral artery injury ranges from 0.5% to 2% of all blunt-trauma patients and less than 1% of penetrating neck-trauma patients.<sup>89–94</sup> Among patients with cervical spine fracture, the incidence may be up to 39%, with mortality rate ranging from 4% to 18%.<sup>89,92,94–98</sup> Vertebral artery injuries can occur anywhere along the course of the artery, from its origin at the subclavian artery to where it enters the foramen magnum. The injuries associated with cervical spine trauma most frequently occur at the intraforaminal segment or V2 segment. The vertebral artery enters the C6 transverse foramen in 71%–90% of normal population, with a minority of cases entering C4, C5, and C7 transverse foramina.<sup>99–105</sup> Relatively fixed anatomy inside the transverse foramen makes the vertebral artery vulnerable to shearing force and is prone to injury. Screening for vertebral injury is indicated in selected high-risk patients, including fracture involving transverse foramen, subluxations, or penetrating injuries adjacent to vascular structures.<sup>46,90,91,94–97</sup> CT angiography (CTA) of the head





**Figure 11 (A–D)** Blunt vertebral artery injury. An axial computed tomography image (A) shows a severely comminuted fracture (arrow) of the left C6 articular pillar, pedicle, lamina, and transverse process. Axial (B) and curved reformat of the left vertebral artery (C) postcontrast computed tomography reveals absence of flow in the right vertebral artery at the level of fracture, above and below it (black arrows). Note an injury depicted on diagram D and a normal left vertebral artery in B (arrowhead).

and neck is currently recommended as a preferred method for screening of vertebral artery injury, because of rapid image-acquisition time and 24-hour availability with acceptable sensitivity and specificity. Digital subtraction angiography should be done to exclude lesion in cases of negative CTA but high clinical suspicion or in cases that need interventional

procedures. MR angiography is another preferable modality if the CTA cannot be done for any reason.<sup>51,89,106</sup>

### Dural injury

The true incidence of the cervical dural tear following blunt injury to the cervical spine is unknown, whereas following



nonmissile-penetrating injury to the neck, it has been reported as high as 36% of cases.<sup>107</sup> The majority of cases are among those suffered from thoracolumbar and lumbar burst fracture and incidental durotomy during spinal surgery.<sup>108–111</sup> Patients with Marfan syndrome and other connective tissue disorders, dural ectasia and dural diverticula, and extensive posterior osteophyte are at increased risk of this injury even after trivial or less violent trauma. Most dural tears can heal spontaneously, leaving an irregular outline of the thecal sac. However, if meningitis occurs, it may result in an indefinite opening tract, persistence or worsening of the neurological symptoms, nerve-root entrapment, formation of pseudomeningocele, spinal cord compression, or even transdural spinal cord herniation.<sup>112–115</sup>

Attention should focus on looking for the possibility of dural injury on imaging, because the defect can be primarily repaired at the time of surgery, particularly if it is accessible. A dural tear is usually associated with unstable fracture with a sharp bony fragment impinging on the dura. It is traditionally diagnosed on conventional myelography, which is potentially not feasible in acutely traumatized patients. Currently, MR myelography or MR cisternography seems to be the investigation of choice.<sup>107,115</sup> Heavily  $T_2$ -weighted images combined with fat-suppression techniques provide excellent contrast between the bright signal of cerebrospinal fluid and the low signal of the adjacent soft tissue, making MRI very sensitive for detecting cerebrospinal fluid accumulation and pseudomeningocele. However, MRI is subject to motion artifact and a small (less than 1 cm) dural tear may still be overlooked. In addition, dural defect or nerve-root herniation may not be demonstrated because of severe encroachment of the spinal canal and coexisting epidural hematoma.<sup>115</sup>

## Summary

The cervicothoracic junction is a unique region of the cervical spine in terms of anatomy and biomechanics. Injuries are often either of a hyperextension or hyperflexion type. Radiography in this location is often difficult and inadequate; therefore, CT with multiplanar reformations is usually performed to diagnose or exclude the presence of cervicothoracic junction trauma. Knowledge about mechanisms of injuries, as well as typical image findings, will make physicians more comfortable and confident in managing these injuries.

## Disclosure

The authors report no conflicts of interest in this work.

## References

1. Wang VY, Chou D. The cervicothoracic junction. *Neurosurg Clin N Am.* 2007;18(2):365–371.
2. Kim JW, Jeong JH. Fractures and dislocations of the cervicothoracic junction. *J Korean Neurosurg Soc.* 2007;42(3):211–215.
3. Jelly LM, Evans DR, Easty MJ, Coats TJ, Chan O. Radiography versus spiral CT in the evaluation of cervicothoracic junction injuries in polytrauma patients who have undergone intubation. *Radiographics.* 2000;20 Spec No: S251–S259; discussion S260–S262.
4. Ireland AJ, Britton I, Forrester AW. Do supine oblique views provide better imaging of the cervicothoracic junction than swimmer's views? *J Accid Emerg Med.* 1998;15(3):151–154.
5. Evans DK. Dislocations at the cervicothoracic junction. *J Bone Joint Surg Br.* 1983;65(2):124–127.
6. Amin A, Saifuddin A. Fractures and dislocations of the cervicothoracic junction. *J Spinal Disord Tech.* 2005;18(6):499–505.
7. Bellabarba C, Nemecek A, Chapman J. Management of injuries to the cervicothoracic junction. *Tech Orthop.* 2002;17(3):355–364.
8. Chen J, Eismont FJ. Cervicothoracic trauma: diagnosis and treatment. *Semin Spine Surg.* 2005;17(2):84–90.
9. Nichols CG, Young DH, Schiller WR. Evaluation of cervicothoracic junction injury. *Ann Emerg Med.* 1987;16(6):640–642.
10. Lowery DW, Wald MM, Browne BJ, et al. Epidemiology of cervical spine injury victims. *Ann Emerg Med.* 2001;38(1):12–16.
11. Leucht P, Fischer K, Muhr G, Mueller EJ. Epidemiology of traumatic spine fractures. *Injury.* 2009;40(2):166–172.
12. Goldberg W, Mueller C, Panacek E, et al. Distribution and patterns of blunt traumatic cervical spine injury. *Ann Emerg Med.* 2001;38(1):17–21.
13. Platzer P, Hauswirth N, Jaendl M, et al. Delayed or missed diagnosis of cervical spine injuries. *J Trauma.* 2006;61(1):150–155.
14. Gerrelts BD, Petersen EU, Mabry J, Petersen SR. Delayed diagnosis of cervical spine injuries. *J Trauma.* 1991;31(12):1622–1626.
15. El Fegoun AB, Staccini P, Gille O, de Peretti F. Delayed diagnosis of inferior cervical spine injury. *Rev Chir Orthop Reparatrice Appar Mot.* 2004;90(6):517–524. French.
16. Reid DC, Henderson R, Saboe L, Miller JD. Etiology and clinical course of missed spine fractures. *J Trauma.* 1987;27(9):980–986.
17. Apfelbaum JD, Cantrill SV, Waldman N. Unstable cervical spine without spinal cord injury in penetrating neck trauma. *Am J Emerg Med.* 2000;18(1):55–57.
18. Grossman MD, Reilly PM, Gillett T, Gillett D. National survey of the incidence of cervical spine injury and approach to cervical spine clearance in US trauma centers. *J Trauma.* 1999;47(4):684–690.
19. Davis JW, Phreaner DL, Hoyt DB, Mackersie RC. The etiology of missed cervical spine injuries. *J Trauma.* 1993;34(3):342–346.
20. Sapkas G, Papadakis S, Katonis P, Roidis N, Kontakis G. Operative treatment of unstable injuries of the cervicothoracic junction. *Eur Spine J.* 1999;8(4):279–283.
21. Cusick JF, Yoganandan N. Biomechanics of the cervical spine 4: major injuries. *Clin Biomech (Bristol, Avon).* 2002;17(1):1–20.
22. Blackmore CC, Emerson SS, Mann FA, Koepsell TD. Cervical spine imaging in patients with trauma: determination of fracture risk to optimize use. *Radiology.* 1999;211(3):759–765.
23. Como JJ, Diaz JJ, Dunham CM, et al. Practice management guidelines for identification of cervical spine injuries following trauma: update from the eastern association for the surgery of trauma practice management guidelines committee. *J Trauma.* 2009;67(3):651–659.
24. Hoffman JR, Mower WR, Wolfson AB, Todd KH, Zucker MI. Validity of a set of clinical criteria to rule out injury to the cervical spine in patients with blunt trauma. National Emergency X-Radiography Utilization Study Group. *N Engl J Med.* 2000;343(2):94–99.
25. Stiell IG, Wells GA, Vandemheen KL, et al. The Canadian C-spine rule for radiography in alert and stable trauma patients. *JAMA.* 2001;286(15):1841–1848.
26. Yealy DM, Auble TE. Choosing between clinical prediction rules. *N Engl J Med.* 2003;349(26):2553–2555.

27. Weiner SG. The actual application of the NEXUS and Canadian c-spine rules by emergency physicians. *Internet J Emerg Med.* 2009;5(2).
28. Mower WR, Hoffman J. Comparison of the Canadian C-Spine rule and NEXUS decision instrument in evaluating blunt trauma patients for cervical spine injury. *Ann Emerg Med.* 2004;43(4):515–517.
29. Knopp R. Comparing NEXUS and Canadian C-Spine decision rules for determining the need for cervical spine radiography. *Ann Emerg Med.* 2004;43(4):518–520.
30. Dickinson G, Stiell IG, Schull M, et al. Retrospective application of the NEXUS low-risk criteria for cervical spine radiography in Canadian emergency departments. *Ann Emerg Med.* 2004;43(4):507–514.
31. Stiell IG, Clement CM, McKnight RD, et al. The Canadian C-spine rule versus the NEXUS low-risk criteria in patients with trauma. *N Engl J Med.* 2003;349(26):2510–2518.
32. Eyre A. Overview and comparison of NEXUS and Canadian c-spine rules. *Am J Clin Med.* 2006;3(4):12–15.
33. Saltzherr TP, Fung Kon Jin PH, Beenen LF, Vandertop WP, Goslings JC. Diagnostic imaging of cervical spine injuries following blunt trauma: a review of the literature and practical guideline. *Injury.* 2009;40(8):795–800.
34. Rethnam U, Yesupalan RS, Bastawrous SS. The Swimmer's view: does it really show what it is supposed to show? A retrospective study. *BMC Med Imaging.* 2008;8:2.
35. Moulton C, Griffiths PD. The adequacy of cervical spine radiographs in the accident and emergency department. *J R Soc Med.* 1993;86(3):141–143.
36. Gale SC, Gracias VH, Reilly PM, Schwab CW. The inefficiency of plain radiography to evaluate the cervical spine after blunt trauma. *J Trauma.* 2005;59(5):1121–1125.
37. Zabel DD, Tinkoff G, Wittenborn W, Ballard K, Fulda G. Adequacy and efficacy of lateral cervical spine radiography in alert, high-risk blunt trauma patient. *J Trauma.* 1997;43(6):952–956; discussion 957–958.
38. Daffner RH. Cervical radiography for trauma patients: a time-effective technique? *AJR Am J Roentgenol.* 2000;175(5):1309–1311.
39. Bailitz J, Starr F, Beecroft M, et al. CT should replace three-view radiographs as the initial screening test in patients at high, moderate, and low risk for blunt cervical spine injury: a prospective comparison. *J Trauma.* 2009;66(6):1605–1609.
40. Holmes JF, Akkinpalli R. Computed tomography versus plain radiography to screen for cervical spine injury: a meta-analysis. *J Trauma.* 2005;58(5):902–905.
41. McCulloch PT, France J, Jones DL, et al. Helical computed tomography alone compared with plain radiographs with adjunct computed tomography to evaluate the cervical spine after high-energy trauma. *J Bone Joint Surg Am.* 2005;87(11):2388–2394.
42. Griffen MM, Frykberg ER, Kerwin AJ, et al. Radiographic clearance of blunt cervical spine injury: plain radiograph or computed tomography scan? *J Trauma.* 2003;55(2):222–226; discussion 226–227.
43. Daffner RH. Helical CT of the cervical spine for trauma patients: a time study. *AJR Am J Roentgenol.* 2001;177(3):677–679.
44. Daffner RH. Controversies in cervical spine imaging in trauma patients. *Sem Musculoskelet Radiol.* 2005;9(2):105–115.
45. Daffner RH, Sciulli RL, Rodriguez A, Protetch J. Imaging for evaluation of suspected cervical spine trauma: a 2-year analysis. *Injury.* 2006;37(7):652–658.
46. Bagley LJ. Imaging of spinal trauma. *Radiol Clin N Am.* 2006;44(1):1–12, vii.
47. Mathen R, Inaba K, Munera F, et al. Prospective evaluation of multislice computed tomography versus plain radiographic cervical spine clearance in trauma patients. *J Trauma.* 2007;62(6):1427–1431.
48. Pinheiro DF, Fontes B, Shimazaki JK, Oliveira Bernini C, Rasslan S. Diagnostic value of tomography of the cervical spine in victims of blunt trauma. *Rev Col Bras Cir.* 2011;38(5):299–303.
49. Hanson JA, Blackmore CC, Mann FA, Wilson AJ. Cervical spine injury: accuracy of helical CT used as a screening technique. *Emerg Radiol.* 2000;7(1):31–35.
50. Sanchez B, Waxman K, Jones T, et al. Cervical spine clearance in blunt trauma: evaluation of a computed tomography-based protocol. *J Trauma.* 2005;59(1):179–183.
51. Daffner RH, Hackney DB. ACR Appropriateness Criteria on suspected spine trauma. *J Am Coll Radiol.* 2007;4(11):762–775.
52. Quann JT, Sidwell RA. Imaging of the cervical spine in injured patients. *Surg Clin N Am.* 2011;91(1):209–216.
53. Van Goethem JW, Maes M, Ozsarlak O, van den Hauwe L, Parizel PM. Imaging in spinal trauma. *Eur Radiol.* 2005;15(3):582–590.
54. Insko EK, Gracias VH, Gupta R, et al. Utility of flexion and extension radiographs of the cervical spine in the acute evaluation of blunt trauma. *J Trauma.* 2002;53(3):426–429.
55. Pitt E, Thakore S. Best evidence topic report. Role of flexion/extension radiography in neck injuries in adults. *Emerg Med J.* 2004;21(5):587–588.
56. Pollack CV Jr, Hendey GW, Martin DR, Hoffman JR, Mower WR. Use of flexion-extension radiographs of the cervical spine in blunt trauma. *Ann Emerg Med.* 2001;38(1):8–11.
57. Lewis LM, Docherty M, Ruoff BE, et al. Flexion-extension views in the evaluation of cervical-spine injuries. *Ann Emerg Med.* 1991;20(2):117–121.
58. Khan SN, Erickson G, Sena MJ, Gupta MC. Use of flexion and extension radiographs of the cervical spine to rule out acute instability in patients with negative computed tomography scans. *J Orthop Trauma.* 2011;25(1):51–56.
59. Nasir S, Hussain M, Mahmud R. Flexion/extension cervical spine views in blunt cervical trauma. *Chin J Traumatol.* 2012;15(3):166–169.
60. Ackland HM, Cameron PA, Varma DK, et al. Cervical spine magnetic resonance imaging in alert, neurologically intact trauma patients with persistent midline tenderness and negative computed tomography results. *Ann Emerg Med.* 2011;58(6):521–530.
61. Menaker J, Philp A, Boswell S, Scalea TM. Computed tomography alone for cervical spine clearance in the unreliable patient – are we there yet? *J Trauma.* 2008;64(4):898–903; discussion 903–894.
62. Steinmetz MP, Miller J, Warbel A, et al. Regional instability following cervicothoracic junction surgery. *J Neurosurg Spine.* 2006;4(4):278–284.
63. Patel MM, Gohil DV, Singel TC. Orientation of superior articular facets from C3 to S1 vertebrae. *J Anat Soc India.* 2004;53(2):35–39.
64. Panjabi MM. The stabilizing system of the spine. Part I. Function, dysfunction, adaptation, and enhancement. *J Spinal Disord.* 1992;5(4):383–389; discussion 397.
65. Minigh J. Traumatic injuries to the cervical spine. *Radiol Technol.* 2005;77(1):53–68; quiz 69–72, 75.
66. Pathria MN. Physical injury: spine. In: Resnick D, editor. *Bone and Joint Imaging.* 3rd ed. Philadelphia: Elsevier; 2005:878–904.
67. Rao SK, Wasyliw C, Nunez DB Jr. Spectrum of imaging findings in hyperextension injuries of the neck. *Radiographics.* 2005;25(5):1239–1254.
68. Kalayci M, Cağavi F, Açıkgöz B. Unilateral cervical facet fracture: presentation of two cases and literature review. *Spinal Cord.* 2004;42(8):466–472.
69. Lee SH, Sung JK. Unilateral lateral mass-facet fractures with rotational instability: new classification and a review of 39 cases treated conservatively and with single segment anterior fusion. *J Trauma.* 2009;66(3):758–767.
70. Hadley MN, Fitzpatrick BC, Sonntag VK, Browner CM. Facet fracture-dislocation injuries of the cervical spine. *Neurosurgery.* 1992;30(5):661–666.
71. Halliday AL, Henderson BR, Hart BL, Benzel EC. The management of unilateral lateral mass/facet fractures of the subaxial cervical spine: the use of magnetic resonance imaging to predict instability. *Spine.* 1997;22(22):2614–2621.
72. Lifeso RM, Colucci MA. Anterior fusion for rotationally unstable cervical spine fractures. *Spine.* 2000;25(16):2028–2034.
73. Beyer CA, Cabanela ME. Unilateral facet dislocations and fracture-dislocations of the cervical spine: a review. *Orthopedics.* 1992;15(3):311–315.

74. Rabb CH, Lopez J, Beauchamp K, et al. Unilateral cervical facet fractures with subluxation: injury patterns and treatment. *J Spinal Disord Tech*. 2007;20(6):416–422.
75. Daffner SD, Daffner RH. Computed tomography diagnosis of facet dislocations: the “hamburger bun” and “reverse hamburger bun” signs. *J Emerg Med*. 2002;23(4):387–394.
76. Razack N, Green BA, Levi AD. The management of traumatic cervical bilateral facet fracture-dislocations with unicortical anterior plates. *J Spinal Disord*. 2000;13(5):374–381.
77. Kim SW, Ciccarelli JM, Fedder IL. Bilateral cervical facet dislocation without neurological injury. *Orthopedics*. 2004;27(12):1297–1298.
78. Lingawi SS. The naked facet sign. *Radiology*. 2001;219(2):366–367.
79. Sahoo SS, Gupta D, Mahapatra AK. Cervical spine injury with bilateral facet dislocation, surgical treatment and outcome analysis: a prospective study of 19 cases. *Indian J Neurotrauma*. 2012;9(1):40–44.
80. Kim KS, Chen HH, Russell EJ, Rogers LF. Flexion teardrop fracture of the cervical spine: radiographic characteristics. *AJR Am J Roentgenol*. 1989;152(2):319–326.
81. Motsitsi NS, Bomela LN. Tear-drop fractures of the cervical spine. *East Afr J Surg*. 2009;14(2):9–12.
82. Braakman M, Braakman R. Hyperflexion sprain of the cervical spine. Follow-up of 45 cases. *Acta Orthop Scand*. 1987;58(4):388–393.
83. Green JD, Harle TS, Harris JH Jr. Anterior subluxation of the cervical spine: hyperflexion sprain. *AJNR Am J Neuroradiol*. 1981;2(3):243–250.
84. McKellar Hall RD. Clay-shoveler's fracture. *J Bone Joint Surg*. 1940;12(1):63–75.
85. Feldman VB, Astri F. An atypical clay shoveler's fracture: a case report. *J Can Chiropr Assoc*. 2001;45(4):213–220.
86. Cancellmo JJ Jr. Clay shoveler's fracture. A helpful diagnostic sign. *AJR Am J Roentgenol*. 1972;115(3):540–543.
87. Bensch FV, Koivikko MP, Kiuru MJ, Koskinen SK. The incidence and distribution of burst fractures. *Emerg Radiol*. 2006;12(3):124–129.
88. Schaaf RE, Gehweiler JA, Miller MD, Powers B. Lateral hyperflexion injuries of the cervical spine. *Skelet Radiol*. 1978;3(2):73–78.
89. Desouza RM, Crocker MJ, Haliasos N, Rennie A, Saxena A. Blunt traumatic vertebral artery injury: a clinical review. *Eur Spine J*. 2011;20(9):1405–1416.
90. Fassett DR, Dailey AT, Vaccaro AR. Vertebral artery injuries associated with cervical spine injuries: a review of the literature. *J Spinal Disord Tech*. 2008;21(4):252–258.
91. Inamasu J, Guiot BH. Vertebral artery injury after blunt cervical trauma: an update. *Surg Neurol*. 2006;65(3):238–245; discussion 245–246.
92. Jang JW, Lee JK, Hur H, et al. Vertebral artery injury after cervical spine trauma: a prospective study using computed tomographic angiography. *Surg Neurol Int*. 2011;2:39.
93. Miller PR, Fabian TC, Bee TK, et al. Blunt cerebrovascular injuries: diagnosis and treatment. *J Trauma*. 2001;51(2):279–285; discussion 285–286.
94. Miller PR, Fabian TC, Croce MA, et al. Prospective screening for blunt cerebrovascular injuries: analysis of diagnostic modalities and outcomes. *Ann Surg*. 2002;236(3):386–393; discussion 393–395.
95. Cothren CC, Moore EE, Biffl WL, et al. Cervical spine fracture patterns predictive of blunt vertebral artery injury. *J Trauma*. 2003;55(5):811–813.
96. Fleck SK, Langner S, Baldauf J, et al. Blunt craniocervical artery injury in cervical spine lesions: the value of CT angiography. *Acta Neurochir (Wien)*. 2010;152(10):1679–1686.
97. Khachatryan T, Fanarjyan R, Menard J, Minasyan A, Grigorian A. Arterial injury in acute cervical spine trauma. *J Neurosurg Rev*. 2012;1(1):31–37.
98. Biffl WL, Moore EE, Elliott JP, et al. The devastating potential of blunt vertebral arterial injuries. *Ann Surg*. 2000;231(5):672–681.
99. Matula C, Trattng S, Tschabitscher M, Day JD, Koos WT. The course of the prevertebral segment of the vertebral artery: anatomy and clinical significance. *Surg Neurol*. 1997;48(2):125–131.
100. Ranganatha Sastry V, Manjunath KY. The course of the V1 segment of the vertebral artery. *Ann Indian Acad Neurol*. 2006;9(4):223–226.
101. Chanapa P, Mahakkanukrauh P. Anatomical variations of the V2 vertebral artery study by measuring the width of transverse foramen. *J Med Assoc Thai*. 2012;95(4):569–573.
102. Bruneau M, Cornelius JF, Marneffe V, Triffaux M, George B. Anatomical variations of the V2 segment of the vertebral artery. *Neurosurgery*. 2006;59(1 Suppl 1):ONS20–ONS24; discussion ONS20–ONS24.
103. Kajimoto BHJ, Addeo RLD, de Campos GC, et al. Anatomical study of the vertebral artery path in human lower cervical spine. *Acta Ortop Bras*. 2007;15(2):84–86.
104. Hong JT, Park DK, Lee MJ, Kim SW, An HS. Anatomical variations of the vertebral artery segment in the lower cervical spine: analysis by three-dimensional computed tomography angiography. *Spine*. 2008;33(22):2422–2426.
105. Heary RF, Albert TJ, Ludwig SC, et al. Surgical anatomy of the vertebral arteries. *Spine*. 1996;21(18):2074–2080.
106. Fredenberg P, Forbes K, Toye L, Partovi S. Assessment of cervical vascular injury with CT angiography. *BNI Q*. 2001;17(3):44–48.
107. Hawk MW, Kim KD. Review of spinal pseudomeningoceles and cerebrospinal fluid fistulas. *Neurosurg Focus*. 2000;9(1):1–8.
108. Hannallah D, Lee J, Khan M, Donaldson WF, Kang JD. Cerebrospinal fluid leaks following cervical spine surgery. *J Bone Joint Surg Am*. 2008;90-A(5):1101–1105.
109. Carl AL, Matsumoto M, Whalen JT. Anterior dural laceration caused by thoracolumbar and lumbar burst fractures. *J Spinal Disord*. 2000;13(5):399–403.
110. Park JK, Park JW, Cho DC, Sung JK. Predictable factors for dural tears in lumbar burst fractures with vertical laminar fractures. *J Korean Neurosurg Soc*. 2011;50(1):11–16.
111. Cammisa FP, Eismont FJ, Green BA. Dural laceration occurring with burst fractures and associated laminar fractures. *J Bone Joint Surg Am*. 1989;71(7):1044–1052.
112. Watters MR, Stears JC, Osborn AG, et al. Transdural spinal cord herniation: imaging and clinical spectra. *AJNR Am J Neuroradiol*. 1998;19(7):1337–1344.
113. Morris RE, Hasso AN, Thompson JR, Hinshaw DB Jr, Vu LH. Traumatic dural tears: CT diagnosis using metrizamide. *Radiology*. 1984;152(2):443–446.
114. Colachis SC 3rd, Rea GL. Dural tear following traumatic spinal cord injury. A delayed complication. *Am J Phys Med Rehabil*. 1992;71(6):352–355.
115. Lee IS, Kim HJ, Lee JS, et al. Dural tears in spinal burst fractures: predictable MR imaging findings. *AJNR Am J Neuroradiol*. 2009;30(1):142–146.

## Reports in Medical Imaging

### Publish your work in this journal

Reports in Medical Imaging is an international, peer-reviewed, open access journal publishing original research, reports, reviews and commentaries on all areas of medical imaging. The manuscript management system is completely online and includes a very quick and fair peer-review system, which is all easy to use.

Submit your manuscript here: <http://www.dovepress.com/reports-in-medical-imaging-journal>

Dovepress

Visit <http://www.dovepress.com/testimonials.php> to read real quotes from published authors.