

Optic nerve sheath meningocele

Juan Carlos Mesa-Gutiérrez
Silvia Muñoz Quiñones
Jorge Arruga Ginebreda

Department of Ophthalmology,
Hospital Universitari de Bellvitge,
L'Hospitalet de Llobregat, Barcelona,
Spain

Abstract: A 53-year-old man presented with a 5-month history of visual loss in his left eye. Visual acuity could be corrected to 20/20 with an increased hyperopic correction. Dilated funduscopy showed faint choroidal folds and elevation of the left optic disc. The coronal view of T2-weighted magnetic resonance imaging demonstrated a fluid-filled dilated sheath surrounding normal optic nerves. General physical examination and cerebrospinal fluid analysis were normal. The subject was diagnosed as having dural ectasia of the optic nerve sheath and followed a course of acetazolamide 250 mg twice daily for three months, and displayed good anatomical and functional results during a 2-year follow-up period. Despite the fact that several authors have recommended an optic nerve decompression, most of the patients follow a benign clinical course. The role of corticosteroids is not described in the literature. Raised levels of proteins in the cerebrospinal fluid in the perioptic subarachnoid space could be a determining factor. On the basis of an osmotic gradient between the cerebral subarachnoid space and perioptic subarachnoid space, carbonic anhydrase inhibitors could be beneficial. In contrast to other reports, we believe that surgical intervention could be reserved for patients with rapid or progressive optic nerve dysfunction.

Keywords: optic nerve, perineural subarachnoid space, optic nerve meningocele, optic nerve tumors

Introduction

Meningocele is a primary cerebrospinal fluid (CSF) cyst of the optic nerve sheath. Presenting symptoms are often related to involvement of the optic nerve, with a slow or rapid decrease in visual acuity.

Computerized tomography (CT) and magnetic resonance imaging (MRI) revealed a tubular-cystic enlargement of the optic nerve/optic-sheath complex with thickening of the optic nerve. Radiological differential diagnosis should include optic nerve tumors such as gliomas, meningiomas, and arachnoid cysts involving the optic nerve sheath. Early surgical management by means of optic nerve/optic nerve sheath decompression affords an improvement of visual function. We report a patient with optic nerve sheath meningocele treated with acetazolamide who showed a maintained improvement during a 2-year follow-up period.

Case report

We report the case of a 53-year-old man who presented with a 5-month history of distorted vision in his left eye. The best corrected visual acuity was 20/40 in the left eye and could be corrected to 20/20 with +2.00D. He was able to perceive all Ishihara color plates and no afferent pupillary defect was present. Humphrey's visual field analysis revealed an enlarged blind spot. Dilated funduscopy showed an elevation of the left optic disc and choroidal folds above the nerve extending into the macula (Figure 1).

A MRI scan with fat-suppression and an off-axis coronal view was performed. On coronal images, a dilated optic nerve sheath was identified as containing a CSF-intensity lesion that was hyperintense on T2-weighted images (Figure 2).

Correspondence: Juan Carlos Mesa-Gutiérrez

Department of Ophthalmology, Hospital
Universitari de Bellvitge, Feixa Llarga
s/n 08907. L'Hospitalet de Llobregat,
Barcelona, Spain
Tel +34 9 3260 7705
Fax +34 9 3260 7981
Email juancarlosmesa@lycos.co.uk

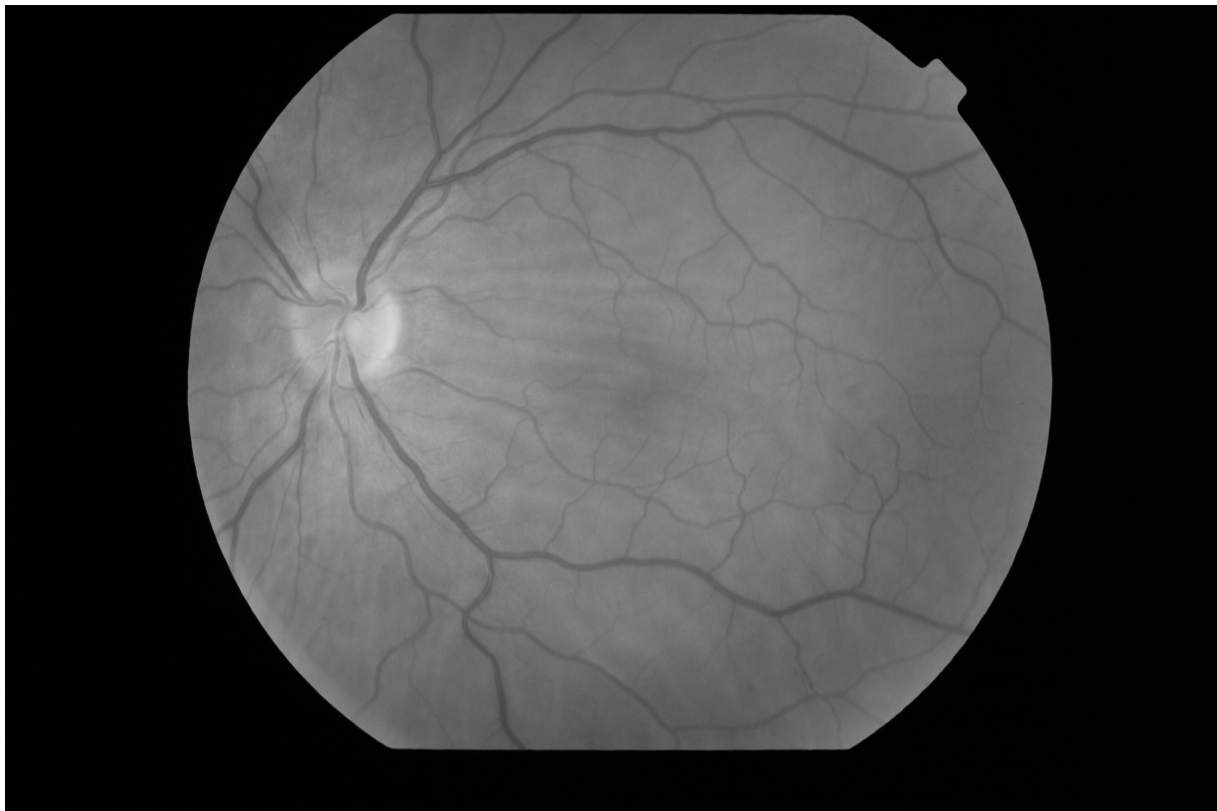


Figure 1 Elevation of the left optic disc and choroidal folds.

The optic nerves were normal, and there was no evidence of tumor in the brain or orbit. A lumbar puncture was performed. CSF opening pressure was 22 mmHg and chemical analysis of CSF was normal. The subject was, therefore, diagnosed as having dural ectasia of the optic nerve sheath, which is also known as optic nerve meningocele, with intracranial hypertension.

Once the diagnosis had been confirmed and the neurosurgical team consulted, the decision to treat with acetazolamide 250 mg twice daily was made. The left optic disc returned to normal within three weeks (Figure 3), and Humphrey's visual field analysis showed no anomalies. The patient was maintained on acetazolamide for three months and remained stable over the next 24 months. In all follow-up examinations, nerve function was normal with a BCVA of 20/20 without optic correction at 24 months.

Discussion

The term "optic nerve sheath meningocele" was first coined in Garrity and colleague's landmark paper in which 13 patients were described with this condition (Garrity et al 1990). As such, the condition arises from the perineural subarachnoid space of the optic nerve, and should be

differentiated from the congenital accumulation of CSF in the perioptic subarachnoid space. In such cases, the lesion is developmental, resulting from an abnormal CSF flow through a diverticulum within the arachnoid membrane. Moreover, a dilation of the optic nerve/optic nerve sheath complex could be secondary to a neoplastic apical mass such as meningioma, vascular hamartoma, glioma, neurofibromatosis, von Hippel-Lindau disease, hemangioma, or cranio-orbital fracture.

The origin of the optic nerve sheath meningocele is still unknown. Hayreh (1984) pointed out that the perioptic subarachnoid space is narrowest in the region of the optic canal, so that the bony part of the optic canal and the cranio-orbital junction could be considered contributing factors in the dynamic alterations of CSF in the perioptic subarachnoid space. Therefore, congenital narrowing of the optic or congenital cranio-orbital junction anomalies could cause optic nerve meningocele.

There were no pathognomonic symptoms that may lead one to suspect an optic nerve dural ectasia. Garrity and colleagues (1990) reported visual blurring and headache as two main symptoms, along with proptosis and optic disc shunt vessels as rare presenting features.

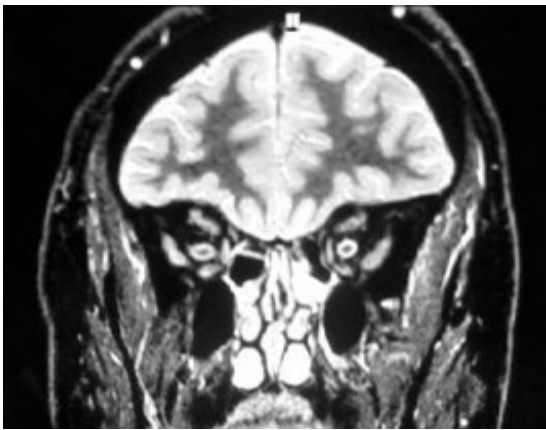


Figure 2 Hyperintense cerebrospinal fluid-intensity lesion.

Apart from its relation to neurofibromatosis type 1 (Lovblad et al 1994; Doi et al 1997), dural ectasia of the optic nerve sheath has been associated with acquired hypermetropia and choroidal folds (Dailey et al 1986; Garrity et al 1990).

The diagnosis can be confirmed by MRI with high spatial resolution, fat-suppression with contrast techniques in

off-axis sagittal views. In coronal MRI, it is possible to see both the optic nerve and sheath: optic nerve sheath meningocele appears as a moderately dilated sheath with fluid and a normal or thickened optic nerve (“bull’s eye”). Short TE/short TR spin echo sequences or chemical shift imaging give the best results. MRI allows a more detailed differential diagnosis of optic nerve meningocele, including optic nerve tumors such as gliomas or meningiomas, especially in the cystic subtype of these tumors.

The role of corticosteroids is not described in the literature; however, in view of its presumed pathology, it may not be beneficial. Surgical intervention involving optic nerve sheath fenestration could be reserved for patients with progressive optic nerve dysfunction.

In summary, optic nerve dural ectasia is a saccular dilatation of the optic nerve sheath. It can be suspected based on the evidence of visual blurring or retrobulbar pressure. Ocular examination may show signs of optic nerve dysfunction. Choroidal folds and hypermetropic shift are suggestive of a meningocele. The radiological investigation of choice is MRI with techniques to emphasize high spatial resolution and optic nerve anatomy. Surgical intervention is reserved for severe cases.

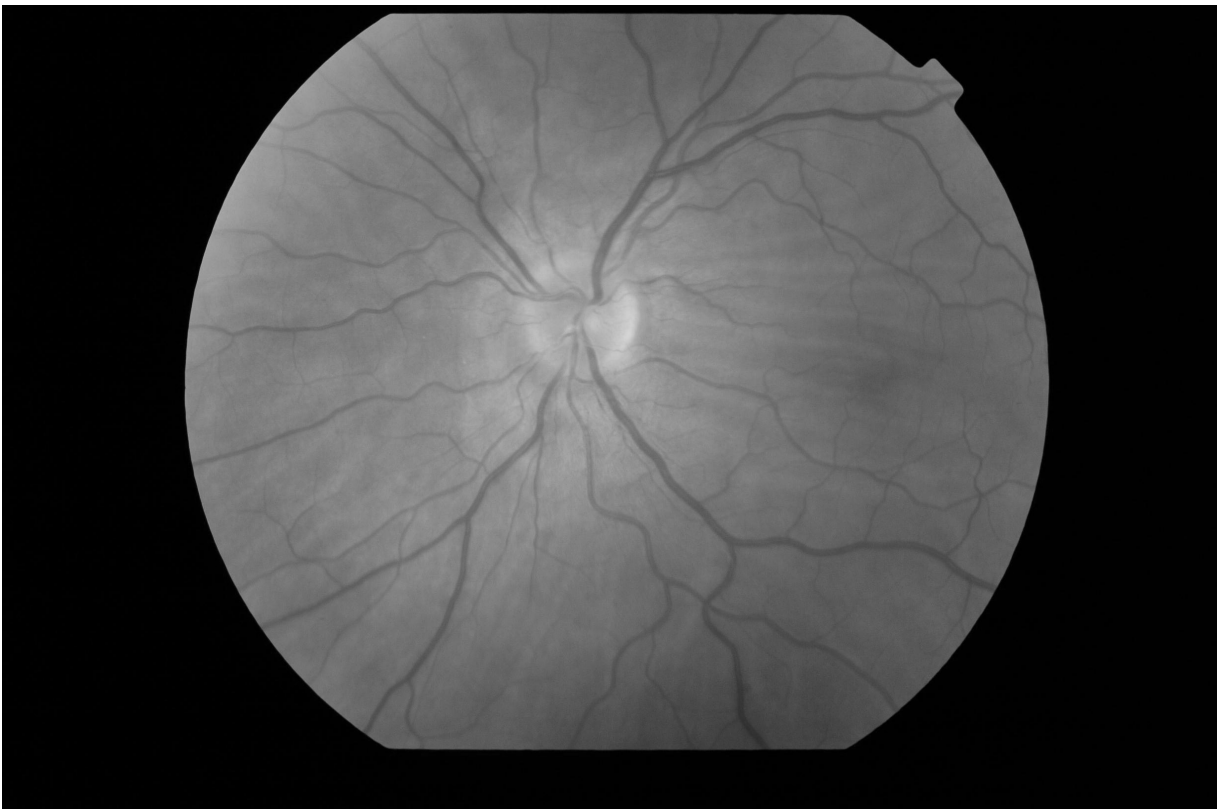

Figure 3 Normal left optic disc.

References

- Dailey RA, Mills RP, Sticmac GK, et al. 1986. The natural history and CT appearance of acquired hyperopia with choroidal folds. *Ophthalmology*, 93:1336–42.
- Doi J, Uchino A, Kato A, et al. 1997. Dural ectasia of the optic nerve sheath in neurofibromatosis type 1: MRI manifestations. *Radiation Med*, 15:197–8.
- Garrity JA, Trautman JC, Bartley GB, et al. 1990. Optic nerve sheath meningoceles. Clinical and radiographic features in 13 cases with a review of the literature. *Ophthalmology*, 97:1519–31.
- Hayreh SS. 1984. The sheath of the optic nerve. *Ophthalmologica*, 189:54–63.
- Lovblad KO, Remonda L, Ozdoba C, et al. 1994. Dural ectasia of the optic nerve sheath in neurofibromatosis type 1: CT and MR features. *J Comput Assist Tomogr*, 18:728–30.