

Systematic review of the role of rituximab in treatment of antineutrophil cytoplasmic autoantibody-associated vasculitis, hepatitis C virus-related cryoglobulinemic vasculitis, Henoch–Schönlein purpura, ankylosing spondylitis, and Raynaud’s phenomenon

Rbab Taha¹
Hadeel El-Haddad¹
Abdulqader Almuallim²
Fatma Alshaiki³
Elaf Obaid²
Hani Almoallim^{1,2,4}

¹Department of Medicine, Dr Soliman Fakeeh Hospital, Jeddah, ²Department of Medicine, Faculty of Medicine, Umm Al-Qura University, Mecca, ³Department of Medicine, East Jeddah Hospital, Jeddah, ⁴Rheumatic Diseases, Umm Al-Qura University, Mecca, Saudi Arabia

Abstract: Rituximab (RTX) is established for the treatment of rheumatoid arthritis. This systematic review of the literature since 2006 summarizes evidence for the use of RTX in the treatment of additional rheumatological diseases: antineutrophil cytoplasmic autoantibody-associated vasculitis (AAV), hepatitis C virus-related cryoglobulinemic vasculitis, Henoch–Schönlein purpura, ankylosing spondylitis, and Raynaud’s phenomenon. Data from randomized controlled trials are available only for AAV, confirming efficacy for remission induction, including in disease resistant to conventional treatment, and maintenance of remission. Further studies are required to confirm optimal maintenance regimens in AAV, important questions needing to be addressed including protocol administration versus treatment in response to clinical relapse and the importance of maintaining B-cell depletion. Sufficient data are available in other diseases to suggest RTX to be useful and that randomized controlled trials should be conducted.

Keywords: anti-CD20 monoclonal antibody, anti-neutrophil cytoplasmic antibody (ANCA)-associated vasculitis, refractory ankylosing spondylitis, resistant cryoglobulinemic vasculitis, refractory rheumatological diseases

Introduction

Antineutrophil cytoplasmic autoantibody (ANCA)-associated vasculitis (AAV), hepatitis C virus (HCV)-related cryoglobulinemic vasculitis (HCVrCV), Henoch–Schönlein purpura (HSP), ankylosing spondylitis (AS), and Raynaud’s phenomenon (RP) are all inflammatory conditions that may present challenges in management, due to failure/intolerance of or contraindications to first-line treatment.

The introduction of cyclophosphamide (CYC) for induction of AAV remission improved remission rates to >90% and reduced mortality dramatically.^{1–3} CYC-, azathioprine (AZA)-, and glucocorticoid (GC)-based regimens have become standard treatment for AAV. However, nearly half of patients relapse using such regimens.^{4,5} Similarly, HCVrCV, HSP, and RP commonly present with severe refractory exacerbations that require one or more cytotoxic medications to control disease activity, with significant associated side effects.

Correspondence: Hani Almoallim
Rheumatic Diseases, Umm Al-Qura
University, Mecca, Saudi Arabia
Tel +966 50 570 3935
Email hani.almoallim@gmail.com

Rituximab (RTX) is a cytotoxic monoclonal antibody that depletes B cells following binding to the B-cell-specific CD20 molecule. This reduces both antibody production and presentation of T-cell epitopes to class II major histocompatibility complex (MHC)-restricted T-helper (T_H) lymphocytes, inhibiting humoral and T_H -cell-dependent autoimmune responses. However, additional mechanisms of action have been suggested.⁶ RTX has proven efficacy in the treatment of non-Hodgkin's lymphoma, chronic lymphocytic leukemia, and rheumatoid arthritis (RA).^{7,8} RTX may have a role in the management of a wide range of chronic inflammatory conditions, in which effects on disease progression are suggested when other treatment modalities fail or are contraindicated, and it may have a role in the management of relapses.⁹⁻¹¹ This systematic review addresses the use of RTX in AAV, HCVrCV, HSP, AS, and RP.

Materials and methods

Search strategy

The Medline (using PubMed), Ovid, EBSCO, Scopus, CINAHL, Trip, and Google Scholar databases were searched in October 2016, restricted to studies published in the English language. Search terms used were rituximab, treatment, remission, update, refractory, relapsing, failure, severe, AAV, AS, HCVrCV, HSP, and RP. References cited in studies identified were also retrieved, and clinical experts were consulted to identify any additional studies.

Eligibility criteria

Inclusion criteria were: patients with AAV, HCVrCV, AS, HSP, or RP; RTX as the intervention being studied; outcomes

of treatment described clearly; randomized controlled trial, cohort study, case series, case report, or systematic review; articles published from 2006 to 2016 (inclusive); and studies published in the English language. Articles related to HCVrCV associated with "other" viral infections (eg, HIV or HBV) were excluded. Patients with destructive AS or who received nonsteroidal anti-inflammatory drugs (NSAIDs) at the time of the study were also excluded. Study characteristics, including RTX-treatment regimens, are summarized in Table 1.

Screening and data extraction

Two independent reviewers screened retrieved reports by review of titles and abstracts. The full texts of potentially relevant reports were retrieved for detailed review. After the second screening, the reviewers considered additional references cited in the retrieved studies. Once a complete list of included studies had been established, the reviewers extracted study-level characteristics (authors, year of publication, geographical location, and number of patients), patient-level characteristics (type of condition, previous treatment, age, sex ratio, number of relapsed cases, duration of relapse, possible factors leading to relapse), intervention/exposure-level characteristics (regimen, dose, duration), and outcome-level characteristics (response, adverse events, and reported side effects).

Rituximab in other rheumatological diseases

Additional rheumatological diseases that RTX may have shown efficacy against include rheumatological diseases resistant to known therapies, primary Sjögren's syndrome,

Table 1 Summary of publications describing use of RTX in vasculitides

Study	Design	Patients (n)	RTX treatment regimen
ANCA-associated vasculitis			
Brodowska-Kania et al ⁴¹	CR	1	I: RTX 1 g ×2, 2 weeks apart
Awad et al ³⁵	CR	1	I: RTX 1 g ×2, 2 weeks apart M: RTX 500 mg ×2 weekly
Wendt et al ²⁷	CS	16	I: RTX 375 mg/m ² /week ×4 (n=5), 1 g ×2, 2 weeks apart (n=6), 500 mg ×2, 2 weeks apart (n=5)
Lovric et al ²⁹	CS	15	I: 375 mg/m ² /week ×4
Rhee et al ³¹	Ret	39	M: 1 g 4-monthly for 2 years
Roubaud-Baudron et al ³²	Ret	28	M: 375 mg/m ² 6-monthly (n=13), 1 g biannually (n=4), 1 g every 12 months (n=3), other regimens (n=8); average infusions: 4 (2-10)
Smith et al ³⁴	Ret	73	I: 375mg/m ² /week ×4 or 1 g ×2 M: RTX only in response to relapses (n=28), RTX regularly 1 g 6-monthly for 2 years postinduction (n=45), or RTX regularly 1 g 6-monthly for 2 years initiated at relapse; cumulative dose in patients treated regularly: 6 (2-11) g
Cartin-Ceba et al ³⁰	Ret	53	I: 375 mg/m ² /week ×4 M: 375 mg/m ² /week ×4 or 1 g every 2 weeks ×2

(Continued)

Table 1 (Continued)

Study	Design	Patients (n)	RTX treatment regimen
Besada et al ⁴⁰	Ret	35	I: 1 g ×2 M: RTX 2 g annually
Calich et al ³⁷	Ret	66	I: 375 mg/m ² /week ×4 or 1 g ×2 M: 500 mg every 6 months ×1.5 years
Pendergraft et al ³⁹	Ret	172	M: 1 g every 3–4 months
Charles et al ³⁸	Ret	80	I: 375 mg/m ² /week ×4 or 1 g ×2, 2 weeks apart M: 375 mg/m ² every 6 months (26%), 500 mg every 6 months (14%), 1 g every 6 months (11%)
Moog et al ³⁶	Ret	17	I: RTX 375 mg/m ² ×1 M: RTX 375 mg/m ² ×1 every 6–9 months (if rising antibody titers or B-cell return)
Alberici et al ⁸⁰	Ret	69	I: 375 mg/m ² /week ×4 or 1 g ×2, 2 weeks apart M: 1 g every 6 months for 24 months
Nagafuchi et al ²⁶	POL	7	I: RTX 375 mg/m ² /week ×4 weeks
Stone et al, ¹¹ Specks et al ¹⁰ (RAVE)	RCT	197	I: RTX 375 mg/m ² /week ×4 or CYC 2 mg/kg/per day orally
Jones et al ^{19,23} (RITUXVAS)	RCT	44	I: randomized 3:1 to GC plus either RTX (375 mg/m ² /week ×4) with two intravenous CYC pulses (n=33, rituximab group), or intravenous CYC for 3–6 months followed by AZA (n=11, control group)
Guillevin et al ³³ (MAINRITSAN)	RCT	118	I: CYC + GC M: RTX 500 mg days 0 and 14 and months 6, 12, and 18 or AZA (daily orally) until month 22
de Menthon et al ²⁸	RCT	17	I: 375 mg/m ² /week ×4 v infliximab M: 375 mg/m ² /week at months 4, 8, and 12
Specific tissue involvement in AAV			
Necrotising scleritis			
Recillas-Gispert et al ²¹	Ret	8 (12 eyes)	I: RTX 1 g ×2, 2 weeks apart
Pulmonary nodules			
Henderson et al ²⁰	CS	5	RTX 1 g ×2, 2 weeks apart
Eosinophilic granulomatosis with polyangiitis			
Umezawa et al ⁴²	CR	1	I: 375 mg/m ² /week ×4
Thiel et al ⁴³	Ret	9	I: RTX 1 g ×2, 2 weeks apart
Mohammad et al ⁴⁴	Ret	41	I: 375 mg/m ² /week ×4 or 1 g ×2, 2 weeks apart M: 375 mg/m ² /week ×4 (3), 1 g ×2, 2 weeks apart (2), 1 g ×1 (16), 600 mg ×1 (1)
Henoch–Schönlein purpura			
Pillebout et al ⁴⁶	CR	1	RTX 1 g ×2, 2 weeks apart
Donnithorne et al ⁴⁷	CS	3	RTX 1 g ×2, 2 weeks apart (n=1), 375 mg/m ² /week ×4 (n=2, repeated for relapse in one patient)
HCV-related vasculitis			
Lamprecht et al ⁵⁷	CR	1	RTX 500 mg every 3 weeks ×6
Petrarca et al ⁵⁶	CS	19	RTX 375 mg/m ² /week ×4
Visentini et al ⁵⁵	CS	6	RTX 250 mg/m ² ×2
Saadoun et al ⁵⁰	PC	16	RTX 375 mg/m ² on days 1, 8, 15, and 22 over a period of 1 month + PEG-IFNα + ribavirin
Terrier et al ⁵²	PC	32	RTX 375 mg/m ² on days 1, 8, 15, and 22 or 1,000 mg on days 1 and 15 + PEG-IFNα + ribavirin (n=20) vs RTX 375 mg/m ² on days 1, 8, 15, and 22 or 1,000 mg on days 1 and 15 (n=12)
Saadoun et al ⁴⁹	PC	95	RTX 375 mg/m ² on days 1, 8, 15, and 22 over 1 month + PEG-IFNα + ribavirin (n=40) versus PEG-IFNα + ribavirin (n=55)
Visentini et al ⁵⁴	PC	27	RTX 250 mg/m ² ×2
Dammacco et al ⁵³	PR	41	RTX (375 mg/m ²) once a week for 1 month followed by two 5-monthly infusions + PEG-IFNα + ribavirin (n=22) versus PEG-IFNα + ribavirin (n=19)
De Vita et al ⁵¹	PR	57	RTX 1 g on days 0 and 14 vs conventional therapy (GC, n=17; PE, n=5; CYC, n=4; AZA, n=3); note four of 57 not associated with HCV
Sneller et al ⁹	RCT	24	RTX 375 mg/m ² on days 1, 8, 15, and 22 vs conventional therapy

Abbreviations: AAV, ANCA-associated vasculitis; ANCA, antineutrophil cytoplasmic autoantibody; AZA, azathioprine; CR, case report; CS, case series; CYC, cyclophosphamide; GC, glucocorticoid; HCV, hepatitis C virus; I, induction; M, maintenance; POL, prospective open-label; PC, prospective cohort; PEG, polyethylene glycol; PR, prospective randomized; RCT, randomized controlled trial; Ret, retrospective cohort study; RTX, rituximab.

scleroderma with myositis, and Behçet's disease. The authors believe that many of these review areas merit separate research. To this extent, the authors are conducting a systematic review and meta-analysis of RTX in resistant lupus cases, as well as another separate analysis of RTX in scleroderma with myositis along with Behçet's disease, and the authors believe that no new evidence has emerged since a review was conducted in 2017 on the safety of biological disease-modifying antirheumatic drugs modulating B cells in primary Sjögren's syndrome.¹²

Assessment of the quality of included studies

Reviewers documented the type of study, the journal, whether data collection was prospective, sequential patient enrolment, the selected intervention, and the duration of follow-up. Assessors were blinded to study author, journal, publication date, and main results. Each study was assessed for overall quality, comprehensiveness, and possible sources of bias. Independent adjudication resolved disagreements.

Statistical analysis

A narrative systematic review was prepared. Meta-analysis was not undertaken, due to heterogeneity in the design and populations of included studies.

Results

Description of included studies

A total of 875 reports were retrieved from the literature search, manual search of cited references, and suggestions by clinical experts. After the first screening process, a total of 145 studies were deemed potentially relevant. Of these, 50 publications were included in this systematic review. There were 21 studies recruiting patients with AAV (including two long-term follow-up studies of patients previously reported)^{10,19} and two additional studies reporting organ-specific outcomes in AAV.^{20,21} Three additional studies reported use of RTX in eosinophilic granulomatosis with polyangiitis (EGPA), and two reported use in HSP. We identified ten studies describing RTX use in HCVrCV, seven in AS, and four in RP. A Cochrane review of treatment of AAV published in 2015⁴ was also considered. A flowchart describing study selection is shown in Figure 1. Study design for selected studies is documented in Tables 1 and 2.

ANCA-associated vasculitis

Between 2001 and 2006, there were a number of case reports and case series and three prospective open-label studies

suggesting RTX to be effective in induction of remission in AAV (predominantly AAV with granuloma formation). These cases were largely patients with treatment failure on conventional treatment, and the open-label studies reported conflicting results.²² However, RTX was suggested to be effective in the treatment of AAV. The published literature since these initial studies has been reviewed, seeking clarity with regard to the efficacy of RTX in AAV, in particular given the publication of results from three prospective randomized controlled trials. We identified 22 articles addressing the role of RTX in three different clinical settings: the induction of remission, the maintenance of remission, and the use of RTX for induction and maintenance of remission in the same patient, including one Cochrane review. Two of these articles described long-term follow-up of patients already described and subgroup analyses of these studies. Two additional studies described the effect of RTX treatment on specific manifestations of AAV (scleritis and pulmonary granulomatous disease). Three articles were identified describing the use of RTX for treatment of EGPA. Finally, one case series and one case report described the use of RTX in four patients with HSP.

These publications described RTX use for de novo induction of remission and as "rescue therapy" in patients in whom conventional treatment had failed to induce remission or in whom relapse was seen. RTX was also used in small numbers of patients in whom conventional therapy (most often CYC) was contraindicated. Overall, RTX was shown to be effective in all settings in AAV. These studies and the RTX regimens used are summarized in Table 1.

Induction

The RAVE¹¹ and RITUXVAS^{19,23} studies demonstrated the efficacy of RTX in remission induction in AAV.⁴ RAVE confirmed RTX (375 mg/m² weekly ×4) remission induction to be noninferior to conventional CYC treatment in a multicenter randomized double-blind placebo-controlled study (remission achieved in 64% vs 53%, *P*=0.09). In this study, 48% of RTX and 49% of control patients were newly diagnosed. Of patients treated for relapse, 82% receiving RTX and 74% of controls had previously received CYC. RITUXVAS demonstrated RTX (375 mg/m² weekly ×4) plus two pulses of intravenous CYC not to be superior to conventional 3- to 6-month intravenous CYC for remission induction in AAV, with outcomes as good following RTX induction through to 2 years' follow-up.¹⁹ In contrast to the RAVE study, all patients in this study were newly diagnosed, and all had renal involvement. In RAVE, RTX induction was followed by withdrawal of GCs by ~6 months, with

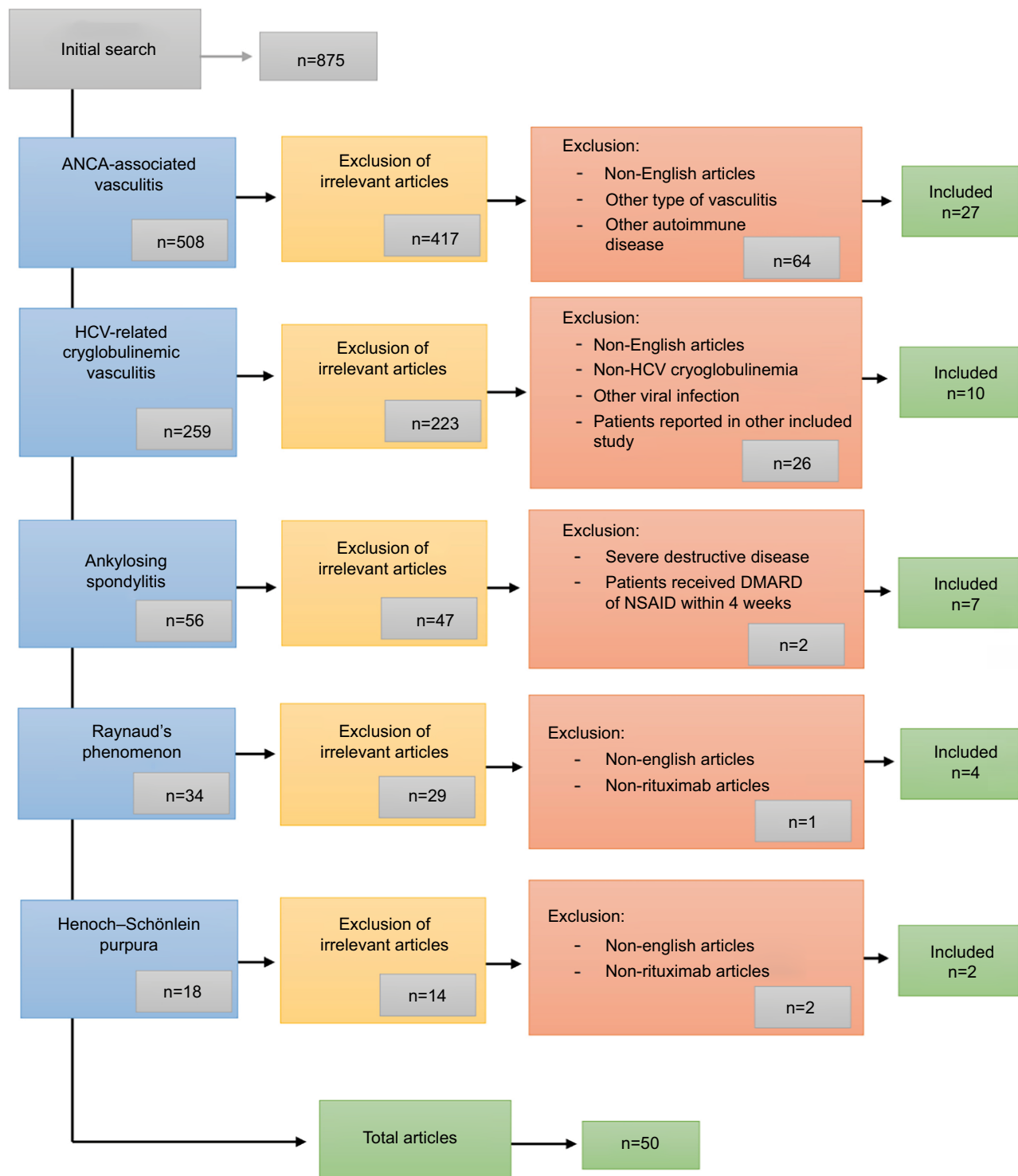


Figure 1 Search strategy and articles excluded and selected.

Abbreviations: ANCA, antineutrophil cytoplasmic autoantibody; DMARD, disease-modifying antirheumatic drug; HCV, hepatitis C virus; NSAID, nonsteroidal anti-inflammatory drug.

no additional maintenance immunosuppression. This was central to study design.^{10,11,24}

In RITUXVAS, patients receiving RTX (plus two doses of CYC) induction continued with a low-dose GC (5 mg

prednisolone). In RAVE and RITUXVAS control arms, patients received conventional CYC continued with oral AZA maintenance. Subgroup analysis of the RAVE cohort indicated that RTX appeared to be equally effective as CYC

Table 2 Summary of publications describing use of RTX in nonvasculitic musculoskeletal disease

Study	Design	Patients (n)	RTX treatment regimen
Ankylosing spondylitis			
Rodríguez-Escalera and Fernández-Nebro ⁶¹	CR	1	I: RTX 1 g ×2, 2 weeks apart + lamivudine for hepatitis B infection
Huang et al ⁶²	CR	1	I: RTX 500 mg ×2, 2 weeks apart (anti-TNF blocker-naïve)
Omair et al ⁶³	CR	1	I: RTX 1 g ×2, 2 weeks apart, repeated 8 months later
Kobak et al ⁶⁰	CR	1	I: RTX 1 g ×2, 2 weeks apart, repeated 6 months later
Aldhaheeri et al ⁶⁴	CR	1	I: 375 mg/m ² /week ×2, 2 weeks apart M: 375 mg/m ² /week ×2 at 6 months and 12 months from induction
Nocturne et al ⁵⁸	CS	8	I: RTX 1 g ×2, 2 weeks apart (only one patient was anti-TNF blocker-naïve)
Song et al ⁵⁹	POL	20	I: RTX 1 g ×2, 2 weeks apart (TNF blocker-naïve vs TNF blocker-treated)
Raynaud's phenomenon			
Rech et al ⁶⁷	CR	1	RTX 375 mg/m ² after each plasma exchange ×9
Dunkley et al ⁶⁶	CR	1	RTX 1 g ×2, 2 weeks apart
Haroon et al ⁶⁵	CR	1	RTX 1 g + iloprost + methylprednisolone + CYC; 2 weeks later, full schedule repeated; two further courses of RTX 1 g + iloprost + methylprednisolone
Shabrawishi et al ⁶⁸	CR	1	RTX 1 g ×2, 2 weeks apart. Second treatment for relapse RTX 375 mg/m ² /week ×4

Abbreviations: CR, case report; CS, case series; CYC, cyclophosphamide; I, induction; M, maintenance; POL, prospective open-label; RTX, rituximab.

in those patients with glomerulonephritis or pulmonary hemorrhage.²⁴ Longer follow-up (18 months) of the RAVE cohort confirmed that the initial single course of RTX was as effective for maintenance of remission as CYC induction plus AZA maintenance.¹⁰ Subgroup analysis demonstrated treatment specifically for renal involvement to be associated with equivalent outcomes in the RTX and CYC arms.²⁵ Comparison of these studies, in addition to differences in induction regimen, shows that RAVE and RITUXVAS recruited different patient groups, with RITUXVAS confined to de novo disease²³ and RAVE including slightly over 50% of patients treated for relapse following “conventional” de novo disease induction.^{4,11}

A number of studies have reported specifically on treatment of refractory disease with RTX. A report of seven Japanese patients with AAV refractory to treatment with CYC demonstrated the induction of remission using RTX in six, with one death.²⁶ These patients did not receive planned maintenance, with relapse being seen in five of the six surviving patients. Wendt et al²⁷ similarly reported good outcomes using RTX for treatment of patients with “difficult” refractory or relapsing disease, although one patient died in this series. Also, de Menthon et al²⁸ reported RTX to be effective at achieving remission in five of eight patients with disease refractory to conventional treatment in a study comparing infliximab and RTX. RTX achieved remission in 14 of 15 patients with refractory disease reported by Lovric et al.²⁹ These authors sounded a note of caution with regard to complications, as one patient died of pneumonia and a further patient experienced reactivation of hepatitis B and died following refusal of dialysis. Subgroup analysis in the

RAVE study confirmed RTX to be as effective in de novo as in refractory/relapsing disease.^{11,24} Cartin-Ceba et al³⁰ reported retrospectively on the use of RTX for induction of remission in a cohort of 53 patients with refractory AAV at the Mayo Clinic. In contrast to conventional findings, this group reported increasing PR3 titers to be predictive of relapse, suggesting this to be an indication for retreatment. Furthermore, they only saw relapse following return of peripheral blood B cells.

Maintenance

The efficacy of RTX for maintenance has also been studied. In keeping with the report from the Mayo Clinic,³⁰ the RITUXVAS study team commented that relapses seen following RTX induction all occurred in patients in whom B-cell recovery had occurred.¹⁹ Numbers were small (n=2), and as 85% of patients had B-cell recovery by study end, this may not be a significant observation. However, given that relapse is seen in ~20% of patients receiving both conventional immunosuppressive regimens and RTX induction regimens for AAV, investigation of optimal maintenance therapy is of interest. Many of the studies reporting use of RTX for induction also comment on treatment of relapses. A number of studies have focused specifically on maintenance treatment. Rhee et al³¹ reported successful use of RTX for maintenance of remission in 39 patients with AAV (1 g 4-monthly in 33 of 39 patients, minor variations to dosing in remaining six) in a retrospective study. Roubaud-Baudron et al³² reported retrospectively specifically on the efficacy of a variety of RTX maintenance regimens (Table 1) in AAV (GPA, n=24; microscopic PA, n=4). A total of 21 of these patients had

received RTX for initial disease treatment also and received RTX maintenance as part of a continuing RTX treatment protocol. Six of the remaining seven patients received RTX maintenance due to intolerance or lack of efficacy of AZA/mycophenolate mofetil regimens, and one received RTX maintenance due to renal insufficiency. Of 28 patients, 17 maintained complete remission and 11 partial remission at a median follow-up of 38 months. Of the 17 patients achieving complete remission, 11 had irreversible organ damage, including 6 with end-stage renal disease.

The MAINRITSAN study subsequently confirmed RTX to be superior to AZA for maintenance of remission in AAV.³³ In this randomized, unblinded, controlled trial, 118 patients received either AZA or RTX after remission induction with CYC and GC. Major relapse occurred in 29% of patients in the AZA group compared with 5% in the RTX group. The frequency of severe adverse events was similar in the two groups. Smith et al³⁴ compared three different RTX maintenance regimens in a retrospective cohort study recruiting 73 patients. Group A received induction followed by RTX treatment only in response to relapses. Following induction of remission, group B were given planned maintenance RTX every 6 months. Group C included relapsed patients who were then given regular maintenance treatment. Complete/partial remission occurred in 93% of group A, 96% of group B, and 95% of group C. Relapse rates after 2 years of treatment were 73%, 12%, and 11% in each group, respectively, and at last follow-up (median 44 months) relapse rates were 85%, 26%, and 56%, respectively, for the three groups.

Induction and maintenance

With demonstrated efficacy of RTX at induction of remission and superiority compared to AZA in remission maintenance in patients receiving conventional CYC-based induction, the remaining question is whether RTX used for induction and maintenance in the same patient is superior to either of these two strategies. Awad et al reported successful use of RTX for induction and maintenance of remission in a 57-year-old female patient.³⁵ Further retrospective studies reported outcomes in 17³⁶ and 66³⁷ patients, demonstrating RTX to be effective and safe for use in both remission induction and maintenance therapy in GPA. In the first study, Moog et al³⁶ administered relatively low-dose RTX (375 mg/m²) for induction and maintenance. In the second study,³⁷ 59 of the patients reported had received previous CYC. The maintenance dose of RTX was relatively low in this study also (500 mg every 6 months). At the 18-month follow-up, the incidence of severe infections was 13.6%. In a multicenter retrospective study

of RTX treatment for AAV, low-dose RTX was shown to induce and maintain remission effectively, with a significantly lower relapse rate than conventional treatment.³⁸ This study sounded a note of caution also with regard to complication rates, with 22 documented side effects (predominantly infectious) and 4 deaths. A long-term follow-up of 69 patients who received repeated RTX as maintenance therapy following RTX induction supported the efficacy and safety of a fixed-interval regimen. A total of 67 of these patients were failing other therapies. Patients received maintenance for 2 years, with 29 patients relapsing a median of 34 months after the last RTX infusion and 9% of patients needing additional immunosuppression.³⁷ A single-center retrospective analysis of 172 patients with AAV who underwent RTX induction and maintenance therapy demonstrated major relapse in only 5%, associated with weaning of additional immunosuppressive agents.³⁹ This was significantly lower than the 20% remission reported using conventional CYC- and AZA-based regimens or RTX induction, and is equivalent to the 5% relapse reported with RTX use for maintenance following CYC remission induction in the MAINRITSAN study.³³ Pendergraft et al³⁹ administered higher doses of RTX with routine 4-monthly 1 g maintenance doses for up to 7 years, specifically aiming to maintain B-cell depletion throughout, in part addressing the comment in the RITUXVAS study that B-cell return was associated with relapse. The dose interval was shortened to 3 months if B-cell return was seen. A total of 25 serious infections were reported, and 17 patients developed late-onset neutropenia, 13 requiring treatment with granulocyte colony-stimulating factor. Neutropenia recovered, and RTX was continued in all patients.

A report of complication rates in 35 patients receiving RTX induction and maintenance for a median of 44 months (2–88 months) is of note.⁴⁰ Following induction with RTX 1 g \times 2 2 weeks apart, further maintenance doses of 2 g were given annually: 37% of patients discontinued RTX, mainly due to hypogammaglobulinemia, and 26% of patients developed a severe infection.⁴⁰ A high dose of concomitant CYC treatment was suggested to be a significant risk factor for severe infection. This study used higher doses of RTX than other studies already discussed, where regular maintenance doses were administered.

Considering specific organ involvement, as discussed, the RAVE and RITUXVAS studies confirmed RTX to be effective in patients with renal disease.^{11,19,23} In a retrospective analysis of eight patients, RTX (1 g \times 2 2 weeks apart) was useful in the treatment of refractory necrotizing scleritis in patients with GPA.²¹ A case report of a patient with AAV of

high disease activity demonstrated the efficacy of RTX in lung disorders, but no significant remission of granulomatous infiltration in the orbits was seen.⁴¹ The Japanese study already referred to²⁶ demonstrated resolution of granulomatous orbital involvement in one patient. A further report of five cases of GPA with persistent pulmonary lesions²⁰ demonstrated RTX to be effective at improving radiological appearances of pulmonary disease. These authors reported readministration of RTX if necessary to maintain B-cell depletion up to 18 months' follow-up.

RTX has also been used successfully for treatment of EGPA refractory to GC, CYC, and intravenous Ig.⁴² A retrospective study of nine patients treated with RTX for relapsing or refractory disease further suggested the efficacy in EGPA.⁴³ Mohammad et al reported retrospectively on 41 patients (36 with relapsing or refractory disease and five with new presentations) from four centers treated effectively with RTX.⁴⁴

HSP is a further clinical variant of small-vessel vasculitis, in which RTX has been suggested to be effective. The vast majority of patients with HSP recover spontaneously, but about a third have recurrent disease episodes.⁴⁵ The recurrence rate is higher in those with severe disease and renal involvement. Conventional treatment for recurrent disease is GCs and CYC.⁴⁶ RTX has been noted to be a successful treatment for severe refractory chronic HSP in three pediatric patients. All three patients responded to one or two courses of RTX, with no serious adverse events reported.⁴⁷ RTX has also been used successfully as de novo treatment in an adult with HSP with renal involvement (Table 1).⁴⁸

HCV-related cryoglobulinemic vasculitis

Ten publications describing RTX for treatment of HCVrCV were identified, describing treatment of 294 patients (Table 2). One publication described a larger study⁴⁹ incorporating data from 16 patients described previously.⁵⁰ A total of 97 patients received RTX only, 110 patients received RTX in combination with other drugs, and 87 patients received either control or conventional treatment.

Sneller et al⁹ randomized 24 patients with HCVrCV in whom antiviral therapy had failed to receive RTX versus "best available therapy". Ten of 12 (83.3%) patients who received RTX achieved remission at 6 months compared to one of 12 in the control group. Of the remaining two patients, one withdrew from the study at month 5 because of a severe febrile illness and the other achieved remission at month 4, then relapsed at month 6. After 6 months of follow-up, six of ten patients in whom remission was achieved were still in remission, while three of the remaining four patients

experienced relapse and were treated with a second course of RTX. These patients achieved and remained in remission for more than 6 months after the second course. One patient was lost to follow-up at month 7.

In a similar study, De Vita et al⁵¹ randomized 59 patients with CV to receive RTX versus conventional treatment, data on 57 patients being available for analysis. Although HCV infection was not an inclusion criterion, 53 of 57 patients had HCV infection, in keeping with our understanding of CV. This study primarily showed good compliance with RTX treatment, confirming also noninferiority of RTX.

RTX has been shown to be more effective when combined with antiviral drugs. Terrier et al⁵² demonstrated 80% complete remission of HCVrCV with RTX combined with polyethylene glycol (PEG)-IFN α and ribavirin compared to 57% complete remission with RTX alone. Dammacco et al⁵³ compared PEGylated IFN α + ribavirin + RTX (n=22) with PEGylated IFN α + ribavirin (n=15). In the group receiving RTX, 54.5% achieved a complete response compared to 33.3% in PEG-IFN α + ribavirin group. Five patients from the RTX group (22.7%) and five from the PEG-IFN α + ribavirin group (33.3%) achieved a partial response.⁵³ Two separate prospective studies by the same group reported complete responses to RTX treatment in 13 patients at six months with two partial responders and four patients relapsing,⁵⁴ and in the second publication, complete clinical response was achieved in four of five patients (80%).⁵⁵

RTX has also been shown to have a useful therapeutic effect in patients with liver cirrhosis due to HCV infection. Petrarca et al⁵⁶ reported two cases of HCVrCV with liver cirrhosis. Both cases had increased portal vein diameter on ultrasound, splenomegaly, and ascites. After RTX infusion, both patients experienced improvement in their symptoms. At the end of follow-up, their portal vein diameter had improved, close to normal, with reduction in maximum longitudinal spleen diameter, no ascites in the first case, and persistence of a very small amount of ascites in the second case. Finally, RTX in combination with PEGylated IFN α has been demonstrated to induce remission of HCVrCV in a patient with non-Hodgkin's lymphoma following failure of conventional treatment.⁵⁷

Ankylosing spondylitis

Seven publications reported use of RTX in the management of AS: five case reports, one case series, and one open-label trial (Table 2). Nocturne et al⁵⁸ reported data from the French autoimmunity and RTX registry on outcomes in ten patients with spondyloarthritis treated with RTX. Two were

excluded because of concomitant infliximab treatment in one and treatment for vasculitis with no effect on concomitant AS in the other. Of the remaining eight patients, three had AS, two had undifferentiated spondyloarthritides, and three had psoriatic arthritis. Seven of the eight patients had previously received anti-TNF treatment. All received RTX 1 g \times 2 2 weeks apart. Five patients also received methotrexate. Clinicians reported a response to RTX in only two of these patients. A further open-label study reported greater efficacy of RTX.⁵⁹ In this study, 20 patients received RTX (1 g \times 2 2 weeks apart), ten of whom were anti-TNF-naïve. All patients had active disease, as defined by a Bath Ankylosing Spondylitis Disease Activity Index (BASDAI) score \geq 4, with response defined as a 20% reduction in disease activity. No patients had received immunosuppression within 4 weeks of RTX administration. A clinical response to RTX occurred as early as 4–8 weeks after the first RTX infusion; 90% of the naïve group responded to treatment. In contrast, at best only a partial response was seen in 30% of the group that had failed anti-TNF treatment.

The five case reports supported the efficacy of RTX in AS. The commonest regimen used was 1 g \times 2 2 weeks apart. Kobak et al reported this regimen to achieve a partial response in a patient who had failed with disease-modifying antirheumatic drugs and anti-TNF treatment, as evidenced by improvement in acute-phase reactants and magnetic resonance imaging. No BASDAI score was recorded.⁶⁰ A further case report documented a 28-year-old female HBV-positive patient with AS and peripheral arthritis who responded to RTX. She had failed on NSAID and methotrexate treatment and refused anti-TNF treatment, fearing TB reactivation. Lamivudine was given with RTX. There was a dramatic improvement in her arthritis, without reactivation of her HBV infection.⁶¹ A further case of axial AS that had failed to improve with NSAID improved significantly with RTX, with resolution of sacroiliac joint edema.⁶² A lower RTX dose (500 mg \times 2) was used to treat this patient. Finally, a case of AS complicated by demyelinating disease due to anti-TNF therapy showed partial improvement after RTX administration, with resolution of neurological symptoms (Table 2).⁶³

A further case report⁶⁴ documented a 38-year-old male patient with AS who initially responded to infliximab and was then given etanercept in response to a disease flare. He subsequently developed papillary thyroid cancer treated with thyroidectomy and radioiodine. RTX was given for a further disease flare not responsive to sulfasalazine and an NSAID, with good response (BASDAI score improved from 7.1 to 2.3).

Raynaud's phenomenon

Four cases of use of RTX in RP have been reported (Table 2). All patients were female and had mixed connective-tissue disease (MCTD). Three of four responded to RTX after having failed on a first-line immunosuppressant. In the first case, there were very high titers of ribonucleoprotein antibody that became negative after treatment, correlating with clinical improvement.⁶⁵ In the second case also, there was severe RP due to MCTD that started to fail to respond to regular immunosuppressive treatment. The patient began to improve after plasmapheresis with intravenous Ig, but there was complete remission after RTX administration. The patient was followed up for 1 year with no relapse.⁶⁶ A third case of RP with MCTD and high titers of ANA received immunosuppression and iloprost infusion, but achieved further significant clinical improvement following RTX. This patient relapsed after 10 months, despite further depletion of B cells at 2- and 6-month intervals.⁶⁷ The fourth case⁶⁸ suffered from primary RP and had responded poorly to aspirin, nifedipine, sildenafil, GC, intravenous heparin, and intravenous iloprost. RTX resulted in an excellent clinical response. Four and a half years after initial treatment, the patient experienced a relapse, which again responded to RTX.

Discussion

Most patients with autoimmune musculoskeletal disease require immunosuppression and/or anti-TNF treatment to control disease activity and slow progression, with a wide range of adverse effects. It is thus important to address the role of alternative medication that has efficacy against these diseases, in particular if alternatives are associated with a safer side-effect profile and can be used in cases where conventional immunosuppression is contraindicated. RTX is suggested to have such benefits. RTX is an established treatment for RA. For other rheumatological diseases, its use is best supported in AAV. The earliest clinical evidence supporting RTX use in AAV came from a case study in 2001,⁶⁹ in which a 66-year-old man with GPA developed severe CYC-induced bone-marrow toxicity. He was thus treated with a combination of GC and RTX. After four doses of RTX, he experienced clinical remission, allowing discontinuation of GC. RTX alone was later used to treat a relapse in the same patient, thus fulfilling the requirement of efficacy with reduced side-effect profile, introducing a new line of treatment for AAV.

RTX is now established as an effective alternative to standard CYC-based treatment in induction of remission of AAV, with RCT evidence supporting use of 375 mg/m² weekly \times 4, but there is evidence for 1 g \times 2 2 weeks apart, as

used in RA, to be effective also (Table 1). RTX is effective in remission induction in both de novo disease and following relapse. Cases refractory to conventional treatment may respond to RTX.

The strongest evidence for remission maintenance in AAV with RTX comes from the MAINRITSAN study using 500 mg 6-monthly to month 18 (Table 1). However, uncertainty remains with regard to the optimal dose, dosing regimen, and whether long-term maintenance is needed. The role of sustained B-cell depletion also remains to be clarified. Importantly, the main benefit of RTX would seem to be avoidance of toxicity, and if prolonged B-cell depletion is needed to maintain remission, then the role of RTX in maintenance of long-term remission will need to be studied carefully in appropriately powered RCTs specifically balancing efficacy against adverse events.

RTX has also been shown to be useful in two other vasculitic diseases: EGPA and HCVrCV. In EGPA, RTX 375 mg/m² weekly \times 4 and 1 g \times 2 weeks apart have been suggested to be effective. Although no RCTs are available, the efficacy in AAV suggests that the evidence of efficacy in EGPA (from more limited reports) is probably reliable. The use of RTX in HCVrCV is of particular interest. A dosing regimen of 1 g \times 2 weeks apart has typically been used in this setting. Importantly, even when used alone, RTX is effective and not associated with exacerbations of viral infection. However, combination therapy of RTX with antiviral therapy would seem to be optimal and is associated with better outcomes than monotherapy with antiviral agents. Two case reports have demonstrated reduction in portal vein diameter and reduction in maximum longitudinal spleen size in patients with associated liver cirrhosis.⁵⁶

RTX also shows efficacy in anti-TNF-naïve patients with AS. The suggestion of a better response to RTX in anti-TNF α -naïve patients is of interest.⁶⁴ However, care must be taken in interpreting these data, due to the potential for selection bias. In general, patients who receive RTX having received anti-TNF treatment have failed the anti-TNF treatment. It is thus possible that the better response in anti-TNF-naïve patients is because those who have failed anti-TNF treatment are a selected population enriched with patients with more “difficult” disease. A report of a patient who had responded to anti-TNF treatment, but in whom RTX was chosen for further treatment due to the development of cancer is of interest. A good response to RTX was seen, despite this patient having received anti-TNF treatment. Therefore, anti-TNF-naïve versus anti-TNF-treated may not be the important discriminator, anti-TNF responder versus

nonresponder perhaps better defining those who will and those who will not subsequently respond to RTX.

There were insufficient data in primary RP to give a conclusive result. However, a significant reduction in autoantibody titer was reported in patients who responded clinically to RTX with an increase in antibody titers in relapse. The report of a patient with primary RP responding to RTX⁶⁸ is of interest, although the authors noted a number of risk factors for progression to secondary RP, making long-term follow-up necessary to confirm that this is a case of primary RP.

Mechanisms of action and predictors of response

RTX binds CD20, depleting B lymphocytes, thus most obviously having an effect on antibody production. However, B lymphocytes have multiple roles in immunoresponses,⁷⁰ including a role as antigen-presenting cells, priming class II MHC-restricted CD4⁺ T_H lymphocytes, in particular at low antigen levels.⁷¹ These cells in turn are essential in CD8⁺ T-cell and macrophage-mediated (delayed-type hypersensitivity) autoimmune diseases. In the context of AAV, the relative contribution of cellular versus humoral responses in disease pathogenesis continues to be debated. However, RTX would impact on both arms of the immunoresponse through direct B-cell depletion and as a consequence an indirect effect on antigen presentation to T cells. Similar considerations may be relevant in EGPA, HCVrCV, and HSP. AS is a disease in which no role has been demonstrated for antibodies, it being mainly an inflammatory process due to CD4⁺ and CD8⁺ T lymphocytes and macrophages. Based on histopathological studies, CD3⁺ T cells (both CD4⁺ and CD8⁺), as well as CD20⁺ B cells, are seen to infiltrate cartilage and subchondral bone.⁷² Interestingly, the number of infiltrating B cells was higher than that of infiltrating T cells.^{73,74} Therefore, the efficacy of RTX in this disease is understandable, due to its impact on T-cell priming. Inflammatory cytokines also play an important role in immunomediated disease.⁶¹ RTX has also been shown to reduce the production of proinflammatory cytokines significantly, including TNF α , IL1, and IL6.⁷⁵

In further consideration of the role of B-cell depletion in the efficacy of RTX, whatever the role of B cells in the disease process, a number of studies have demonstrated differential depletion of B cells in different B-cell compartments. Peripheral blood B cells are very effectively depleted by RTX, as are synovial infiltrates in RA. However, depletion of germinal center B cells is less effective. It is not clear whether this is due to pharmacokinetic or biological reasons. However, immunosuppressive monoclonal antibodies (anti-MHC class

II, anti-CD4, anti-CD52) penetrate germinal centers poorly in animal models (Richard Smith, personal communication), supporting a pharmacokinetic explanation.

The median half-life of RTX after completion of the first infusion is about 21 days. The infusion can be repeated after 6–12 months if the patient relapses.⁷⁰ Minimal data from uncontrolled trials, particularly in RA, show that the clinical effect of RTX is first evident 4–8 weeks after infusion and lasts longer than 1 month.^{76,77} Differences in the reported response to RTX may be due to differences in concomitant GC administration.^{78,79}

RTX is effective in AAV, as reported herein. In a large European cohort with relapsing–refractory AAV, RTX was an effective treatment. Favorable prognostic factors in this cohort included kidney involvement, age >50 years, and achievement of negative ANCA following 6 months of treatment.⁸⁰ In HCVrCV, the combination of RTX with antiviral treatment (PEGylated IFN/ribavirin) was associated with better outcomes than the use of RTX alone.⁵⁰ In AS it is of note that TNF α blocker-naïve patients respond better than patients who have failed with anti-TNF therapy. The reason for this is not clear. A lack of response to anti-TNF may mark a subgroup of patients who for whatever reason are destined to respond poorly to RTX.

In RP associated with MCTD and high titers of RNP, RTX treatment was successful in patients with negative ANA, but failed in those who had positive ANA.⁶⁶ Some cases relapsed after weaning of other immunosuppressive agents.³⁹ Penetration of RTX into affected tissues might also play a role, as there was a case report⁴¹ showing dramatic improvement in lung symptoms, but limited improvement in orbital manifestations of disease.

Adverse reactions

RTX has been shown to be effective, with a good margin of safety in many rheumatological diseases. However, it should be noted that its safety is not yet definitively established, in particular in AAV, because of the relatively short follow-up of patients so far. Discontinuation of RTX due to toxicity has been reported. Adverse effects associated with RTX use include infusion reactions, hypogammaglobulinemia, especially after repeated courses, infections, reactivation of HBV, and late-onset neutropenia, which may manifest months after therapy and is mostly asymptomatic and reversible. In patients with AAV, infections are a major cause of morbidity and mortality, particularly during remission induction, when the most intensive immunosuppressive regimens are

administered. It is likely that total immunosuppressive exposure is an important determinant of infection risk.

In AS, HBV reactivation has been reported following treatment with RTX, despite the administration of lamivudine. No hepatocyte damage was observed in this case. Upper respiratory tract infection and allergic reactions have also been reported in AS following RTX treatment, although no serious events were attributed to RTX.⁵⁹ Clear guidelines that minimize the use of immunosuppression may minimize toxicities. In patients who are HBV- or HCV-positive, concomitant use of antiviral agents is most probably of benefit. Finally, some studies reported hypotension during infusion, it being recommended to infuse RTX slowly and withhold anti-hypertensive medication at the time of RTX administration.⁸¹

Suggested studies

We suggest that further randomized trials are required, in particular: 1) to define clear guidelines for use of RTX in rheumatological disease, including in particular definition of optimal maintenance regimens and whether sustained B-cell depletion is necessary; 2) to address how RTX may be used to minimize the use of anti-TNF therapies and overall immunosuppressive load; and 3) to define more clearly toxicities associated with RTX use.

Limitations of the study

Differences in inclusion and exclusion criteria among studies is a minor limitation of this study. More significant is the quality of the studies identified. Case reports have been included, as they define possible therapeutic uses of RTX. However, definitive studies to address the questions posed by these case reports are largely lacking. We feel that this makes this review particularly relevant as a documentation of these areas of interest and a stimulus to conduct definitive studies.

Also, we have included evidence from low-quality studies with regard to RP. We felt that this was appropriate to report, as higher quality studies are not available. However, this should be recognized as a research gap, and results from these studies should be interpreted with caution.

Conclusion

RTX might be revolutionary in rheumatological disease therapy, but its use is limited by lack of high-quality studies. Efficacy is suggested in AAV, HCVrCV, anti-TNF-naïve AS, and RP, but prospective RCTs have only addressed induction of remission in AAV. In particular, a role replacing conventional immunosuppression due to reduced toxicity is

suggested. However, further studies are needed to address this. Finally, although RTX is an expensive drug, if it reduces remission rates (reducing hospital admissions) and avoids adverse events, it might overall be a cost-effective treatment.

Disclosure

The authors report no conflicts of interest in this work.

References

- Fauci AS, Haynes BF, Katz P, Wolff SM. Wegener's granulomatosis: prospective clinical and therapeutic experience with 85 patients for 21 years. *Ann Intern Med.* 1983;98(1):76–85.
- Fauci AS, Wolff SM. Wegener's granulomatosis: studies in eighteen patients and a review of the literature. *Medicine (Baltimore).* 1973;52(6):535–561.
- Hoffman GS, Kerr GS, Leavitt RY, et al. Wegener granulomatosis: an analysis of 158 patients. *Ann Intern Med.* 1992;116(6):488–498.
- Walters G, Willis NS, Craig JC. Interventions for renal vasculitis in adults. *Cochrane Database Syst Rev.* 2015;(9):CD003232.
- Westman KW, Bygren PG, Olsson H, Ranstam J, Wieslander J. Relapse rate, renal survival, and cancer morbidity in patients with Wegener's granulomatosis or microscopic polyangiitis with renal involvement. *J Am Soc Nephrol.* 1998;9(5):842–852.
- Taylor RP, Lindorfer MA. Drug insight: the mechanism of action of rituximab in autoimmune disease – the immune complex decoy hypothesis. *Nat Clin Pract Rheumatol.* 2007;3(2):86–95.
- Chatzidionysiou K, Lie E, Nasonov E, et al. Effectiveness of two different doses of rituximab for the treatment of rheumatoid arthritis in an international cohort: data from the CERERRA collaboration. *Arthritis Res Ther.* 2016;18:50.
- Randall KL. Rituximab in autoimmune diseases. *Aust Prescr.* 2016;39(4):131–134.
- Sneller MC, Hu Z, Langford CA. A randomized controlled trial of rituximab following failure of antiviral therapy for hepatitis C virus-associated cryoglobulinemic vasculitis. *Arthritis Rheum.* 2012;64(3):835–842.
- Specks U, Merkel PA, Seo P, et al. Efficacy of remission-induction regimens for ANCA-associated vasculitis. *N Engl J Med.* 2013;369(5):417–427.
- Stone JH, Merkel PA, Spiera R, et al. Rituximab versus cyclophosphamide for ANCA-associated vasculitis. *N Engl J Med.* 2010;363(3):221–232.
- Letaief H, Lukas C, Barnetche T, Gaujoux-Viala C, Combe B, Morel J. Efficacy and safety of biological DMARDs modulating B cells in primary Sjögren's syndrome: systematic review and meta-analysis. *Joint Bone Spine.* Epub 2017 Jun 30.
- Innami K, Mukai T, Kodama S, Morita Y. Successful treatment using rituximab in a patient with refractory polymyositis complicated by scleroderma renal crisis. *BMJ Case Rep.* 2017;2017:221205.
- Melsens K, Vandecasteele E, Deschepper E, et al. Two years follow-up of an open-label pilot study of treatment with rituximab in patients with early diffuse cutaneous systemic sclerosis. *Acta Clin Belg.* Epub 2017 Sep 11.
- Oddis CV, Reed AM, Aggarwal R, et al. Rituximab in the treatment of refractory adult and juvenile dermatomyositis and adult polymyositis: a randomized, placebo-phase trial. *Arthritis Rheum.* 2013;65(2):314–324.
- Davatchi F, Shams H, Rezaipoor M, et al. Rituximab in intractable ocular lesions of Behçet's disease; randomized single-blind control study (pilot study). *Int J Rheum Dis.* 2010;13(3):246–252.
- Sadreddini S, Noshad H, Molaefard M, Noshad R. Treatment of retinal vasculitis in Behçet's disease with rituximab. *Mod Rheumatol.* 2008;18(3):306–308.
- Zhao BH, Oswald AE. Improved clinical control of a challenging case of Behçet's disease with rituximab therapy. *Clin Rheumatol.* 2014;33(1):149–150.
- Jones RB, Furuta S, Tervaert JW, et al. Rituximab versus cyclophosphamide in ANCA-associated renal vasculitis: 2-year results of a randomised trial. *Ann Rheum Dis.* 2015;74(6):1178–1182.
- Henderson SR, Copley SJ, Pusey CD, Ind PW, Salama AD. Prolonged B cell depletion with rituximab is effective in treating refractory pulmonary granulomatous inflammation in granulomatosis with polyangiitis (GPA). *Medicine (Baltimore).* 2014;93(27):e229.
- Recillas-Gispert C, Serna-Ojeda JC, Flores-Suarez LF. Rituximab in the treatment of refractory scleritis in patients with granulomatosis with polyangiitis (Wegener's). *Graefes Arch Clin Exp Ophthalmol.* 2015;253(12):2279–2284.
- Wang CH, Finkel RS, Bertini ES, et al. Consensus statement for standard of care in spinal muscular atrophy. *J Child Neurol.* 2007;22(8):1027–1049.
- Jones RB, Tervaert JW, Hauser T, et al. Rituximab versus cyclophosphamide in ANCA-associated renal vasculitis. *N Engl J Med.* 2010;363(3):211–220.
- Specks U, Merkel PA, Hoffman GS, et al. Design of the Rituximab in ANCA-Associated Vasculitis (RAVE) Trial. *Open Arthritis J.* 2011;4:1–18.
- Geetha D, Specks U, Stone JH, et al. Rituximab versus cyclophosphamide for ANCA-associated vasculitis with renal involvement. *J Am Soc Nephrol.* 2015;26(4):976–985.
- Nagafuchi H, Atsumi T, Hatta K, et al. Long-term safety and efficacy of rituximab in 7 Japanese patients with ANCA-associated vasculitis. *Mod Rheumatol.* 2015;25(4):603–608.
- Wendt M, Gunnarsson I, Bratt J, Bruchfeld A. Rituximab in relapsing or refractory ANCA-associated vasculitis: a case series of 16 patients. *Scand J Rheumatol.* 2012;41(2):116–119.
- de Menthon M, Cohen P, Pagnoux C, et al. Infliximab or rituximab for refractory Wegener's granulomatosis – long-term follow up: a prospective randomised multicentre study on 17 patients. *Clin Exp Rheumatol.* 2011;29(1 Suppl 64):S63–S71.
- Lovric S, Erdbruegger U, Kumpers P, et al. Rituximab as rescue therapy in anti-neutrophil cytoplasmic antibody-associated vasculitis: a single-centre experience with 15 patients. *Nephrol Dial Transplant.* 2009;24(1):179–185.
- Cartin-Ceba R, Golbin JM, Keogh KA, et al. Rituximab for remission induction and maintenance in refractory granulomatosis with polyangiitis (Wegener's): ten-year experience at a single center. *Arthritis Rheum.* 2012;64(11):3770–3778.
- Rhee EP, Laliberte KA, Niles JL. Rituximab as maintenance therapy for anti-neutrophil cytoplasmic antibody-associated vasculitis. *Clin J Am Soc Nephrol.* 2010;5(8):1394–1400.
- Roubaud-Baudron C, Pagnoux C, Meaux-Ruault N, et al. Rituximab maintenance therapy for granulomatosis with polyangiitis and microscopic polyangiitis. *J Rheumatol.* 2012;39(1):125–130.
- Guillevin L, Pagnoux C, Karras A, et al. Rituximab versus azathioprine for maintenance in ANCA-associated vasculitis. *N Engl J Med.* 2014;371(19):1771–1780.
- Smith RM, Jones RB, Guerry MJ, et al. Rituximab for remission maintenance in relapsing antineutrophil cytoplasmic antibody-associated vasculitis. *Arthritis Rheum.* 2012;64(11):3760–3769.
- Awad N, Hafiz S, Albeity A, Almoallim H. A case of rituximab use as an induction and maintenance of remission in ANCA-associated vasculitis. *Case Rep Rheumatol.* 2016;2016:7275860.
- Moog P, Probst M, Kuechle C, Hauser C, Heemann U, Thuermel K. Single-dose rituximab for remission induction and maintenance therapy in ANCA-associated vasculitis: a retrospective analysis of 17 patients. *Scand J Rheumatol.* 2014;43(6):519–523.
- Calich AL, Puechal X, Pugnet G, et al. Rituximab for induction and maintenance therapy in granulomatosis with polyangiitis (Wegener's): results of a single-center cohort study on 66 patients. *J Autoimmun.* 2014;50:135–141.
- Charles P, Néel A, Tieulié N, et al. Rituximab for induction and maintenance treatment of ANCA-associated vasculitides: a multi-centre retrospective study on 80 patients. *Rheumatology (Oxford).* 2014;53(3):532–539.

39. Pendergraft WF, Cortazar FB, Wenger J, et al. Long-term maintenance therapy using rituximab-induced continuous B-Cell depletion in patients with ANCA vasculitis. *Clin J Am Soc Nephrol*. 2014;9(4):736–744.
40. Besada E, Koldingsnes W, Nossent JC. Long-term efficacy and safety of pre-emptive maintenance therapy with rituximab in granulomatosis with polyangiitis: results from a single centre. *Rheumatology (Oxford)*. 2013;52(11):2041–2047.
41. Brodowska-Kania D, Rymarz A, Saracyn M, Geisler P, Niemczyk S. Zastosowanie rituksimabu w indukcji remisji ciężkiej, opornej na leczenie postaci zapalenia naczyń z obecnością przeciwciał c-ANCA – opis przypadku [Use of rituximab in the induction of remission of severe, resistant and recurrent form of polyangiitis associated with c-ANCA antibodies: case report]. *Pol Merkur Lekarski*. 2015;38(226):216–218. Polish.
42. Umezawa N, Kohsaka H, Nanki T, et al. Successful treatment of eosinophilic granulomatosis with polyangiitis (EGPA; formerly Churg-Strauss syndrome) with rituximab in a case refractory to glucocorticoids, cyclophosphamide, and IVIg. *Mod Rheumatol*. 2014;24(4):685–687.
43. Thiel J, Hassler F, Salzer U, Voll RE, Venhoff N. Rituximab in the treatment of refractory or relapsing eosinophilic granulomatosis with polyangiitis (Churg-Strauss syndrome). *Arthritis Res Ther*. 2013;15(5):R133.
44. Mohammad AJ, Hot A, Arndt F, et al. Rituximab for the treatment of eosinophilic granulomatosis with polyangiitis (Churg-Strauss). *Ann Rheum Dis*. 2016;75(2):396–401.
45. Prais D, Amir J, Nussinovitch M. Recurrent Henoch-Schönlein purpura in children. *J Clin Rheumatol*. 2007;13(1):25–28.
46. Coppo R, Andrulli S, Amore A, et al. Predictors of outcome in Henoch-Schönlein nephritis in children and adults. *Am J Kidney Dis*. 2006;47(6):993–1003.
47. Donnithorne KJ, Atkinson TP, Hinze CH, et al. Rituximab therapy for severe refractory chronic Henoch-Schönlein purpura. *J Pediatr*. 2009;155(1):136–139.
48. Pillebout E, Rocha F, Fardet L, Rybojad M, Verine J, Glotz D. Successful outcome using rituximab as the only immunomodulation in Henoch-Schönlein purpura: case report. *Nephrol Dial Transplant*. 2011;26(6):2044–2046.
49. Saadoun D, Rigon MR, Sene D, et al. Rituximab plus PEG-interferon- α /ribavirin compared with PEG-interferon- α /ribavirin in hepatitis C-related mixed cryoglobulinemia. *Blood*. 2010;116(3):326–334.
50. Saadoun D, Resche-Rigon M, Sene D, Perard L, Karras A, Cacoub P. Rituximab combined with PEG-interferon-ribavirin in refractory hepatitis C virus-associated cryoglobulinaemia vasculitis. *Ann Rheum Dis*. 2008;67(10):1431–1436.
51. De Vita S, Quartuccio L, Isola M, et al. A randomized controlled trial of rituximab for the treatment of severe cryoglobulinemic vasculitis. *Arthritis Rheum*. 2012;64(3):843–853.
52. Terrier B, Saadoun D, Sène D, et al. Efficacy and tolerability of rituximab with or without PEGylated interferon alfa-2b plus ribavirin in severe hepatitis C virus-related vasculitis: a long-term followup [sic] study of thirty-two patients. *Arthritis Rheum*. 2009;60(8):2531–2540.
53. Dammacco F, Tucci FA, Lauletta G, et al. PEGylated interferon- α , ribavirin, and rituximab combined therapy of hepatitis C virus-related mixed cryoglobulinemia: a long-term study. *Blood*. 2010;116(3):343–353.
54. Visentini M, Ludovisi S, Petrarca A, et al. A phase II, single-arm multicenter study of low-dose rituximab for refractory mixed cryoglobulinemia secondary to hepatitis C virus infection. *Autoimmun Rev*. 2011;10(11):714–719.
55. Visentini M, Tinelli C, Colantuono S, et al. Efficacy of low-dose rituximab for the treatment of mixed cryoglobulinemia vasculitis: phase II clinical trial and systematic review. *Autoimmun Rev*. 2015;14(10):889–896.
56. Petrarca A, Rigacci L, Monti M, et al. Improvement in liver cirrhosis after treatment of HCV-related mixed cryoglobulinemia with rituximab. *Dig Liver Dis*. 2007;39 (Suppl 1):S129–S133.
57. Lamprecht P, Lerin-Lozano C, Merz H, et al. Rituximab induces remission in refractory HCV associated cryoglobulinaemic vasculitis. *Ann Rheum Dis*. 2003;62(12):1230–1233.
58. Nocturne G, Dougados M, Constantin A, et al. Rituximab in the spondyloarthropathies: data of eight patients followed up in the French autoimmunity and rituximab (AIR) registry. *Ann Rheum Dis*. 2010;69(2):471–472.
59. Song IH, Heldmann F, Rudwaleit M, et al. Different response to rituximab in tumor necrosis factor blocker-naïve patients with active ankylosing spondylitis and in patients in whom tumor necrosis factor blockers have failed: a twenty-four-week clinical trial. *Arthritis Rheum*. 2010;62(5):1290–1297.
60. Kobak S, Karaarslan A, Oksel F. The efficacy and safety of rituximab in a patient with rheumatoid spondylitis. *Case Rep Rheumatol*. 2013;2013:792526.
61. Rodríguez-Escalera C, Fernández-Nebro A. The use of rituximab to treat a patient with ankylosing spondylitis and hepatitis B. *Rheumatology (Oxford)*. 2008;47(11):1732–1733.
62. Huang Y, Cheng F, Zhang X, Tang J. Marked reduction of sacroiliac joint inflammation on magnetic resonance imaging in a patient with ankylosing spondylitis after rituximab treatment. *J Rheumatol*. 2011;38(9):2083–2084.
63. Omair MA, Alnaqbi KA, Lee P. Rituximab in a patient with ankylosing spondylitis with demyelinating disease: a case report and review of the literature. *Clin Rheumatol*. 2012;31(8):1259–1261.
64. Aldhaheri F, Almtari T, Dwid N, Majdali A, Janoudi N, Almoallim H. Rituximab can induce remission in a patient with ankylosing spondylitis who failed anti-TNF- α agent. *Am J Case Rep*. 2017;18:143–147.
65. Haroon M, O’Gradaigh D, Foley-Nolan D. A case of Raynaud’s phenomenon in mixed connective tissue disease responding to rituximab therapy. *Rheumatology (Oxford)*. 2007;46(4):718–719.
66. Dunkley L, Green M, Gough A. Comment on: a case of Raynaud’s phenomenon in mixed connective tissue disease responding to rituximab therapy response. *Rheumatology (Oxford)*. 2007;46(10):1628–1629.
67. Rech J, Kallert S, Hueber AJ, Requad C, Kalden JR, Schulze-Koops H. Combination of immunoadsorption and CD20 antibody therapy in a patient with mixed connective tissue disease. *Rheumatology (Oxford)*. 2006;45(4):490–491.
68. Shabrawishi M, Albeity A, Almoallim H. Severe primary Raynaud’s disease treated with rituximab. *Case Rep Rheumatol*. 2016;2016:2053804.
69. Specks U, Fervenza FC, McDonald TJ, Hogan MC. Response of Wegener’s granulomatosis to anti-CD20 chimeric monoclonal antibody therapy. *Arthritis Rheum*. 2001;44(12):2836–2840.
70. Dalakas MC. B cells as therapeutic targets in autoimmune neurological disorders. *Nat Clin Pract Neurol*. 2008;4(10):557–567.
71. Rivera A, Chen CC, Ron N, Dougherty JP, Ron Y. Role of B cells as antigen-presenting cells in vivo revisited: antigen-specific B cells are essential for T cell expansion in lymph nodes and for systemic T cell responses to low antigen concentrations. *Int Immunol*. 2001;13(12):1583–1593.
72. Braun J, Bollow M, Neure L, et al. Use of immunohistologic and in situ hybridization techniques in the examination of sacroiliac joint biopsy specimens from patients with ankylosing spondylitis. *Arthritis Rheum*. 1995;38(4):499–505.
73. Appel H, Kuhne M, Spiekermann S, et al. Immunohistologic analysis of zygapophyseal joints in patients with ankylosing spondylitis. *Arthritis Rheum*. 2006;54(9):2845–2851.
74. Appel H, Loddenkemper C, Grozdanovic Z, et al. Correlation of histopathological findings and magnetic resonance imaging in the spine of patients with ankylosing spondylitis. *Arthritis Res Ther*. 2006;8(5):R143.
75. Dorner T. Crossroads of B cell activation in autoimmunity: rationale of targeting B cells. *J Rheumatol Suppl*. 2006;77:3–11.
76. Mintz G, Enriquez RD, Mercado U, Robles EJ, Jimenez FJ, Gutierrez G. Intravenous methylprednisolone pulse therapy in severe ankylosing spondylitis. *Arthritis Rheum*. 1981;24(5):734–736.
77. Richter MB, Woo P, Panayi GS, Trull A, Unger A, Shepherd P. The effects of intravenous pulse methylprednisolone on immunological and inflammatory processes in ankylosing spondylitis. *Clin Exp Immunol*. 1983;53(1):51–59.

78. Cohen SB, Emery P, Greenwald MW, et al. Rituximab for rheumatoid arthritis refractory to anti-tumor necrosis factor therapy: results of a multicenter, randomized, double-blind, placebo-controlled, phase III trial evaluating primary efficacy and safety at twenty-four weeks. *Arthritis Rheum.* 2006;54(9):2793–2806.
79. Prevo ML, van 't Hof MA, Kuper HH, van Leeuwen MA, van de Putte LB, van Riel PL. Modified disease activity scores that include twenty-eight-joint counts: development and validation in a prospective longitudinal study of patients with rheumatoid arthritis. *Arthritis Rheum.* 1995;38(1):44–48.
80. Alberici F, Smith R, Cassia M, et al. Clinical predictors of response to rituximab in ANCA-associated vasculitis: a European cohort. Poster presented at: 53rd European Renal Association–European Dialysis and Transplant Association Congress; May 21–24, 2016; Vienna, Austria.
81. Kosmidis ML, Dalakas MC. Practical considerations on the use of rituximab in autoimmune neurological disorders. *Ther Adv Neurol Disord.* 2010;3(2):93–105.

Open Access Rheumatology: Research and Reviews

Dovepress

Publish your work in this journal

Open Access Rheumatology: Research and Reviews is an international, peer-reviewed, open access journal publishing original research, reports, editorials, reviews and commentaries on all aspects of clinical and experimental rheumatology in the clinic and laboratory including the following topics: Pathology, pathophysiology of rheumatological diseases; Investigation, treatment and

management of rheumatological diseases; Clinical trials and novel pharmacological approaches for the treatment of rheumatological disorders. The manuscript management system is completely online and includes a very quick and fair peer-review system, which is all easy to use. Visit <http://www.dovepress.com/testimonials.php> to read real quotes from published authors.

Submit your manuscript here: <https://www.dovepress.com/open-access-rheumatology-research-and-reviews-journal>