

# Perfluorocarbon liquid-assisted intraocular foreign body removal

Cindy Ung  
Inês Laíns  
Thanos D Papakostas  
Safa Rahmani  
John B Miller

Retina Service, Massachusetts Eye and Ear, Harvard Medical School, Boston, MA, USA

**Abstract:** We describe the benefits of perfluoro-N-octane (PFO), a perfluorocarbon liquid, in the removal of nonmagnetic intraocular foreign bodies (IOFBs) from the macula and posterior segment. Two consecutive cases of posterior segment IOFB were reviewed. An 18-year-old male presented to the emergency room after a motor vehicle accident with a zone 1 open globe injury and large glass IOFB in the left eye. A 53-year-old male presented to the emergency room with a history of a 3-week delayed presentation of a zone 1 open globe injury from a nail to the right eye. He was found to have a metallic IOFB. In both cases, PFO was used to slide the nonmagnetic IOFBs outside of the macula for safer retrieval. PFO was also able to protect the posterior pole from IOFB drops during early attempts at removal. PFO can be a useful surgical adjunct to pars plana vitrectomy in the removal of certain nonmagnetic IOFBs.

**Keywords:** intraocular foreign body, trauma, open globe, perfluorocarbon liquid

## Introduction

The presence of an intraocular foreign body (IOFB) is a common and serious ocular injury, accounting for up to 40% of all penetrating ocular injuries.<sup>1-3</sup> The composition of IOFBs varies from glass, plastic, organic material or metals.<sup>4</sup> Among them, metallic IOFBs (such as zinc, nickel, aluminum, mercury, iron and copper) are the most common, with approximately half being magnetic.<sup>1,5</sup> Posterior segment IOFBs can be removed through the entry or exit wound, pars plana sclerostomy that can be enlarged, a scleral tunnel or a corneoscleral limbal wound.<sup>6</sup>

Extraction of the IOFB is an important step associated with many potential complications. PPV and the use of specially designed instruments such as intraocular magnets and forceps allow surgeons to extract IOFBs. Intraocular magnets allow for elevation of small metallic IOFBs safely away from the retina, but have limited effectiveness with larger objects and are of no use with nonmagnetic IOFBs. Nonmagnetic IOFBs need to be retrieved with specialized forceps and present a particular challenge in that vitreous manipulation and traction may lead to retinal tears.<sup>7</sup> Insufficient grasping by the intraocular forceps can also lead to dislodging of the IOFB and secondary iatrogenic injury to the retina or optic nerve.

Perfluorocarbon liquids (PFCLs) have been widely adopted for vitreoretinal surgery. Due to their chemical and physical properties, including optical clarity, high specific gravity, low viscosity and immiscibility in water, they offer advantages, especially for retinal detachment (RD) surgery.<sup>8-10</sup> PFCLs are used most commonly to flatten retinal folds, displace subretinal fluid and stabilize the retina during complex maneuvers. They can also be quite helpful in the removal of some IOFBs, as described in one prior report where the IOFB was lifted into the anterior vitreous to facilitate extraction.<sup>11</sup>

Correspondence: John B Miller  
Retina Service, Massachusetts Eye and Ear, Harvard Medical School, 243 Charles St, Boston, MA 02114, USA  
Tel +1 617 573 3750  
Fax +1 617 573 3698  
Email john\_miller@meei.harvard.edu

Herein, we present two cases in which perfluoro-N-octane (PFO), a PFCL, was used to move the nonmagnetic IOFBs away from vision critical structures in the posterior pole, thus allowing their safer retrieval. Furthermore, PFO was able to protect the posterior pole from IOFB drops during initial attempts of removal from the eye. By assisting retrieval and protecting the macula, PFO is a useful adjunct for the surgical removal of certain nonmagnetic IOFBs.

## Methods

Two consecutive cases of posterior IOFBs involving the macula were reviewed. Patients were evaluated and treated for open globe injuries at Massachusetts Eye and Ear Infirmary, according to a previously published standardized protocol.<sup>12</sup> Upon arrival to the emergency room, a comprehensive ophthalmic examination was completed. A noncontrast computed tomography scan with thin cuts through the orbits was also obtained. Both surgeries were performed by the same surgeon (JBM). The details of both cases are included in an ocular trauma database as part of a Massachusetts Eye and Ear Institutional Review Board approved protocol.

## Case reports

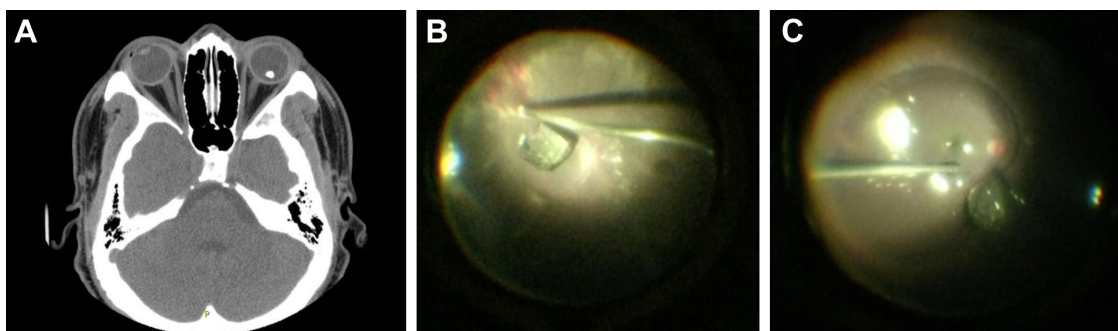
### Case 1: glass IOFB

An 18-year-old male presented to the emergency room after a motor vehicle accident with a zone 1 open globe injury in the left eye. His visual acuity was 20/20 in the right eye and LP in the left eye. Intraocular pressures were 14 mm Hg in the right eye and 4 mm Hg in the left eye. Slit-lamp examination of the left eye showed a large superotemporal curvilinear corneal laceration spanning 5 clock hours with uveal prolapse. The anterior chamber was noted to be flat with iris against the posterior cornea. Dilated fundus examination revealed vitreous hemorrhage. Examination of the right eye was unremarkable. Orbital CT imaging demonstrated a

radiopaque foreign body in the posterior aspect of the vitreous of the left globe measuring 6–7 mm (Figure 1A). The patient underwent a primary open globe repair by the trauma service and was then referred to retina for IOFB removal. He underwent 23-gauge pars plana vitrectomy (Constellation; Alcon, Fort Worth, TX, USA). Intraoperatively, there was a large glass foreign body located in the macula with surrounding vitreous hemorrhage (Figure 1B). After core vitrectomy and removal of the vitreous surrounding the IOFB, 1 mL of PFO was slowly injected over the macula, displacing the foreign body past the arcades (Figure 1C). Its removal was then attempted with a 19-gauge Grieshaber diamond-dusted IOFB forceps (Alcon), but this instrument was unable to get a good hold of the foreign body given its large size and smooth, slippery edges. A superior scleral tunnel was performed using a crescent blade to facilitate the IOFB removal. A 23-gauge soft tip extrusion cannula (Alcon) was used to elevate the IOFB into the anterior chamber with assistance from the light pipe. Despite dropping the IOFB a few times, the PFO bubble was able to protect the macula from any iatrogenic injury. The IOFB was then removed from the anterior chamber via the previously initiated scleral tunnel with a 0.5 forceps and a sheets glide. Postoperatively at 1-year follow up, he had light perception vision in the setting of significant corneal scarring, but the retina remained attached (Table 1). A video demonstrating the technique in case 1 is available ([Video S1](#)).

### Case 2: metallic IOFB

A 53-year-old male presented to the emergency room with a history of a 3-week delayed presentation of a zone 1 open globe injury from a nail injury in the right eye. The patient presented after noticing progressively decreased vision. Visual acuity at presentation was hand motion in the right eye and 20/20 in the left eye. Intraocular pressure was 11 mm Hg



**Figure 1** Case 1 with glass IOFB. (A) Axial orbital CT with IOFB in the posterior segment of the left eye. (B) Intraoperative image of glass IOFB near the macula. (C) PFO moving glass IOFB away from macula.

**Abbreviations:** CT, computed tomography; IOFB, intraocular foreign body; PFO, perfluoro-N-octane.

**Table 1** Pre-op and post-op visual acuities of IOFB cases

	Pre-op visual acuity	Post-op visual acuity (1-year follow-up)
Case 1: glass IOFB	Light perception	Count fingers
Case 2: metallic IOFB	Light perception	Count fingers

**Abbreviations:** IOFB, intraocular foreign body; post-op, postoperative; pre-op, preoperative.

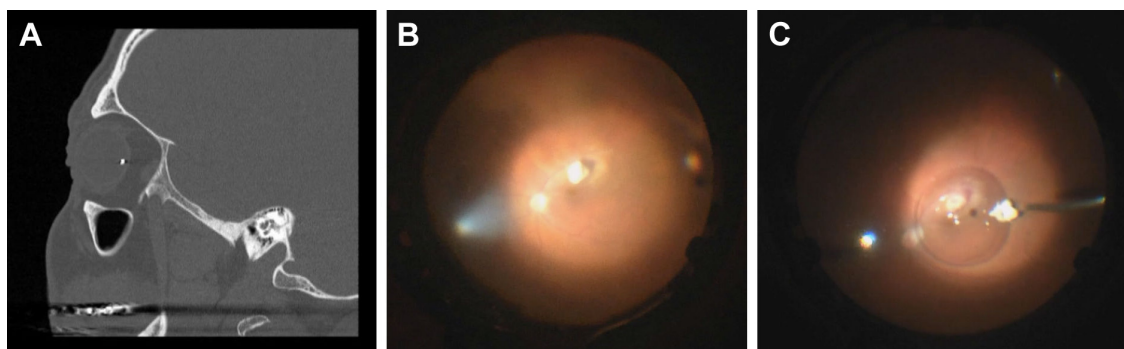
in the right eye and 13 mm Hg in the left eye. There was an afferent pupillary defect in the right eye. Slit-lamp examination revealed a large self-sealing corneal laceration with iris incarceration, hyphema and peaked pupil in the right eye. Examination of the left eye was unremarkable. Orbital CT imaging revealed a 2 mm metallic foreign body in the posterior segment (Figure 2A). After providing written informed consent, the patient underwent phacoemulsification cataract extraction and 23-gauge pars plana vitrectomy (Constellation; Alcon). The metallic IOFB was embedded into the inferior macula, with underlying retinal whitening and dense vitreous hemorrhage (Figure 2B). Vitreous adherent to IOFB was cut until it became free from all adhesions. A small bubble of PFO was injected to displace the IOFB and protect the macula during removal (Figure 2C). Multiple attempts were made to remove the IOFB with Grieshaber max grip forceps (Alcon) and an intraocular magnet. However, neither the magnet nor max grip forceps were able to create a firm enough adhesion to remove the IOFB. The PFO bubble protected the macula and allowed the IOFB to slide to an extramacular location. Ultimately, an additional superior sclerotomy site was created with an MVR blade (Alcon) and the foreign body was successfully removed with IOFB forceps. Then, 3 months after surgery, the patient developed a macula-off RD due to proliferative vitreoretinopathy at the previous strike site, which was repaired with additional surgery. After 1 year, the retina remained attached with hand motions vision.

## Discussion

The association of IOFBs with ruptured globes is a leading cause of visual impairment in ocular trauma. Posterior segment IOFBs increase the risk of retinal breaks and detachments, subretinal fibrosis, choroidal hemorrhage and epiretinal membranes.<sup>13,14</sup> Prompt removal is recommended. Although surgical instrumentation and techniques have improved, there is a high rate of complications related to removal of IOFBs.<sup>13,14</sup> Here, we report two cases on the use of PFO to facilitate the removal of posterior segment IOFBs and to protect the macula from iatrogenic damage.

The use of PFCL during vitrectomy constitutes a major advance in vitreoretinal surgery. Its higher-than-water specific gravity, along with the immiscibility of PFCLs with water, allows the surgeon to use PFO as a tamponading agent. Its low viscosity also enables easy intraocular injection and removal. Several studies have reported the utility of PFCLs in the management of IOFB. PFO, in particular, has been used to float various materials off the posterior retina,<sup>11</sup> to prevent the spread of hemorrhages and RD during IOFB removal,<sup>14</sup> and to stabilize and make grasping easier for sinking IOFBs.<sup>15</sup>

In our first case, the patient had a perforating injury following a motor vehicle accident with a large glass foreign body located in the macula. We were able to inject PFO to mobilize the IOFB outside the arcades. Ruddat and Johnson<sup>11</sup> first reported the use of PFO to float a large glass foreign body up into the anterior vitreous cavity. In this report, they commented that buoyancy alone could not explain the ability of glass to float on PFO, as the specific gravity of glass (2.2–2.8) exceeds that of PFO (1.76–2.03). In further studies, the same authors demonstrated that all materials denser than PFO, regardless of size, sank when placed on PFO in an air-filled breaker. However, they found that dense specimens had a



**Figure 2** Case 2 with metallic IOFB. (A) Axial orbital CT with IOFB in the posterior segment of the left eye. (B) Intraoperative image of glass IOFB near the macula. (C) PFO moving metallic IOFB away from macula.

**Abbreviations:** CT, computed tomography; IOFB, intraocular foreign body; PFO, perfluoro-N-octane.

higher affinity for saline than for PFO and floated stably at the saline–PFO interface. Therefore, the ability of PFO to support IOFBs of higher density lies in the adhesive force between the material and saline. The magnitude of this adhesive force, which is proportional to the surface area of the specimen, is strong enough to overcome the gravity for small specimens.<sup>16</sup> Thus, PFCL can levitate large foreign bodies for extraction through either the corneal wound or pars plana.

Another challenge encountered during IOFB removal is that current vitreoretinal forceps may be inadequate to ensure a secure grasp of the object. This occurred in case 1, given the large size and slippery surface of the glass IOFB. In these situations, careful attention should be made to avoid slippage, as dropping an IOFB during removal can cause damage to the macula, retinal breaks and hemorrhages. Prior experimental studies suggest that PFO may not support a metallic foreign body.<sup>17</sup> However, this report demonstrates two examples where the injection of PFO protected the macula with both glass and metallic IOFBs.

In our second case, we were able to utilize PFO to first slide the metal IOFB away from the macula and protect the macula from any iatrogenic drop injury during early failed attempts at retrieval. Care was taken to prevent the foreign body from damaging the macula, as its preservation is correlated with good visual outcomes.<sup>3,18</sup> This protective shielding of the macula with PFO was examined by Shah et al<sup>19</sup> who tested the impact of various dropped metallic IOFBs in a model eye. With the exception of the heaviest IOFB, all the remaining IOFBs were deflected by the PFO–balanced salt solution (BSS) interface in at least 99% of the tests. Similar to what had been described by Ruddat and Johnson,<sup>11</sup> deflection of the dropped IOFBs in this study occurred at the interface between the PFO and BSS primarily as a result of the PFO–BSS interfacial tension. This interfacial tension acts as a protective barrier and is able to divert the falling IOFB and deflect it away from the macula. These additional studies further support our clinical examples that PFO may be used as a protective method by retinal surgeons during the removal of IOFBs.

Removal of IOFBs is challenging as IOFBs can be frequently dropped on the macula, causing iatrogenic retinal breaks. Both cases demonstrate that the use of PFO can protect the posterior pole from intraoperative falling and trauma during grabbing of two different types of IOFBs, both metal and glass. Neither of our cases developed a macular injury despite difficult removals due to size, shape and nonmagnetic characteristics of the IOFB. Further studies

on the visual outcomes of these patients and secondary RDs are warranted.

## Conclusion

Surgical extraction of IOFBs can be challenging. Here, we have described the use of PFO to facilitate the removal of IOFBs and to protect the macula during removal attempts. We have shown that intraoperative PFCL may be a safe and useful surgical adjunct to pars plana vitrectomy in the management of IOFBs.

## Disclosure

The authors report no conflicts of interest in this work.

## References

1. Greven CM, Engelbrecht NE, Slusher MM, Nagy SS. Intraocular foreign bodies: management, prognostic factors, and visual outcomes. *Ophthalmology*. 2000;107(3):608–612.
2. Woodcock MG, Scott RA, Huntbach J, Kirkby GR. Mass and shape as factors in intraocular foreign body injuries. *Ophthalmology*. 2006; 113(12):2262–2269.
3. Zhang Y, Zhang M, Jiang C, Qiu HY. Intraocular foreign bodies in China: clinical characteristics, prognostic factors, and visual outcomes in 1,421 eyes. *Am J Ophthalmol*. 2011;152(1):66.e1–73.e1.
4. Upshaw JE, Brenkert TE, Losek JD. Ocular foreign bodies in children. *Pediatr Emerg Care*. 2008;24(6):409–414; quiz 415–417.
5. Williams DF, Mieler WF, Abrams GW, Lewis H. Results and prognostic factors in penetrating ocular injuries with retained intraocular foreign bodies. *Ophthalmology*. 1988;95(7):911–916.
6. Riemann CD, Mehta MC, Yeh EC. Innovative use of a magnetized pick for removal of an intraocular foreign body with 25-gauge transconjunctival sutureless vitrectomy. *Retin Cases Brief Rep*. 2011;5(4):330–332.
7. Gopal L, Banker AS, Deb N, et al. Management of glass intraocular foreign bodies. *Retina*. 1998;18(3):213–220.
8. Lopez R, Chang S. Long-term results of vitrectomy and perfluorocarbon gas for the treatment of severe proliferative vitreoretinopathy. *Am J Ophthalmol*. 1992;113(4):424–428.
9. Chang S. Perfluorocarbon liquids in vitreoretinal surgery. *Int Ophthalmol Clin*. 1992;32(2):153–163.
10. Soheilian M, Peyman GA, Wafapoor H, Navarro GC, Thompson H. Surgical management of traumatic retinal detachment with perfluorocarbon liquid. The Vitreous Study Group. *Int Ophthalmol*. 1996–1997; 20(5):241–249.
11. Ruddat MS, Johnson MW. The use of perfluorocarbon liquid in the removal of radiopaque intraocular glass. *Arch Ophthalmol*. 1995;113(12): 1568–1569.
12. Andreoli CM, Andreoli MT, Kloek CE, Ahuero AE, Vavvas D, Durand ML. Low rate of endophthalmitis in a large series of open globe injuries. *Am J Ophthalmol*. 2009;147(4):601.e2–608.e2.
13. Ahmadieh H, Sajjadi H, Azarmina M, Soheilian M, Baharivand N. Surgical management of intraretinal foreign bodies. *Retina*. 1994;14(5): 397–403.
14. Slusher MM. Intraretinal foreign bodies. Management and observations. *Retina*. 1990;10 Suppl 1:S50–S54.
15. Vartanyan AH, Hovhannisyan TA. Application of perfluorocarbon liquid in the removal of metallic intraretinal foreign bodies. *Med Sci Monit*. 2002;8(2):CR66–CR71.
16. Sudhalkar HA, Johnson MW. Perfluorocarbon liquid manipulation of high-density intraocular foreign bodies. *Retina*. 1998;18(5):460–465.

17. Ernst BJ, Velez-Montoya R, Kujundzic D, Kujundzic E, Olson JL. Experimental measure of retinal impact force resulting from intraocular foreign body dropped onto retina through media of differing viscosity. *Clin Exp Ophthalmol*. 2013;41(5):471–475.
18. Ehlers JP, Kunimoto DY, Ittoop S, Maguire JI, Ho AC, Regillo CD. Metallic intraocular foreign bodies: characteristics, interventions, and prognostic factors for visual outcome and globe survival. *Am J Ophthalmol*. 2008;146(3):427–433.
19. Shah CM, Gentile RC, Mehta MC. Perfluorocarbon liquids' ability to protect the macula from intraocular dropping of metallic foreign bodies: a model eye study. *Retina*. 2016;36(7):1285–1291.



## Supplementary material

**Video S1** This video highlights the ability of PFO to move the large glass intraocular foreign body away from the center of the fovea in case 1. A scleral tunnel, sheets glide, viscoelastic and 0.5 forceps were used to remove the piece of glass.

**Abbreviation:** PFO, perfluoro-N-octane.

### Clinical Ophthalmology

Dovepress

### Publish your work in this journal

Clinical Ophthalmology is an international, peer-reviewed journal covering all subspecialties within ophthalmology. Key topics include: Optometry; Visual science; Pharmacology and drug therapy in eye diseases; Basic Sciences; Primary and Secondary eye care; Patient Safety and Quality of Care Improvements. This journal is indexed on

Submit your manuscript here: <http://www.dovepress.com/clinical-ophthalmology-journal>

PubMed Central and CAS, and is the official journal of The Society of Clinical Ophthalmology (SCO). The manuscript management system is completely online and includes a very quick and fair peer-review system, which is all easy to use. Visit <http://www.dovepress.com/testimonials.php> to read real quotes from published authors.